

## **Cysticerci of *Taenia mustelae* in the Fox Squirrel**

Authors: Langham, R. F., Rausch, R. L., and Williams, J. F.

Source: Journal of Wildlife Diseases, 26(2) : 295-296

Published By: Wildlife Disease Association

URL: <https://doi.org/10.7589/0090-3558-26.2.295>

---

The BioOne Digital Library (<https://bioone.org/>) provides worldwide distribution for more than 580 journals and eBooks from BioOne's community of over 150 nonprofit societies, research institutions, and university presses in the biological, ecological, and environmental sciences. The BioOne Digital Library encompasses the flagship aggregation BioOne Complete (<https://bioone.org/subscribe>), the BioOne Complete Archive (<https://bioone.org/archive>), and the BioOne eBooks program offerings ESA eBook Collection (<https://bioone.org/esa-ebooks>) and CSIRO Publishing BioSelect Collection (<https://bioone.org/csiro-ebooks>).

Your use of this PDF, the BioOne Digital Library, and all posted and associated content indicates your acceptance of BioOne's Terms of Use, available at [www.bioone.org/terms-of-use](http://www.bioone.org/terms-of-use).

Usage of BioOne Digital Library content is strictly limited to personal, educational, and non-commercial use. Commercial inquiries or rights and permissions requests should be directed to the individual publisher as copyright holder.

---

BioOne is an innovative nonprofit that sees sustainable scholarly publishing as an inherently collaborative enterprise connecting authors, nonprofit publishers, academic institutions, research libraries, and research funders in the common goal of maximizing access to critical research.

## Cysticerci of *Taenia mustelae* in the Fox Squirrel

R. F. Langham,<sup>1</sup> R. L. Rausch,<sup>2</sup> and J. F. Williams,<sup>3</sup> <sup>1</sup> Department of Pathology and the Animal Health Diagnostic Laboratory, College of Veterinary Medicine, Michigan State University, East Lansing, Michigan 48824, USA; <sup>2</sup> University of Washington, Department of Comparative Medicine SB-42, Seattle, Washington 98195, USA; <sup>3</sup> Department of Microbiology and Public Health, Michigan State University, East Lansing, Michigan 48824, USA

**ABSTRACT:** The liver of a fox squirrel (*Sciurus niger rufiventer*) contained many clear, spherical cysts approximately 1 mm in diameter throughout the parenchyma. On dissection, most of these exhibited a dense, white area with four muscular suckers at a single point on the bladder. Based on the size of the organisms, the characteristically tiny hooks on the scolex and the location of the cysts in this host, the parasites were identified as cysticerci of *Taenia mustelae*. This is the first report in this host. The parasites were surrounded by an intense inflammatory response consisting primarily of lymphocytes mixed with some eosinophils, and early deposition of fibrous connective tissue.

**Key words:** Fox squirrel, *Sciurus niger rufiventer*, case report, cysticercosis, larval cestodes, *Taenia mustelae*, hooklets.

The liver of a hunter-killed fox squirrel (*Sciurus niger rufiventer*) at the Rose Lake Research Center (Rose Lake, Michigan, USA; 42°50'N, 83°50'W) contained many clear, spherical cysts approximately 1 mm in diameter throughout the parenchyma (Fig. 1). On dissection, most of these contained a dense, white area with four muscular suckers at a single point on the bladder. Identification of these larval cestodes was made possible by the detection of a ring of 30 to 60 extremely small hooks (Fig. 2), each of which was about 20  $\mu$ m in length. The parasites were surrounded by an intense inflammatory response, consist-

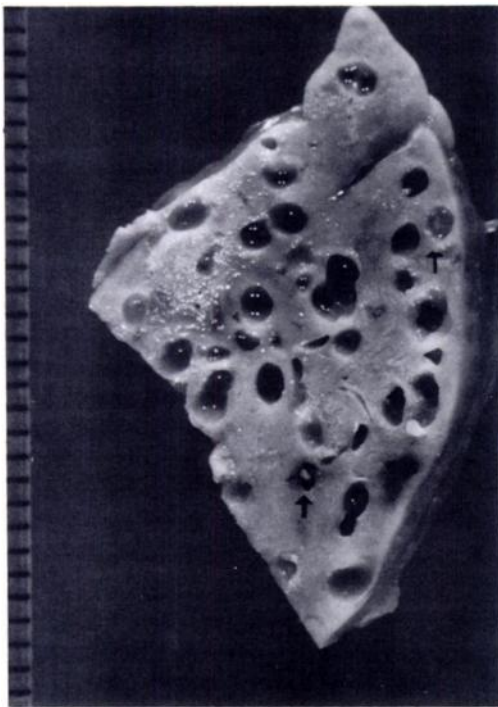


FIGURE 1. Sagittal section of liver of fox squirrel with cysts and cysticerci (arrows) of *Taenia mustelae*. Scale divisions = 1 mm.

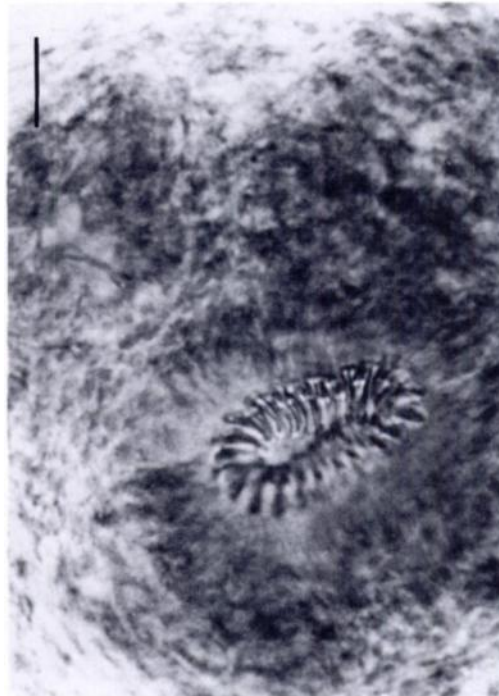

FIGURE 2. Scolex of *Taenia mustelae* showing small hooks measuring about 20  $\mu$ m in length. Bar = 40  $\mu$ m.

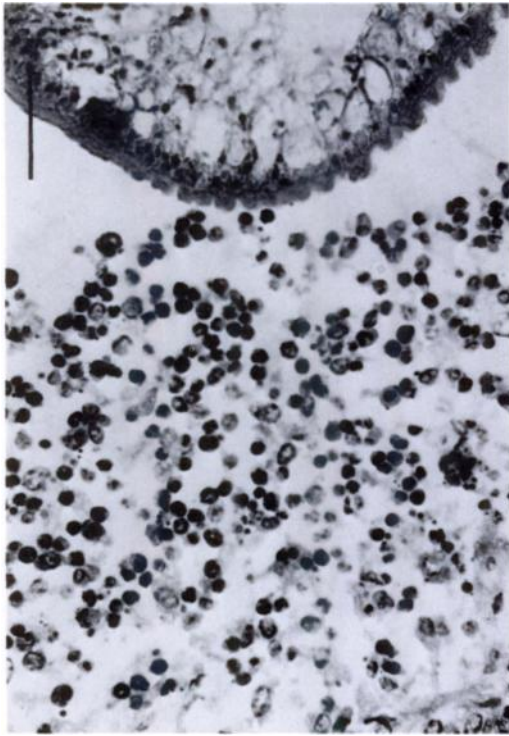


FIGURE 3. Tissue section of liver of fox squirrel infected with cysticerci of *Taenia mustelae*. Note section of cestode cysticerci and adjacent lymphocyte and eosinophil inflammatory response. Bar = 100  $\mu$ m. H&E.

ing primarily of lymphocytes mixed with some eosinophils, and there was early deposition of fibrous connective tissue (Fig. 3). Patches of necrosis and hemorrhage were distributed throughout the paren-

chyma; this was suggestive of recent damage by the migration of metacestodes.

On the basis of the size of the organisms, the characteristically tiny hooks on the scolex and the location of the cysts in this host, these parasites were identified as the cysticerci of *Taenia mustelae* (formerly designated *T. tenuicollis*), which develops to the strobilar stage in the intestine of small carnivores of the family Mustelidae (Freeman, 1956; Mahrt and Chai, 1972). The species has been reported previously in North America from several species of rodents, including a red squirrel (*Tamiasciurus hudsonicus*) in Alberta (Canada). In this host the parasite was a cysticercus as seen in the present case, but the larval stage can apparently assume a polycephalic form in some hosts (Mahrt and Chai, 1972). Although the liver is the most commonly affected organ, cysts in subcutaneous foci, on the mesentery and in thoracic and pericardial cavities are frequently seen in naturally infected rodents (Mahrt and Chai, 1972).

#### LITERATURE CITED

- FREEMAN R. S. 1956. Life history studies on *Taenia mustelae* Gmelin, 1790 and the taxonomy of certain Taenioid cestodes from Mustelidae. Canadian Journal of Zoology 54: 219-242.
- MAHRT, J. L., AND S. J. CHAI. 1972. Parasites of red squirrels in Alberta, Canada. The Journal of Parasitology 58: 639-640.

Received for publication 20 December 1988.