



EPIDEMIOLOGIC FEATURES OF AN INTRACRANIAL ABSCESSATION/SUPPURATIVE MENINGOENCEPHALITIS COMPLEX IN WHITE-TAILED DEER

Authors: Davidson, William R., Nettles, Victor F., Hayes, Lynn E., Howerth, Elizabeth W., and Couvillion, C. Edward

Source: Journal of Wildlife Diseases, 26(4) : 460-467

Published By: Wildlife Disease Association

URL: <https://doi.org/10.7589/0090-3558-26.4.460>

BioOne Complete (complete.BioOne.org) is a full-text database of 200 subscribed and open-access titles in the biological, ecological, and environmental sciences published by nonprofit societies, associations, museums, institutions, and presses.

Your use of this PDF, the BioOne Complete website, and all posted and associated content indicates your acceptance of BioOne's Terms of Use, available at www.bioone.org/terms-of-use.

Usage of BioOne Complete content is strictly limited to personal, educational, and non - commercial use. Commercial inquiries or rights and permissions requests should be directed to the individual publisher as copyright holder.

BioOne sees sustainable scholarly publishing as an inherently collaborative enterprise connecting authors, nonprofit publishers, academic institutions, research libraries, and research funders in the common goal of maximizing access to critical research.

EPIDEMIOLOGIC FEATURES OF AN INTRACRANIAL ABCESSATION/SUPPURATIVE MENINGOENCEPHALITIS COMPLEX IN WHITE-TAILED DEER

William R. Davidson,^{1,2} Victor F. Nettles,¹ Lynn E. Hayes,¹
Elizabeth W. Howerth,^{1,3} and C. Edward Couvillion^{1,4}

¹ Southeastern Cooperative Wildlife Disease Study, Department of Parasitology,
College of Veterinary Medicine, The University of Georgia,
Athens, Georgia 30602 USA

² School of Forest Resources, The University of Georgia, Athens, Georgia 30602 USA

³ Present address: Department of Pathology, College of Veterinary Medicine,
The University of Georgia, Athens, Georgia 30602 USA

⁴ Present address: Department of Parasitology, College of Veterinary Medicine,
Mississippi State University, Mississippi State, Mississippi 39762 USA

ABSTRACT: Case records of 683 white-tailed deer (*Odocoileus virginianus*) submitted to the Southeastern Cooperative Wildlife Disease Study (Georgia, USA) for diagnostic purposes from 1971 to 1989 were reviewed for the occurrence of pyogenic infections of the central nervous system, specifically intracranial abscessation or suppurative meningoencephalitis. These conditions, either alone or in combination, were diagnosed in 24 of 683 (4%) deer. Thirteen genera of bacteria were isolated; the most frequent species was *Actinomyces pyogenes*. The disease was strongly sex biased ($P < 0.01$); 88% of the cases occurred in males. Cases were more prevalent ($P < 0.05$) in older bucks; the median age of infected bucks was 3.2 yr, and 71% of these were ≥ 2.5 -yr-old. Intracranial abscessation/suppurative meningoencephalitis cases accounted for 20% of the diagnoses among 56 bucks ≥ 3 -yr-old. Cases were seasonal, occurring only from October to April. Characteristic necrosis, erosion, and pitting of skull bones were common, and this bone damage may be useful in determining cause of death when only skeletal remains are found. Males, especially older bucks, apparently are predisposed to intracranial abscessation/suppurative meningoencephalitis because of the cycle of antler development and behavioral traits associated with reproduction. The strong bias toward prime age bucks suggests that these infections could specifically hinder management strategies designed to produce populations with older buck age structures.

Key words: White-tailed deer, *Odocoileus virginianus*, intracranial abscesses, meningoencephalitis, *Actinomyces pyogenes*, case reports, epidemiology.

INTRODUCTION

Pyogenic infections of the central nervous system, including intracranial abscesses and suppurative meningoencephalitis, occur in many species of mammals. These infections, especially cerebral abscesses, are considered particularly common among domestic ungulates compared to other mammalian taxa (Blood et al., 1983). Cerebral abscesses have been reported among domestic sheep (Hull and Taylor, 1941; Hartley and Kater, 1962; Andrews and Ingram, 1982), cattle (Griner et al., 1956), water buffalo (Lal and Verma, 1979), and horses (DeLahunta, 1973; Ford and Lokai, 1980; Raphael, 1982). Intracranial abscesses also occur in captive wild ungulates such as musk ox (*Ovibos*

moschatus) and Barbados sheep (*Musimus* spp.) (Beckley and Dieterich, 1970; Amand et al., 1973). In contrast to domestic and captive wild ungulates, reports of intracranial abscesses in wild, free-ranging ungulates are rare, especially among the Cervidae. Johnson et al. (1983) reported a single case in a mule deer (*Odocoileus hemionus hemionus*), and Davidson and Nettles (1988) briefly reviewed certain aspects of brain abscesses among white-tailed deer (*Odocoileus virginianus*) but did not provide detailed case data.

Since 1971 we have examined numerous white-tailed deer submitted to the Southeastern Cooperative Wildlife Disease Study (SCWDS; College of Veterinary Medicine, The University of Georgia, Athens, Geor-

gia 30602, USA) for diagnostic purposes. During these activities we encountered several cases of pyogenic infections of the central nervous system, predominately cerebral abscesses. This report reviews these cases, focusing on certain epidemiologic features of this disease in white-tailed deer.

MATERIALS AND METHODS

Necropsy records on white-tailed deer submitted to SCWDS by state and federal wildlife agency personnel from 1 January 1971 through 30 June 1989 were searched for instances of pyogenic infections of the central nervous system. The criteria for inclusion of a case were either (1) the presence of obvious purulent material within the cranial vault detected grossly at necropsy or (2) microscopic lesions of the brain or cerebral meninges characterized as suppurative. Data retrieved from each case record were the point of origin, date of submission, clinical signs, lesion descriptions, species of bacteria isolated, host age and sex, and the status of antler development for bucks. Necropsy and laboratory diagnostic procedures were at the discretion of the diagnostician responsible for the case, and consequently the tests performed and amount of laboratory work varied among cases. Aerobic and anaerobic bacterial isolations from swabs taken of lesions were conducted according to standard methods by either the Department of Medical Microbiology or the Athens Diagnostic Laboratory (College of Veterinary Medicine, The University of Georgia, Athens, Georgia 30602, USA). Bacteria isolated were identified to at least the generic level. Tissues were preserved in 10% neutral buffered formalin, processed for histopathologic study by standard methods, and examined microscopically. Since 1980, skulls of affected animals often were retained for removal of soft tissues to facilitate the evaluation of bone damage associated with abscesses. Prevalence data were evaluated for differences between deer sexes by a Chi square test. Prevalence data among bucks were evaluated for differences among age classes by a G-test of independence (Sokal and Rohlf, 1981) and by odds ratio methodology (Martin et al., 1987). The age structure of adult (≥ 1.5 yr) bucks submitted for diagnostic examination was compared to the age structure of hunter-harvested bucks in Georgia (Allen, 1987) by a G-test for goodness of fit (Sokal and Rohlf, 1981) in order to determine whether the frequency of intracranial abscesses in diagnostic submissions could be assumed to be representative of their occurrence in bucks in the wild.

RESULTS

Among necropsy records of 683 white-tailed deer (331 males, 352 females) submitted to SCWDS for diagnostic evaluation were 24 cases that fit the criteria for case selection (Table 1). All were free-ranging, wild deer except for one male that had been raised since birth in a large outdoor enclosure. Case history information varied considerably, and clinical signs contained in the histories often were observations by individuals that found the deer. Clinical signs were not available for three animals that were found dead. The frequency of clinical signs reported for the remaining 21 animals found alive were incoordination (12 cases), lack of fear (5), blindness (4), weakness (4), profound depression (4), emaciation (2), circling (2), and single instances of torticollis, bilateral horizontal nystagmus, lameness, fever, and anorexia.

Fourteen cases involved only well-defined intracranial abscesses (Fig. 1), six cases were diffuse suppurative meningoencephalitis, and four cases were a combination of well-defined abscesses and suppurative meningoencephalitis. Abscesses most often involved one cerebral hemisphere, although in a few cases both cerebral hemispheres were affected. Abscesses occurred less frequently in the cerebellum or brain stem. Abscesses typically were from 1 to 3 cm in diameter, contained off-white, yellow or pale green viscous pus, and were surrounded by an intense inflammatory reaction. Those cases characterized a suppurative meningitis had extensive involvement of the majority of the cranial meninges.

Examination of cleaned skulls of bucks disclosed necrosis, erosion, and pitting of cranial bones. Bone lesions occurred on the external surfaces of the parietal and frontal bones usually on or near the antler pedicels (Fig. 2). Erosions often extended into the cranium through sutures between the frontal bones or between the frontal and parietal bones (Fig. 3). Several factors that

TABLE 1. Cases of cerebral abscesses among 683 white-tailed deer submitted to the SCWDS between 1971 and 1989.

Sex	County/state	Date (mo/yr)	Age (yr)	Bacteria isolated	Possible contributing factors
Males					
	Washington, North Carolina ^a	2/72	6.0	<i>Fusobacterium</i> sp.	Pulmonary abscess
	Clinch, Georgia ^a	11/73	3.5	<i>Streptococcus</i> sp. <i>Serratia</i> sp.	Subcutaneous abscess around antler pedicel
	McIntosh, Georgia ^a	4/74	5.5	<i>Actinomyces</i> sp.	Subcutaneous abscesses due to tick infestation
	Williamsburg, South Carolina ^b	10/75	3.5	<i>Actinomyces</i> sp. <i>Klebsiella</i> sp.	Subcutaneous abscesses on legs and sternum
	Grady, Georgia ^a	12/75	2.5	<i>Actinomyces</i> sp.	Subcutaneous abscess around fractured antler pedicel
	Sumter, Georgia ^a	3/78	0.8	<i>Pasteurella multocida</i> <i>Streptococcus</i> sp.	Fractured antler bud
	Chatham, Georgia ^a	11/78	5.5	Not cultured	Intraspecific trauma suspected
	Allendale, South Carolina ^a	1/79	3.5	<i>Proteus</i> sp.	Purulent otitis due to ear mites
	Beaufort, South Carolina ^c	10/79	1.5	<i>Actinomyces pyogenes</i>	Fractured antler pedicel, abscess around pedicel
	Jasper, Georgia ^b	11/79	1.5	Not cultured	None recorded
	Wheeler, Georgia ^a	10/80	4.5	<i>Serratia marcescens</i> <i>Streptococcus</i> sp. <i>Klebsiella pneumoniae</i> <i>Proteus mirabilis</i> <i>Escherichia coli</i> <i>Hafnia alvei</i>	Purulent otitis due to ear mites
	Putnam, Georgia ^c	10/81	1.5	Not cultured	Subcutaneous abscess around antler pedicel
	Richland, South Carolina ^a	11/81	3.5	Not cultured	Subcutaneous abscesses on head
	Emanuel, Georgia ^b	2/83	4.5	<i>Citrobacter</i> sp.	Fractured antler pedicel
	Glynn, Georgia ^a	1/86	1.5	<i>Actinomyces pyogenes</i>	Fractured and abscessed antler pedicel
	Edgefield, South Carolina ^a	3/86	4.0	<i>Actinomyces pyogenes</i>	None recorded
	Leon, Florida ^a	10/86	1.5	<i>Actinomyces pyogenes</i>	Subcutaneous abscess around antler pedicel
	Clarke, Georgia ^c	2/87	4.5	<i>Serratia marcescens</i> <i>Pseudomonas</i> sp. <i>Alcaligenes dentrificans</i>	Intraspecific trauma, fractured and abscessed antler pedicel
	Jefferson, Georgia ^a	4/88	2.5	<i>Actinomyces pyogenes</i>	Abrasions at base of antlers
	Glynn, Georgia ^a	4/89	3.0	<i>Actinomyces pyogenes</i> <i>Pseudomonas aeruginosa</i> <i>Escherichia coli</i> <i>Staphylococcus</i> sp.	Subcutaneous abscesses due to tick infestation
	Richland, South Carolina ^b	4/89	3.0	<i>Actinomyces pyogenes</i> <i>Proteus</i> sp. <i>Staphylococcus</i> sp.	Fractured antler pedicel
Females					
	Liberty, Florida ^a	12/71	3.5	Not cultured	Sequellae of hemorrhagic disease
	Jefferson, Georgia ^a	4/82	2.0	Not cultured	Multiple cutaneous ulcers, laminitis
	Habersham, Georgia ^a	2/84	3.5	<i>Streptococcus acidominimus</i>	Mycotic rhinitis

^a Well demarcated cerebral abscess(es).

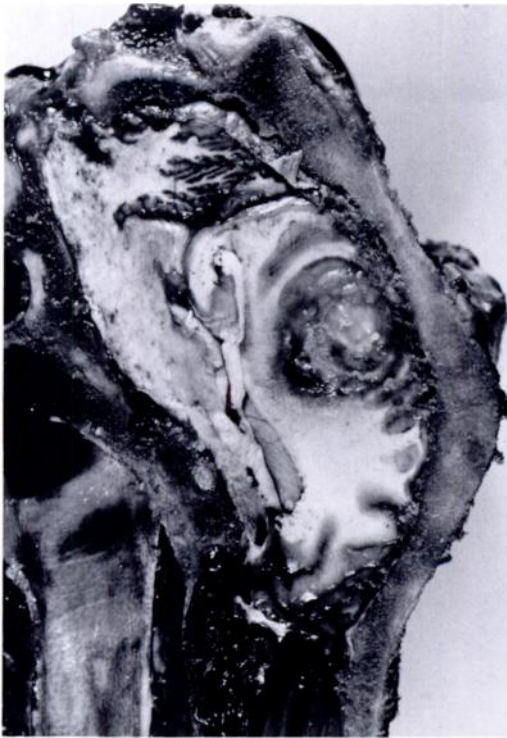

FIGURE 1. Cerebral abscess surrounded by inflammation in the cerebrum of an adult male white-tailed deer.

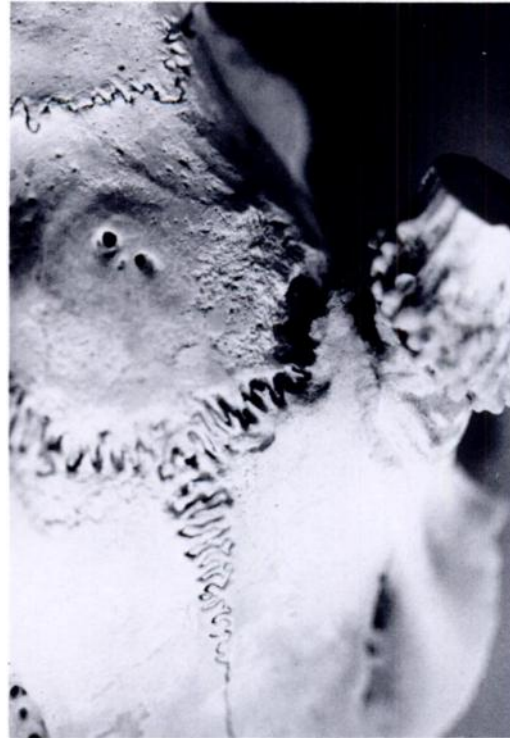

FIGURE 2. Erosion and pitting of the frontal bone and antler pedicel in an adult male white-tailed deer with a cerebral abscess.

may have contributed to development of abscesses were identified (Table 1). Fractured antler pedicels or subcutaneous abscesses around the antler pedicels were each noted in seven bucks. Records for 10 bucks contained specific descriptions of tract-like lesions extending through or between cranial bones. The following were considered contributory to formation of intracranial abscesses in two bucks each (1) subcutaneous abscesses on the head or ears due to ticks (*Amblyomma* spp.), (2) bacterial otitis due to ear mites (*Psoroptes cuniculi*), and (3) known or suspected intraspecific trauma.

Thirteen genera of bacteria were cultured from 18 animals from which isolation was attempted (Table 1). Eleven cases produced only a single species of bacte-

rium, including *Actinomyces pyogenes*, *Actinomyces* sp., *Citrobacter* sp., *Fusobacterium* sp., *Proteus* sp., and *Streptococcus acidominimus*. Multiple species were isolated from seven cases. The most frequently isolated genus was *Actinomyces* which was recovered from 10 (56%) of the 18 cases, including seven cases (39%) in which either *Actinomyces* sp. or *A. pyogenes* were the only bacteria isolated. The seven *Actinomyces* sp. that were identified to the species level were *A. pyogenes*.

Twenty-one (88%) of 24 cases were in bucks, and the frequency of occurrence in males was significantly higher ($P < 0.01$) than in females ($\chi^2 = 17.1$, $df = 1$). The frequency of cases differed significantly among age classes of males ($G = 13.8$, $df = 5$; $P < 0.05$). If males < 1 yr were as-

←

^b Both well demarcated cerebral abscess(es) and suppurative meningitis.
^c Suppurative meningitis.

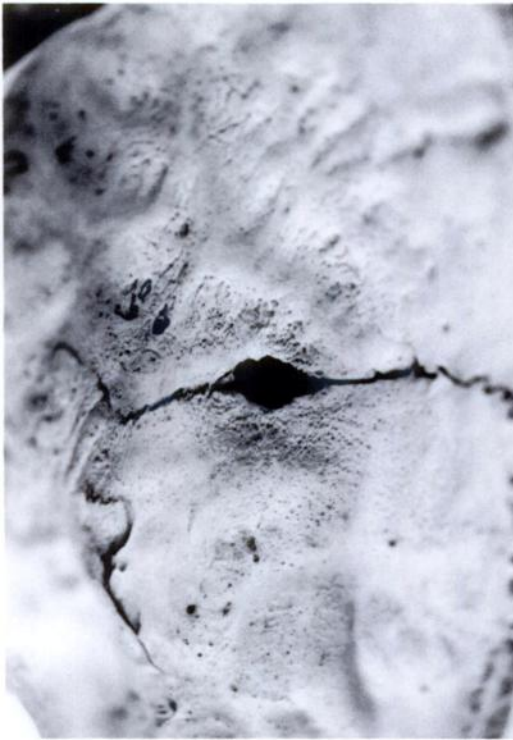

FIGURE 3. Pitting of inner surface of cranial vault adjacent to necrotic and eroded suture between frontal bones in an adult male white-tailed deer which had a cerebral abscess.

signed a risk factor of 1, odds ratio testing disclosed that 1- to 3-yr-old bucks were 13 times more likely and bucks ≥ 4 -yr-old were 38 times more likely to be affected than the youngest bucks were. Of 19 males for which antler status was recorded, 13 (68%) had hard, polished antlers and six (32%) had recently cast antlers or had velvet-covered pedicels.

The occurrence of cases was seasonal, and all cases, including those in females, were submitted during the period of October through April. Although sample size was insufficient for statistical analysis, the temporal distribution of cases among adult males (≥ 1.5 yr) appeared to be related to age. Four of five yearling (1.5 yr) bucks were submitted in October and November. In contrast, older (≥ 2.5 yr) males were submitted each month from October through April, with the highest percentage (27%) of accessions occurring in April (Fig.

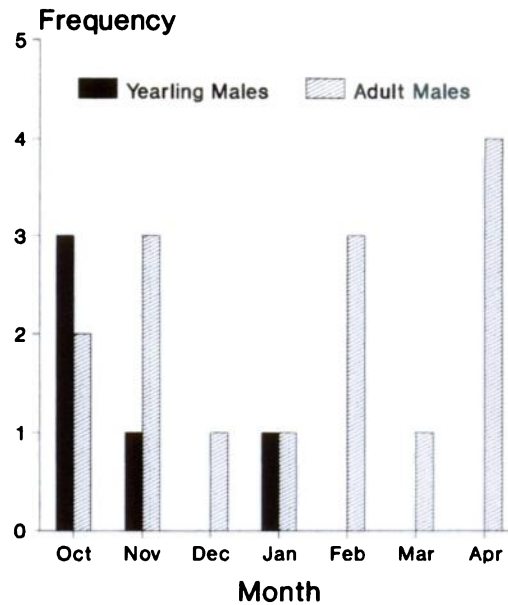


FIGURE 4. Seasonal distribution of cerebral abscesses in yearling (1.5 yr) and older adult (≥ 2.5 yr) male white-tailed deer from the southeastern United States.

4). The age structure of bucks submitted for diagnostic purposes was not the same as the age structure of hunter-harvested deer in Georgia ($G = 14.1$, $df = 7$).

DISCUSSION

The two pathologic conditions, intracranial abscessation and suppurative meningoencephalitis, reported herein were due to multiple etiologic agents, pathogenetic mechanisms, and predisposing factors. However, intracranial abscesses and suppurative meningoencephalitis in white-tailed deer can be considered to be a disease complex because (1) the same etiologic agents often were isolated from animals with both conditions, (2) in both conditions the pathogenetic mechanisms appeared to be the same, (3) the apparent predisposing factors for both conditions were the same, and (4) several animals had both abscesses and suppurative meningitis. Because of these similarities and because abscesses predominated among the cases, the term intracranial abscess will be used hereafter as a general descriptive term re-

ferring to both of these pathologic conditions.

The clinical signs and lesions associated with intracranial abscesses in white-tailed deer were typical of those in other ungulates (Jubb and Kennedy, 1970; Blood et al., 1983). The preponderance of *A. pyogenes*, either alone or in combination with other bacteria, also is similar to cerebral abscess cases in other ungulates (Beckley and Dieterich, 1970; Jubb and Kennedy, 1970; Amand et al., 1973; Andrews and Ingram, 1982; Blood et al., 1983; Johnson et al., 1983). Intracranial abscesses may arise from a variety of sources including direct invasion from surrounding structures, hematogenous spread and from various injuries including parasitic lesions (Jubb and Kennedy, 1970; Blood et al., 1983). Examination of our case records disclosed contributing factors that could represent all of these potential sources, although direct invasion through or between cranial bones predominated among males. Thus, the general clinical, pathologic, and etiologic features of intracranial abscesses in white-tailed deer do not appear to differ substantively from those in other ungulates.

The significant difference between bucks and does in the prevalence of intracranial abscesses suggests that their occurrence is governed primarily by factors related to host sex. The most obvious factor is the sexually dimorphic characteristic of antlers in males but not females. Many affected bucks had evidence that abscesses were initiated in direct association with antlers, either from cutaneous abrasions and subcutaneous infections adjacent to antler pedicels or from pedicel fractures.

Furthermore, the occurrence of abscesses was seasonal, indicating that bucks were at increased risk only during certain stages of the antler cycle. Abscesses were found only during the period that began following velvet shedding and lasted until shortly after antler casting; no cases were diagnosed among males in which new antler growth had progressed much beyond vel-

vet-covered pedicels. This suggests that behavioral and physiologic idiosyncrasies characteristic of adult males such as antler rubbing, sparring, antler casting, and nutritional stress during rut are important predisposing factors in the process of intracranial abscess formation. Although our data are limited, they further suggest an interaction between male age and these behavioral and physiologic factors. Yearling bucks undergoing their first antler cycle may be at greater risk during the initial sign-post and rut behavior activities than during the post-rut period. This is suggested by the fact that 80% of all yearling buck cases were submitted during October or November, but none were submitted during February or later when antlers are normally cast. In contrast, older males appear to have a longer period of risk extending from sign-post/rut activities through antler casting. The relatively high proportion of older male case accessions during the period of February to April (54%) suggests that the post-rut period and antler casting may represent high risks of abscess initiation for older animals.

The prevalence of intracranial abscesses in our case accessions was low (4%) when compared to other important diseases in the southeastern United States such as hemorrhagic disease (Prestwood et al., 1974; Couvillion et al., 1981) or haemochrosis/malnutrition syndrome (Davidson et al., 1980; McGhee et al., 1981). Therefore, intracranial abscesses are not a significant mortality factor for white-tailed deer populations on a regional basis. However, the strong predisposition for bucks, and especially older bucks, to develop abscesses indicates that this disease is a much more important cause of mortality in the adult buck segment than in the remainder of the population. Comparison of hunter-harvested bucks in Georgia with bucks submitted as clinical cases (13 of 21 from Georgia) disclosed different ($P > 0.05$) age structures for the two groups, indicating that sampling biases may exist between clinical case and hunter-harvested data sets.

Thus, if hunter-harvested bucks are assumed to represent male age structure, which they may not (Allen, 1987), the age-specific prevalences of abscesses may not accurately estimate the proportion of disease losses attributable to intracranial abscesses among bucks. Despite these possible discrepancies, the fact that this disease accounted for 20% of the diagnoses among 56 bucks ≥ 3 -yr-old suggests that it may account for a substantial amount of disease-induced mortality in adult males.

In studies from widely divergent ecologic settings, Gavin et al. (1984), Nelson and Mech (1986), and DeYoung (1989) found that natural mortality of adult male white-tailed deer exhibited similar seasonal trends and that losses to natural causes occurred at a disproportionately higher rate during late fall and winter. Natural mortalities in these studies were attributed primarily to predation by wolves (*Canis lupus*) (Nelson and Mech, 1986), coyotes (*C. latrans*) (DeYoung, 1989), cougars (*Felis concolor*) (DeYoung, 1989), or dogs (Gavin et al., 1984), to nutritional or physiologic stress associated with reproductive activities (Gavin et al., 1984; Nelson and Mech, 1986), or to undetermined causes (DeYoung, 1989). All of these potential causes of mortality could have intracranial abscesses as an underlying factor. The clinical signs associated with intracranial abscesses would clearly predispose animals to predation, and the apparent protracted course of some abscesses can lead to pronounced declines in physical condition resembling severe nutritional stress or starvation. We do not suggest that intracranial abscesses alone afford a single explanation for the apparently common phenomenon of high adult buck mortality during late fall and winter; however, we do contend that this disease could account for a portion of the mortality that has been attributed to other causes. Unless specifically eliminated by thorough diagnostic examination, which is often difficult if not impossible because of decomposition or destruction of carcasses by predators or scavengers (as

noted by Nelson and Mech, 1986, and DeYoung, 1989), intracranial abscesses should be considered a possible cause of natural mortality of bucks during late fall or winter. In this regard, the characteristic erosion and pitting of cranial bones may be a useful diagnostic criterion when only skeletal remains are found or when autolysis is advanced.

DeYoung (1989) concluded that trophy management for white-tailed deer in south Texas was inefficient because adult bucks died at disproportionately high rates before reaching the desired older age classes. Wildlife managers should recognize that harvest strategies designed to produce older buck age structures may be specifically hindered by higher natural mortality rates in adult bucks, not the least of which appears to be intracranial abscesses. Managers should make allowances for this mortality when setting management goals.

ACKNOWLEDGMENTS

This study was supported by the Federal Aid in Wildlife Restoration Act (50 Stat. 917) and by Contract Numbers 14-16-0009-81-015, 14-16-0009-82-500, 14-16-0004-83-004, 14-16-0004-84-005, 14-16-0004-85-007, 14-16-0004-86-910, 14-16-0004-87-910, 14-16-0004-88-903, and 14-16-0004-89-912, Fish and Wildlife Service, U.S. Department of the Interior. The authors thank the many state and federal wildlife biologists who submitted sick and dead deer for diagnostic evaluation. Personnel with the Athens Diagnostic Assistance Laboratory, College of Veterinary Medicine, The University of Georgia, and E. B. Shotts, Department of Medical Microbiology, College of Veterinary Medicine, The University of Georgia, provided the microbiologic support mentioned herein. We thank L. Whited for assistance with searches of case records and data compilation and D. E. Stallknecht for statistical advice and analyses. We also acknowledge the superb assistance of many past and present SCWDS co-workers during these studies. We thank G. A. Wobeser for reviewing an earlier draft of this manuscript.

LITERATURE CITED

- ALLEN, C. 1987. Statewide deer herd reconstruction and population monitoring. Final Report, Federal Aid Project Number W-47-R, Study III, Georgia Department of Natural Resources, Game

- and Fish Division, Atlanta, Georgia, 39 pp. plus appendix tables.
- AMAND, W., A. DELAHUNTA, J. ANSLEY, AND J. JOHNSON. 1973. Brain abscess in a Barbados sheep. *Journal of the American Veterinary Medical Association* 163: 562-564.
- ANDREWS, A. H., AND P. L. INGRAM. 1982. A brain abscess in a ewe. *Veterinary Medicine/Small Animal Clinician* 77: 101-103.
- BECKLEY, J. C., AND R. A. DIETERICH. 1970. Corynebacterial infection in the domesticated musk ox (*Ovibos moschatus*). *Veterinary Medicine/Small Animal Clinician* 65: 1063-1067.
- BLOOD, D. C., O. M. RADOSTITS, AND J. A. HENDERSON. 1983. *Veterinary medicine*, 6th ed. Baillere Tindall, London, England, 1,310 pp.
- COUVILLON, C. E., V. F. NETTLES, W. R. DAVIDSON, AND J. E. PEARSON. 1981. Hemorrhagic disease among white-tailed deer in the Southeast from 1971 through 1980. *Proceedings of the United States Animal Health Association* 85: 522-537.
- DAVIDSON, W. R., M. B. MCGHEE, V. F. NETTLES, AND L. C. CHAPPELL. 1980. Haemonchosis in white-tailed deer in the southeastern United States. *Journal of Wildlife Diseases* 16: 499-508.
- DAVIDSON, W. R., AND V. F. NETTLES. 1988. *Field manual of wildlife diseases in the southeastern United States*. Southeastern Cooperative Wildlife Disease Study, College of Veterinary Medicine, The University of Georgia, Athens, Georgia, 309 pp.
- DELAHUNTA, A. 1973. Neurologic problems of the horse. *Proceedings American Association of Equine Practitioners* 19: 25-32.
- DEYOUNG, C. A. 1989. Mortality of adult male white-tailed deer in south Texas. *The Journal of Wildlife Management* 53: 513-518.
- FORD, J., AND M. D. LOKAI. 1980. Complications of *Streptococcus equi* infections. *Equine Practitioner* 2: 41-44.
- GAVIN, T. T., L. H. SURING, P. A. VOHS, JR., AND E. C. MESLOW. 1984. Population characteristics, spatial organization, and the natural mortality in the Columbian white-tailed deer. *Wildlife Monographs* No. 91, 41 pp.
- GRINER, L. A., R. JENSEN, AND W. W. BROWN. 1956. Infectious embolic meningo-encephalitis in cattle. *Journal of the American Veterinary Medical Association* 129: 417-421.
- HARTLEY, W. J., AND J. C. KATER. 1962. Observations on diseases of the central nervous system of sheep in New Zealand. *New Zealand Veterinary Journal* 10: 128-142.
- HULL, F. W., AND E. L. TAYLOR. 1941. Abscesses affecting the central nervous system of sheep. *American Journal of Veterinary Research* 2: 356-367.
- JOHNSON, J. L., J. B. CAMPBELL, A. R. DOSTER, G. NASON, AND R. J. CAGNE. 1983. Cerebral abscess and *Cephenemyia phobifer* in a mule deer in central Nebraska. *Journal of Wildlife Diseases* 19: 279-280.
- JUBB, K. V. F., AND P. C. KENNEDY. 1970. *Pathology of domestic animals*, Vol. 2, 2nd ed. Academic Press, New York, New York, 697 pp.
- LAL, K. B., AND B. B. VERMA. 1979. Clinico pathological studies of brain abscesses in buffalo (*Bubalus bubalis*). *Indian Veterinary Journal* 56: 321-325.
- MARTIN, S. W., A. H. MEEK, AND P. WILLEBERG. 1987. *Veterinary epidemiology: Principles and methods*. Iowa State University Press, Ames, Iowa, 343 pp.
- MCGHEE, M. B., V. F. NETTLES, E. A. ROLLOR, III, A. K. PRESTWOOD, AND W. R. DAVIDSON. 1981. Studies on cross-transmission and pathogenicity of *Haemonchus contortus* in white-tailed deer, domestic cattle and sheep. *Journal of Wildlife Diseases* 17: 353-364.
- NELSON, M. E., AND L. D. MECH. 1986. Mortality of white-tailed deer in northeastern Minnesota. *The Journal of Wildlife Management* 50: 691-698.
- PRESTWOOD, A. K., T. P. KISTNER, F. E. KELLOGG, AND F. A. HAYES. 1974. The 1971 outbreak of hemorrhagic disease among white-tailed deer of the southeastern United States. *Journal of Wildlife Diseases* 10: 217-224.
- RAPHEL, C. 1982. Brain abscesses in three horses. *Journal of the American Veterinary Medical Association* 180: 874-877.
- SOKAL, R. R., AND F. J. ROHLF. 1981. *Biometry*, 2nd ed. W. H. Freeman and Company, New York, New York, 859 pp.

Received for publication 12 January 1990.