



INTEGUMENTAL LESIONS CAUSED BY ECTOPARASITES IN A WILD POPULATION OF THE SIDE-BLOTCHED LIZARD (UTA STANSBURIANA)

Authors: Goldberg, Stephen R., and Bursey, Charles R.

Source: Journal of Wildlife Diseases, 27(1) : 68-73

Published By: Wildlife Disease Association

URL: <https://doi.org/10.7589/0090-3558-27.1.68>

BioOne Complete (complete.BioOne.org) is a full-text database of 200 subscribed and open-access titles in the biological, ecological, and environmental sciences published by nonprofit societies, associations, museums, institutions, and presses.

Your use of this PDF, the BioOne Complete website, and all posted and associated content indicates your acceptance of BioOne's Terms of Use, available at www.bioone.org/terms-of-use.

Usage of BioOne Complete content is strictly limited to personal, educational, and non - commercial use. Commercial inquiries or rights and permissions requests should be directed to the individual publisher as copyright holder.

BioOne sees sustainable scholarly publishing as an inherently collaborative enterprise connecting authors, nonprofit publishers, academic institutions, research libraries, and research funders in the common goal of maximizing access to critical research.

INTEGUMENTAL LESIONS CAUSED BY ECTOPARASITES IN A WILD POPULATION OF THE SIDE-BLOTCHED LIZARD (*UTA STANSBURIANA*)

Stephen R. Goldberg¹ and Charles R. Bursey²

¹ Department of Biology, Whittier College, Whittier, California 90608, USA

² Department of Biology, Pennsylvania State University, Shenango Valley Campus, Sharon, Pennsylvania 16146, USA

ABSTRACT: Histopathological effects of ectoparasites on integument were examined for a wild population of the side-blotched lizard *Uta stansburiana*. These included the trombiculid *Neotrombicula californica*, the pterygosomatid mite *Geckobiella texana*; the macronyssid mite *Ophionyssus natricis* (Macronyssidae) and the ixodid tick *Ixodes pacificus*. A diffuse inflammatory response occurred at the site of chigger and tick attachment which consisted of histiocyte, heterophil, fibroblast and lymphocyte infiltration that often extended into the dermis. Granuloma formation also was noted. The most prevalent parasite was *N. californica* which frequently occurred in large aggregations above the eyelids. Ectoparasites were most abundant from February through April.

Key words: *Uta stansburiana*, Iguanidae, histopathology, inflammation, granuloma, integument, ectoparasite, chigger, *Neotrombicula californica*, mite, *Geckobiella texana*, *Ophionyssus natricis*, tick, *Ixodes pacificus*.

INTRODUCTION

Mites and ticks frequently infest reptiles (Reichenbach-Klinke and Elkan, 1965; Frank, 1981). Epidemics of ectoparasites often occur when reptiles are kept in close confinement and may kill the host (Mader et al., 1986). Camin (1948) showed that the macronyssid mite *Ophionyssus serpentina* may transmit hemorrhagic septicemia in snakes. While the problems with ectoparasites in captive reptiles have been reported (Frye, 1981), the effects of ectoparasites on wild reptile populations apparently have received little attention. The purpose of this report is to describe the histopathology of integumental lesions associated with infestations of chiggers (*Neotrombicula californica*), ticks (*Ixodes pacificus*) and mites (*Geckobiella texana* and *Ophionyssus natricis*) on a wild population of the side-blotched lizard (*Uta stansburiana*). Previous studies on ectoparasites of *U. stansburiana* emphasized their seasonal distribution but there have been no studies on the pathology resulting from these infestations (Spoecker, 1967; Loomis and Stephens, 1973).

MATERIALS AND METHODS

Two hundred thirty two side-blotched lizards (mean snout-vent length = 51 mm \pm 5 mm SD,

range = 33 to 63 mm) were collected by hand-held noose in the San Gabriel Mountains at Strawberry Peak off California Highway 2 (34°17'N, 118°07'W, elevation 1,878 m; Los Angeles County, California, USA) during February to June (spring) and September to November (autumn) 1989. At necropsy, integumental tissues with attached parasites were excised and fixed in neutral buffered 10% formalin. Subsequently, tissues were embedded in paraffin by standard histological technique. Sections were cut at 5 μ m and stained with hematoxylin and eosin. Selected sections were stained with Giemsa stain, Masson's trichrome connective tissue stain, Brown-Brenn gram stain and Warthin-Starry stain (Luna, 1968). Squash preparations of ectoparasites were stained with Wright's stain. Representative slides of ticks were deposited in the U.S. National Tick Collection, Smithsonian Institution (Washington, D.C. 20560, USA; accession numbers RML 119772, RML 119773). Other ectoparasites were sent to the U.S. National Parasite Collection (Beltsville, Maryland 20705, USA; accession numbers 80963, 80964, 80965 for *G. texana*, *O. natricis* and *N. californica*, respectively).

RESULTS

Neotrombicula californica occurred in dense aggregations on the upper eyelids, occasionally on the gular folds and ventral surface, and rarely on the dorsum of the lizards (Table 1). In cases of heavy infestation on the upper eyelids, a few chiggers

TABLE 1. Monthly distribution patterns (1989) of the chigger *Neotrombicula californica* on *Uta stansburiana*.

Month	Hosts					Parasites						
	Number examined	Infested		Lesions		Eye	Gular	Dorsum	Under-side	Total	Mean intensity	Range
		Number	%	Number	%							
Feb	10	10	100	0	0	199	0	0	0	199	20	4-45
Mar	65	51	78	25	38	795	0	0	0	795	16	11-61
Apr	72	47	65	21	29	679	81	0	0	760	16	1-79
Jun	22	20	91	8	36	8	459	37	0	504	25	1-50
Sep	16	6	38	0	0	7	0	0	0	7	1	1-2
Oct	28	9	32	1	4	25	7	0	47	79	9	1-34
Nov	19	5	26	3	16	13	2	0	2	17	3	1-10

would sometimes also occur on the lower eyelids. Sixty-four percent (148 of 232) of the lizard sample were infected with *N. californica*, but there was a marked decrease in prevalence and intensity as well as a change in infestation site near the end of the collection period. Of those infested, 76% were from the spring subsample and

24% from the autumn subsample. There was no significant difference in intensity of infestation between males and females (Kruskal-Wallis statistic = 1.06, 1 df, $P > 0.05$). There was no correlation between lizard snout-vent length and intensity of infestation ($r^2 = 0.07$, $P > 0.05$). Not all infested lizards exhibited histopathological lesions (Table 1).

In chigger lesions, necrosis of the epidermis was typically seen at the site of attachment. Occasionally a serocellular crust of serum protein exudate also formed. *Neotrombicula californica* embedded its mouthparts in the integument (Fig. 1). Stylostomes extended into the dermis and were surrounded by what appeared to be coagulated host proteins. Squash preparations of chiggers found them to contain a clear fluid.

Larvae and nymphs of the tick *I. pacificus*, were found in the gular region or attached to the skin bordering the tympanum (Table 2) in sixteen percent (36 of 232) of the lizards sampled. All but one (97%) of the infested lizards were from the spring subsample. There was no significant difference in intensity of infestation between males and females (Kruskal-Wallis statistic = 1.12, 1 df, $P > 0.05$). Thirty-three male lizards had 85 ticks; three female lizards had four ticks. Ticks were embedded in the integument (Fig. 2) and were observed to contain blood. The hypostome was surrounded by an acellular,

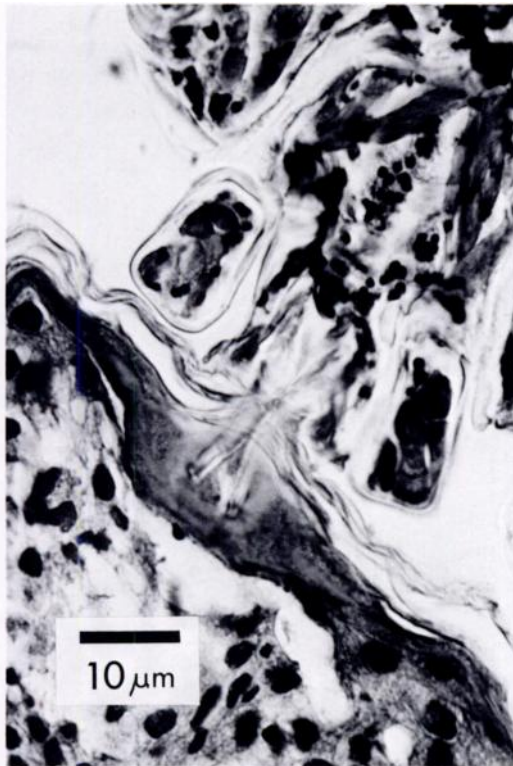


FIGURE 1. Mouthparts of *Neotrombicula californica* penetrating the eyelid of *Uta stansburiana*. H&E.

TABLE 2. Monthly distribution patterns (1989) of the tick *Ixodes pacificus*, on *Uta stansburiana*.

Month	Hosts			Parasites		
	Number examined	Infested		Total number	Mean intensity	Range
		Number	%			
Feb	10	0	0	—	—	—
Mar	64	13	20	34	3	1-6
Apr	72	21	29	49	2	1-10
Jun	22	1	5	4	4	—
Sep	16	0	0	—	—	—
Oct	28	0	0	—	—	—
Nov	19	1	5	2	2	—

amorphous, hyaline precipitate which extended into the dermis. Around the tip of the hypostome were coagulated proteins, edematous fluid and cellular debris indicative of an acute fibrinoid reaction.

Eleven percent (26 of 232) of the lizard sample were infested with *O. natricis*. Twenty-seven percent of those infested were from the spring subsample and 73% from the autumn subsample. These mites were first seen in June, absent in September, but again present in October and November. They were very mobile and appeared to wander over all parts of the host's body. Because their rapid movements precluded an accurate count of numbers of individuals, intensity was not determined. They occasionally left the lizard to infest the investigator; on the human host they caused episodes of intense itching that lasted for approximately one day. This has been reported previously (Reichenbach-Klinke and Elkan, 1965). On the lizard these mites tended to aggregate on the upper eyelids and around the tympanum but did not embed in the integument; none were found in histological sections. Small amounts of lizard blood were found in squash preparations of *O. natricis*.

The mite *G. texana* was rarely seen; only 10 were found. They were taken from nine (4%) lizards; eight mites on seven lizards from spring and two mites on two lizards from autumn. They embedded on the upper eyelid or the edge of the tympanum.

A few lizard erythrocytes were found in squash preparations of *G. texana*, however, these mites were not found in any histological sections of the lesions.

Integumental lesions due to chiggers and ticks were most prevalent in spring; 32% (54 of 169) of the spring subsample had lesions as compared to 6% (4 of 63) from the autumn subsample (Table 1). The lesions penetrated into the dermis and consisted of diffuse areas of inflammatory infiltrate (Figs. 3, 4). These areas contained histiocytes, heterophils, fibroblasts and occasionally lymphocytes. Skeletal muscle was sometimes infiltrated. Some interstitial edema was noted. Several layers of hyperplastic epithelial cells also were noted. Granulomas (Fig. 5) consisting of histiocytes with foamy cytoplasm, heterophils, plasma cells and occasionally lymphocytes were present below the level of mouthpart penetration. Fibroblasts were seen at the periphery of the granuloma. Masson's trichrome stain did not indicate that collagen had been deposited in the granulomas. Likewise, secondary infection was not demonstrated as Giemsa stain and Brown-Brenn gram stain, for bacteria and Warthin-Starry stain for spirochetes were negative, respectively.

DISCUSSION

We believe the lesions examined here were caused primarily by the chigger and to a lesser extent by the tick. There was no histological evidence to implicate *O. natricis* or *G. texana* as the cause for lesions in this host. Although *G. texana* did attach to the integument, it occurred so rarely ($n = 10$, nine hosts, only one without coectoparasites) that damage, if any, must be minimal. *Ophionyssus natricis* was never found embedded in the lizard integument. Lesions were most prevalent in February and March which is also the time when the greatest number of chiggers were present. In addition, the paucity of lesions (only three were found) in November when *O. natricis* were most abundant but *G. texana*, *N. californica* and *I. pacificus* were

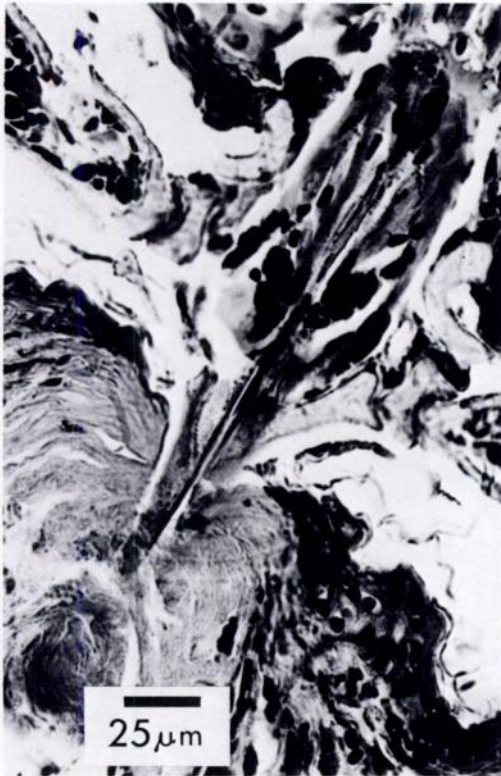

FIGURE 2. Mouthparts of *Ixodes pacificus* penetrating the skin bordering the tympanum of *Uta stansburiana*. H&E.

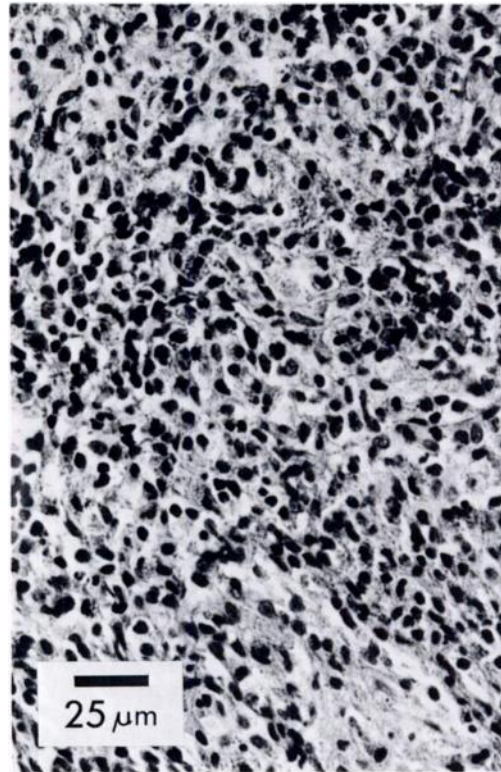


FIGURE 3. Inflamed eyelid of *Uta stansburiana* resulting from ectoparasite attachment. H&E.

absent or infrequent further suggests that chiggers were responsible for most of the lesions seen in this host. The finding of small numbers of lizard erythrocytes in *O. natricis* may have resulted from them feeding near tick bite wounds.

Host response as exhibited by *U. stansburiana* seemed to be the same whether elicited by chigger or tick attachment. In most cases, the ectoparasite was lost in histological processing. However, sufficient numbers of chiggers and ticks were present in the histological preparations to allow specific observations about the parasite and evoked tissue response. In addition, stylostomes (indicative of chigger attachment) were readily detectable with hematoxylin and eosin staining. Chiggers do not suck blood, but ingest lymph and dissolved host tissue (Frank, 1981); they also secrete a substance which liquifies epider-

mal cells. Fluids are ingested through a stylostome (=histiosiphon) (Jones, 1950; Woolley, 1988) which forms in the host's tissue in response to salivary secretions (Noble et al., 1989). Ticks suck blood from their hosts and their stylets penetrate deeper into the host's integument than do those of chiggers.

The preferred attachment site of *N. californica* appears to be the upper eyelid. These ectoparasites were found around the eyes during each month of this study. Gular infestation was first noted in April, while underside infestation was noted in October. The gular fold, under-eye, ventral surface and dorsum are apparently secondary sites of infestation. Spoecker (1967) reported seasonal variation of *Neotrombicula* sp. on *U. stansburiana* but found them only on the eyelids. Loomis and Stephens (1973) found seasonal variation in intensity for five species of chiggers infesting *U.*

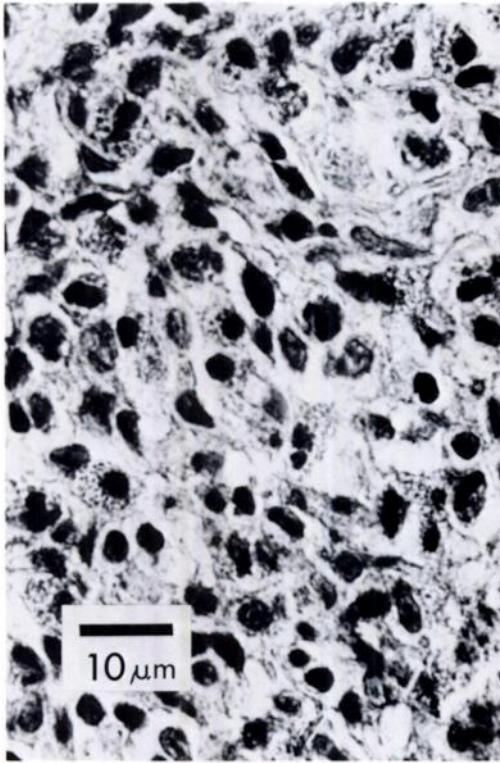


FIGURE 4. Inflammatory reaction from ectoparasite attachment on the eyelid of *Uta stansburiana*. Histiocytes and heterophils are the predominant cells present. H&E.

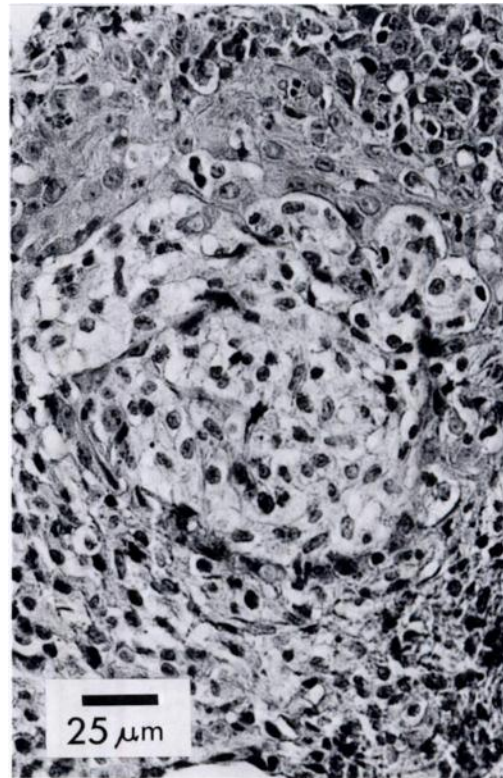


FIGURE 5. Granuloma from the eyelid of *Uta stansburiana*. Histiocytes with foamy cytoplasm predominate. H&E.

stansburiana from southern California and observed that *Odontacarus arizonensis* attached further posteriorly as the season progressed. Wharton and Fuller (1952) postulated that in mites, attachment of one individual makes the adjacent skin more attractive to others. In contrast, Loomis and Stephens (1973) found that anterior sites became unsuitable due to tissue damage caused by earlier chigger attachment. In addition, Loomis and Stephens (1973) reported that larvae seemed to attach more readily to new skin than to old, and rarely attached at previous feeding sites which had not been repaired.

We have no data on the time required for formation of the lesions reported here: diffuse inflammatory reaction and granuloma formation. Mateo et al. (1984) induced inflammation in the alligator (*Al-*

ligator mississippiensis) by turpentine injection and found that heterophils began to accumulate within 4 to 8 hr. The diffuse inflammatory reaction may have been in part a response to anticoagulants secreted by the ectoparasites (Woolley, 1988). The presence of fibroblasts at the periphery of the granulomas suggests an attempt to wall-off the lesion, typically a late stage tissue response.

We have no information on how long inflammatory lesions persist in *U. stansburiana*. Allen (1948) reported that lesions in humans from a chigger (*Trombicula irritans*) were evident after 8 mo and those from tick bites persisted for 18 mo. Tobias (1949) studied tick bite granulomas in a patient 11 mo after the bite. Lesions appeared to be similar in both humans and lizards. The human lesions consisted of dense dermal infiltrations of eosinophilic

leucocytes, plasma cells and histiocytes, not unlike the lesions we reported for *U. stansburiana*. Since tick and chigger lesions persist in humans, it might be expected that a similar time course would occur in lizards.

Unfortunately, the life cycle of *U. stansburiana* did not allow us to determine the amount of time required for granuloma resolution. As reported by Tinkle (1967), *U. stansburiana* is an oviparous, short-lived lizard. Mating occurs during March and April; most eggs hatch in July and August. By September most of the individuals within a population are juveniles. The mean life expectancy is 1.1 to 1.4 yr, thus population turnover is essentially complete every year. Lizards that were active during spring when ectoparasites were abundant have been replaced in autumn by juveniles yet to be exposed to peak ectoparasite populations. Studies to assess duration of ectoparasite inflicted skin lesions are currently in progress on longer-lived lizards.

ACKNOWLEDGMENTS

We thank M. L. Goff (University of Hawaii at Manoa) for identification of ectoparasites, D. D. Porter (Department of Pathology, School of Medicine, University of California at Los Angeles), G. Ford, B. Hook, E. Hughes and especially H. J. Holshuh (Comparative Medical and Veterinary Services, County of Los Angeles) for discussions on histopathology and helpful suggestions. T. A. Beinz assisted with field work.

LITERATURE CITED

- ALLEN, A. C. 1948. Persistent "insect bites" (dermal eosinophilic granulomas) simulating lymphoblastomas, histiocytoses, and squamous cell carcinomas. *American Journal of Pathology* 24: 367-387.
- CAMIN, J. H. 1948. Mite transmission of a hemorrhagic septicemia in snakes. *The Journal of Parasitology* 34: 345-354.
- FRANK, W. 1981. Ectoparasites. *In Diseases of the Reptilia*. Vol. 1, J. E. Cooper and O. F. Jackson (eds.). Academic Press, London, England, pp. 359-383.
- FRYE, F. L. 1981. Biomedical and surgical aspects of captive reptile husbandry. Krieger Publishing Company, Inc., Melbourne, Florida, 456 pp.
- JONES, B. M. 1950. The penetration of the host tissue by the harvest mite, *Trombicula autumnalis* Shaw. *Parasitology* 40: 247-260.
- LOOMIS, R. B., AND R. C. STEPHENS. 1973. The chiggers (Acarina, Trombiculidae) parasitizing the side-blotched lizard (*Uta stansburiana*) and other lizards in Joshua Tree National Monument, California. *Bulletin of the Southern California Academy of Science* 72: 78-89.
- LUNA, L. G. 1968. Manual of histologic staining methods of the Armed Forces Institute of Pathology. 3rd Ed. McGraw-Hill Book Company, New York, New York, 258 pp.
- MADER, D. R., R. S. HOUSTON, AND F. L. FRYE. 1986. *Hirstiella trombidiformis* infestation in a colony of chuckwalla. *Journal of American Veterinary Medical Association* 189: 1138-1139.
- MATEO, M. R., E. D. ROBERTS, AND F. M. ENRIGHT. 1984. Inflammation induced by subcutaneous turpentine inoculation of young American alligators (*Alligator mississippiensis*). *American Journal of Veterinary Research* 45: 1870-1875.
- NOBLE, E. R., G. A. NOBLE, G. A. SCHAD, AND A. J. MACINNES. 1989. Parasitology, the biology of parasites. 5th Ed. Lea & Febiger, Philadelphia, Pennsylvania, 574 pp.
- REICHENBACH-KLINKE, H., AND E. ELKAN. 1965. The principal diseases of lower vertebrates. Academic Press, London, England, 600 pp.
- SPOECKER, P. D. 1967. Ectoparasites of a Mohave desert population of the lizard *Uta stansburiana stejnegeri* Schmidt. *American Midland Naturalist* 77: 539-542.
- TINKLE, D. W. 1967. The life and demography of the side-blotched lizard, *Uta stansburiana*. Miscellaneous publications No. 132, Museum of Zoology, University of Michigan, Ann Arbor, Michigan, 182 pp.
- TOBIAS, N. 1949. Tickbite granuloma. *Journal of Investigative Dermatology* 12: 255-259.
- WHARTON, G. W., AND H. S. FULLER. 1952. A manual of the chiggers. *Memoirs of the Entomological Society of Washington* 4: 1-185.
- WOOLLEY, T. A. 1988. Acarology. Mites and human welfare. John Wiley & Sons, New York, New York, 484 pp.

Received for publication 5 February 1990.