

## **CHRONIC UPPER RESPIRATORY TRACT DISEASE OF FREE-RANGING DESERT TORTOISES (XEROBATES AGASSIZII)**

Authors: Jacobson, E. R., Gaskin, J. M., Brown, M. B., Harris, R. K., Gardiner, C. H., et al.

Source: Journal of Wildlife Diseases, 27(2) : 296-316

Published By: Wildlife Disease Association

URL: <https://doi.org/10.7589/0090-3558-27.2.296>

---

BioOne Complete ([complete.BioOne.org](https://complete.BioOne.org)) is a full-text database of 200 subscribed and open-access titles in the biological, ecological, and environmental sciences published by nonprofit societies, associations, museums, institutions, and presses.

Your use of this PDF, the BioOne Complete website, and all posted and associated content indicates your acceptance of BioOne's Terms of Use, available at [www.bioone.org/terms-of-use](https://www.bioone.org/terms-of-use).

Usage of BioOne Complete content is strictly limited to personal, educational, and non - commercial use. Commercial inquiries or rights and permissions requests should be directed to the individual publisher as copyright holder.

---

BioOne sees sustainable scholarly publishing as an inherently collaborative enterprise connecting authors, nonprofit publishers, academic institutions, research libraries, and research funders in the common goal of maximizing access to critical research.

## CHRONIC UPPER RESPIRATORY TRACT DISEASE OF FREE-RANGING DESERT TORTOISES (*XEROBATES AGASSIZII*)

E. R. Jacobson,<sup>1</sup> J. M. Gaskin,<sup>1</sup> M. B. Brown,<sup>1</sup> R. K. Harris,<sup>2</sup>  
C. H. Gardiner,<sup>2</sup> J. L. LaPointe,<sup>3</sup> H. P. Adams,<sup>3</sup> and C. Reggiardo<sup>4</sup>

<sup>1</sup> College of Veterinary Medicine, University of Florida, Gainesville, Florida 32610, USA

<sup>2</sup> Department of Veterinary Pathology, Armed Forces Institute of Pathology, Washington, D.C. 20306, USA

<sup>3</sup> Department of Biology and Electron Microscopy Laboratory, New Mexico State University, Las Cruces,  
New Mexico 88003, USA

<sup>4</sup> Department of Veterinary Science, University of Arizona, Tucson, Arizona 85721, USA

**ABSTRACT:** Seventeen desert tortoises, *Xerobates agassizii*, with upper respiratory tract disease were examined; thirteen were euthanatized for necropsy. Four normal control desert tortoises from a clinically healthy population were similarly evaluated. Hemoglobin and phosphorus values were significantly ( $P \leq 0.05$ ) lower and serum sodium, urea, SGOT, and cholesterol values were significantly higher in ill tortoises compared to controls. No significant differences in concentrations of serum or liver vitamins A and E were found between the two groups. While no significant differences were found for concentrations of lead, copper, cadmium, and selenium, the livers of ill tortoises had higher concentrations of mercury and iron. Lesions were found consistently in the upper respiratory tract (URT) of ill tortoises. In all ill tortoises dense infiltrates of lymphocytes and histiocytes obscured the mucosal epithelium and underlying glands. The mucosal epithelium was variably dysplastic, hyperplastic, and occasionally ulcerated. Electron microscopic studies revealed small (350 to 900 nm), pleomorphic organisms resembling *Mycoplasma* sp., in close association with the surface epithelium of the URT of ill tortoises. *Pasteurella testudinis* was cultured from the nasal cavity of all ill tortoises and one of four control tortoises. A *Mycoplasma* sp. was cultured from the nasal passageways of four ill tortoises and was ultrastructurally similar to the pleomorphic organism present on the mucosa in tissue section.

**Key words:** Upper respiratory tract disease, *Mycoplasma* sp., *Pasteurella testudinis*, Desert Tortoise, *Xerobates agassizii*.

### INTRODUCTION

Respiratory disease is often encountered in captive reptiles. Viruses, bacteria, fungi, and parasites have all been incriminated as causative agents of reptilian respiratory disease (Jacobson, 1978; Migaki et al., 1984; Jacobson, 1986). Although diseases of the lower respiratory tract are common in crocodilians, lizards and snakes, a necropsy survey of 144 tortoises (Keymer, 1978) revealed few cases. However, in captive tortoises, rhinitis is a common occurrence (Lawrence and Needham, 1985). Epidemics of rhinitis in captive tortoises often follow the introduction of a new animal into a collection (Jackson and Needham, 1983). Since nasal swabs taken of many tortoises with rhinitis often do not yield bacterial organisms, some investigators have suspected a viral agent as the cause of this disease (Jackson and Needham, 1983). In another report, although not isolated from tortoises with rhinitis, *Mycoplasma* was

listed as a suspect organism (Lawrence and Needham, 1985). A recently described bacterial organism, *Pasteurella testudinis*, has been isolated from both healthy and ill tortoises and may be involved in an upper respiratory tract disease (URTD) in captive desert tortoises (Snipes and Biberstein, 1982). Still, the exact cause of this disease has not been elucidated.

In 1988, desert tortoises with URTD were seen in the Desert Tortoise Natural Area (DTNA), Kern County, California (USA) (K. H. Berry, pers. comm.). In 1989, a detailed survey of the DTNA and nearby areas in the Rand Mountains and Freemont Valley indicated that 43% of 468 live desert tortoises encountered on the sections surveyed showed signs of this disease (Knowles, 1989). Additionally, carcasses of 627 tortoises were recovered from the sampled areas. Free-ranging desert tortoises with signs of URTD have been seen also in the eastern Mojave Desert, California

(K. H. Berry, pers. comm.), Clark County, Nevada (D. B. Hardenbrook, pers. comm.), Beaver Dam Slope, Utah and Arizona (M. N. Coffeen, pers. comm.; C. Schwalbe, pers. comm.), and the Sonoran Desert, Arizona (C. Schwalbe, pers. comm.). This study was undertaken to determine the cause of URTD in free-ranging desert tortoises. Clinicopathologic and microbiologic finds are reported.

## MATERIALS AND METHODS

### Turtles

Four groups of tortoises were transported to the College of Veterinary Medicine, University of Florida (Gainesville, Florida 32610, USA) for clinicopathological evaluations. In May 1989, 11 male and one female desert tortoises (Group I), with clinical signs of URTD, weighing 390 to 4,900 g and mean carapace lengths (MCL) of 133 to 306 mm, from the DTNA (35°12'N, 117°52'W), Kern County, California (USA) were evaluated. In June 1989, four clinically healthy male desert tortoises (Group II), weighing 1,180 to 3,887 g and MCL of 199 to 280 mm, from Ivanpah Valley (35°20'N, 115°22'W), San Bernardino County, California (USA) were evaluated. These tortoises were used as controls. In November 1989, one female desert tortoise (Group III), with URTD, weighing 2,090 g and a MCL of 229 mm, from the Red Hill (37°5'N, 113°55'W) population north of St. George, Washington County, Utah (USA) was evaluated. This tortoise was collected in June 1989 and was healthy at the time of collection. It was subsequently housed with other captive desert tortoises, several of which manifested URTD. In September 1989, this tortoise exhibited signs of URTD. In December 1989, two male and two female desert tortoises (Group IV) with URTD, weighing 3,395 to 3,990 g and MCL of 224 to 292 mm, from private land (35°12'N, 117°56'W), adjacent to the DTNA were evaluated. These tortoises were collected in July and August 1989 and were kept in an outdoor enclosure.

All tortoises within Groups I, II, and III were euthanatized within 3 wk of arrival utilizing an intraperitoneal injection of a concentrated barbiturate solution. Once the tortoises showed complete muscle relaxation and were unresponsive to painful stimulation, they were decapitated. Heads of seven tortoises in Group I, three tortoises in Group II, and the one tortoise in Group III were bisected longitudinally with an electric saw. Heads of one tortoise each in Groups I and II were transversely sectioned with an electric saw. The plastron was removed from

the carapace, and viscera within the coelomic cavity were exposed.

### Hematologic and serum biochemical evaluations

At necropsy, blood samples were collected from tortoises in Groups I and II by intracardiac puncture. Portions of blood from each tortoise were placed in tubes containing lithium heparin for hematologic evaluations and silicone coated tubes for serum separation and biochemical determinations. Hematologic evaluations were: red blood cell (RBC) counts, white blood cell (WBC) counts, differential white blood cell counts, hemoglobin (Hb) concentrations, and packed cell volumes (PCV). The RBC count was determined by use of an electronic counter (Coulter Counter 21316, Coulter Diagnostics, Hialeah, Florida 33012, USA). The white blood cell count was determined manually, using conventional techniques for reptile and avian species (Schermer, 1967). The hemoglobin concentration was determined using an automated method (Coulter Hemoglobinometer, Coulter Diagnostics, Hialeah, Florida 33012, USA). The PCV concentration was determined using centrifugation.

Serum biochemical evaluations included determinations of the amounts of glucose, sodium, potassium, chloride, CO<sub>2</sub>, BUN (urea), creatinine, uric acid, calcium, phosphorus, alkaline phosphatase (ALP), serum glutamic oxalacetic transaminase (SGOT) activity, serum glutamic pyruvic transaminase (SGPT) activity, total cholesterol, and total bilirubin; all evaluations were made utilizing an automated analyzer (Hitachi 737, BMD, Indianapolis, Indiana 46250, USA). Triglyceride concentrations were also determined utilizing an autoanalyzer (Encore Autoanalyzer, Baker Instruments, Allentown, Pennsylvania 18001, USA).

Serum was collected from each sample and was electrophoresed on cellulose polyacetate strips at 200 V for 20 min, stained with panceau-S in 7.5% trichloroacetic acid, and rinsed with 5% acetic acid. After clearing the strips in 40% aqueous N-methyl pyrrolidine, the strips were dried for 20 min at 90 C. The separated proteins were densitometrically quantitated using a scanning densitometer (GS300, Hoefer Instruments, San Francisco, California 94710, USA) at 540 nm.

Concentrations of vitamin A and E in sera were determined for six tortoises in Group I and four tortoises in Group II using an HPLC method (Catignani and Bieri, 1983).

### Liver vitamin and metal determinations

Concentrations of the following were determined on portions of liver from 10 Group I tortoises and four Group II tortoises: vitamin A,

vitamin E, selenium (Se), iron (Fe), mercury (Hg), lead (Pb), and cadmium (Cd). Concentrations of vitamins A and E were determined according to the procedure described for sera above. Concentrations of selenium were determined by capillary gas chromatography with electron capture detection (Poole et al., 1977). Amounts of copper and iron were determined by flame atomic absorption spectrometry (Instrumentation Laboratory Video 12 Atomic Absorption Spectrophotometer, Waltham, Massachusetts 02254, USA). Concentrations of lead and cadmium were determined utilizing graphite furnace atomic absorption (IL 655, Instrumentation Laboratory, Waltham, Massachusetts 02254, USA). Mercury values were determined using cold-vapor atomic absorption spectrometry (IL 400, Instrumentation Laboratory, Waltham, Massachusetts 02254, USA).

#### Pathologic investigations

A gross necropsy was conducted on all euthanatized tortoises. An acetic acid digestion technique (Goldstine et al., 1975) was used to locate the thymus of two tortoises in Group I. For histopathological studies, one-half of each longitudinally sectioned head of tortoises in Groups I, II, and III and transversely sectioned heads of one tortoise each in Groups I and II were fixed in neutral buffered 10% formalin (NBF), decalcified, embedded in paraffin, sectioned at 7  $\mu$ m, and stained with hematoxylin and eosin and by the Brown and Hopps method (Luna, 1968) for identification of gram-positive and gram-negative microorganisms. Tissues from the following visceral structures were collected, fixed in NBF, embedded in paraffin, sectioned at 7  $\mu$ m, and stained with hematoxylin and eosin: glottis, cranial trachea, tracheal bifurcation, right bronchus, left bronchus, right cranial-lung lobe, right mid-lung lobe, right caudal-lung lobe, left cranial-lung lobe, left mid-lung lobe, left caudal-lung lobe, thyroid, left and right thymus, spleen, heart, liver, cranial and caudal stomach, small intestine, pancreas, colon, right and left kidney, right and left reproductive tracts, bladder, and pectoral muscle. Liver sections of all tortoises in Groups I and II were also stained for iron by the Prussian Blue method.

Sections of nasal mucosa from paraffin embedded tissues of one tortoise in Group I were deparaffinized, then fixed in Dalton's osmium dichromate solution and embedded in polaron 812 (Polarbed, Micro Structure, PTY, Ltd., London, England). Thick sections were stained with toluidine blue and examined by light microscopy. Ultrathin sections were placed on copper grids, stained with uranyl acetate and lead citrate, and examined with an electron microscope.

Nasal cavity mucosa of one tortoise in each of Groups I and Group III were separated from subadjacent tissues, cut into 1 mm cubes, placed in 2.5% glutaraldehyde, and post-fixed in osmium tetroxide. Some specimens were prepared for scanning electron microscopy (SEM) by critical point drying and sputter coating with gold. Other specimens were prepared for transmission electron microscopy (TEM) by embedding in epon-araldite and sectioning with an ultramicrotome. Formalin fixed nasal cavity mucosa of three tortoises in Group I and two tortoises in Group II was post-fixed in osmium tetroxide and similarly processed. Thick sections were stained with toluidine blue and examined by light microscopy. Ultrathin sections were placed on copper grids, stained with uranyl acetate and lead citrate, and examined with an electron microscope.

#### Microbial investigations

Swab specimens of choanae, nasal cavities, tracheal mucosa, and right lungs of all tortoises in Groups I and II were collected and cultured on sheep blood agar and MacConkey's agar, and incubated at 37 C for aerobic bacteria. A swab specimen of the nasal cavity of the Group III tortoise was similarly cultured. All aerobes were identified utilizing growth characteristics on various media and standard biochemical tests. All isolates of organisms consistent with *Pasteurella* sp. were identified to species according to biochemical profiles listed for *P. testudinis* (Snipes and Biberstein, 1982). The type specimen for *P. testudinis* was purchased (American Type Culture Collection, Rockville, Maryland 20852, USA) and used for comparison.

Swab specimens of choanae of five Group I tortoises and three Group II tortoises, liver samples of three Group I tortoises and three Group II tortoises, spleen samples of two Group I tortoises and three Group II tortoises, and colon contents of one Group I tortoise and three Group II tortoises were placed in minimal essential media (MEM; Remel, Regional Media Laboratories, Lenexa, Kansas 66215, USA) and submitted to the National Animal Disease Center, Ames, Iowa, USA, for chlamydial isolation attempts utilizing embryonated chicken eggs.

Nasal washings utilizing phosphate buffered saline (PBS) were collected from one Group I tortoise, the Group III tortoise, and from all four tortoises in Group IV for isolation of mycoplasmas. Initial isolations were performed using modified Fabricant's, arginine, Hayflick's, 10 B and SP4 broths and agars (Razin and Tully, 1983). Broth cultures were incubated at 22, 30 and 37 C. Agar plates were incubated in 5% CO<sub>2</sub> at 22, 30 and 37 C. The initial isolates were

obtained with SP4 isolation medium at 30 C, and this medium and incubation temperature were used for subsequent isolation attempts. At weekly intervals, plates were examined for growth with the aid of a dissection microscope. Broth cultures were examined for a color change biweekly. If a color change was observed, the broth was subcultured to agar, fresh broth, and the remaining culture frozen at -70 C. At one week a single blind passage was made to SP4 agar. When growth was observed on agar, agar plugs were removed aseptically, placed in SP4 broth, and treated as described for other broth cultures.

Aseptically collected kidneys were obtained from each tortoise in Group I and Group II for viral isolation. Kidney tissue from each tortoise was minced and digested with a trypsin-EDTA solution in a trypsinizing flask, on a magnetic stirrer at room temperature (22 C). The resultant slurry was centrifuged at  $500 \times g$  for 10 min to pellet the cells. The supernatant fluid was decanted and the cell pellet was suspended in cell culture growth medium (MEM) with 10% fetal bovine serum. The suspension was placed into cell culture flasks and incubated at 30 C with replenishment of media as necessary. When a confluent monolayer of cells was obtained, it was subdivided to form subcultures. This was repeated twice for each successfully initiated culture so that the primary, secondary, and tertiary cultures could be monitored for the development of cytopathic effects.

Swab specimens of the nasal passages for virus isolation were suspended in MEM and were subsequently frozen at -85 C for virologic studies. When subcultures of primary kidney cell cultures were prepared, they were inoculated with 0.45  $\mu$ m membrane filtrates of the thawed, vortexed nasal specimens in MEM. The monolayers were observed every 48 hr for evidence of viral cytopathic effects (CPE). After 6 to 8 days, these inoculated cultures were subdivided to produce new monolayers which were observed in the same way. A second subculture was also made and monitored.

For electron microscopy a sample of agar containing colonies of *P. testudinis* was fixed in 2.5% glutaraldehyde, post-fixed in 1% osmium tetroxide, and embedded in Spurr's low viscosity resin (Electron Microscopy Sciences, Ft. Washington, Pennsylvania 19034, USA). Equal portions of broth containing an organism isolated on SP4 agar and 5% glutaraldehyde were mixed, centrifuged, and the resulting pellet resuspended in 1% osmium tetroxide, then embedded in EM-BED-812 (Electron Microscopy Sciences). For electron microscopy, ultrathin sections were placed on copper grids, stained with uranyl ac-

etate and lead citrate, and examined with a Hitachi H-7000 STEM electron microscope.

#### Statistical analysis

Student's *t*-test was used to evaluate differences between Group I and II tortoises for the following variables: hematologic values, serum biochemical values, concentrations of serum vitamins A and E, SE, Pb, Cu, Fe, Cd, and Hg. A value of  $P \leq 0.05$  was considered significant.

## RESULTS

### Hematologic and serum biochemical evaluations

Hematologic values for tortoises in Groups I (ill) and II (control) are presented in Table 1. Of the 14 values determined only hemoglobin concentration in the ill tortoises (7.6 g/dl) was significantly lower than that of controls (9.0 g/dl).

Serum biochemical values for tortoises in Groups I and II are presented in Table 2. Ill tortoises were found to have significantly higher values for sodium (153 mEq/L), BUN (100 mg/dl), creatinine (0.2 mg/dl), SGOT activity (117 IU/L) and total cholesterol (305 mg/dl) while values for phosphorus (1.9 mg/dl) were significantly lower than those for controls.

### Liver vitamin and metal determinations

Values for liver and serum vitamins A and E for Groups I and II are presented in Table 3. No significant differences between the two groups were found. Serum vitamin E showed considerable variation between tortoises in each group. In Group I, the highest value recorded (6.32  $\mu$ g/ml) was over 30 times greater than the lowest value for a tortoise in that group.

Liver values for selenium, copper, iron, lead, cadmium, and mercury for Groups I and II are presented in Table 4. In Group I tortoises, the mean value for iron (1,526 ppm) and mercury (0.326 ppm) were significantly higher than those of controls (361 ppm and 0.0287 ppm, respectively). There were no differences for concentrations of selenium, copper, lead and cadmium between the two groups.

TABLE 1. Hematologic values (mean,  $\bar{x}$ ; standard deviation, SD) for Group I and Group II desert tortoises.

Determinant <sup>a</sup>	Group I			Group II		
	<i>n</i> <sup>b</sup>	$\bar{x}$	SD	<i>n</i>	$\bar{x}$	SD
RBC ( $10^6/\mu\text{l}$ )	9	0.60	0.09	4	0.70	0.08
WBC ( $/\mu\text{l}$ )	9	2,390	1,032	4	3,483	2,791
Hb (g/dl)	9	7.6	1.1	4	9.0	0.4
PCV (%)	9	23.2	4.3	4	27.7	1.7
MCV (fl)	9	388	62	4	403	69
MCH (pg)	9	126	13	4	131	19
MCHC (g/dl)	9	33	6	4	31	3
Differential (%)						
Heterophils	9	43	24	4	36	21
Lymphocytes	9	16	10	4	30	13
Monocytes	9	9	7	4	12	8
Eosinophils	9	1	1	4	2	2
Basophils	9	16	11	4	16	12
AGM <sup>c</sup>	9	5	12	4	0	0
AM <sup>d</sup>	9	10	10	4	5	5

<sup>a</sup> See text for definition of determinant and abbreviations.<sup>b</sup> Sample size.<sup>c</sup> Activated granular monocytes.<sup>d</sup> Azurophilic monocytes.TABLE 2. Serum biochemical profiles (mean,  $\bar{x}$ ; standard deviation, SD) for Group I and Group II desert tortoises.

Determinant <sup>a</sup>	Group I			Group II		
	<i>n</i> <sup>b</sup>	$\bar{x}$	SD	<i>n</i>	$\bar{x}$	SD
Glucose (mg/dl)	9	95	22	4	96	16
Sodium (mEq/L)	9	153	14	4	136	5
Potassium (mEq/L)	9	4.9	0.8	4	5.0	0.2
Chloride (mEq/L)	9	118	12	4	110	4
CO <sub>2</sub> (mEq/L)	9	29	6	4	29	4
BUN (mg/dl)	9	100	74	4	6	2
Creatinine (mg/dl)	9	0.3	0.1	4	0.2	0
Uric acid (mg/dl)	9	7.2	3.1	4	4.9	2.6
Calcium (mg/dl)	9	11.2	0.9	4	9.8	1.1
Phosphorus (mg/dl)	9	1.9	0.4	4	2.5	0.2
ALP (U/L)	9	114	52	4	152	49
SGOT (U/L)	9	117	62	4	56	24
SGPT (U/L)	9	2	1	4	2	0.4
Cholesterol (mg/dl)	9	305	180	4	83	23
Triglyceride (mg/dl)	9	18	15	4	17	7
Bilirubin (mg/dl)	9	0.1	0.1	4	0.05	0.05
Albumin (g/dl)	9	0.8	0.2	4	0.9	0.2
Globulins (g/dl)						
$\alpha_1$	9	0.6	0.2	4	0.5	0.1
$\alpha_2$	9	0.8	0.1	4	0.7	0.2
$\beta_1$	9	0.6	0.2	4	0.4	0.2
$\beta_2$	9	0.1	0.2	4	0	0
$\gamma$	9	0.8	0.6	4	0.9	0.1

<sup>a</sup> See text for definitions of determinant abbreviations.<sup>b</sup> Sample size.

TABLE 3. Liver and serum vitamins A and E ( $\bar{x}$ , mean; SD, standard deviation) for Group I and Group II desert tortoises.

	Group I			Group II		
	<i>n</i>	$\bar{x}$	SD	<i>n</i>	$\bar{x}$	SD
SVA <sup>a</sup> ( $\mu\text{g/ml}$ )	6	0.155	0.086	4	0.153	0.106
LVA <sup>b</sup> ( $\mu\text{g/gram}$ )	10	40.72	38.70	4	14.58	8.02
SVE <sup>c</sup> ( $\mu\text{g/ml}$ )	6	3.1	2.8	4	1.14	1.08
LVE <sup>d</sup> ( $\mu\text{g/gram}$ )	10	<1.00	—	4	<1.00	—

<sup>a</sup> Serum vitamin A.<sup>b</sup> Liver vitamin A.<sup>c</sup> Serum vitamin E.<sup>d</sup> Liver vitamin E.

### Normal anatomy and histology

The external nares were continuous with large nasal cavities, which were separated by an internasal septum (Fig. 1A, B). Ventrally, the nasal passageways were continuous with the choanae (internal nares), which opened into the palatine region of the dorsal oral cavity.

Histologic examination revealed the integument continued through the external nares into a short vestibule, which was initially lined by keratinized stratified squamous epithelium. However, on the ventrolateral aspects of this vestibule, there was an abrupt change to a mucous glandular epithelium. The vestibule subsequently opened into the nasal cavity. The mucosa of the rostral nasal cavity was comprised of areas of pseudostratified mucous epithelial cells, with associated ciliated epithelial cells (Fig. 2A) and areas of olfactory epithelium (Fig. 2B). Within the basal cell layer of the mucosa, a cell type with a large lightly basophilic nucleus was com-

monly seen. In the caudal nasal cavity, the olfactory epithelium was located on the dorsal surface and the mucous epithelium was ventral. Numerous serous and mucous glands, vessels, nerve bundles, and clusters of melanophores were present in the connective tissue surrounding the URT. With the exception of a small focal infiltrate of lymphocytes in the propria-submucosa of one tortoise, the URT of controls contained few inflammatory cells.

The thymus was easy to find in controls and was located on both sides of the trachea, cranial to the base of the heart, adjacent to the vagus nerve, and at the branching of the subclavian and carotid arteries. The thymus was multilobulated and measured from 1.2 to 2.0 by 0.7 to 1.5 cm. Histologically, there was a typically dark staining cortex and a lighter staining medulla. The disparity in staining was due to density of cells in each area. The cortex contained densely packed thymocytes and the medulla contained significantly fewer

TABLE 4. Liver values (ppm;  $\bar{x}$ , mean; SD, standard deviation) for minerals and heavy metals in Group I and Group II desert tortoises.

Assay <sup>a</sup>	Group I			Group II		
	<i>n</i>	$\bar{x}$	SD	<i>n</i>	$\bar{x}$	SD
Se	10	0.383	0.141	4	0.212	0.059
Cu	10	8.67	7.90	4	9.16	2.800
Fe	10	1,526	674	4	361	64
Pb	10	0.035	0.022	4	0.012	0.017
Cd	10	0.51	0.26	4	0.41	0.15
Hg	10	0.326	0.086	4	0.0287	0.017

<sup>a</sup> See text for definition of assay abbreviations.

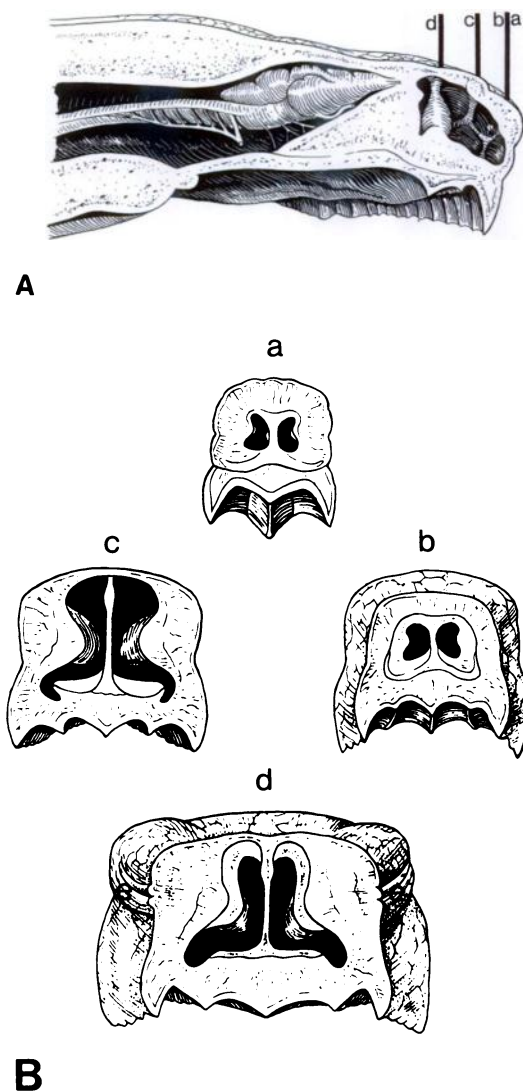


FIGURE 1. Diagrammatic representation of desert tortoise heads, sectioned longitudinally (A) and transversely (B). A large nasal cavity can be seen cranial to the eyes (e). Lines in A correspond to cross-sections in B. Sections a and b are opposite sides of the same cut.

thymocytes, as well as thymic epithelial cells, myoid cells and heterophils.

The spleen was located on the right side, between the proximal duodenum and transverse colon and was closely associated with pancreatic tissue. Spleens of healthy tortoises measured from 2.5 to 5 cm by 1.0 to 1.3 cm. Histologically, spleens were composed of distinct areas of white and

red pulp. White pulp consisted of collections of lymphoid tissue surrounding blood vessels. Red pulp, located between the perivascular collections of the white pulp, included red blood cells within sinusoids and few lymphoid cells.

#### Pathologic findings

At necropsy, small amounts of fat were found in the coelomic cavities of both Group I and Group II tortoises. Controls had more abundant subcutaneous fat in the axillary and inguinal areas of both fore- and hindlimbs.

Examination of longitudinally and transversely sectioned heads of ill tortoises revealed a moderate to large amount of exudate within the nasal cavity and nasal passageways. Microscopic findings were similar in the URT of all ill tortoises examined. In the nasal vestibule, there was a diffuse loss of mucosal glands. Glandular structures which remained were either replaced by and/or filled with proliferating epithelial cells (Fig. 3). In the more severely affected areas, there were dense infiltrates of lymphocytes and histiocytes that often formed a linear band which obscured the mucosal epithelium and extended into the deep lamina propria. It was frequently perivascular, and effaced mucosal glands. A moderate number of plasma cells and occasional Mott cells (activated plasma cells) were admixed with the lymphocytes and histiocytes.

In the olfactory mucosa, the normal multilayered arrangement of epithelial cells could not be discerned (Fig. 4A). Multifocally, there were variable numbers of heterophils in the lamina propria, transmigrating the mucosal epithelium, filling the lumina of mucosal glands, and accumulating on the mucosal surface. Heterophils were the predominant inflammatory cell in a few areas. Within the mucosal epithelium were small to moderate numbers of macrophages containing phagocytized cellular debris and, occasionally, variable sized, up to 5  $\mu$ m in diameter, pink, homogeneous, intracytoplasmic bod-



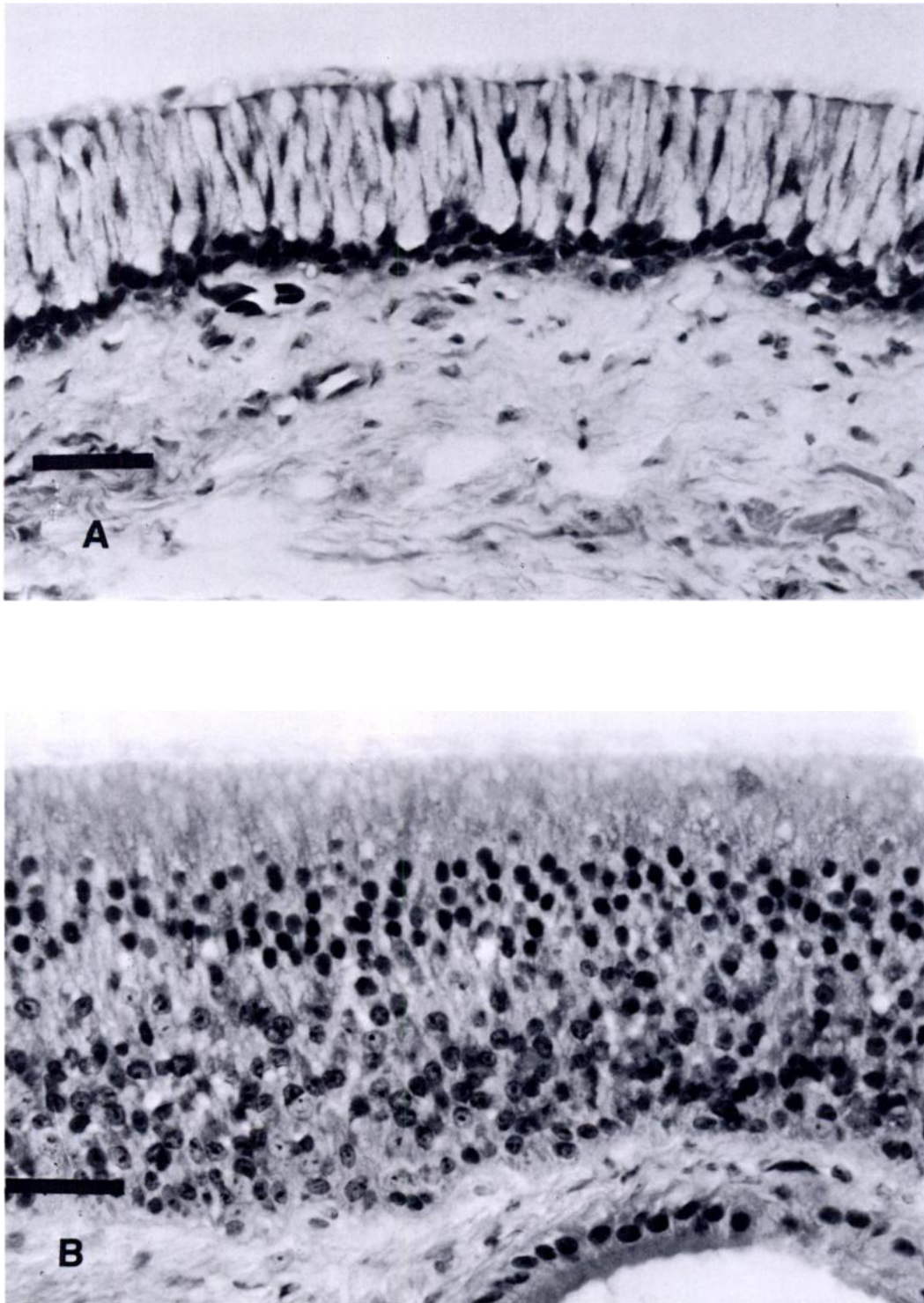


FIGURE 2. Photomicrographs of the nasal cavity of a healthy desert tortoise demonstrating an area of mucous and ciliated epithelial cells (A) and an area consisting of a multilayered olfactory epithelium (B). H&E. Bar = 30  $\mu$ m.

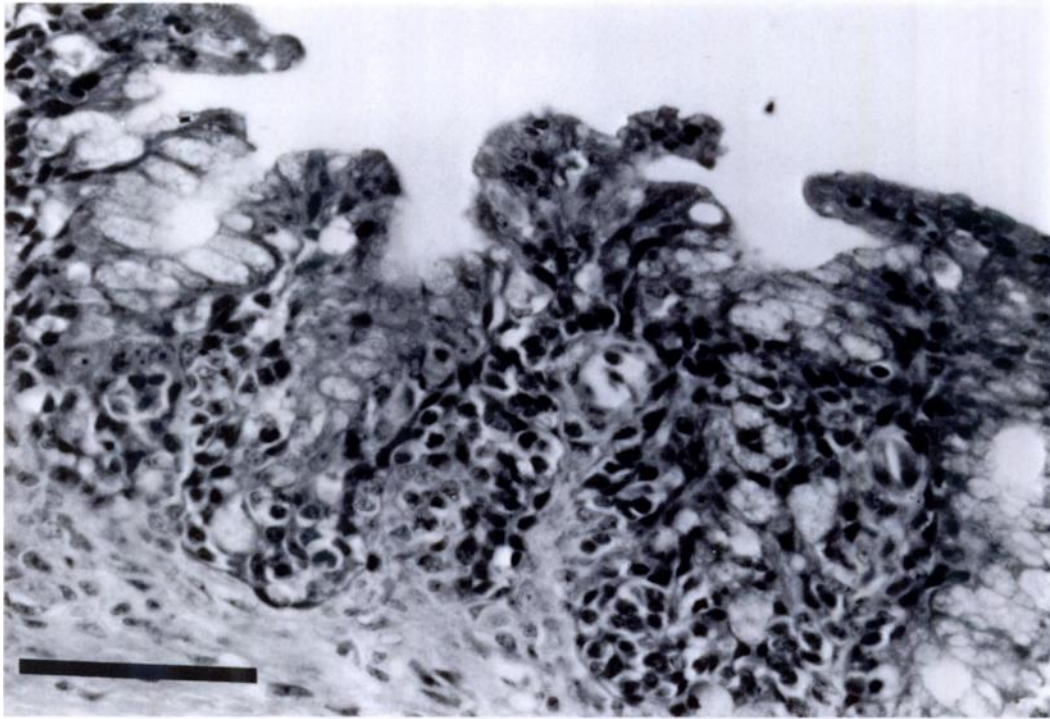


FIGURE 3. Photomicrograph of the nasal vestibule of a desert tortoise with URTD. There is a proliferation of mucosal epithelial cells, reduction in glandular structure, and infiltrates of mononuclear inflammatory cells. H&E. Bar = 100  $\mu$ m.

ies (Fig. 4B). These structures were interpreted as either cell debris or phagocytized heterophil granules.

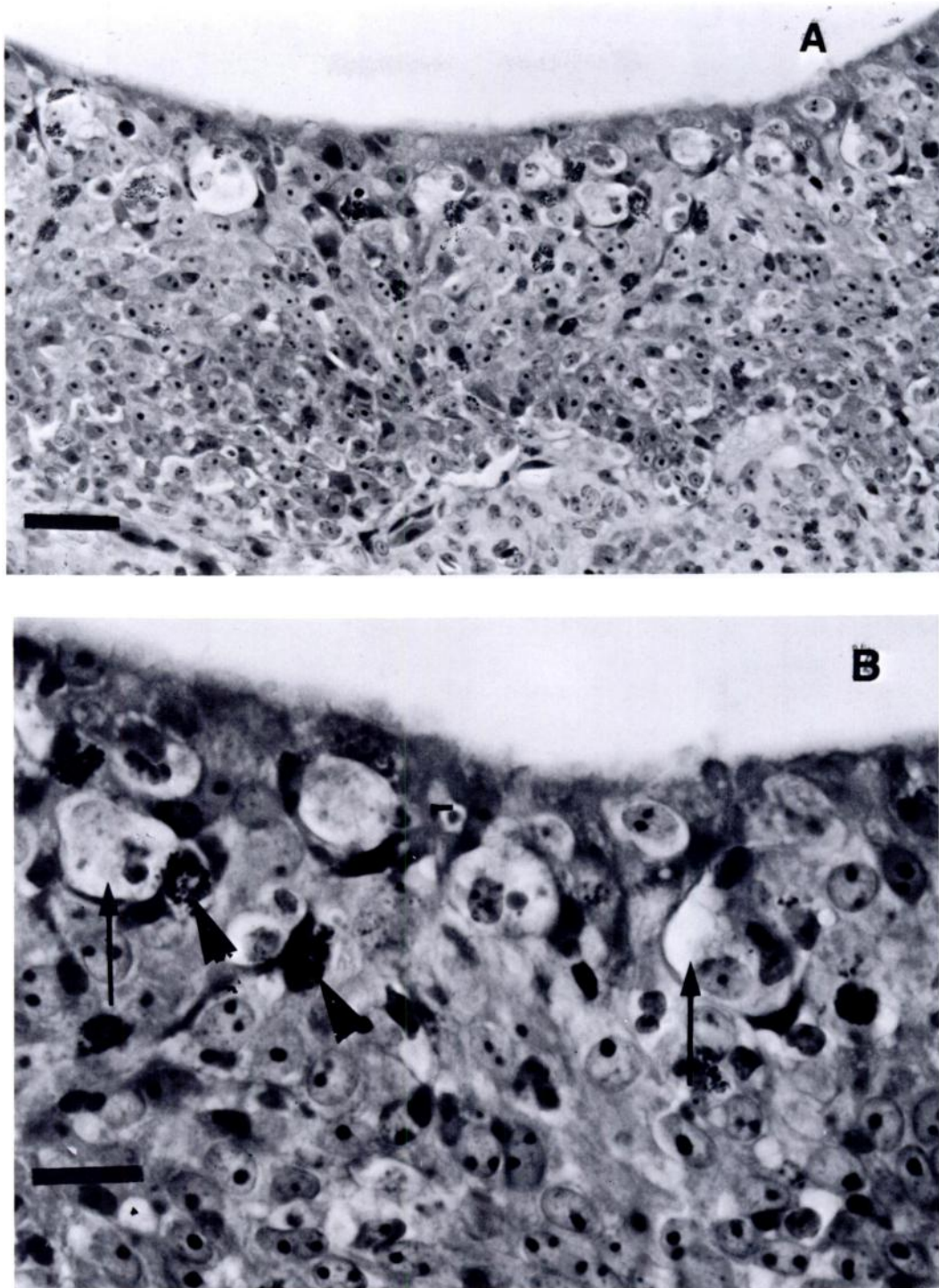
In areas of inflammation, there was loss of cilia, and atrophy and loss of goblet cells in the mucous segments of the mucosal epithelium. In both mucous and olfactory areas there was swelling and vacuolation of the epithelium, loss of cell cohesiveness, replacement of preexisting epithelium by proliferating undifferentiated basaloid cells, and occasional squamous metaplasia. The basaloid cell hyperplasia involved both surface epithelium and underlying glands, with formation of irregular downgrowths into underlying lamina propria and occasional replacement of glands. There was scattered individual epithelial cell necrosis and occasional erosion and ulceration of the mucosal epithelium.

In several tortoises, an exudate composed of necrotic cellular debris and heterophils partially filled the nasal passages.

Other changes observed in varying degrees were congestion and edema of the lamina propria and deeper connective tissue, and fibrosis of the lamina propria.

Scanning electron microscopical study of the nasal cavity mucosa of one ill tortoise revealed numerous pleomorphic organisms on the cell surface (Fig. 5). Occasionally, organisms were also seen to form chains. Examination of nasal cavity mucosa of four ill tortoises by transmission electron microscopy revealed pleomorphic organisms closely associated with cell membranes of surface epithelial cells (Fig. 6A, B). These organisms often were situated in part between microvilli. The organisms lacked cell walls and measured from 350 to 900 nm. Ultrastructurally, the organisms were consistent with members of the genus *Mycoplasma*. No similar organisms were seen on the mucosal surface of the nasal cavities of the two controls examined.





**FIGURE 4.** Photomicrograph of the olfactory epithelium of a desert tortoise with URTD. A. The normal multilayered arrangement of epithelial cells is replaced by proliferating undifferentiated cells, with infiltrates of lymphocytes, histiocytes, and heterophils. H&E. Bar = 30  $\mu$ m. B. At a higher magnification histiocytes with a vacuolated cytoplasm (arrows) and heterophils (arrow heads) are seen within the mucosal epithelium. H&E. Bar = 60  $\mu$ m.




FIGURE 5. Scanning electron photomicrograph of the nasal cavity mucosa of a desert tortoise with URTD. Pleomorphic organisms are diffusely seen on the mucosal surface. Bar = 5  $\mu$ m.

Histological examination revealed two Group I tortoises had focal proliferations of the epithelium in the trachea and bronchi. Nodules observed within the right lung lobe of one tortoise were composed of mature granulomas with caseous centers.

The thyroid of one Group I tortoise measured 2 by 1 cm, and was larger than thyroids of controls (0.7 to 1.2 cm by 0.7 to 0.8 cm). This thyroid consisted of proliferating follicular epithelial cells and well-developed follicles with abundant colloid. This was interpreted to be a colloid goiter.

The thymus of only two of 12 Group I tortoises could be located, and required acetic acid digestion of surrounding tissues for visualization. The thymus of these tortoises appeared to be smaller than those of

healthy tortoises. Since acetic acid digestion was utilized for visualization, accurate measurements could not be made. The cortex and medullary areas of these thymuses appeared to be more densely packed with thymocytes and the medullary area contained fewer epithelial and myoid cells compared to those of controls.

Gross examination revealed no remarkable differences between spleens of Group I and controls. However, microscopic examination revealed spleen of Group I tortoises contained less dense collections of lymphocytes around the periarteriolar and periellipsoidal vessels. In addition, the red pulp of the ill tortoises had increased numbers of lymphocytes in the sinusoids.

With H&E staining, golden brown gran-

FIGURE 6. Transmission photomicrographs of the nasal cavity mucosa of a desert tortoise with URTD. Intimate associations between organisms and host cell membranes can be seen. A. Bar = 1,000 nm; B. Bar = 400 nm.



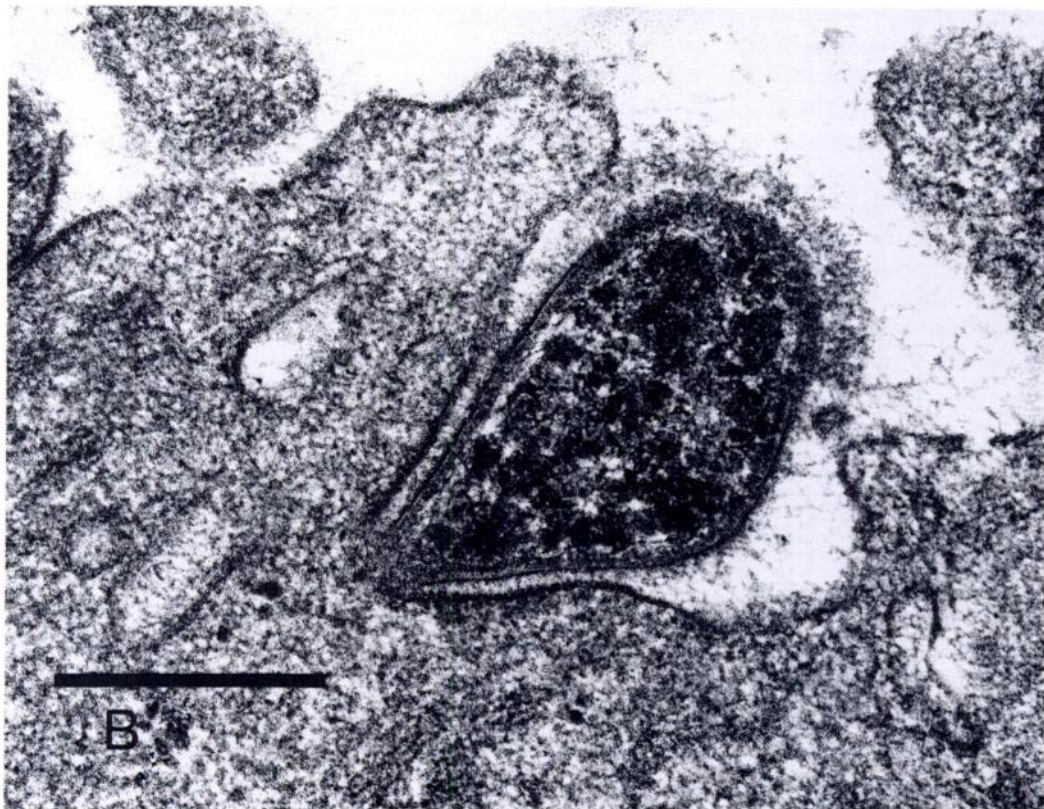
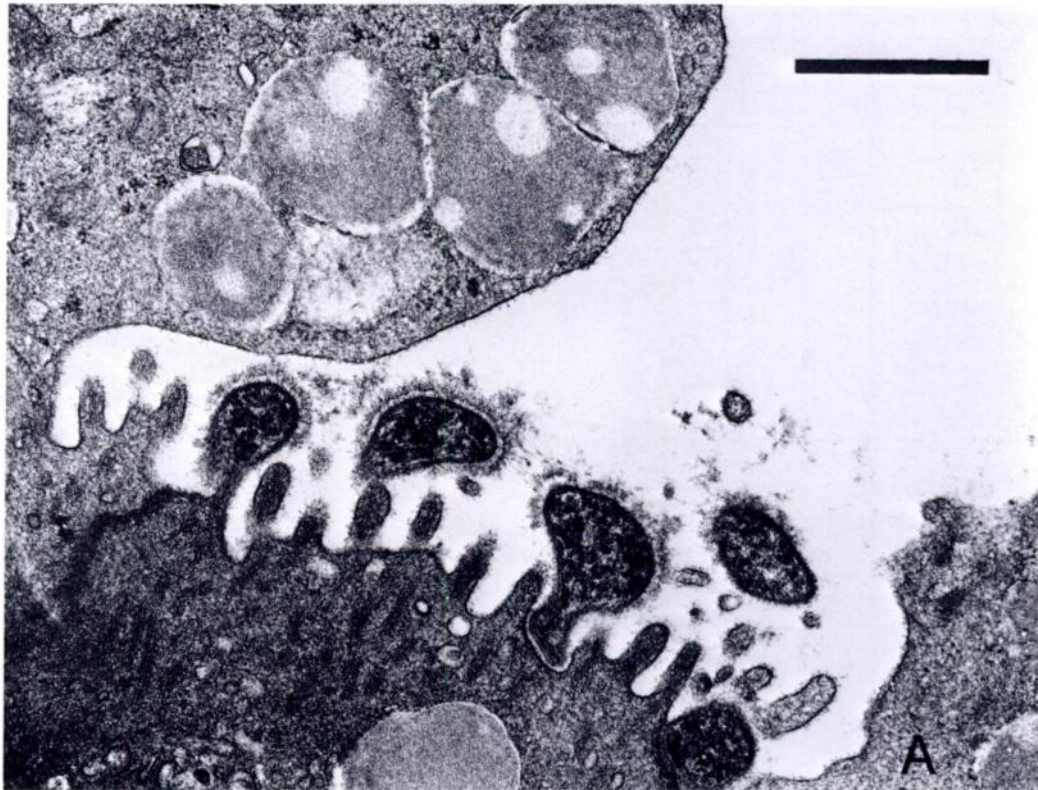

TABLE 5. Microbial isolates from respiratory tract of Group I and Group II desert tortoises.

Organism	Group I				Group II			
	CH <sup>a</sup>	NC <sup>a</sup>	TR <sup>a</sup>	LU <sup>a</sup>	CH	NC	TR	LU
<i>Staphylococcus</i> sp.	6/8 <sup>b</sup>	ND <sup>c</sup>	2/8	1/8	3/4	0/4	1/4	0/4
<i>Streptococcus</i> sp.	3/8	ND	0/8	1/8	1/4	0/4	0/4	0/4
<i>Corynebacterium</i> sp.	1/8	ND	0/8	0/8	0/4	0/4	0/4	0/4
<i>Bacillus</i> sp.	6/8	ND	2/8	0/8	0/4	0/4	0/4	0/4
<i>Aeromonas hydrophila</i>	1/8	ND	1/8	1/8	1/4	0/4	1/4	0/4
<i>Klebsiella oxytoca</i>	1/8	ND	0/8	0/8	0/4	0/4	1/4	0/4
<i>Enterobacter</i> sp.	1/8	ND	0/8	0/8	0/4	0/4	1/4	0/4
<i>Serratia</i> sp.	0/8	ND	0/8	0/8	1/4	0/4	0/4	0/4
<i>Pseudomonas</i> sp.	0/8	ND	0/8	0/8	1/4	0/4	0/4	0/4
<i>Pasteurella testudinis</i>	1/8	6/6	0/8	0/8	1/4	1/4	0/4	0/4
<i>Escherichia coli</i>	0/8	ND	1/8	2/8	0/4	0/4	0/4	0/4

<sup>a</sup> CH, choanae; NC, nasal cavity; T, trachea; L, lung.

<sup>b</sup> No. positive/No. cultured.

<sup>c</sup> Not determined.

ules were seen within hepatocytes and Kupffer cells throughout the livers of ill tortoises. In livers of healthy tortoises, fewer granules were seen. By the Prussian Blue method, most of these granules stained positive for iron.

#### Microbial investigations

Aerobic bacterial isolates from Groups I and II are presented in Table 5. A variety of gram-positive and gram-negative bacteria were isolated from the nasal passageways of Group I tortoises. While *Pasteurella testudinis* was cultured from the nasal cavity of all tortoises sampled in this group, it was only isolated from a choanal swab of one tortoise. Compared to the URT, fewer bacterial organisms were isolated from the trachea and lungs of Group I tortoises.

Few bacteria were isolated from the choanae, nasal cavities, tracheas and lungs of controls. *Pasteurella testudinis* was isolated from the nasal cavity of one control.

Viruses and *Chlamydia* spp. were not isolated from any of the tissues evaluated from Group I and II tortoises.

Microorganisms resembling *Mycoplasma* sp. were isolated from one tortoise in Group I, the one Group III tortoise, and from two tortoises in Group IV. All isolations were made in SP4 medium at 30 C.

These isolates were relatively slow growers (7 to 14 days) on primary isolation and fermented glucose. Passage in antibiotic-free medium did not cause the isolates to revert to bacterial colonies. By electron microscopy, the microorganism was found to measure 350 to 900 nm and lacked a cell wall (Fig. 7A, B). The morphology and size of the microorganism was consistent with the microorganism seen by electron microscopy on the mucosal epithelium of the nasal cavity of tortoises with URTD.

#### DISCUSSION

The URTD of free-ranging desert tortoises in the Mojave Desert was clinically similar to that described for captive desert tortoises (Snipes et al., 1980) and a variety of captive tortoises imported into England (Lawrence and Needham, 1985). We have seen this disease also in the following captive tortoises submitted to the Veterinary Medical Teaching Hospital, University of Florida (Gainesville, Florida 32610 USA): red-footed tortoises (*Geochelone carbonaria*), leopard tortoises (*Geochelone pardalis*), Indian star tortoises (*Geochelone elegans*), radiated tortoises (*Geochelone radiata*) and gopher tortoises (*Gopherus polyphemus*).

Anecdotal observations on captive desert tortoises suggest that this disease is



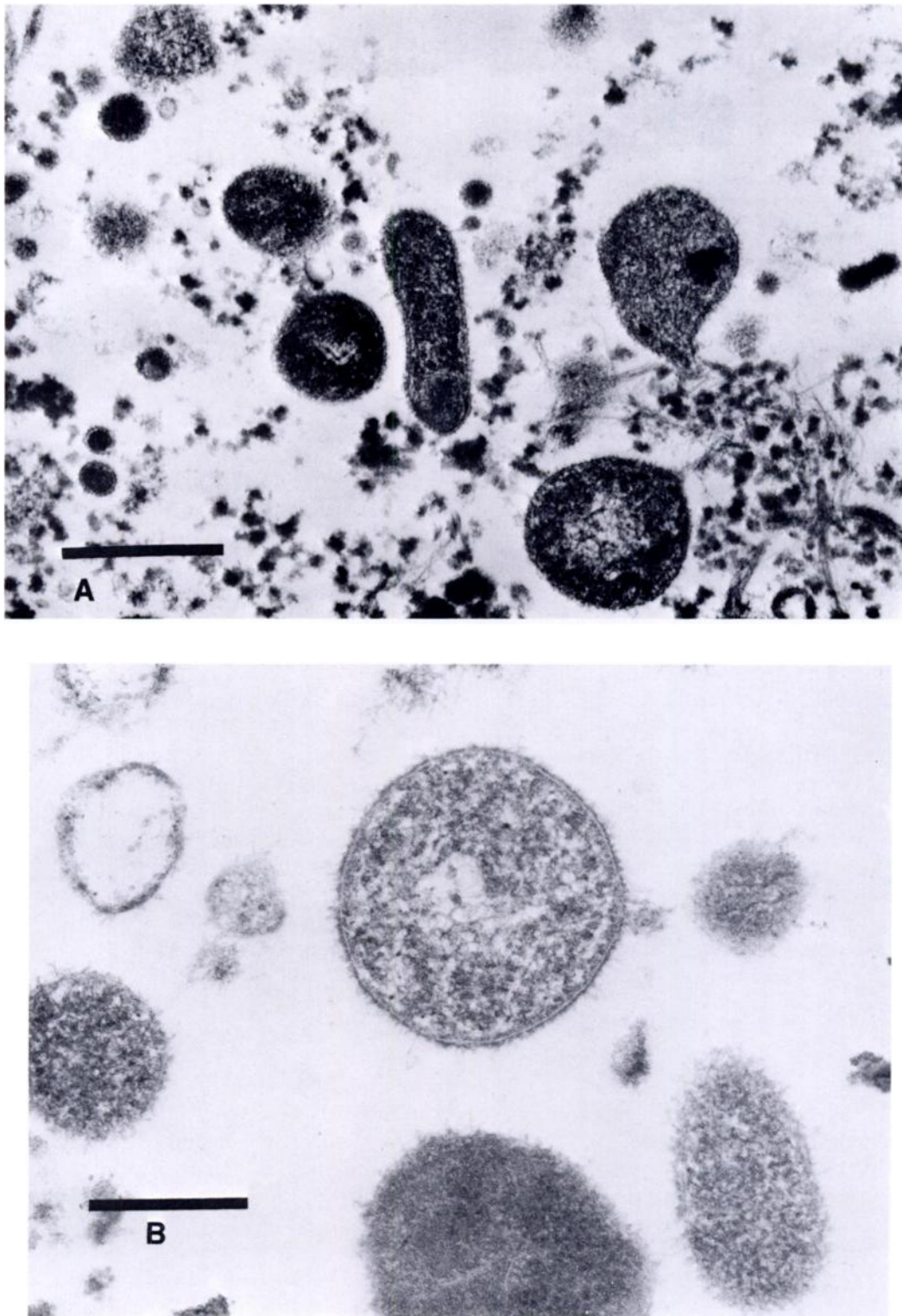


FIGURE 7. A. Ultrastructural appearance of *Mycoplasma* isolated from a desert tortoise. Bar = 1,000 nm. B. At a higher magnification, no cell wall can be seen. Bar = 500 nm.

highly infectious in nature (Roskopf, 1988). In the DTNA and adjacent areas, large numbers of desert tortoises became ill and died in a relatively brief period of time (Knowles, 1989). A similar decline in desert tortoises has been seen on the Beaver Dam slope of Arizona/Utah (USA), and tortoises ill with URTD have been found at this site (M. N. Coffeen, pers. comm.). Because most tortoises affected and dying of this disease are reproductive adults, the consequences for severely affected populations may be disastrous. In addition, recruitment of juveniles into the adult population of the western Mojave Desert, are further compromised because of raven predation (K. H. Berry, pers. comm.). Since the desert tortoise is one of the longest lived terrestrial vertebrates, requiring 12 to 20 yr to reach reproductive age in free-ranging females (Woodbury and Hardy, 1948) and producing small numbers of eggs in a clutch (Turner et al., 1986), we cannot expect to see recovery of severely affected populations in our life-time. As such on 2 April 1990, the Federal Government of the United States listed desert tortoise populations north and west of the Colorado River as threatened.

In desert tortoises and other tortoises, the disease is seen as a rhinitis characterized by an intermittent serous discharge flowing or bubbling from the nares. Tortoises will "wipe" the discharge using the cranial surface of their forelimbs and the surfaces may appear moist. On days where a discharge is not observable, the nares will appear dry. Captive tortoises in the early stages of the disease can maintain a good appetite.

As the disease progresses, the discharge becomes more tenacious and contains large numbers of inflammatory cells, desquamated epithelial cells plus myriads of bacteria. In several free-ranging ill desert tortoises examined as part of this study, the nasal passageways were occluded with exudate, and the nares were dry. In the field, when viewed at a distance, these tortoises might be considered healthy since no dis-

charge would be seen draining from the nares. Tortoises must be examined closely to determine the patency of the nares.

Severely affected tortoises appear unhealthy. The soft and hard integument may appear dull. There may be palpebral edema and the globes may be recessed into the orbits, indicating dehydration. Tortoises may appear listless and be anorectic.

The average duration of illness in free-ranging desert tortoises is unknown. One of the ill tortoises in Group I was first seen with a nasal discharge in August 1988. Clearly this disease is chronic in nature, lasting up to 1 yr before tortoises eventually die. In captivity, ill tortoises may survive for several years before succumbing to systemic disease. In our experience and the experience of others (Roskopf, 1988), no antibiotic or combination of antibiotics has been useful in successfully treating captive tortoises with this disease.

The percentage of tortoises which recover after showing clinical signs of illness is unknown. During a survey conducted at the DTNA and surrounding areas in the spring of 1989, several dying tortoises were found (Knowles, 1989). In all 627 carcasses were found in 11 sampled areas. One permanent long-term trend plot was sampled in 1989, and of 162 tortoises identified, 40 were dead (K. H. Berry, pers. comm.), suggesting that about 25% of the tortoises marked on the trend plot died within 1 yr. Eighty-four percent of the carcasses were in the sub-adult and adult age-size classes. Obviously, tortoises, many of which are >50 yr of age, were suddenly dying.

Hemoglobin concentrations for tortoises ill with URTD were significantly lower than those of controls. In domestic animals, anemia is often a secondary response following or associated with disease (Coles, 1986). Infectious agents such as blood parasites, bacteria and viruses may all result in excessive destructive or shortened erythrocyte life span. The anemia in the desert tortoises with URTD was probably secondary to the chronic inflammation.

Liver iron values of ill tortoises were



significantly higher than those of controls. Iron probably accumulated in the livers of chronically ill tortoises as a consequence of red blood cell breakdown and inability to reutilize iron released from hemoglobin. Hepatic hemosiderosis has been reported in mammals with hemolytic anemia and cachexia (Kelly, 1985). One of us (ERJ) has seen many cases of hemosiderosis in numerous species of recently imported carchectic reptiles.

Serum sodium, BUN, SGOT activity, and cholesterol were significantly higher and phosphorus significantly lower for ill tortoises compared to controls. Increases in plasma BUN have been reported in captive hibernating Mediterranean tortoises (*Testudo graeca* and *T. hermanni*) (Lawrence, 1987) and in Texas tortoises (*Gopherus berlandieri*) and desert tortoises which were experimentally dehydrated (Dantzler and Schmidt-Nielsen, 1966; Baze and Horne, 1970). In Texas tortoises, the activity of the urea cycle enzyme, argininosuccinate synthetase, also increased upon dehydration and fasting; this probably accounted for the increased urea production. During dehydration and fasting, a switch to greater protein catabolism may explain the increase in activity of argininosuccinate synthetase.

Ultimately, urea production may assist in water conservation by elevating plasma osmolality, thereby reducing water loss through the soft integument and increasing water uptake from the bladder. In the desert tortoises with URTD, the increased serum BUN and sodium may have been a response to lack of water and inadequate nutrient availability during the period between emergence and collection in late May. From October to December, 1988, there was only 25.6 mm of rain in Randsburg, approximately 6.3 km east of the DTNA, and this was inadequate in spring 1989 for germination of annual plants normally eaten by desert tortoises (K. H. Berry, pers. comm.). Further, since ill animals have higher caloric needs than healthy animals (Selivanov and Sheldon, 1984), if nu-

trients are initially a compromising factor in the health status of tortoises, then once a tortoise becomes ill, it probably becomes further compromised.

Serum cholesterol of ill tortoises was significantly greater than that of controls. Hypercholesterolemia has been seen in ponies and rabbits which were fasted experimentally (Aladjem and Rubin, 1954; Bauer, 1983). Although the exact mechanism for elevated blood cholesterol concentrations in these animals is unknown, mobilization of lipids from adipose tissue is probably involved. The elevated serum levels of cholesterol in the ill desert tortoises may similarly be a response to starvation and an attempt to meet energy needs through lipid metabolism. Some investigators have suggested that stored fats are a source of both energy and water in tortoises (Woodbury and Hardy, 1948; Khalil and Abdel-Messeih, 1962).

Glutamic oxalacetic transaminase is an enzyme which is produced at multiple tissue sites. Elevated serum levels of this enzyme reflect tissue damage (Coles, 1986). Activity for captive desert tortoises ranges from 10 to 100 IU/L (Roskopf, 1982). In the present study, SGOT activity for ill tortoises was significantly elevated above that of controls. Whether this is a response to specific or diffuse tissue damage is unknown.

Fowler (1980) believed that vitamin A deficiency was a predisposing factor in URTD of desert tortoises since squamous metaplastic changes were seen in captive desert tortoises with this disease. Squamous metaplasia of mucosal epithelium was not a major component of the disease in tortoises in the current study and it was considered a secondary response to the chronic inflammation in the involved tissues. Furthermore, serum and liver vitamin A values were not significantly different between ill and control tortoises. Hence vitamin A does not appear to be a factor in the pathogenesis of URTD.

Vitamin E, selenium, cadmium, copper and lead values in liver of ill tortoises were

similar to those of controls. However, liver mercury values (0.326 ppm) were significantly greater than those of controls (0.0287 ppm). Although these values were below those considered toxic for mammals (Koller et al., 1977), several investigators have reported altered host resistance to pathogens (Koller, 1975; Gainer, 1977), depressed antibody responses to mitogen stimulation (Koller, 1973; Koller et al., 1977), and thymic cortex and splenic follicular atrophy with concomitant depression of IgM and IgG antibody response to mitogen stimulation (Blakley et al., 1980) in rodents exposed to sublethal amounts of mercury. The thymus could only be found in two of 12 ill tortoises examined, whereas, it was easily observed in all four controls. Since malnutrition has also been reported to result in thymic involution and secondary infectious disease in turtles (Borysenko and Lewis, 1979), it is not possible to determine if mercury or other factors were responsible to thymic atrophy in the ill desert tortoises. Additional studies are needed to identify the source and significance of mercury in the desert tortoises in the DTNA.

The illness in free-ranging desert tortoises appears to primarily involve the URT, with minimal involvement of the LRT. Since moribund tortoises were not evaluated, it is unknown what ultimately kills these animals. Possibly, systemic invasion of opportunistic organisms may be an end-stage event in severely debilitated tortoises. In addition since ill tortoises appear to be in a negative nitrogen and energy balance, they may eventually die of cachexia.

The size range and ultrastructural appearance of the pleomorphic organism on the nasal mucosa suggested it was *Mycoplasma* sp. (Razin, 1981). *Mycoplasma* sp., although suspected as a potential cause of URTD of Mediterranean tortoises (Lawrence, 1987), has not been isolated previously from tortoises with URTD. Recently, Hill (1985) isolated *Mycoplasma testudi-*

*nis* from the cloaca of a Mediterranean tortoise (*T. graeca*).

Organisms forming colonies typical of *Mycoplasma* sp. were isolated from the URT of four ill desert tortoises. Electron microscopic evaluation of one of the isolates confirmed it to be identical in size and morphology to the *Mycoplasma* sp. demonstrated in tissue section. Still, immunohistochemical staining will have to be performed to clearly establish the identity of the organism seen in tissue section. No attempts have been made to isolate *Mycoplasma* sp. from clinically healthy tortoises, and we do not know if a carrier state exists in these animals.

Chlamydia or viruses were not isolated from the URT of ill tortoises. If a virus is involved in URTD of tortoises, it probably would only be present in abundance in the early stages of the disease. We have worked on other diseases of reptiles which initially commence as a viral infection and after a relatively brief period of time become complicated by secondary bacterial infection (Jacobson et al., 1986). Further viral isolation attempts need to be conducted on desert tortoises with URTD.

While a large number of gram-negative and gram-positive bacteria were isolated from nasal cavities of ill tortoises, relatively few organisms were isolated from those of healthy tortoises. The only bacterial organism consistently isolated from ill tortoises was *Pasteurella testudinis*; it was also isolated from one healthy tortoise. *Pasteurella testudinis* was originally isolated from desert tortoises ill with URTD and from healthy captive tortoises, and from free-ranging tortoises from the Mojave Desert in southern California (Snipes et al., 1980; Snipes and Biberstein, 1982). However, the disease could not be transmitted experimentally using isolates of *P. testudinis* in healthy desert tortoises.

Necrosis of the surface tissues and abscess formation, which are commonly seen in *Pasteurella* infections of mammals, were not seen in URTD of desert tortoises. Atrophy of nasal turbinates, with necrosis of

supporting bone, seen in rabbits with *P. multocida* infection (DiGiacomo et al., 1989) was not observed in tortoises. However, strains of *P. testudinis* with varying pathogenicity may exist in desert tortoises and maybe acting synergistically with another organism.

Mycoplasmas are the etiologic agents of respiratory disease in a number of hosts, including humans (*Mycoplasma pneumoniae*), pigs (*M. hyopneumoniae*), cattle (*M. mycoides* subsp. *mycoides*, *M. bovis*, *M. dispar*, *Ureaplasma diversum*), laboratory rodents (*M. pulmonis*) and poultry (*M. gallisepticum*, *M. melagridis*, *M. iowae*) (Casell et al., 1985). With the exception of *M. mycoides* subsp. *mycoides*, the mycoplasmas associated with respiratory disease produce chronic, slowly progressing infections which are frequently multifactorial. In many cases, these pathogens resemble opportunistic infections because they can be isolated from seemingly normal carriers. However, studies with gnotobiotic animals have demonstrated their pathogenic potential in the absence of other agents. In several cases, the interaction between mycoplasmas and other infectious agents is synergistic (Cassell et al., 1985; Gourlay and Houghton, 1985; Schoeb et al., 1985; Weinach et al., 1985). In these instances, the mycoplasma appears to be the initial colonizer of the respiratory tract and may predispose the host to secondary agents.

Although the pathogenic mechanisms are not fully defined, a concept for pathogenesis has been proposed which is relevant to most mycoplasmal infections (Cassell et al., 1985). Disease is dependent upon attachment and association of the mycoplasma with the host surface, elicitation of an immune response which may be detrimental as well as beneficial to the host, and interaction with the host immune system which may enhance chronicity. Attachment to host tissue may require specific receptors on the host surface as well as adhesins on the mycoplasma. To date, only the P1 protein of *M. pneumoniae* has

been fully characterized (Su et al., 1987). Attachment may or may not involve a specialized attachment tip (Cassell et al., 1985). Electron micrographs of the tortoise isolate suggest that the mycoplasmas isolated from diseased desert tortoises possess a putative attachment structure. Once attached to the host, mycoplasmas may cause cell injury by a variety of methods, including but not limited to ciliostasis, hydrogen peroxide production, and toxin production (Cassell et al., 1985; Gabridge et al., 1985). It has been suggested that the host defense system may influence lesion development. Many mycoplasmas are nonspecific mitogens, both for B and T cells (Cole et al., 1985). Recent evidence suggests that *M. pulmonis* can act as both a chemotactic and a chemokinetic agent in addition to its role as a mitogen (Ross et al., 1989).

Predisposing factors are very likely involved in the development and spread of this disease in free-ranging populations. Released, previously captive desert tortoises with URTD have been found on the DTNA and elsewhere within the geographic range of the desert tortoise. Possibly, an extremely pathogenic organism has been introduced into wild populations at multiple sites. Since captive desert tortoises are often exposed to other pet tortoises, possibly a pathogenic organism has been introduced by contact. We have recently isolated *Mycoplasma* sp. from a Greek tortoise (*Testudo graeca*) and leopard tortoises (*Geochelone pardalis*) with rhinitis. Furthermore, desert tortoises along roads are collected commonly by local citizens, tourists, and other travelers, and may ultimately be released at other sites. The ease with which tortoises can be collected and transported probably have contributed to the spread of the disease. This problem should be managed through massive education, within public schools, on radio and television, and through literature given to travelers in airports, at roadside rest areas, and border agricultural check stations.

Since nutritional deficiency diseases are known to result in immunosuppression (Miller, 1985; Nockels, 1988; Ullrey, 1986) and important infections in human populations are made more severe by the presence of malnutrition (Selivanov and Sheldon, 1984), habitat degradation and reduction in quality of forage must be considered as another potential predisposing factor in the severity and spread of this disease. It may be that domestic animals, by their grazing, are altering the physical environment and structure of plant and animal communities of the Mojave Desert (Webb and Stielstra, 1979). Since desert tortoises are selective feeders, consuming annual forbs, annual and perennial grasses, cacti, and on rare occasions some other items (K. H. Berry, pers. comm.), perhaps necessary nutrients are no longer available in the DTNA. Additionally, it seems unlikely that desert tortoises can compete with domestic animals for the same food resources. In one study, approximately 60% of the biomass of annuals were consumed by sheep grazing on a study plot in one day (Webb and Stielstra, 1979).

Superimposed are climatic factors which influence plant production. Studies of rainfall patterns in the Southwestern U.S. (Phillips et al., 1984), indicated that autumn rainfall in the Mojave Desert has never been as great as it was during the 1940's. Hastings and Turner's (1965) analyses of long-term changes of vegetation in southeastern Arizona and Mexico showed that profound changes in the vegetational communities of this region have occurred since the 1880's. In considering causes, they believed that a combination of climatic and cultural stress was responsible. Long-term studies will have to be done to correlate changes in plant structure, i.e., changes in nutrient availability to desert tortoises, with population dynamics of this species. Since malnutrition is known to cause thymic atrophy and immunosuppression in turtles (Borysenko and Lewis, 1979), structural and functional studies of the immune system need to be done to

identify the interplay between forage quality, immune status and URTD of desert tortoises. In this way the pathogenesis of URTD of desert tortoises may be better understood.

#### ACKNOWLEDGMENTS

The authors of this report would like to thank the following individuals for information provided and scientific support for various aspects of this study: Bobby Collins, College of Veterinary Medicine, University of Florida, Gainesville, Florida, USA; Kristin Berry, Bureau of Land Management, Riverside, California, USA; Michael Weinstein, SAIC, Santa Barbara, California, USA; Robert Benton, U.S. Fish and Wildlife Service, Salt Lake City, Utah, USA; Michael Coffeen, St. George, Utah, USA; James Tappe, National Animal Disease Center, Ames, Iowa, USA; and John Jenkins, Armed Forces Institute of Pathology, Washington, D.C., USA. This study was supported by the California Department of Fish and Game and U.S. Bureau of Land Management through contract No. CA 950-CT9-28 (BLM, California Desert District, Riverside, California, USA). Published as University of Florida, Agricultural Experiment Station Number R-00801.

#### LITERATURE CITED

- ALADJEM, F., AND L. RUBIN. 1954. Serum lipoprotein changes during fasting in rabbits. *American Journal of Physiology* 178: 67-68.
- BAUER, J. E. 1983. Plasma lipids and lipoproteins of fasted ponies. *American Journal of Veterinary Research* 44: 379-384.
- BAZE, W., AND F. R. HORNE. 1970. Ureogenesis in chelonia. *Comparative Biochemistry and Physiology* 34: 91-100.
- BLAKLEY, B. R., C. S. SISODIA, AND T. K. MUKKUR. 1980. The effect of methylmercury, tetraethyl lead, and sodium arsenite on the humoral immune response in mice. *Toxicology and Applied Pharmacology* 52: 245-254.
- BORYSENKO, M., AND S. LEWIS. 1979. The effect of malnutrition on immunocompetence and whole body resistance to infection in *Chelydra serpentina*. *Developmental and Comparative Immunology* 3: 89-100.
- CASELL, G. H., W. A. CLYDE, AND J. K. DAVIS. 1985. Mycoplasmal respiratory infections. In *The mycoplasmas*, Vol. IV, S. Razin and M. F. Barile (eds.). Academic Press, New York, New York, pp. 69-107.
- CATIGNANI, G. L., AND J. G. BIERI. 1983. Simultaneous determination of retinol and  $\alpha$ -tocopherol in serum or plasma by liquid chromatography. *Clinical Chemistry* 29: 708-712.

- COLE, B. C., Y. NAOT, E. J. STANBRIDGE, AND K. S. WISE. 1985. Interactions of mycoplasmas and their products with lymphoid cells *in vitro*. In *The mycoplasmas*, Vol. IV, S. Razin and M. F. Barile (eds.). Academic Press, New York, New York, pp. 204–258.
- COLES, E. H. 1986. *Veterinary clinical pathology*. W. B. Saunders Co., Philadelphia, Pennsylvania, 486 pp.
- DANTZLER, W. H., AND B. SCHMIDT-NIELSEN. 1966. Excretion in fresh-water turtle (*Pseudemys scripta*) and desert tortoise (*Gopherus agassizii*). *American Journal of Physiology* 210: 198–210.
- DIGIACOMO, R. F., B. J. DEEB, W. E. GIDDENS, B. L. BERNARD, AND M. M. CHENGAPPA. 1989. Atrophic rhinitis in New Zealand white rabbits infected with *Pasteurella multocida*. *American Journal of Veterinary Research* 50: 1460–1465.
- FOWLER, M. E. 1980. Comparison of respiratory infection and hypovitaminosis A in desert tortoises. In *The comparative pathology of zoo animals*, R. J. Montali and G. Migaki (eds.). Smithsonian Institution Press, Washington, D.C., pp. 93–98.
- GABRIDGE, M. G., D. K. F. CHANDLER, AND M. J. DANIELS. 1985. Pathogenicity factors in mycoplasmas and spiroplasmas. In *The mycoplasmas*, Vol. IV, S. Razin and M. F. Barile (eds.). Academic Press, New York, pp. 313–352.
- GAINER, J. H. 1977. Effects of heavy metals and of deficiency of zinc on mortality rates in mice infected with encephalomyocarditis virus. *American Journal of Veterinary Research* 38: 869–873.
- GOLDSTINE, S. N., V. MANICKAVEL, AND N. COHEN. 1975. Phylogeny of gut-associated lymphoid tissue. *American Zoologist* 15: 107–118.
- GOURLAY, R. N., AND S. B. HOUGHTON. 1985. Experimental pneumonia in conventionally reared and gnotobiotic calves by dual infection with *Mycoplasma bovis* and *Pasteurella haemolytica*. *Research in Veterinary Science* 38: 377–382.
- HASTINGS, J. R., AND R. M. TURNER. 1965. *The changing mile*. University of Arizona Press, Tucson, Arizona, 317 pp.
- HILL, A. C. 1985. *Mycoplasma testudinis*, a new species isolated from a tortoise. *International Journal of Systematic Bacteriology* 35: 489–492.
- JACKSON, O. F., AND J. R. NEEDHAM. 1983. Rhinitis and virus antibody titers in chelonians. *Journal of Small Animal Practice* 24: 31–36.
- JACOBSON, E. R. 1978. Diseases of the respiratory system of reptiles. *Veterinary Medicine/Small Animal Clinician* 73: 1169–1175.
- . 1986. Viruses and viral associated diseases of reptiles. *Acta Zoologica et Pathologica Antverpiensia* 79: 73–90.
- , J. M. GASKIN, M. ROELKE, E. GREINER, AND J. ALLEN. 1986. Conjunctivitis, tracheitis, and pneumonia associated with herpesvirus infection in green sea turtles. *Journal of the American Veterinary Medical Association* 189: 1020–1023.
- KELLY, W. R. 1985. The liver and biliary system. In *Pathology of domestic animals*, 3rd ed., Vol. 2, Chpt. 2. Academic Press, New York, New York, pp. 239–312.
- KEYMER, I. F. 1978. Diseases of chelonians (1) Necropsy survey of tortoises. *Veterinary Record* 103: 548–552.
- KHALIL, F., AND G. ABDEL-MESSEIH. 1962. Tissue constituents of reptiles in relation to their mode of life. II. Lipid content. *Comparative Biochemistry and Physiology* 6: 171–174.
- KNOWLES, C. 1989. A survey for diseased desert tortoises in and near the Desert Tortoise Natural Area, Spring 1989. Report prepared for the Bureau of Land Management, Riverside, California (Contract No. CA 950-(T9-23), 26 pp.
- KOLLER, L. D. 1973. Immunosuppression produced by lead, cadmium, and mercury. *American Journal of Veterinary Research* 34: 1457–1458.
- . 1975. Methylmercury: effect on oncogenic and nononcogenic viruses in mice. *American Journal of Veterinary Research* 36: 1501–1504.
- , J. H. EXON, AND J. A. BRAUNER. 1977. Methylmercury: Decreased antibody formation in mice. *Proceedings of the Society for Experimental Biology and Medicine* 155: 602–604.
- LAWRENCE, K. 1987. Seasonal variation in blood chemistry of long term captive Mediterranean tortoises (*Testudo graeca* and *T. hermanni*). *Research in Veterinary Science* 43: 379–383.
- , AND J. R. NEEDHAM. 1985. Rhinitis in long term captive Mediterranean tortoises (*Testudo graeca* and *T. hermanni*). *Veterinary Record* 117: 662–664.
- LUNA, L. G. 1968. *Manual of histologic staining methods of the Armed Forces Institute of Pathology*, 3rd ed. McGraw-Hill Book Company, New York, New York, 258 pp.
- MIGAKI, G., E. R. JACOBSON, AND H. W. CASEY. 1984. Fungal diseases in reptiles. In *Diseases of amphibians and reptiles*, G. L. Hoff, F. L. Frye, and E. R. Jacobson (eds.). Plenum Press, New York, New York, pp. 183–204.
- MILLER, E. R. 1985. Mineral × disease interactions. *Journal of Animal Science* 60: 1500–1507.
- NOCKELS, C. F. 1988. Increased vitamin needs during stress and disease. *Proceedings of the Georgia Nutrition Conference for the Feed Industry* 1988: 9–16.
- PHILLIPS, A., P. SCHUMANN, K. BOHUSKI, AND V. RYDEN. 1984. Rainfall patterns in the southwest and the desert tortoise. Appendix 9. In *The status of the desert tortoise (Gopherus agassizii) in the United States*, K. H. Berry (ed.). Report to U.S. Fish and Wildlife Service from the Desert Tortoise Council on Order Number 11310-0083-81, 29 pp.
- POOLE, C. F., N. J. EVANS, AND D. G. WIBBERLEY.

1977. Determination of selenium in biological samples by gas-liquid chromatography with electron capture detection. *Journal of Chromatography* 136: 73-83.
- RAZIN, S. 1981. Mycoplasmas: The smallest pathogenic procaryotes. *Israel Journal of Medical Science* 17: 510-515.
- , AND J. G. TULLY. 1983. Methods in mycoplasmaology, Vol. I, *Mycoplasma* characterization. Academic Press, New York, New York, pp. 127-158.
- ROSS, S., G. GAMBILL, J. SIMECKA, J. DAVIS, AND G. H. CASSELL. 1989. Chemotactic properties of *Mycoplasma pulmonis* for rat leukocytes. 89th American Society for Microbiology Meeting Abstracts G12: 150.
- ROSSKOPF, W. J. 1982. Normal hemogram and blood chemistry values for California desert tortoises. *Veterinary Medicine/Small Animal Clinician* 77: 85-87.
- . 1988. Protocol for treating diseased tortoises (respiratory disease) at the Desert Tortoise Natural Area. Report to the U.S. Bureau of Land Management, California Desert District, Riverside, California, Contract No. CA 950-(T8-51), 22 pp.
- SCHERMER, S. 1967. The blood morphology of laboratory animals, 3rd ed. F. A. Davis, Philadelphia, Pennsylvania, 212 pp.
- SCHOEB, T. R., K. C. KERVIN, AND J. R. LINDSEY. 1985. Exacerbation of murine respiratory mycoplasmosis in gnotobiotic F344/N rats by Sendai virus infection. *Veterinary Pathology* 22: 272-282.
- SELIVANOV, V., AND G. F. SHELDON. 1984. Enteral nutrition and sepsis. In *Enteral and tube feeding*, J. L. Rombeau and M. D. Caldwell (eds.). W. B. Saunders Company, Philadelphia, Pennsylvania, pp. 403-411.
- SNIPES, K. P., AND E. L. BIBERSTEIN. 1982. *Pasteurella testudinis* sp. nov.: A parasite of desert tortoises. *International Journal of Systematic Bacteriology* 32: 201-210.
- , E. L. BIBERSTEIN, AND M. E. FOWLER. 1980. A *Pasteurella* sp. associated with respiratory disease in captive desert tortoises. *Journal of the American Veterinary Medical Association* 177: 804-807.
- SU, C. J., V. V. TRYON, AND J. B. BASEMAN. 1987. Cloning and sequence analysis of cytoadhesin P1 gene from *Mycoplasma pneumoniae*. *Infection and Immunity* 55: 3023-3029.
- TURNER, F. B., P. HAYDEN, B. L. BURGE, AND J. B. ROBERSON. 1986. Egg production by the desert tortoise (*Gopherus agassizii*) in California. *Herpetologica* 42: 93-104.
- ULLREY, D. E. 1986. Mineral nutrition and the immune system. *Proceedings of the 21st Annual Pacific Northwest Animal Nutrition Conference* 1986: 42-59.
- WEBB, R. H., AND S. S. STIELSTRA. 1979. Sheep grazing effects on Mojave Desert vegetation and soils. *Environmental Management* 3: 517-529.
- WEINACH, O. M., G. H. SNOEYBOS, C. F. SMEYER, AND A. S. SOERJUDE-LIEM. 1985. Influence of *Mycoplasma gallisepticum*, infectious bronchitis, and cyclohexamide on chickens protected by native intestinal microflora against *Salmonella typhimurium* or *Escherichia coli*. *Avian Diseases* 28: 416-425.
- WOODBURY, A. M., AND R. HARDY. 1948. Studies of the desert tortoise, *Gopherus agassizii*. *Ecological Monographs* 18: 145-200.

Received for publication 21 June 1990.