



## **GUT ASSOCIATED LYMPHOID TISSUE IN THE COTTON RAT (SIGMODON HISPIDUS) AND ITS RESPONSE TO PROTEIN RESTRICTION**

Authors: Lochmiller, Robert L., Vestey, Michelle R., and Nash, Dana

Source: Journal of Wildlife Diseases, 28(1) : 1-9

Published By: Wildlife Disease Association

URL: <https://doi.org/10.7589/0090-3558-28.1.1>

---

BioOne Complete ([complete.BioOne.org](https://complete.BioOne.org)) is a full-text database of 200 subscribed and open-access titles in the biological, ecological, and environmental sciences published by nonprofit societies, associations, museums, institutions, and presses.

Your use of this PDF, the BioOne Complete website, and all posted and associated content indicates your acceptance of BioOne's Terms of Use, available at [www.bioone.org/terms-of-use](https://www.bioone.org/terms-of-use).

Usage of BioOne Complete content is strictly limited to personal, educational, and non - commercial use. Commercial inquiries or rights and permissions requests should be directed to the individual publisher as copyright holder.

---

BioOne sees sustainable scholarly publishing as an inherently collaborative enterprise connecting authors, nonprofit publishers, academic institutions, research libraries, and research funders in the common goal of maximizing access to critical research.

## GUT ASSOCIATED LYMPHOID TISSUE IN THE COTTON RAT (*SIGMODON HISPIDUS*) AND ITS RESPONSE TO PROTEIN RESTRICTION

Robert L. Lochmiller, Michelle R. Vestey, and Dana Nash

Department of Zoology, Oklahoma State University, Stillwater, Oklahoma 74078, USA

**ABSTRACT:** We examined age and nutritional related changes in the distribution and size of gut associated lymphoid tissues in the intestinal tract of cotton rats (*Sigmodon hispidus*). Peyer's patches in the small intestine are prominent, ranging from four to 13, and increase in size (surface area) with age. The average Peyer's patch in the adult cotton rat measured 23.9 mm<sup>2</sup>. Lymphoid tissue in the cecum was primarily limited to a large aggregate located in the vermiform appendix, which increased in size with age. Age related changes in the number of visible lymphoid follicles in the large intestine were highly significant, increasing from 24.8 in juveniles to 45.1 in adults. Weights of dissectable Peyer's patch tissue in animals consuming a low protein diet were significantly lower in juveniles and greater in subadults compared to those on high protein diets. Relative weights of Peyer's patch tissue averaged 84 to 95% more in low protein-fed animals than in the group on the high quality protein diet. Our results suggest that peripheral lymphoid tissues in wild cotton rats are more resistant to protein deficiencies than other tissues in the body and could be a useful index for assessing nutritional status.

**Key words:** Cotton rats, *Sigmodon hispidus*, Peyer's patches, gut associated lymphoid tissue, lymphoid tissue, protein nutrition, malnutrition, immunology.

### INTRODUCTION

Immune mechanisms of mucosal tissues have received considerable attention from researchers during recent years (Asquith, 1979; Bourne, 1981). The gut associated lymphoid tissue (GALT) system forms an important part of the peripheral mucosal immune system, providing localized immunity in the intestinal tract for coping with ingested materials that are potentially antigenic and pathogenic (Whitehead and Skinner, 1978). Two basic types of lymphoid tissues are found in the mammalian intestinal tract; multiple aggregates known as Peyer's patches in the small intestine and isolated lymphoid follicles scattered throughout the intestinal tract. Histologic descriptions of their structure and cell content are available for a number of different domestic and laboratory mammalian species (Cooper et al., 1968; Faulk et al., 1971; Cole and Morris, 1973; Waksman et al., 1973; Chapman et al., 1974; Lopez et al., 1985).

The GALT system is an area of intense lymphopoietic activity following antigenic stimulation in the gut (Kagnoff, 1978) and responsible for the generation of the IgA

lineage of B lymphocytes (Craig and Cebra, 1971; Kawanishi et al., 1983). Alterations in mucosal immune system function have been observed in response to nutritional restriction in humans (Chandra, 1983) and laboratory rodents (McGee and McMurray, 1988). During protein and calorie restriction, secretory IgA levels in gut secretions are often depressed (Reddy et al., 1976) and Peyer's patch tissues have been shown to atrophy (Lopez et al., 1985). Immunosuppression at the gut can lead to enteric disease which often results in malabsorption states (Gershwin et al., 1985).

Despite the importance of GALT in inhibition of microbial pathogen colonization and infiltration of dietary antigens, little is known of its structure and function in wild rodents. Basic information on the structure of this component of the peripheral immune system and its response to various environmental stressors such as nutritional restriction is needed to better understand disease and how it may influence the dynamics of rodent populations. Consumption of low protein forage is common in wild herbivore populations and can result in high mortality rates within juvenile



age classes (White, 1978). This study was initiated to elucidate the distribution and gross morphology of GALT throughout the intestinal tract of the cotton rat (*Sigmodon hispidus*) and to examine the effects of consuming a diet low in protein on its gross development.

## MATERIALS AND METHODS

### Distribution of GALT

To provide baseline information on the distribution and size of GALT in cotton rats, we used either wild-caught or offspring of wild-caught animals maintained in our conventional outbred laboratory colony (Oklahoma State University, Stillwater, Oklahoma 74078, USA). All animals were maintained in the laboratory for at least 1 wk on a commercial laboratory chow diet prior to use and were housed (two to four/cage) in standard plastic cages (48 × 27 × 20 cm) with sawdust bedding. Animals were classified into age-groups on the basis of body weight criteria (juveniles <60 g; subadults 60–99 g; adults >100 g) (Stafford and Stout, 1983). Animals were anesthetized with ketamine hydrochloride prior to cervical dislocation and evisceration. The intestinal tract from the duodenum to the rectum was removed from each animal, separated from the mesentery, any adhering fat tissue removed, and subjected to acetic acid treatment as described below.

### Experimental protein nutrition trials

Weanling (18-days-old,  $n = 41$ , trial = 3 wk duration), juvenile (5-wk-old,  $n = 22$ , trial = 6 wk duration), and subadult (8-wk-old,  $n = 45$ , trial = 6 wk duration) cotton rats were used in a series of three experimental trials to examine the effects of protein concentration in the diet on the development of GALT. For each trial, animals were blocked by litter and randomly assigned to either a high (16% crude protein) or low (4% crude protein) quality diet. Diets were isocaloric and formulated with casein as the protein source (United States Biochemical, Cleveland, Ohio 44128, USA).

Experimental diets and water were provided ad libitum during each trial which we felt better reflected foraging conditions in the wild where low quality forage is highly available (Batzli, 1985). Daily food consumption of low and high quality diets by experimental subjects in the juvenile trial was measured to document that diets were palatable and determine if animals fed a low quality diet could compensate for protein quality by increased consumption. A known weight of food was introduced into cages

and uneaten portions reweighed the following day.

After termination of each trial, animals were anesthetized, sacrificed, and intestinal tracts removed as described above. Intestinal tracts of weanling and juvenile cotton rats were subjected to acetic acid treatment to highlight Peyer's patches before obtaining weights of tissues; tracts of subadults were processed fresh due to their larger size.

### Acetic acid treatment

Intestinal tracts were split-open along the longitudinal axis approximated by the junction of the tracts with the mesenteries. Intestinal contents were thoroughly washed from the tract with phosphate buffered saline. The acetic acid treatment procedure of Cornes (1965) was used to remove epithelial tissue for macroscopic visualization of lymphoid aggregates along the intestinal tract. Basically, washed intestinal tracts were laid flat on a styrofoam board, secured in place with pins, and immersed in 10% acetic acid overnight at room temperature. Following acetic acid treatment, intestinal tracts were again washed with buffered saline, sandwiched between two clear sheets of acetate, and a permanent record of the number and distribution of lymphoid aggregates made by tracing the outline of the intestinal tract and the position and size of each aggregate. Lymphoid aggregates and individual lymphoid follicles were quite visible following acetic acid treatment, appearing as white patches, as previously described for other species (Cornes, 1965; Goldstine et al., 1975; Langman et al., 1986). Confirmation that these white nodules were lymphoid aggregates was made by histologically examining selected nodules using light microscopy.

### Morphometrics

Measurements on the number, size, and distribution of GALT were made for the small intestine, cecum, and large intestine of cotton rats. The Peyer's patches in the small intestine, cecal patches and lymphoid follicles in the cecum, and lymphoid follicles and lymphoid aggregates (aggregation of >4 lymphoid follicles) in the large intestine were enumerated. Solitary lymphoid follicles in the intestine have also been termed lymphoid nodules (Keren, 1978). The total number of follicles in all Peyer's patches was determined in 20 adult cotton rats after acetic acid-treated small intestinal tracts were sandwiched between two sheets of clear acetate and viewed on a light-table. Peyer's and cecal patches were assumed to be ellipsoidal in shape (Langman et al., 1986). Perpendicular diameters (to the nearest 0.01 mm) of each patch were

measured using vernier calipers and surface area calculated using the surface area formula for an ellipsoid (area =  $\pi r_1 \times r_2$ ). Both the total surface area contributed by all Peyer's patches and the mean size (surface area) of an individual Peyer's patch were calculated for each cotton rat.

The effects of protein restriction on experimental animals were examined by measuring the development of Peyer's patch tissues. Peyer's patches were enumerated and carefully dissected from acetic acid-treated (weanling and juvenile trials) or fresh (subadult trials) small intestinal tracts. Removed Peyer's patches were gently blotted dry and total weight recorded for each animal (Lopez et al., 1985). Because of processing differences we did not compare weights between acetic acid-treated and fresh Peyer's patches.

**Statistical analysis**

Differences in the number and size of lymphoid tissues and other morphometric parameters among juvenile, subadult, and adult cotton rats were tested for significance by one-way analysis of variance using SYSTAT (Wilkinson, 1989). When significance was indicated, differences among means were determined by Tukey's HSD multiple range test. Differences in relative food consumption between diet groups was tested using a t test. The effects of protein quality on Peyer's patch development were examined by analysis of variance with litter (block effect) and diet (high, low) as main factors.

**RESULTS**

**Distribution of GALT**

The distribution of Peyer's patches in the small intestine was similar among individuals, although differences in number were apparent. A few solitary lymphoid follicles were visible in the proximal duodenum adjacent to the stomach in a small number of individuals. Distinct Peyer's patches were the only lymphoid aggregates visible in the small intestine of the majority of cotton rats examined. Only two Peyer's patches could be consistently located in the same anatomical area in the small intestine. The proximal duodenal patch was small in size and occurred 3 to 5 cm from the pylorus. All animals had a large Peyer's patch in the terminal ileum about 1 to 3 cm from the ileocecal junction. Other Peyer's patches were distributed in an unpredictable manner between the

TABLE 1. Distribution and size (surface area) of gut associated lymphoid tissue in the intestinal tract of juvenile, subadult, and adult cotton rats (*Sigmodon hispidus*). A large intestine lymphoid aggregate is defined as a cluster of >4 lymphoid follicles.

Measurement	Statistic	Age class		
		Juvenile	Subadult	Adult
Number of Peyer's patches per animal	n	32	29	35
	$\bar{x}$	6.33 <sup>a</sup>	7.31 <sup>a</sup>	7.40 <sup>a</sup>
	SE	0.38	0.44	0.34
Peyer's patch size (surface area, mm <sup>2</sup> /patch)	n	9	15	13
	$\bar{x}$	12.9 <sup>a</sup>	17.0 <sup>a,b</sup>	23.9 <sup>a,c</sup>
	SE	2.6	2.5	2.0
Total surface area (all patches, mm <sup>2</sup> )	n	9	15	13
	$\bar{x}$	76.7 <sup>a</sup>	113.8 <sup>a</sup>	162.4 <sup>b</sup>
	SE	8.7	13.0	10.0
Large intestine, number of lymphoid follicles	n	32	36	52
	$\bar{x}$	24.8 <sup>a</sup>	35.5 <sup>b</sup>	45.1 <sup>c</sup>
	SE	1.7	2.0	1.9
Large intestine, number of lymphoid aggregates	n	32	36	52
	$\bar{x}$	1.0 <sup>a</sup>	2.1 <sup>a</sup>	5.0 <sup>b</sup>
	SE	0.0	0.3	0.4
Cecal lymphoid patch (mm <sup>2</sup> )	n	9	14	10
	$\bar{x}$	8.0 <sup>a</sup>	23.4 <sup>b</sup>	30.7 <sup>c</sup>
	SE	1.8	1.7	1.9

<sup>a,b,c</sup> Means followed by the same letter were not significantly different (P = 0.05).

proximal duodenal and terminal ileal patches.

Although the mean number of Peyer's patches per individual was lower for juveniles compared to adults (Table 1), the difference was not significant (P > 0.05). The number of Peyer's patches per individual ranged from 4 to 13, with an overall mean of 7.2 ± 0.38 (SE). Size (surface area, mm<sup>2</sup>) distribution of Peyer's patches was quite variable and influenced by age. Average size of Peyer's patches in adults was twice as large as those in juveniles (P < 0.02). Average size of Peyer's patches in subadult cotton rats was intermediate and did not differ (P > 0.10) from juveniles, but tended (P > 0.09) to be smaller than mature adults. The terminal ileocecal Peyer's patch was one of the largest, averaging 28.4 ± 2.0 (SE) mm<sup>2</sup> in mature adults. The

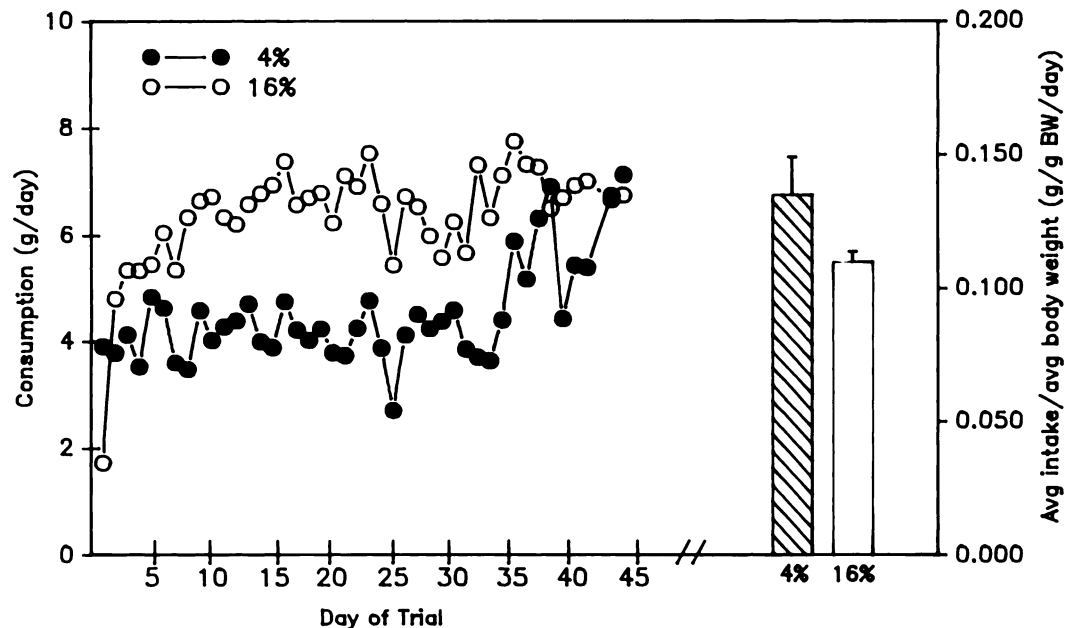


FIGURE 1. Mean daily food consumption (g/day) of juvenile cotton rats fed isocaloric diets containing either 4% or 16% protein. Consumption was measured at 4-day intervals throughout the 6-wk trial. Relative food consumption measured as average daily intake/average body weight is shown as a bar graph with standard error bar.

proximal duodenal Peyer's patch was smaller in size, averaging  $17.8 \pm 2.5$  (SE)  $\text{mm}^2$  in adults. The total number of follicles in all Peyer's patches of 20 individual adult cotton rats averaged  $103 \pm 5.5$  (SE).

All animals examined possessed a prominent lymphoid aggregate located in the vermiform appendix of the cecum. This cecal lymphoid patch was identical in gross appearance to the Peyer's patches of the small intestine. Most animals possessed no other lymphoid tissue in the cecum; however, a small number of additional solitary lymphoid follicles was present in the cecum of a few subadults and adults. Size of the cecal lymphoid patch differed significantly ( $P < 0.01$ ) among age classes (Table 1).

Large lymphoid aggregates were not present in the large intestine of cotton rats. Solitary lymphoid follicles were widely distributed throughout the entire length of the large intestine. Only a very small number of actual aggregates (defined as a cluster of  $\geq 4$  lymphoid follicles) were observed in the tracts examined (Table 1).

Both the number of lymphoid follicles and aggregates differed significantly ( $P < 0.01$ ) among age classes: greater in adults than younger age classes and greater in subadults compared to juveniles. The number of lymphoid aggregates also increased with increasing age, with greater numbers in adults compared to younger age classes.

#### Effect of diet protein content

Both the 4 and 16% protein diets were highly palatable with an overall average intake of  $4.26 \pm 0.43$  (SE) and  $7.62 \pm 0.21$  (SE) g/day/animal, respectively, in the juvenile trial (Fig. 1). Animals on the 4% protein diet were unable to compensate for the low concentration of protein in the diet by increased consumption. Average food consumption per gram of body weight (expressed as mean intake/mean body weight) in the juvenile trial was slightly higher for the 4% diet group but was not statistically different ( $P = 0.12$ ) from the 16% group (Fig. 1). Cotton rats receiving a 4% crude protein diet were unable to support normal body growth but did maintain their initial body weight in all three trials indicating an adequate caloric intake (Table 2). Development was normal in cotton rats receiving the 16% protein diet.

No significant ( $P > 0.10$ ) difference in the

TABLE 2. Experimental conditions and body weight changes in three protein (4% versus 16% crude protein, isocaloric diets) feeding trials using weanling, juvenile, and subadult cotton rats (*Sigmodon hispidus*).

Parameter	Dietary protein (%)	Weanling trial	Juvenile trial	Subadult trial
Sample size	4	21	10	24
	16	20	12	21
Age at onset	both diets	18 days	5 wk	8 wk
Trial duration	both diets	3 wk	6 wk	6 wk
Initial body weight	4	37.2 ± 0.9	32.6 ± 2.1	81.3 ± 3.2
	16	36.8 ± 1.3	33.9 ± 1.5	84.3 ± 3.1
Final body weight	4	38.8 ± 1.2	32.1 ± 2.2	84.7 ± 5.4
	16	67.2 ± 2.0	81.7 ± 2.4	121.1 ± 4.4

number of Peyer's patches in the small intestine of weanling, juvenile or subadult cotton rats was observed. Weight of total dissectable Peyer's patch tissue was influenced by diet, but dietary effects were inconsistent among experimental trials. Average total weight of Peyer's patches did not differ significantly ( $P > 0.10$ ) between diets for weanling cotton rats. However, total tissue weights for animals receiving the 4% protein diet were significantly ( $P < 0.02$ ) lower in the juvenile trial and greater in the subadult trial compared to 16% protein groups (Fig. 2). Average weights of individual Peyer's patches were largely unaffected by dietary protein restriction, although weights tended to be greater among subadults on low quality than high quality diets (Fig. 3).

Expressed relative to body weight (mg/g), Peyer's patches contributed a significantly greater ( $P < 0.001$ ) proportion of weight to total

body weight in the 4% protein group than in the 16% protein group for all three trials (Fig. 4). Relative weights of Peyer's patch tissue averaged 84 to 95% more in 4% than 16% protein diet groups. Relative weights also were greater among weanling than subadult and adult age classes, suggesting early development of these structures relative to total body mass.

DISCUSSION

The GALT system of the cotton rat is basically comprised of four to 13 Peyer's patches in the small intestine, a prominent Peyer's patch-like cecal patch, and numerous solitary lymphoid follicles throughout the large intestine. These intestinal lymphoid tissues share a similar gross morphology, and probably share many functional similarities as in other rodent species (Waksman and Ozer, 1976).

The major developmental changes from

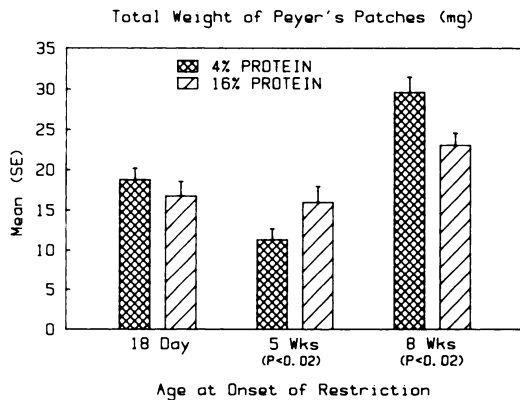


FIGURE 2. Total weight (mean ± SE) of dissectable Peyer's patch tissues from the small intestine of cotton rats fed isocaloric diets containing 4% or 16% protein. Weanling (18-days-old at onset), juvenile (5-wk-old at onset), and subadult (8-wk-old at onset) animals were fed experimental diets for 3, 6, and 6 wk, respectively.

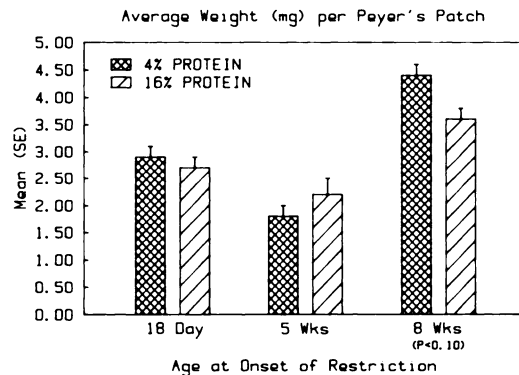


FIGURE 3. Average weight (mean ± SE) of individual Peyer's patches from the small intestine of weanling, juvenile, and subadult cotton rats fed isocaloric diets containing 4% or 16% protein.

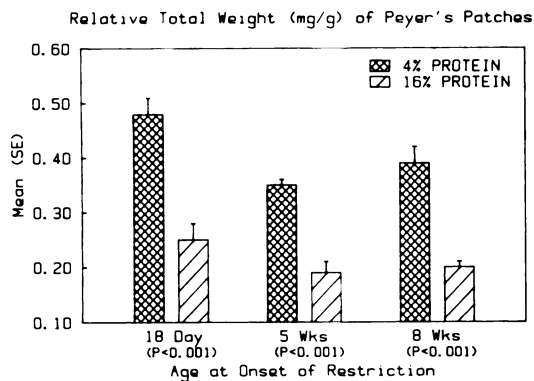


FIGURE 4. Relative (mg/g body weight) total weight (mean  $\pm$  SE) of dissectable Peyer's patch tissues from the small intestine of weanling, juvenile, and subadult cotton rats fed isocaloric diets containing 4% or 16% protein.

juvenile (our youngest cotton rat in this study was 18 days of age) to adult age classes that we observed occurred primarily with size (surface area) of lymphoid aggregates, especially Peyer's and cecal patches. Of these, Peyer's patches reached a maximum size at an earlier age than the cecal lymphoid patch. Although we found no evidence that the number of small intestinal or cecal lymphoid aggregates changed with age (from weaning to maturity), this was not the case in the large intestine of cotton rats. Both the number of visible lymphoid aggregates and solitary follicles increased from postweaning to maturity. There appears to be no correlation between the number of Peyer's patches and age or sex in other rodent species (Richter and Hall, 1947).

There were several noteworthy differences between the GALT system of cotton rats and other small mammals. Although the distribution of Peyer's patches appears to be remarkably similar to albino and wild rats (Hummell, 1935; Richter and Hall, 1947; Hummell, 1966), laboratory strains of mice (Kelsall, 1946), rabbits (Perey et al., 1970), and even sheep (Reynolds and Morris, 1983), substantial differences exist among species with respect to number of patches. A large ileocecal and small proximal duodenal Peyer's patch occurs in both

cotton rats and albino rats (Hummell, 1935), as well as other species (Perey et al., 1970; Reynolds and Morris, 1983). However, the total number of Peyer's patches varies from 18 to 26 in the albino rat (Hummell, 1935) and as high as 25 to 40 in sheep (Reynolds and Morris, 1983). A comparison of Peyer's patches in wild and domestic Norway rats (*Rattus norvegicus*) (Richter and Hall, 1947) revealed significant differences in number of patches per rat, ranging from nine to 23 (mean = 16) in wild rats and 13 to 26 (mean = 19) in domestics. Peyer's patches have also been shown to differ among strains of laboratory mice (Kelsall, 1946).

The single lymphoid cecal patch observed in the cotton rat appears to be common among all rodents (Takeuchi, 1986) and is probably homologous to the rabbit appendix (Waksman et al., 1973). Similar to Peyer's patches, the cecal patch was consistently present and grossly visible from the serosal surface of the cecum in cotton rats. Solitary lymphoid follicles were only occasionally present in the cecum. Considerable differences also exist between cotton rats and other rodent species in the distribution and number of lymphoid tissues in the large intestine (Hummell, 1935). Cotton rats possess very few lymphoid aggregates, and no patches, relative to the number of solitary follicles which have a diffuse pattern of distribution throughout the large intestine.

The consequences of consuming diets containing low concentrations of protein on development of lymphoid tissues have been examined in laboratory animals by a number of investigators (Gershwin et al., 1985). Decreased weights for spleen, thymus, and mesenteric lymph nodes are commonly reported in laboratory mice fed 4% protein diets (Kenney et al., 1968; Bell et al., 1976). Lopez et al. (1985) observed that Peyer's patches of juvenile laboratory rats suffer severe reductions in weight when fed protein-free diets for 15 days. Smythe et al. (1971) observed reductions in the size of a variety of lymphoid tissues in the gut

during malnutrition in humans, including tonsils, adenoids, Peyer's patches, appendix, and lymphoid aggregates in the colon. Reductions in the size and cellularity of lymphoid tissues reflect the impairment in growth that results from a lack of protein for cell division (Bell et al., 1976).

Our results suggest that development of peripheral lymphoid tissues in wild cotton rats may be somewhat more resistant to protein deficiencies than other tissues (i.e., body mass) and species. Responses (decreased weight of Peyer's patches) of juvenile cotton rats to low protein-containing diets were in agreement with observations reported for laboratory animals (Lopez et al., 1985). Responses in this age group may reflect a highly sensitive stage in the development of GALT. For example, mature germinal centers do not develop in Peyer's patches of laboratory mice before 4–5 wk of age (Ferguson and Parrott, 1972). In contrast, absolute weights of Peyer's patches were greater among animals fed a 4% protein diet than 16% protein diet in the subadult trial. Relative weights of Peyer's patch tissue for low protein-fed cotton rats in all age classes exceeded those fed high protein diets.

Stability, or increases as in the subadult trial, in weight of Peyer's patch tissues could also reflect an elevated response to antigenic stimulation in cotton rats fed a diet containing a low concentration of protein; however, we have no evidence to support such a mechanism in this study. The GALT matures under the influence of enteric flora (Carter and Pollard, 1971). Germ-free mice exposed to antigenic stimulation show increased development of Peyer's patches in the gut (Pollard and Sharon, 1970). In comparison, isolation of lymphoid tissues such as appendix from antigenic stimulation in the gut results in acute shrinkage due to disappearance of germinal centers (Blythman and Waksman, 1973). Decreased immunocompetence in 4% protein-fed cotton rats may have resulted in increased antigenic stimulation in the gut. Although lymphoid or-

gan hypertrophy is a common response to antigenic challenge in healthy animals, Bell et al. (1976) observed that this response (popliteal lymph node) will diminish in mice fed a low protein diet.

The dramatic fluctuations in weight of the thymus gland in response to nutritional conditions has led to the use of this measurement as an indicator of condition in white-tailed deer (*Odocoileus virginianus*) (Ozoga and Verme, 1978). Unfortunately, the use of thymus glands in many rodent species is limited as this lymphoid tissue will atrophy at a very early age. Alternatively, relative weight of Peyer's patch tissues may prove to be a useful indicator of nutritional status in cotton rats for all age classes.

#### ACKNOWLEDGMENTS

This study was supported in part by grants from the National Science Foundation (BSR 8657043), The Kerr Foundation, and the Department of Zoology, Oklahoma State University. We greatly appreciate the technical expertise of N. Hoshaw in the laboratory.

#### LITERATURE CITED

- ASQUITH, P. 1979. Immunology of the gastrointestinal tract. Churchill Livingstone Co., New York, New York, 348 pp.
- BATZLI, G. O. 1985. Nutrition. In *Biology of New World Microtus*, R. H. Tamarin (ed.). Special Publication No. 8, The American Society of Mammalogists, Lawrence, Kansas, pp. 779–811.
- BOURNE, F. J. 1981. The mucosal immune system. *Current Topics in Veterinary Medicine Animal Science* 12: 1–24.
- BELL, R. G., L. A. HAZELL, AND P. PRICE. 1976. Influence of dietary protein restriction on immune competence II. Effect on lymphoid tissue. *Clinical and Experimental Immunology* 26: 314–326.
- BLYTHMAN, H. E., AND B. H. WAKSMAN. 1973. Effect of irradiation and appendicostomy on appendix structure and responses of appendix cells to mitogens. *Journal of Immunology* 111: 171–182.
- CARTER, P. B., AND M. POLLARD. 1971. Host responses to normal microbial flora in germ-free mice. *Journal of the Reticuloendothelial Society* 9: 580–586.
- CHANDRA, R. K. 1983. Mucosal immune responses in malnutrition. *Annals of the New York Academy of Sciences* 409: 345–351.



- CHAPMAN, H. A., J. S. JOHNSON, AND M. D. COOPER. 1974. Ontogeny of Peyer's patches and immunoglobulin-containing cells in pigs. *Journal of Immunology* 112: 555-563.
- COLE, G. J., AND B. MORRIS. 1973. The lymphoid apparatus of the sheep: Its growth, development and significance in immunologic reaction. *Advances in Veterinary Science and Comparative Medicine* 17: 225-263.
- COOPER, G. N., J. C. THONARD, R. L. CROSBY, AND M. H. DALBOW. 1968. Immunological responses in rats following antigenic stimulation of Peyer's patches. II. Histological changes in germ-free animals. *Australian Journal of Experimental Biology and Medical Science* 46: 407-414.
- CORNES, J. S. 1965. Number, size and distribution of Peyer's patches in the human small intestine. *Gut* 6: 225-229.
- CRAIG, S. W., AND J. J. CEBRA. 1971. Peyer's patches: An enriched source of precursors for IgA-producing immunocytes in the rabbit. *Journal of Experimental Medicine* 134: 188-200.
- FAULK, W. P., J. N. MCCORMICK, J. R. GOODMAN, AND J. M. YOFFEY. 1971. Peyer's patches: Morphologic studies. *Cellular Immunology* 1: 500-520.
- FERGUSON, A., AND D. M. V. PARROTT. 1972. The effect of antigen deprivation on thymus-dependent and thymus-independent lymphocytes in the small intestine of the mouse. *Clinical and Experimental Immunology* 12: 477-483.
- GERSHWIN, M. E., R. S. BEACH, AND L. S. HURLEY. 1985. *Nutrition and immunity*. Academic Press, New York, New York, 417 pp.
- GOLDSTINE, S. N., V. MANICKAVEL, AND N. COHEN. 1975. Phylogeny of gut-associated lymphoid tissue. *American Zoologist* 15: 107-118.
- HUMMELL, K. P. 1935. The structure and development of the lymphatic tissue in the intestine of the albino rat. *American Journal of Anatomy* 57: 351-383.
- . 1966. Anatomy. In *The biology of the laboratory mice*, E. L. Green (ed.). McGraw-Hill, New York, New York, pp. 247-307.
- KAGNOFF, M. F. 1978. Effects of antigen-feeding on intestinal and systemic immune responses. I. Priming of precursor cytotoxic T cells by antigen feeding. *Journal of Immunology* 120: 395-399.
- KAWANISHI, H., L. E. SALTZMAN, AND W. STROBER. 1983. Mechanisms regulating IgA class-specific immunoglobulin production in murine gut-associated lymphoid tissues. I. T cells derived from Peyer's patches that switch sIgM B cells to sIgA B cells in vitro. *Journal of Experimental Medicine* 157: 433-450.
- KELSALL, M. A. 1946. Number of Peyer's patches in mice belonging to high and low mammary tumor strains. *Proceedings of the Society for Experimental Biology and Medicine* 61: 423-424.
- KENNEY, M. A., C. E. RODERUCK, L. ARNRICH, AND F. PIEDAD. 1968. Effect of protein deficiency on the spleen and antibody formation in rats. *Journal of Nutrition* 95: 173-179.
- KEREN, D. F. 1978. The role of Peyer's patches in the local immune response of rabbit ileum to live bacteria. *Journal of Immunology* 120: 1892-1896.
- LANGMAN, J. M., N. L. FAZZALARI, R. ROWLAND, AND B. VERNON-ROBERTS. 1986. Lymphoid aggregates in the guinea pig large bowel: Development of quantification techniques for number, volume and distribution. *Australian Journal of Experimental Biology and Medical Science* 64: 11-17.
- LOPEZ, M. C., M. E. ROUX, S. H. LANGINI, M. E. RIO, AND J. C. SANAHUJA. 1985. Effect of severe protein deficiency and refeeding on precursor IgA-cells in Peyer's patches of growing rats. *Nutrition Reports International* 32: 667-674.
- MCGEE, D. W., AND D. N. MCMURRAY. 1988. The effect of protein malnutrition on the IgA immune response in mice. *Immunology* 63: 25-29.
- OZOGA, J. J., AND L. J. VERME. 1978. The thymus gland as a indicator of nutritional status in deer. *The Journal of Wildlife Management* 42: 791-798.
- PEREY, D. Y. E., D. FROMMEL, R. HONG, AND R. A. GOOD. 1970. The mammalian homologue of the avian bursa of Fabricius. *Laboratory Investigation* 22: 212-227.
- POLLARD, M., AND N. SHARON. 1970. Responses of Peyer's patches in germ-free mice to antigenic stimulation. *Infection and Immunity* 2: 96-100.
- REDDY, B., N. RAGHURAMULU, AND C. BASKARAM. 1976. Secretory IgA in protein-calorie malnutrition. *Archives of Disease in Childhood* 51: 871-874.
- REYNOLDS, J. D., AND B. MORRIS. 1983. The evolution and involution of Peyer's patches in fetal and postnatal sheep. *European Journal of Immunology* 13: 627-635.
- RICHTER, C. P., AND C. E. HALL. 1947. Comparison of intestinal lengths and Peyer's patches in wild and domestic Norway and wild Alexandrine rats. *Proceedings of the Society for Experimental Biology and Medicine* 66: 561-566.
- SMYTHE, P. M., G. G. BRETON-STILES, J. J. GRACE, A. MAFOYANE, M. SCHONLAND, H. M. COOVEDIA, W. E. LOENING, M. A. PARENT, AND G. H. VOS. 1971. Thymolymphatic deficiency and depression of cell-mediated immunity in protein-calorie malnutrition. *Lancet* 2: 939-943.
- STAFFORD, S. R., AND J. J. STOUT. 1983. Dispersal of the cotton rat, *Sigmodon hispidus*. *Journal of Mammalogy* 64: 210-217.
- TAKEUCHI, A. 1986. Morphology of the gastro-intestinal tract, including the gut associated lymphoid tissue, related to microbiological status. In *Laboratory animal models for domestic animal production*, E. J. Ruitenberg and P. W. J. Peters (eds.). Elsevier, Amsterdam, pp. 119-142.

- WAKSMAN, B. H., H. OZER, AND H. E. BLYTHMAN. 1973. Appendix and M-antibody formation. VI. The functional anatomy of the rabbit appendix. *Laboratory Investigation* 28: 614-626.
- , AND H. OZER. 1976. Specialized amplification elements in the immune system: The role of nodular lymphoid organs in the mucus membranes. *Progress in Allergy* 21: 1-113.
- WHITE, T. C. R. 1978. The importance of a relative shortage of food in animal ecology. *Oecologia* 33: 71-86.
- WHITEHEAD, R., AND J. M. SKINNER. 1978. Morphology of the gut associated lymphoid system in health and disease: A review. *Pathology* 10: 3-16.
- WILKINSON, L. 1989. SYSTAT: The system for statistics. SYSTAT, Inc., Evanston, Illinois, 822 pp.

*Received for publication 21 December 1990.*