

## **Pneumocystis carinii in Corticosteroid-Treated Voles: A Comparison of Three Different Staining Methods**

Authors: Sukura, A., Laakkonen, J., Soveri, T., Henttonen, H., and Lindberg, L.-A.

Source: Journal of Wildlife Diseases, 28(1) : 121-124

Published By: Wildlife Disease Association

URL: <https://doi.org/10.7589/0090-3558-28.1.121>

---

BioOne Complete ([complete.BioOne.org](https://complete.BioOne.org)) is a full-text database of 200 subscribed and open-access titles in the biological, ecological, and environmental sciences published by nonprofit societies, associations, museums, institutions, and presses.

Your use of this PDF, the BioOne Complete website, and all posted and associated content indicates your acceptance of BioOne's Terms of Use, available at [www.bioone.org/terms-of-use](https://www.bioone.org/terms-of-use).

Usage of BioOne Complete content is strictly limited to personal, educational, and non - commercial use. Commercial inquiries or rights and permissions requests should be directed to the individual publisher as copyright holder.

---

BioOne sees sustainable scholarly publishing as an inherently collaborative enterprise connecting authors, nonprofit publishers, academic institutions, research libraries, and research funders in the common goal of maximizing access to critical research.

## ***Pneumocystis carinii* in Corticosteroid-Treated Voles: A Comparison of Three Different Staining Methods**

**A. Sukura,<sup>1</sup> J. Laakkonen,<sup>1</sup> T. Soveri,<sup>1</sup> H. Henttonen,<sup>2</sup> and L.-A. Lindberg,<sup>1</sup>** <sup>1</sup> Department of Anatomy, College of Veterinary Medicine, P.O. Box 6, 00581 Helsinki 58, Finland; <sup>2</sup> Department of Forest Protection, Finnish Forest Research Institute, P.O. Box 18, SF-01301 Vantaa, Finland

**ABSTRACT:** *Pneumocystis carinii* (PC) is an opportunistic pathogen which causes clinical disease in immunocompromised hosts. Three different staining protocols were employed to detect this organism in lung samples of corticosteroid treated voles in order to discover a suitable method for large-scale screening. The procedures employed were: Grocott's methenamine silver (GMS)-stained paraffin sections, toluidine blue O-stained impression smears, and methenamine-silver-stained frozen sections. GMS-stained paraffin sections were relatively easy to interpret and gave more positive results than the other methods. It seemed to be the satisfactory method for large-scale population analyses. An unexpected result was that methylprednisolone treatment did not induce in voles a similarly fatal pneumocystosis infection as occurred in rats. All infections found in voles were mild. This might be due to species-dependent differences in metabolizing methylprednisolone.

**Key words:** *Pneumocystis carinii*, immunosuppression, corticosteroid, *Clethrionomys* spp., Grocott's methenamine silver, Toluidine blue O, voles.

In many regions, microtine rodents (voles and lemmings) undergo wide population fluctuations, often called cycles. These fluctuations are especially prominent in northern Fennoscandia (Henttonen et al., 1987; Hansson and Henttonen, 1988). No general agreement yet exists on the causes of the population crashes in the cycles, even though predation (Hansson and Henttonen, 1988; Korpimäki and Norrdahl, 1989) and diseases, probably interactive with nutritive factors (Hansson and Henttonen, 1988) have been recently emphasized. *Pneumocystis carinii* is a well known opportunistic pathogen in immunological disorders. The epidemiology of pneumocystosis as a possible indicator of immunosuppression, or even as the cause of death, could therefore aid in differentiating among the factors mentioned above. In addition, in Central Europe, human ep-

idemics of *P. carinii* have been reported to coincide with high-density phases of vole populations in the 1960's (Kucera, 1967). To get basic data on the occurrence of *P. carinii* in voles, we used in this study similar methylprednisolone immunosuppression in voles as has been done in experimental works using rats.

The most specific and also very sensitive methods for identification of *P. carinii* are immunohistochemical (Sundberg et al., 1989; Elvin et al., 1988; Midgley et al., 1989), but *P. carinii* obtained from different species are not necessarily antigenically identical (Graves, 1989). Therefore, conventional histochemical techniques are also needed until the specificity of the antibodies to the organism from studied host species has been checked. None of the histochemical stainings used are specific to *P. carinii*; a variety of fungi and protozoa could stain as well, and morphologically they may be confusingly alike (Sundberg et al., 1989).

In this study, Grocott's methenamine silver (GMS)-stained paraffin sections, toluidine blue O-stained impression smears, and methenamine-silver-stained frozen sections are compared for their suitability for population samples screening.

Twenty-six bank voles (*Clethrionomys glareolus*) (11 males and 15 females), and 27 grey-sided voles (*Clethrionomys rufocanus*) (14 males and 13 females) were used in the experiment. Bank voles were trapped at Heinola (26°02'N, 61°14'E) in southern Finland in January 1989. Grey-sided voles were raised in the animal stables of the Department of Zoology, University of Helsinki (Helsinki, Finland), where the colony, originally from Pallasjärvi, Lapland (68°03'N, 24°09'E), has been maintained for several years. In our study

the animals were housed in ordinary open-top cages with one male and female together when available. Different species were kept in separate buildings.

At the beginning of the experiment animals were divided into five groups for each species. After an acclimatization period of 20 days animals were put on a 6% protein diet and placed on the immunosuppression regimen of 0.4 mg of methylprednisolone injected subcutaneously once a week (DepoMedrol®, The Upjohn Company, Kalamazoo, Michigan, 49001, USA). Water was provided ad libitum, and the voles were regularly weighed. After 0, 1, 3, 8 and 20 weeks following initiation of immunosuppression, the animals were euthanized with ether. If an animal died spontaneously it was considered as being a member of the previous time-group.

Impression smears were prepared by touching a section of the left caudal lobe of the lung to a microscope slide. The imprints were air-dried, fixed in acetone-methanol (1:1) and stained with toluidine blue O (Settnes and Larsen, 1979).

Samples for frozen sections were taken close to the site of origin of the touch imprint. Sections approximately 10  $\mu\text{m}$  thick were cut and stained, using a modification of methenamine-silver-staining with no counterstaining.

For the paraffin method a lung sample from each left lobe was fixed in neutral buffered formalin (10%). Fixed tissue was dehydrated, embedded in paraffin, and sectioned at 5  $\mu\text{m}$  and then stained with GMS according to Grocott (1955) with 1 hr incubation time in methenamine-silver solution. The slides were coded and studied blind.

A sample was considered *P. carinii*-positive if at least two *P. carinii* cysts were found. An animal was positive in the parallel test result if any of the employed stainings of its tissues were positive. If all stainings were positive, the animal was positive also in the series result. Efficiency of each staining was determined by using the parallel result as the reference.

TABLE 1. Number of positive voles in different stainings and time groups, 1 and 3, and 8 and 20 weeks pooled together.

	imp*	cyro*	GMS*	paral- lel*	series*	n
	pos	pos	pos	pos	pos	
0 week						
C. gla*	0	0	0	0	0	4
C. ruf*	1	0	3	3	0	6
subtotal	1	0	3	3	0	10
1 + 3 weeks						
C. gla	2	1	2	2	1	12
C. ruf	1	1	3	5	0	12
subtotal	3	2	5	7	1	24
8 + 20 weeks						
C. gla	6	3	4	6	3	10
C. ruf	2	2	2	3	1	9
subtotal	8	5	6	9	4	19
Total						
C. gla	8	4	6	8	4	26
C. ruf	4	3	8	11	1	27
Total	12	7	14	19	5	53

\* imp, toluidine blue O stained touch imprint; cryo, methenamine silver stained frozen section; GMS, Grocott's methenamine silver stained paraffin section; Parallel, an animal had at least one positive staining result; series, an animal had the positive result in all three stainings; n, number of studied animals in each group; C. gla, *Clethrionomys glareolus*; C. ruf, *Clethrionomys rufocanus*.

All positive voles had mild infections, with no severe or lethal pneumocystosis being found. In the positive samples only a few cysts could be seen on individual microscopic fields. No interspecific difference appeared (pooled data with parallel results,  $\chi^2 = 0.57$ ,  $P = 0.45$ ), nor any clear trends during the course of the experiment in *P. carinii* prevalence (species combined data with parallel results, weeks 1 + 3 against weeks 8 + 20,  $\chi^2 = 1.5$ ,  $P = 0.22$ ) (Table 1). Thus, corticosteroid treatment failed to cause fatal or severe pneumocystosis in voles.

Because neither of the species was in contact with other animals in the laboratory, it is therefore likely that both bank voles and grey-sided voles originated from populations endemically infected with *P. carinii*.

GMS-stained paraffin sections showed

positive results most frequently (74% of the positive parallel results). The toluidine blue O-stained touch imprint method was the next most frequently positive (63% of the parallel results), whereas methenamine-silver-staining of frozen sections was clearly less efficient (37%) than the two other procedures. Paraffin and frozen sections could be examined equally rapidly, but the toluidine blue O-stained touch imprint was more time-consuming because of a larger sample area. In contrast, toluidine blue was the most rapid staining procedure.

GMS-staining is time-consuming, compared to many other staining methods (Moas et al., 1989; Woosley, 1989). However, the major advantage of the GMS method is its outstanding contrast between *P. carinii* and the host tissue, which makes identification of cysts easier and, therefore, large-scale screening relatively fast. A practical feature is that routine formalin-fixed material from the field can also be used for *P. carinii* analyses.

In all groups, animals lost weight in the beginning of the experimental period (Fig. 1). Compared to weight-losses in rats on a normal commercial diet and on methylprednisolone immunosuppression (Sukura et al., 1991), relative weight-loss in our voles was less impressive. Furthermore, the voles partly recovered from their weight-loss in 20 weeks. *Clethrionomys* voles are very sensitive to increasing daylight (Tähkä et al., 1984), and therefore weight-gain could be due to increasing light in spring when these animals start to mature. The smaller weight-loss in voles when compared to rats could be due to the catabolic effect of methylprednisolone on voles being less than on rats.

The most unexpected result of our study was the finding that methylprednisolone treatment, which induces pneumocystosis-infections in rodents of other families (rats and mouse) (Hughes, 1989; Walzer et al., 1989), failed to induce severe pneumocystosis in our voles. Bartlett et al. (1987) suggest that immunosuppression of rats from a virus-free colony did not induce

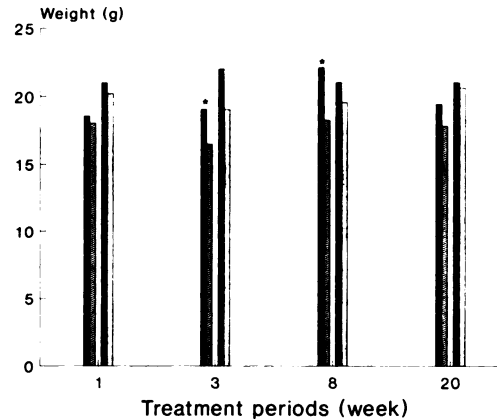


FIGURE 1. Weight dynamics of voles infected with *Pneumocystis carinii* in different treatment groups. Average weight of the *Clethrionomys glareolus* in the beginning (■) and at the end (▨) of each treatment period. Average weight of the *C. rufocanus* in the beginning (□) and at the end (■) of each treatment period. (\*) Difference in weight is statistically significant (paired *t*-test,  $P < 0.05$ ).

pneumocystosis, but in their study none of the animals showed any detectable organisms, probably due to the absence of the infective forms in the laboratory environment. In our vole material, light infections occurred regularly, but we found neither clinical disease nor lungs full of cysts, as in immunosuppressed rats. The reason for this difference between murid and microtine rodents could be a weaker immunosuppressive effect of methylprednisolone on voles than on rats, perhaps due to differences in metabolizing methylprednisolone. Specific measurements of the effects of methylprednisolone on the immunostatus of voles, as well as investigations on the pharmacology of the compound in voles should be carried out.

We acknowledge the comments on the manuscript by professor Jaakko Tuomi and Pekka Huhtanen for his help in preparing the low-protein diet. This study was supported by the College of Veterinary Medicine, Helsinki, Finland, and Research Council for Natural Sciences in Finland.

#### LITERATURE CITED

- BARTLETT, M. S., M. M. DURKIN, M. A. JAY, S. F. QUEENER, AND J. W. SMITH. 1987. Sources of

- rats free of latent *Pneumocystis carinii*. *Journal of Clinical Microbiology* 25: 1794–1795.
- ELVIN, K. M., A. BJÖRKMAN, E. LINDER, N. HEURLIN, AND A. HJERPE. 1988. *Pneumocystis carinii* pneumonia: Detection of parasites in sputum and bronchoalveolar lavage fluid by monoclonal antibodies. *British Medical Journal* 297: 381–384.
- GRAVES, D. C. 1989. Immunological Studies of *Pneumocystis carinii*. *Journal of Protozoology* 36: 60–69.
- GROCOTT, R. G. 1955. A stain for fungi in tissue sections and smears. *American Journal of Clinical Pathology* 25: 975–979.
- HANSSON, L., AND H. HENTTONEN. 1988. Rodent dynamics as community processes. *Trends in Ecology and Evolution* 3: 195–200.
- HENTTONEN, H., T. OKSANEN, A. JORTIKKA, AND V. HAUKISALMI. 1987. How much do weasles shape microtine cycles in the northern Fennoscandian taiga? *Oikos* 50: 353–365.
- HUGHES, W. T. 1989. Animal models for *Pneumocystis carinii* pneumonia. *Journal of Protozoology* 36: 41–45.
- KORPIMÄKI, E., AND K. NORRDAHL. 1989. Avian predation on mustelids in Europe 2: Impact on small mustelid and microtine dynamics—A hypothesis. *Oikos* 55: 273–276.
- KUCERA, K. 1967. La pneumocystose en tant qu'anthropozoonose. *Annales de Parasitologie* 5: 465–482.
- MIDGLEY, J., P. PARSONS, T. R. LEIGH, J. V. COLLINS, D. C. SHANSON, O. A. N. HUSAIN, AND J. N. HARCOURT-WEBSTER. 1989. Increased sensitivity of immunofluorescence for detection of *Pneumocystis carinii*. *The Lancet* 30: 1523.
- MOAS, C. M., D. A. EVANS, J. STEIN-STREILEIN, P. GANJEL, AND A. E. PITCHENIK. 1989. Cresyl violet: A rapid, simple, easily interpretable stain for detecting *Pneumocystis carinii* in sputum. *Southern Medical Journal* 82: 957–959.
- SETTNES, O. P., AND P.-E. LARSEN. 1979. Inhibition of toluidine blue O stain for *Pneumocystis carinii* by additives in the diethyl ether. *American Journal of Clinical Pathology* 72: 493–494.
- SUKURA, A., T. SOVERI, AND L.-A. LINDBERG. 1991. Superiority of methylprednisolone over dexamethasone for induction of *Pneumocystis carinii* infection in rats. *Journal of Clinical Microbiology* 29: In press.
- SUNDBERG, J. P., T. BURNSTEIN, L. D. SHULZ, AND H. BEDIGIAN. 1989. Identification of *Pneumocystis carinii* in immunodeficient mice. *Laboratory Animal Science* 39: 213–218.
- TÄHKÄ, K., H. WALLGREN, AND M. VUORINEN. 1984. Endocrine aspects of population regulation in the genus *Clethrionomys*. *Memorandum Societas Fauna et Flora Fennica* 60: 93–106.
- WALZER, P. D., C. K. KIM, M. J. LINKE, C. L. POGUE, M. J. HUERKAMP, C. E. CHRISP, A. V. LERRO, S. K. WIXSON, E. HALL, AND L. D. SHULTZ. 1989. Outbreaks of *Pneumocystis carinii* pneumonia in colonies of immunodeficient mice. *Infection and Immunity* 57: 62–70.
- WOOSLEY, J. T. 1989. Rapid and simple metachromatic stain for *Pneumocystis carinii*. *Southern Medical Journal* 82: 245–246.

Received for publication 1 February 1991.