

PARASITISM OF WILD GOULDIAN FINCHES (ERYTHRURA GOULDIAE) BY THE AIR-SAC MITE STERNOSTOMA TRACHEACOLUM

Authors: Tidemann, Sonia C., McOrist, Steven, Woinarski, J. C. Z., and Freeland, W. J.

Source: Journal of Wildlife Diseases, 28(1) : 80-84

Published By: Wildlife Disease Association

URL: <https://doi.org/10.7589/0090-3558-28.1.80>

BioOne Complete (complete.BioOne.org) is a full-text database of 200 subscribed and open-access titles in the biological, ecological, and environmental sciences published by nonprofit societies, associations, museums, institutions, and presses.

Your use of this PDF, the BioOne Complete website, and all posted and associated content indicates your acceptance of BioOne's Terms of Use, available at www.bioone.org/terms-of-use.

Usage of BioOne Complete content is strictly limited to personal, educational, and non - commercial use. Commercial inquiries or rights and permissions requests should be directed to the individual publisher as copyright holder.

BioOne sees sustainable scholarly publishing as an inherently collaborative enterprise connecting authors, nonprofit publishers, academic institutions, research libraries, and research funders in the common goal of maximizing access to critical research.

PARASITISM OF WILD GOULDIAN FINCHES (*ERYTHRURA GOULDIAE*) BY THE AIR-SAC MITE *STERNOSTOMA TRACHEACOLUM*

Sonia C. Tidemann,¹ Steven McOrist,² J. C. Z. Woinarski,¹ and W. J. Freeland¹

¹ Conservation Commission of the Northern Territory, P.O. Box 496, Palmerston, Northern Territory 0831, Australia.

² Veterinary Research Institute, Park Drive, Parkville, Victoria 3052, Australia

ABSTRACT: Sixty-two percent of 26 wild caught Gouldian finches (*Erythrura gouldiae*) were infected with *Sternostoma tracheacolum*, a parasitic rhinonyssid mite. The intensity of infection was higher in adult finches than juveniles, and higher in juvenile females than juvenile males. Histopathological investigation of wild Gouldian Finches revealed bronchopneumonia and air sacculitis associated with mite infection. Although this mite may not have contributed to the decline of Gouldian finch populations in the wild during the past 20 yr, it may be suppressing the return of the finch to its former status.

Key words: Gouldian finch, respiratory parasite, air-sac mite, *Erythrura gouldiae*, *Sternostoma tracheacolum*, disease, air sacculitis.

INTRODUCTION

Gouldian finches (*Erythrura gouldiae*) are distributed across tropical northern Australia from the Kimberleys, Western Australia to northwestern Queensland at latitudes of about 15 to 17°S. Measures of abundance from trapping returns provided by commercial trappers (Western Australian Department of Conservation and Land Management, Como, Western Australia 6152, Australia) indicate that, during the years of maximal catch (1972-73) until 1982 when trapping of Gouldian finches became illegal, the numbers caught decreased by about 70%. During the same period there was an increase in numbers of the sympatric long-tailed finch (*Poephila acuticauda*) (Fig. 1). Anecdotal reports (e.g., Heumann, 1926) and surveys (Blakers et al., 1984) also indicate a substantial decline in numbers of the Gouldian finch. Legal trapping, changes in food availability or loss of preferred habitat during this century are unlikely to have caused the decline in the Gouldian finch. Cooccurring finch species such as the long-tailed finch, Zebra finch (*Taeniopygia guttata*), double-barred finch (*T. bichenovii*), and masked finch (*P. personata*) possibly are subject to similar pressures and have not declined.

Aviary populations of Gouldian finches

are susceptible to infection with a rhinonyssid mite (*Sternostoma tracheacolum*) (Murray, 1966). Infected individuals show signs of respiratory distress, including a characteristic "clicking" sneeze or cough, difficulty in breathing and poor tolerance of exercise. Affected birds may live for many months or die quickly, depending on the severity of the infection.

The aim of this study was to determine (1) the prevalence and intensity of infection of *S. tracheacolum* in wild populations of Gouldian finches compared with those in other species of finches in northern Australia and those in other native birds; (2) the date of earliest occurrence of *S. tracheacolum* in wild birds in Australia; and (3) the pathological effect of *S. tracheacolum* on individuals.

METHODS

We dissected 380 individuals of eight finch and mannikin species from 13 sites across the Northern Territory and Western Australia (14°00' to 16°05'S, 128°05' to 132°05'E). Specimens of the Gouldian finch were collected from eight sites within this range (Fig. 2). As well, 240 individuals of another 78 genera (32 families) were examined. Birds were dissected from the ventral surface, and the body cavity examined using a binocular microscope (10 to 64×). About 10% were fresh road or accident kills while the others were collected by mist nets (55%) or shot for museum specimens (32%) or airport clearance (2%).

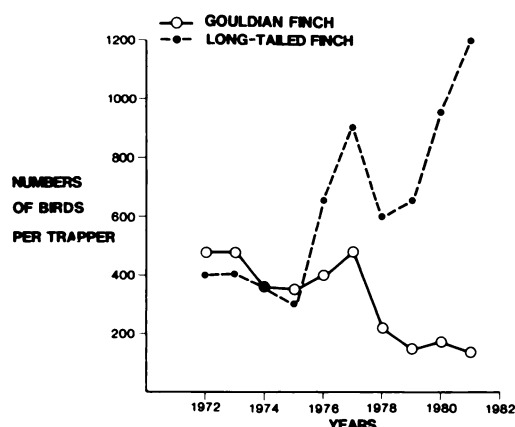


FIGURE 1. Numbers of Gouldian and long-tailed finches caught per finch trapper from 1972 to 1981 in Western Australia. (Courtesy of Department of Conservation and Land Management, Western Australia.)

An attempt was made to obtain spirit specimens of wild Gouldian finches from Australian, and 10 overseas, museums in which Australian avifauna are held.

Whenever *S. tracheacolum* was located in the air sacs, lungs or trachea we counted the numbers of mites, noted their distribution and searched all other organs. Scanning electron micrographs were taken of some mites to examine their relationship to the host tissue. A selection of mites was deposited in the Australian National Insect Collection (ANIC), CSIRO Division of Entomology, Canberra, ACT 2601, Australia; no accession numbers, refer to Tidemann Collection, 1991.

Portions of lung, trachea, spleen and kidney from 12 Gouldian and 15 long-tailed finches were fixed in 10% buffered formalin. Tissues were embedded in paraffin, sectioned and stained with haematoxylin and eosin. Histolog-

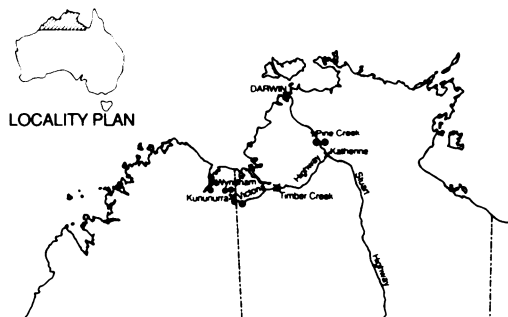


FIGURE 2. Locations (dots) of sites where air-sac mite has been located in Gouldian finches collected for necropsy, Northern Territory and Western Australia. Towns are marked with a cross for references.

ical examination was performed without knowledge of air-sac mite numbers or species of bird examined. Differences in intensity of infection were tested using Student's *t*-test.

RESULTS

Prevalence of *S. tracheacolum* infection was 62% ($n = 26$) in Gouldian finches, 13% in pictorella mannikins (*Heteromunia pectoralis*) ($n = 8$) and <1% in masked finches ($n = 118$). Intensity of mite infection ranged from 1 to 102 in Gouldian finches. Intensities in the only infected pictorella mannikin and masked finch were 1 and 11 mite(s), respectively. *Sternostoma tracheacolum* was not found in any other avian species (Table 1).

Intensity of infection differed significantly between adult ($\bar{x} = 31.8 \pm 12.8$) and subadult/juvenile Gouldian finches ($\bar{x} = 15.0 \pm 6.0$) ($t = -3.64$, $df = 23$, $P < 0.01$) (Table 1). Intensity of air-sac mite infection was not significantly different between adult males ($\bar{x} = 34.3 \pm 26.8$, $n = 3$) and females ($\bar{x} = 30.2 \pm 18.0$, $n = 5$) ($t < 2$, $df = 7$, $P > 0.1$). Subadult/juvenile females were more heavily infected ($\bar{x} = 19.5 \pm 7.6$, $n = 10$) than males in the same age class ($\bar{x} = 9.0 \pm 5.2$, $n = 7$) ($t = -1.99$, $df = 8$, $P < 0.06$) (Table 2). Distribution of air-sac mites in one infected Gouldian finch was not recorded. In the remaining fifteen infected, air-sac mites were distributed more widely throughout the respiratory system in subadult/juveniles than in adults (Table 2).

Mites were 0.2–0.3 mm wide, 0.4–0.6 mm long and dorso-ventrally flattened. Scanning electron micrographs indicated that individuals attached themselves by embedding their legs into connective tissue. A mucous coat, secreted by the host, covered most individuals. When mites were present in the trachea, they (plus their mucous coats) would have reduced the internal volume of the trachea.

Four (A–D) of the 12 Gouldian finches examined histologically had mites at necropsy. Birds A–C (one male and two females) had two to 23 mites in the trachea,

TABLE 1. Systematic list of native bird species dissected and in which *Sternostoma tracheacolum* was not present.

| Family | Number of species | Number of individuals |
|-------------------|-------------------|-----------------------|
| Procellariidae | 1 | 1 |
| Ardeidae | 1 | 1 |
| Plataleidae | 1 | 4 |
| Accipitridae | 6 | 15 |
| Anatidae | 1 | 1 |
| Rallidae | 2 | 2 |
| Burhinidae | 1 | 1 |
| Glaucolidae | 1 | 4 |
| Charadriidae | 1 | 1 |
| Columbidae | 10 | 21 |
| Psittacidae | 12 | 77 |
| Cuculidae | 2 | 3 |
| Strigidae | 2 | 6 |
| Podargidae | 1 | 10 |
| Caprimulgidae | 2 | 8 |
| Alcedinidae | 5 | 15 |
| Meropidae | 1 | 4 |
| Coraciidae | 1 | 2 |
| Hirundinidae | 1 | 1 |
| Campephagidae | 1 | 1 |
| Pachycephalidae | 3 | 5 |
| Sylviidae | 1 | 1 |
| Neosittidae | 1 | 2 |
| Meliphagidae | 8 | 32 |
| Zosteropidae | 1 | 1 |
| Ploceidae | 5 | 228 |
| Dicruridae | 1 | 3 |
| Ptilonorhynchidae | 2 | 3 |
| Corcoracidae | 1 | 1 |
| Grallinidae | 1 | 7 |
| Artamidae | 2 | 3 |
| Cracticidae | 3 | 3 |
| Corvidae | 1 | 1 |

10 to 25 in the anterior air sacs and three to five in the lungs. Bird D (an immature male) had only one mite in its right anterior air-sac. Grossly, three Gouldian finches (A–C) had partially opaque, thickened linings of the anterior air sacs and mild consolidation of the lungs.

Histologically, the lungs of birds A–C contained focal areas of bronchial dilatation with detritus, macrophages and lymphocytes in the lumen. The mucosa was infiltrated by macrophages, lymphocytes and fibrocytes. Portions of mites, giant cells and macrophages containing hemosiderin were evident. The air sacs were thickened

by oedema and infiltration of fibroblasts and lymphocytes. The trachea had moderate epithelial necrosis and lymphocyte and macrophage infiltration was apparent in the mucosa. These changes were not evident in bird D. Examination of spleen, liver and kidney tissues revealed no abnormalities.

None of the long-tailed finches examined histologically had air-sac mites or histological lesions. No whole specimens of Gouldian finches collected on early, historical expeditions were available from anywhere in the world. Hence, it was not possible to determine the earliest record of air-sac mites in the wild in Australia any earlier than this study.

DISCUSSION

This is the first time that air-sac mite *S. tracheacolum* has been reported from wild birds in Australia. Since its discovery in a captive canary (*Serinus canarius*) in 1947 (Lawrence, 1948), *S. tracheacolum* has been recorded from other captive birds as well as 20 species of birds from the wild (Fain and Hyland, 1962). Of the wild birds only *Cyanerpes cyanea* from Brazil was from the southern hemisphere.

Sternostoma tracheacolum may affect the survival of infected birds in the wild. If Gouldian finches infested with air-sac mite survive in aviaries, body condition may be poor and fecundity reduced (Murray, 1966; Madill, 1987). The disproportionate number of deaths of females compared with males in captivity and the unequal sex ratio in the wild (1.5 males:1 female) (Woinarski and Tidemann, 1991) may be related to the high prevalence of mites in subadult females. In addition, birds in the wild have been observed to fly further during the late dry season (October to November) than earlier in the year to obtain both food and water (S. C. Tidemann, pers. obs.). The presence of mites in the trachea in the high numbers recorded in this study, plus the respiratory lesions, suggest that affected birds may be

TABLE 2. Prevalence and intensity of *Sternostoma tracheacolum* and its distribution in fifteen of twenty-five infected Gouldian finches from the wild, north-west Australia.

| Age | Sex | N | Number infected | Number mites | Mean number mites | Location of mites (% occurrence) | | | | | |
|-------------------|-----|----|-----------------|--------------|-------------------|----------------------------------|--------------------|----------|------|----------|-------------|
| | | | | | | Nasal and buccal cavity | Trachea and syrinx | Bronchus | Lung | Air-sacs | Body cavity |
| Adult | M | 3 | 2 | 103 | 34.3 | | 5 | | 22 | 60 | 13 |
| Adult | F | 5 | 3 | 151 | 30.2 | | 36 | | 12 | 44 | 8 |
| Subadult/juvenile | M | 7 | 4 | 63 | 9.0 | 2 | 38 | 2 | 3 | 33 | 22 |
| Subadult/juvenile | F | 10 | 6 | 195 | 19.5 | 3 | 29 | 2 | 11 | 50 | 5 |

compromised in their ability to survive the late dry season conditions.

Sternostoma tracheacolum may have been a recent introduction to Australia. A source may have been migratory birds, or aviary birds that came into Australia before quarantine procedures were mandatory. Accidental or deliberate release of infected aviary birds may have resulted in the release of *S. tracheacolum* into the wild. Given the reported nomadic nature of Gouldian finches (Immelmann, 1982), infected birds may have spread the mite from a primary source, across the geographic range of these birds. Fain and Hyland (1962) suggest that the normal hosts of *S. tracheacolum* in the northern hemisphere are wild birds because infected wild birds survive better than infected captive canaries. Similarly, the adverse effects of *S. tracheacolum* on Gouldian finches suggest that their host-parasite relationship is of relatively recent origin. The lack of wild-caught bird specimens (whole birds) collected during early exploratory expeditions to this country means that probably we will never be able to determine the time of arrival of *S. tracheacolum* in Australia.

Elsewhere, other internal parasites have been reported to influence populations by affecting social behaviour (Freeland, 1981), the production of young (Hudson, 1986) or the distribution and the abundance of their hosts (van Riper and van Riper, 1986). Given the effects of *S. tracheacolum* on its host, it is possible that this parasite, even if it did not cause the massive decline of

the Gouldian finch, may be suppressing the return of the finch to its former status.

ACKNOWLEDGMENTS

We thank C. Burgoyne, E. Strauss, S. Kerin, S. Munro, J. de Koning and J. McCartney for assistance in the field; R. Domrow for identifying air-sac mites; P. Bell, S. Munro, C. Pearce and R. Mulder for dissecting birds; N. Call for the histology; pastoralists in the VR District for access to properties; C. Webb for the scanning electron micrographs; Department of Conservation and Land Management, Western Australia for trapping returns; D. Spratt and two referees for advice on the manuscript; and World Wide Fund for Nature for support.

REFERENCES

- BLAKERS, M., S. J. J. F. DAVIES, AND P. N. REILLY. 1984. The atlas of Australian birds. Melbourne University Press, Melbourne, Australia, 738 pp.
- FAIN, A., AND K. E. HYLAND. 1962. The mites parasitic in the lungs of birds. The variability of *Sternostoma tracheacolum* Lawrence, 1948, in domestic and wild birds. *Parasitology* 52: 401-424.
- FREELAND, W. J. 1981. Parasitism and behavioural dominance among male mice. *Science* 213: 461-462.
- HEUMANN, G. A. 1926. Birds in the Northern Territory and the new finch. *Emu* 25: 134-136.
- HUDSON, P. J. 1986. The effect of a parasitic nematode on the breeding production of Red Grouse. *Journal of Animal Ecology* 55: 85-92.
- IMMELMANN, K. 1982. Australian finches in bush and aviary. 5th edition. Angus & Robertson, Sydney, Australia, 216 pp.
- LAWRENCE, R. F. 1948. Studies on some parasitic mites from Canada and South Africa. *The Journal of Parasitology* 34: 364-379.
- MADILL, D. 1987. Parasitic diseases. Everybird: A guide to health. In P. Macwhirter (ed.). Inkata, Sydney, Australia, pp. 45-59.

- MURRAY, M. D. 1966. Control of respiratory acariasis of Gouldian Finches caused by *Sternostoma tracheacolum* by feeding carbaryl. Australian Veterinary Journal 42: 262-264.
- VAN RIPER, C., AND S. G. VAN RIPER. 1986. The epizootiology and ecological significance of malaria in Hawaiian birds. Ecological Monographs 56: 327-344.
- WOINARSKI, J. C. Z., AND S. C. TIDEMANN. 1991. Survivorship and some population parameters for the endangered Gouldian Finch *Erythrura gouldiae* and two other finch species at two sites in tropical northern Australia. Emu 91: In press.

Received for publication 4 March 1991.