

## **An Epizootic of Malignant Catarrhal Fever in a Large Captive Herd of White-Tailed Deer (*Odocoileus virginianus*)**

Authors: Brown, C. C., and Bloss, L. L.

Source: Journal of Wildlife Diseases, 28(2) : 301-305

Published By: Wildlife Disease Association

URL: <https://doi.org/10.7589/0090-3558-28.2.301>

---

BioOne Complete ([complete.BioOne.org](https://complete.BioOne.org)) is a full-text database of 200 subscribed and open-access titles in the biological, ecological, and environmental sciences published by nonprofit societies, associations, museums, institutions, and presses.

Your use of this PDF, the BioOne Complete website, and all posted and associated content indicates your acceptance of BioOne's Terms of Use, available at [www.bioone.org/terms-of-use](https://www.bioone.org/terms-of-use).

Usage of BioOne Complete content is strictly limited to personal, educational, and non - commercial use. Commercial inquiries or rights and permissions requests should be directed to the individual publisher as copyright holder.

---

BioOne sees sustainable scholarly publishing as an inherently collaborative enterprise connecting authors, nonprofit publishers, academic institutions, research libraries, and research funders in the common goal of maximizing access to critical research.

## An Epizootic of Malignant Catarrhal Fever in a Large Captive Herd of White-Tailed Deer (*Odocoileus virginianus*)

C. C. Brown,<sup>1</sup> and L. L. Bloss,<sup>2</sup> <sup>1</sup>Foreign Animal Disease Diagnostic Laboratory, National Veterinary Services Laboratory, Science and Technology, Animal and Plant Health Inspection Service, United States Department of Agriculture, P.O. Box 848, Greenport, New York 11944, USA; <sup>2</sup>Veterinary Services, Animal and Plant Health Inspection Service, United States Department of Agriculture, 2333 Whitehorse-Mercerville Road, Trenton, New Jersey 08625, USA

**ABSTRACT:** Over a 4-mo period 23 of 28 white-tailed deer kept at a small zoo in New Jersey (USA) died. Clinical signs prior to death were minimal and consisted of depression, central nervous system disorders, and watery diarrhea in a few animals only. Histopathology revealed widespread acute vascular lesions, ranging from modest accumulations of blast-like mononuclear cells and edema in the adventitia through to disruption of the tunica media and thrombosis. These vascular lesions were seen in a variety of organs but were most prominent in lung, heart, liver and intestine. Severe vascular changes were associated with necrosis. Lymphoreticular hyperplasia was evident in the lymphoid tissue of all animals.

**Key words:** malignant catarrhal fever, white-tailed deer, *Odocoileus virginianus*.

Malignant catarrhal fever (MCF) is a multisystemic, usually fatal, viral disease of cattle and certain other ruminants. There are two epidemiologically distinct, yet clinicopathologically similar, forms of MCF (Heuschele, 1984). One occurs among animals co-mingling with wildebeest and is referred to as wildebeest-derived MCF. The causative agent is a gammaherpesvirus, alcelaphine herpesvirus-1. The other form is found among animals in contact with sheep (sheep-associated MCF). The etiologic agent of this latter form was cultured very recently after passing blood and spleen from an infected cow through a rabbit (Schuller et al., 1990). It appears to be another gammaherpesvirus.

Although usually considered to be a disease of cattle, MCF can cause serious morbidity and mortality in cervids (Clark et al., 1970; Sanford et al., 1977; Denholm and Westbury, 1982; McAllum et al., 1982). White-tailed deer (*Odocoileus virginianus*) are experimentally susceptible to infection with either the wildebeest-derived

form (Whitenack et al., 1981) or the sheep-associated form (Clark et al., 1972), and natural infections have been documented several times (Clark et al., 1970; Wyand et al., 1971; Wobeser et al., 1973; Shulaw and Oglesbee, 1989). In this report we describe a particularly severe epizootic of MCF in which 23 of 28 white-tailed deer at a small zoo in New Jersey, USA (39°50'N and 74°15'W), were lost over a 4-mo period.

The zoo contained 28 white-tailed deer: 12 adult males, 10 adult females, and 6 fawns. Eleven of the deer ranged freely, whereas others were kept in adjacent pens of one to six animals each. The free-ranging animals had fairly close contact with cougars (*Felis concolor*), tigers (*Panthera tigris*), lions (*Panthera leo*), and a domestic pig (*Sus domestica*). Enclosures containing raccoons (*Procyon lotor*), bears (*Ursus americanus*), an elephant (*Elephas maximus*), a hyena (*Crocuta crocuta*), domestic sheep (*Ovis aries*), and domestic goats (*Capra hircus*) also were on the grounds but were separated from the deer by a distance of 100 to 200 m.

The epizootic began in early October 1990 when two adult females became ill. They were febrile, depressed, anorexic, and had watery diarrhea. Both died in <1 wk. Within a few days more animals became ill and died. The clinical signs for the remaining deer were minimal, despite the fact that the herd was watched closely by the attendants. Some animals were depressed and reluctant to feed for a day prior to death. A few had seizures terminally. Others simply were found dead. By early February 1991, only five of the original herd were alive.

Gross findings among the dead animals included blood-tinged intestinal contents, congested and edematous lungs, petechial to ecchymotic hemorrhages on serosal surfaces of intestine and spleen, multifocal necrotic foci in liver and heart, and moderate enlargement of lymph nodes.

Tissues from six animals were submitted to the Foreign Animal Disease Diagnostic Laboratory (FADDL), National Veterinary Services Laboratory (NVSL), Greenport, New York, for histopathologic and virologic evaluation. Blood and/or serum from thirteen animals was submitted to the Diagnostic Virology Laboratory (DVL), NVSL, Ames, Iowa for virus isolation or serology.

The tissues submitted for histological evaluation included a minimum of lung, heart, kidney, cerebral cortex, lymph node, and spleen from each of the six animals. In addition, liver and urinary bladder were submitted from five animals, and large and small intestine from two animals.

Vascular changes commonly were seen in the various tissues. In all animals, small to medium-sized pulmonary vessels had varying degrees of disruption, usually with prominent sero-cellular accumulations in the adventitia. Cell populations were pleomorphic, with blast-like mononuclear cells predominating. Occasionally, inflammatory cells were present within the tunica media. In some animals, severe inflammation of the vascular walls was accompanied by thrombosis (Fig. 1). One animal had a severe inflammation of the myocardium, with a lymphocytic-lymphoblastic cell infiltrate extending from vessels into the myocardium and associated with myocardial necrosis and early mineralization (Fig. 2). Less severe, yet similar, inflammatory changes were seen in the hearts of two other animals. In four of five livers, accumulations of heterogeneous mononuclear cells, many of which were blast-like, extended in variably-sized aggregates into the hepatic parenchyma from the portal vessels. In one liver, the cellular infiltrate was associated with hepatic necrosis.

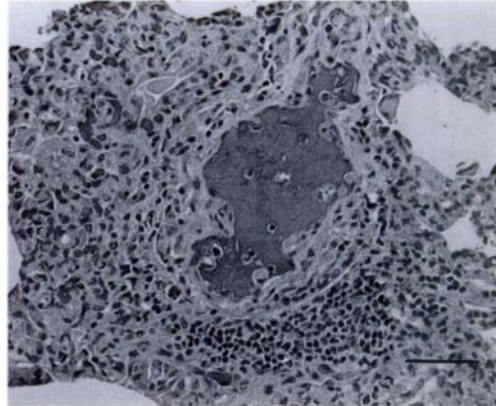


FIGURE 1. A thrombosed pulmonary blood vessel severely disrupted by inflammatory cell infiltration in the tunica media and adventitia. H&E. Bar = 100  $\mu$ m.

Lymph nodes invariably were hyperplastic, with hypercellularity in the paracortical and interfollicular areas. In some animals, the outer "cap" region of many follicles was depleted. Vascular changes consisting of peri-vascular edema and hemorrhage occasionally were seen in lymph nodes.

Five of six deer had subtle edematous changes in the deep cortical laminae of the cerebral cortex. In three animals these edematous changes were associated with sero-cellular accumulations within the walls of small to medium-sized blood vessels.

Bladders of two animals had focal vasculitis in the submucosa. Sections of the small and large intestines were examined from only two animals; in both, there was severe crypt cell damage with villous atrophy. Regenerative changes were evident in focal areas. In all sections of gut, there was marked vascular involvement in the submucosa, with edema, prominent endothelial swelling and sero-cellular accumulations in the adventitia, and occasionally, muscularis. In one animal, there was a marked proliferation of blast-like mononuclear cells associated with the vascular changes in the submucosa.

Heparinized whole blood or spleen was

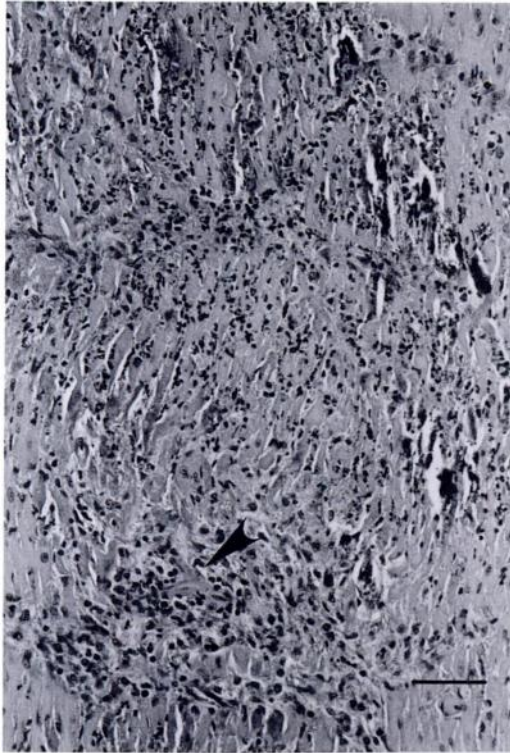


FIGURE 2. Myocardial necrosis and mineralization secondary to disrupted blood vessels (arrow). H&E. Bar = 100  $\mu$ m.

submitted for virus isolation from fourteen (thirteen to DVL, NVSL, one to FADDL, NVSL) animals affected during the outbreak. Samples were cultured according to standard NVSL protocols. Briefly, they were inoculated intravenously into embryonated eggs and onto a variety of cell cultures, including Vero (American Type Culture Collection (ATCC)) baby hamster kidney (ATCC), and in some instances, primary embryonic bovine lung, primary bovine turbinate, and primary embryonic lamb kidney. A portion of spleen (0.65 g) from one animal was macerated, suspended in 5 ml of media and inoculated oro-nasally into two rabbits. Animals were monitored daily for 28 days for signs of clinical disease. No embryonic deaths were observed in the eggs and in the cell culture no cytopathic effect was observed, even after two blind passages.

Serum samples from six deer were tested

by agar gel immunodiffusion for antibodies to bluetongue and epizootic hemorrhagic disease according to standard NVSL protocols. Sera from two deer also were tested for antibodies to bluetongue by enzyme-linked immunosorbent assays (Afshar et al., 1987). Serum from a seventh animal was tested by virus neutralization for antibodies to epizootic hemorrhagic disease and alcelaphine herpesvirus-1 according to standard NVSL protocol.

No viruses were isolated, and no signs of illness developed in the rabbits inoculated with macerated spleen tissues. The results of all serological tests were negative.

Early in the outbreak, epizootic hemorrhagic disease, bluetongue, and malignant catarrhal fever were considered as possible etiologic agents. However, the very prominent lymphoreticular hyperplasia and lymphoblastic infiltrates seen were inconsistent with either epizootic hemorrhagic disease or bluetongue. Also, serum samples from six different animals were negative for antibodies to either bluetongue or epizootic hemorrhagic disease. Furthermore, although the first deaths occurred in October, when *Culicoides* spp. could be active, animals continued to die into December and January—well past the time when competent vectors for epizootic hemorrhagic disease or bluetongue would be present in this geographic area.

Failure to isolate a virus was disappointing but not surprising. To date, there has been only one recorded instance of successfully culturing the agent of sheep-associated malignant catarrhal fever (Schuller et al., 1990). This required inoculation of infective material from a clinically-ill steer intravenously or intraperitoneally into a rabbit and co-cultivation of rabbit spleen cells with embryonic bovine gingivial cells after the rabbit became clinically ill. In this epizootic among deer, we inoculated macerated spleen oro-nasally into a rabbit. The rabbit did not develop clinical illness. Failure to develop clinical illness may have been due to oro-nasal, rather than intra-

venous or intra-peritoneal inoculation. Also, the virus may have been inactivated during transit. With alcelaphine herpesvirus-1 (the agent of wildebeest-derived MCF), it is well-recognized that the agent is rapidly inactivated and should be inoculated onto cell cultures <24 hr post-mortem. Also, the lack of serologic reaction to alcelaphine herpesvirus-1 in the one animal tested is not surprising, since although there is limited cross-reaction by indirect fluorescent antibody testing, serum from animals affected with the sheep-associated form of MCF does not cross-react with alcelaphine herpesvirus-1 by virus neutralization (Rossiter, 1983).

Our findings are similar to what others have described for malignant catarrhal fever in deer. Compared to cattle, the disease in deer is much more acute, often with few or no premonitory signs prior to death (Wobeser et al., 1973); lesions tend to be more hemorrhagic, and there usually is more visceral involvement than in cattle. In the deer, gastrointestinal and myocardial lesions were prominent. Such lesions are less frequently seen in cattle dying from malignant catarrhal fever.

The zoo contained no wildebeest or any other members of the alcelaphine subfamily. In contrast, it had 20 sheep; so we assumed that the malignant catarrhal fever was the sheep-associated form. A puzzling feature is that the sheep and deer were separated by a large distance (100 to 200 meters). However, in some cases of MCF in deer, there was little or no apparent contact with sheep (Denholm and Westbury, 1982; McAllum et al., 1982). Others have suggested contact transmission from deer to deer (Reid et al., 1986).

The most surprising feature of this epizootic was its very extensive nature, with 23 of the 28 white-tailed deer succumbing over a 4-mo period. Although it is not proven that all died of MCF, the six submitted for histologic examination did; it is reasonable to assume that the others died of the same process. Malignant catarrhal fever normally is considered to be a sporadic

disease affecting only one or two animals in a herd. Rarely, it occurs as an epizootic in cattle (Pierson et al., 1973). In deer, there seems to be a greater tendency for large numbers of animals to be affected (Clark et al., 1970; McAllum et al., 1982). This case was extreme in that regard. Perhaps it should be kept in mind that MCF in deer tends to be clinically, pathologically, and epidemiologically different from MCF in cattle.

The authors thank Dr. Hubert Paluch for performing many of the necropsies, Dr. Harvey Olander for reviewing the histopathology, and Drs. Carol House, Merwin Frey and David Alstad for virus isolation and serology.

#### LITERATURE CITED

- AFSHAR, A., F. C. THOMAS, P. F. WRIGHT, J. L. SHAPIRO, T. P. SHETTIGARA, AND J. ANDERSON. 1987. Comparison of competitive and indirect enzyme-linked immunosorbent assays for detection of bluetongue virus antibodies in serum and whole blood. *Journal of Clinical Microbiology* 25: 1705-1710.
- CLARK, K. A., R. M. ROBINSON, R. G. MARBURGER, L. P. JONES, AND J. H. ORCHARD. 1970. Malignant catarrhal fever in Texas cervids. *Journal of Wildlife Diseases* 6: 376-383.
- , ———, L. L. WEISHUHN, AND S. MCCONNELL. 1972. Further observations on malignant catarrhal fever in Texas deer. *Journal of Wildlife Diseases* 8: 72-74.
- DENHOLM, L. J., AND H. A. WESTBURY. 1982. Malignant catarrhal fever in farmed *Rusa* deer (*Cervus timorensis*). I. Clinico-pathological observations. *Australian Veterinary Journal* 58: 81-87.
- HEUSCHELE, W. P., 1984. Malignant catarrhal fever. In *Foreign animal diseases: Their prevention, diagnosis and control*, G. S. Trevino and J. L. Hyde (eds.). U.S. Animal Health Association, Richmond, Virginia, pp. 244-255.
- MCALLUM, H. J., N. M. MAVOR, AND P. HEMMINGSEN. 1982. A malignant catarrhal fever-like disease in red deer (*Cervus elaphus*) in New Zealand. *New Zealand Veterinary Journal* 30: 99-101.
- PIERSON, R. E., D. THAKE, A. E. MCCHESENEY, AND J. STORZ. 1973. An epizootic of malignant catarrhal fever in feedlot cattle. *Journal of the American Veterinary Medical Association* 163: 349-360.
- REID, H. W., D. BUXTON, I. POW, AND J. FINLAYSON. 1986. Malignant catarrhal fever: Experimental transmission of the 'sheep-associated' form of the

- disease from cattle and deer to cattle, deer, rabbits and hamsters. *Research in Veterinary Science* 41: 76-81.
- ROSSITER, P. B. 1983. Antibodies to malignant catarrhal fever in cattle with non-wildebeest-associated malignant catarrhal fever. *Journal of Comparative Pathology* 93: 93-97.
- SANFORD, S. E., P. B. LITTLE, AND W. A. RAPLEY. 1977. The gross and histopathologic lesions of malignant catarrhal fever in three captive sika deer (*Cervus nippon*) in southern Ontario. *Journal of Wildlife Diseases* 13: 29-32.
- SCHULLER, W., S. CERNY-REITERER, AND R. SILBER. 1990. Evidence that the sheep associated form of malignant catarrhal fever is caused by a herpes virus. *Journal of Veterinary Medicine Series B* 37: 442-447.
- SHULAW, W. P., AND M. OGLESBEE. 1989. An unusual clinical and pathological variant of malignant catarrhal fever in a white-tailed deer. *Journal of Wildlife Diseases* 25: 112-117.
- WHITENACK, D. L., A. E. CASTRO, AND A. A. KOCAN. 1981. Experimental malignant catarrhal fever (African form) in white-tailed deer. *Journal of Wildlife Diseases* 17: 443-451.
- WOBESER, G., J. A. MAJKA, AND J. H. L. MILLS. 1973. A disease resembling malignant catarrhal fever in captive white-tailed deer in Saskatchewan. *Canadian Veterinary Journal* 14: 106-109.
- WYAND, D. S., C. F. HELMBOLDT, AND S. W. NIELSEN. 1971. Malignant catarrhal fever in white-tailed deer. *Journal of the American Veterinary Medical Association* 159: 605-610.

*Received for publication 3 June 1991.*