



Lymphangiomyomatosis in the Atlantic Bottlenose Dolphin (*Tursiops truncatus*)

Authors: Rawson, Arnold J., Patton, Geoffrey W., and Brooks, John S.J.

Source: Journal of Wildlife Diseases, 28(2) : 323-325

Published By: Wildlife Disease Association

URL: <https://doi.org/10.7589/0090-3558-28.2.323>

BioOne Complete (complete.BioOne.org) is a full-text database of 200 subscribed and open-access titles in the biological, ecological, and environmental sciences published by nonprofit societies, associations, museums, institutions, and presses.

Your use of this PDF, the BioOne Complete website, and all posted and associated content indicates your acceptance of BioOne's Terms of Use, available at www.bioone.org/terms-of-use.

Usage of BioOne Complete content is strictly limited to personal, educational, and non - commercial use. Commercial inquiries or rights and permissions requests should be directed to the individual publisher as copyright holder.

BioOne sees sustainable scholarly publishing as an inherently collaborative enterprise connecting authors, nonprofit publishers, academic institutions, research libraries, and research funders in the common goal of maximizing access to critical research.

Lymphangiomyomatosis in the Atlantic Bottlenose Dolphin (*Tursiops truncatus*)

Arnold J. Rawson, M.D.,¹ Geoffrey W. Patton, B.S.,¹ John S.J. Brooks, M.D.,² ¹ Mote Marine Laboratory, 1600 Thompson Parkway, Sarasota, Florida 34236, USA; ² Department of Pathology and Laboratory Medicine, University of Pennsylvania, Philadelphia, Pennsylvania 19104, USA

ABSTRACT: The first case of lymphangiomyomatosis in a marine mammal is reported from a stranded male Atlantic bottlenose dolphin (*Tursiops truncatus*). This progressive proliferative disease involved the lungs and the mediastinal and probably mesenteric lymph nodes. An extraordinarily low level of testosterone may have been pathologically significant since all reported cases of this disease in humans occur in females.

Key words: *Tursiops truncatus*, bottlenose dolphin, lymphangiomyomatosis, lung, testosterone, first case, case report.

Lymphangiomyomatosis (also known as lymphangioleiomyomatosis) is an uncommon non-malignant but life-threatening proliferative process, of which numerous case studies have been reported in humans (Enzinger and Weiss, 1988). The lesion is composed of proliferating masses of smooth muscle and lymph vessels within pulmonary parenchymal and mediastinal lymph nodes, and may involve retroperitoneal lymph nodes as well. The smooth muscle cells are arranged about endothelium-lined spaces. Foci of lymphocytes and hemosiderin deposits may be seen throughout (Enzinger and Weiss, 1988). Involved lungs show evidence of bronchial obstruction. The involvement may be nodular or diffuse. Affected individuals present with dyspnea and often with intractable pleural effusion (Graham et al., 1984). All reported cases have been in females (Enzinger and Weiss, 1988), and studies have shown receptors for both estrogen and progesterone on the smooth muscle cells of the lesions (Brentani et al., 1984; Colley et al., 1989). Exposure to estrogens speeds the progression of the lesion (Shen et al., 1987), whereas ovariectomy, and especially progesterone administration permit regression (McCarty et al., 1980).

The literature contains no previous report of this lesion in marine mammals. Hence, the following report of lymphangiomyomatosis in the Atlantic bottlenose dolphin (*Tursiops truncatus*) is presented.

As Tropical Storm Marco was building off Florida's west coast the evening of 10 October 1990, a 295 cm, 193 kg male dolphin was found alive at a rocky gulf shore on Casey Key (27°10'35"N, 82°29'50"W). A beachgoer who saw the animal wash into the rocks went into the water and moved the animal to a nearby sandy shore while another person went to notify authorities. The animal was transported by stranding network personnel to Mote Marine Laboratory (Sarasota, Florida 34236, USA) and was placed in a natural seawater tank for evaluation and treatment.

The animal exhibited only superficial abrasions with slightly foul breath, small amounts of brown nasal exudate (<1 ml/collection attempt) and mild emaciation (sleek and bony appearance with dorsal and ventral blubber thicknesses >1.0 cm). Respirations were regular and averaged 1 to 3/min with a heart rate of 66 bpm. The dolphin was physiologically stabilized through rehydration and medication. After three days, the animal was taking food fish by hand and, by day five, it was decided to transfer the dolphin to another facility for long-term recuperation. During an examination on day nine, the animal died and was examined post-mortem the following day.

At necropsy the lungs were described as lumpy and somewhat hard to cut. Large firm areas suggestive of neoplasm were present and scattered cystic change was seen in the surrounding parenchyma. On section the firm areas consisted of uni-

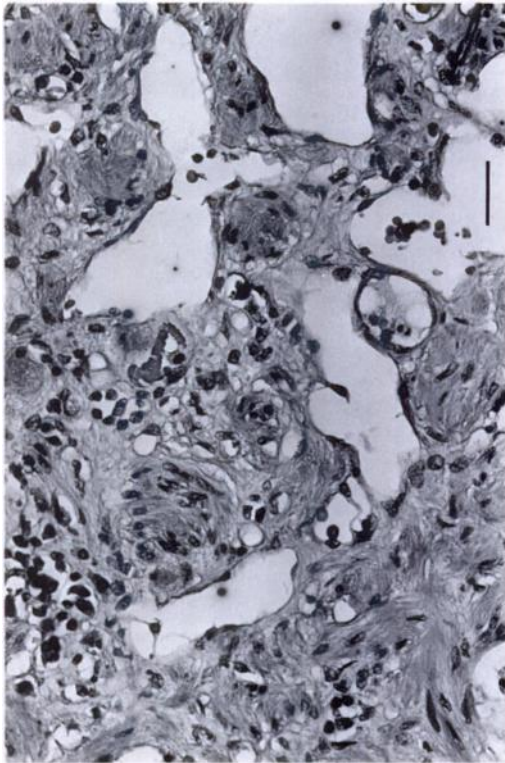


FIGURE 1. Section of a lung nodule in an Atlantic bottlenose dolphin with lymphangiomyomatosis showing dilated lymphatic channels of various sizes surrounded by smooth muscle bundles. H&E. Bar = 320 μ m.

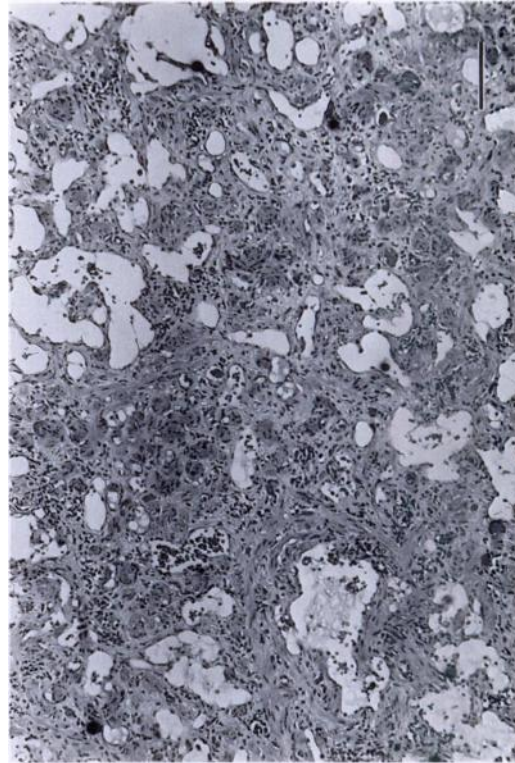


FIGURE 2. Section of lung nodule in an Atlantic bottlenose dolphin with lymphangiomyomatosis showing smooth muscle nodules in relation to dilated lymphatic channels, clusters of small lymphocytes in the interstitium and scattered lymphocytes in the channel. H&E. Bar = 80 μ m.

formly pale grayish tissue, throughout which were large dark foci, which proved on microscopy to be hemosiderin deposits. Mediastinal lymph nodes measured 4 cm in diameter and were composed of similar firm grayish tissue with dark hemosiderin deposits. Mesenteric lymph nodes measured 3 cm in diameter. Testes appeared grossly normal; testicular tissue was not saved for microscopy. No abnormality was seen in the other organs. Counting of growth layer groups (GLG) in the teeth (Hohn et al., 1989) showed this animal was >20-yr-old. Representative specimens of this lesion were sent to the Registry of Comparative Pathology (Armed Forces Institute of Pathology, Washington, D.C. 20306, USA; Accession Number 2304654-3). In histologic sections of lung taken from

the pale firm areas, lung parenchyma was entirely replaced. There were numerous short fasciculi of smooth muscle throughout. The muscle bundles were distinguished from collagen by means of the Masson Trichrome stain (Masson, 1929) and their nature was confirmed by means of a positive reaction for desmin using the immuno-peroxidase technique (Sheehan and Hrapchak, 1987). In some areas the muscle formed small nodular aggregates, while elsewhere it surrounded small endothelium-lined vascular channels which contained proteinaceous fluid and occasional lymphocytes but no red blood cells. Between these channels were blood capillaries filled with red blood cells. Numerous foci of lymphocytes and of hemosiderin were scattered throughout the tissue (Figs.

1, 2). In the lung parenchyma at the periphery of the lesions were many cystically dilated bronchi. Elsewhere in the lung there was patchy acute bronchopneumonia.

Sections of mediastinal lymph nodes revealed very little remaining lymph node structure. The node was almost totally replaced by muscle fasciculi, lymphatic vessels, lymphocytes, and hemosiderin deposits similar to those seen in the involved areas of the lung. In a mesenteric lymph node, the node structure was largely preserved. However, there was a focal increase in smooth muscle surrounding lymphatic vessels, suggestive of early involvement.

Hormonal assays performed on frozen serum collected the first day showed total estrogen <25 pg/ml (normal female dolphin is 5 to 45 pg/ml depending on estrus cycle; Kirby, 1990) and testosterone 15 ng/dl (normal mature male dolphin is 100–5,440 ng/dl depending on season; Schroeder and Keller, 1989).

This dolphin showed a classical morphological picture of lymphangiomyomatosis as seen in the human. It also had the typical human organ distribution (diffuse nodular lung involvement, mediastinal and mesenteric/retroperitoneal lymph node involvement). In the human, there is a strong hormonal overtone to this entity, as all cases have been female and, in addition, hormonal therapeutic intervention is helpful. Here, the one remarkable difference was that the animal was male. However, the low testosterone level may have an important bearing on the pathogenesis of this lesion. We believe this to be the first reported case of this entity in a dolphin.

The authors wish to thank the more than 100 people who volunteered to assist in the care of the dolphin over the 9 days it sur-

vived and the subsequent post-mortem examination. We particularly thank the Sarasota Memorial Hospital and Sarasota Pathology Laboratory for help with the lab analyses.

LITERATURE CITED

- BRENTANI, M. M., M. D. CARVALHO, M. D. SALDIVA, M. M. PACHECO, AND C. T. F. OSHIMA. 1984. Steroid receptors in pulmonary lymphangiomyomatosis. *Chest* 85: 96–99.
- COLLEY, M. H., E. GEPPERT, AND W. A. FRANKLIN. 1989. Immunohistochemical detection of steroid receptors in a case of pulmonary lymphangiomyomatosis. *American Journal of Surgical Pathology* 13: 803–807.
- ENZINGER, F. M., AND S. W. WEISS. 1988. *Soft tissue tumors*, 2nd ed. C. V. Mosby Co., Washington, D.C., 1008 pp.
- GRAHAM, M. L., T. C. SPELSBERG, D. E. DINES, W. S. PAYNE, J. BJORNSSON, AND J. T. LIE. 1984. Pulmonary lymphangiomyomatosis. *Mayo Clinic Proceedings* 59: 3–11.
- HOHN, A. A., M. D. SCOTT, R. S. WELLS, J. C. SWEENEY, AND A. B. IRVINE. 1989. Growth layers in teeth from known-age free-ranging bottlenose dolphins. *Marine Mammal Science* 5: 315–342.
- KIRBY, V. L. 1990. Endocrinology of marine mammals. In *Handbook of Marine Mammal Medicine*, L. A. Dierauf (ed.). CRC Press, Boca Raton, Florida, pp. 303–351.
- MASSON, P. 1929. Trichrome stain. *Journal of Technologic Methods* 12: 75–90.
- MCCARTY, K. S., J. A. MOSSLER, R. MCLELLAND, AND H. O. SIEKER. 1980. Pulmonary lymphangiomyomatosis responsive to progesterone. *New England Journal of Medicine* 303: 1461–1465.
- SCHROEDER, J. P., AND K. V. KELLER. 1989. Seasonality of testosterone and sperm density in *Tursiops truncatus*. *Journal of Experimental Zoology* 249: 316–326.
- SHEEHAN, D. C., AND B. B. HRAPCHAK. 1987. *Theory and practice of histotechnology*, 2nd ed. C. V. Mosby Company, St. Louis, Missouri, 493 pp.
- SHEN, A., J. A. WALDRON, AND T. E. KING. 1987. Exacerbation of pulmonary lymphangiomyomatosis by exogenous estrogens. *Chest* 91: 782–785.

Received for publication 7 May 1991.