



Physical and Behavioral Findings in a Pseudohermaphrodite American Bison

Authors: Lott, Dale F., Benirschke, Kurt, McDonald, Jerry N., Stormont, Clyde, and Nett, Terry

Source: Journal of Wildlife Diseases, 29(2) : 360-363

Published By: Wildlife Disease Association

URL: <https://doi.org/10.7589/0090-3558-29.2.360>

BioOne Complete (complete.BioOne.org) is a full-text database of 200 subscribed and open-access titles in the biological, ecological, and environmental sciences published by nonprofit societies, associations, museums, institutions, and presses.

Your use of this PDF, the BioOne Complete website, and all posted and associated content indicates your acceptance of BioOne's Terms of Use, available at www.bioone.org/terms-of-use.

Usage of BioOne Complete content is strictly limited to personal, educational, and non - commercial use. Commercial inquiries or rights and permissions requests should be directed to the individual publisher as copyright holder.

BioOne sees sustainable scholarly publishing as an inherently collaborative enterprise connecting authors, nonprofit publishers, academic institutions, research libraries, and research funders in the common goal of maximizing access to critical research.

Physical and Behavioral Findings in a Pseudohermaphrodite American Bison

Dale F. Lott,¹ Kurt Benirschke,² Jerry N. McDonald,³ Clyde Stormont,⁴ and Terry Nett,⁵ ¹ Department of Wildlife and Fisheries Biology, University of California, Davis, California 95616, USA; ² Department of Pathology, University of California Medical Center, 225 Dickinson, San Diego, California 92103, USA; ³ The McDonald and Woodward Publishing Company, P.O. Box 10308, Blacksburg, Virginia 24062-0308, USA; ⁴ Stormont Laboratories, Inc., 1237 East Beamer Street, Suite D, Woodland, California 95695, USA; ⁵ Department of Physiology and Biophysics, Colorado State University, Fort Collins, Colorado 80523, USA

ABSTRACT: A pseudohermaphrodite American bison (*Bison bison*) behaved like an adult male when interacting with adult females, but like an adult female when interacting with adult males. Its chromosomes were a normal 60, XX and it had a uterus; but it had bilateral testes rather than ovaries. Skull measurements were intermediate between a bull and a cow. Gonadotrophin levels were typical of ovariectomized domestic cows or steers.

Key words: Pseudohermaphrodite; American bison, *Bison bison*; sexual behavior.

Hermaphroditism is an unusual condition in feral animals and has been studied extensively in humans. One generally differentiates "true" hermaphroditism with ovotestes (or ovary and testis) and variable external genitalia, and pseudohermaphroditism (Polani, 1981). The latter may be male or female pseudohermaphroditism, depending upon the nature of the gonadal tissues. In male pseudohermaphrodites the gonads are testes, while external and ductal organization is in the female direction. Conversely, in the case of female pseudohermaphroditism, the gonads are ovaries with the external genitalia of male differentiation.

The pseudohermaphrodite was part of a free-ranging population of about 400 American bison (*Bison bison*) on Catalina Island, California (USA; 33°22'N, 118°22'W) derived from two small introductions in 1924 and 1932. It had the head and shoulders of a 4-yr-old bull when first recognized in 1975, and looked the same when it was killed in October 1984. Blood was drawn from a jugular puncture for blood typing and determination of hormone levels before death; reproductive organs were removed by blunt dissection,

and sterile tissue samples of the skin were taken for karyotyping. The head and five cervical vertebrae were removed for comparison with representatives of extant and extinct bison species.

When killed, the subject weighed 414.6 kg, the weight of either an exceptionally heavy cow or a light 4-yr-old bull from Catalina (D. Propst, pers. comm.). Using the karyotyping method described by Benirschke et al. (1984), the chromosomes were a normal 60 XX, without abnormalities. We used the methods of Stormont (1954) for blood typing; there was no evidence for bloodgroup chimerism.

All physiological and soft tissue anatomical findings were consistent with a diagnosis of pseudohermaphroditism (Fig. 1). The vagina joined the urethra and was blind; the vagina was 11 cm long from that point. The external vagina was 2 cm deep with an 8 cm by 2 cm clitoris. The vagina was 18.5 cm long and 18 cm in circumference. It was enlarged and filled with viscid brown mucus. The uterine body was 20 × 15 mm; the horns were 150 × 25 mm and were empty. There were bilateral testes located where the ovaries would normally be; epididymides (25 × 10 mm and 20 × 8 mm) (Fig. 2) were present and were dark ocher yellow and firm. A cyst was present in one testis and one epididymis had a cyst containing white fluid with crystals. The anus and bladder were normal. The tubular structure crossing the bladder consisted of umbilical arteries with calcific content.

Upon microscopic examination, of hematoxylin and eosin stained tissue sections, the cervix, uterus, and vagina were normal

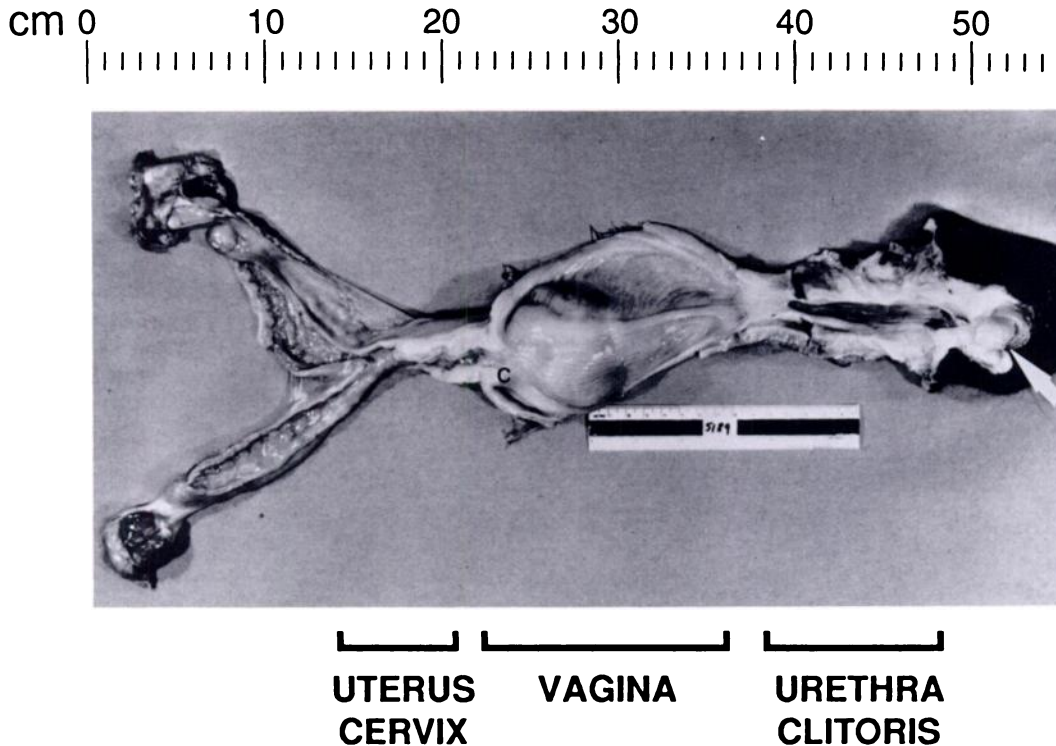


FIGURE 1. Macroscopic view of entire genital tract. At right the clitoris is indicated by a large arrow. To its left is the urethra, then vagina. The cervix is indicated by "C," to the left of which is the uterus and at extreme left are the testes.

and inactive. Mammary tissue was well-developed with some inspissated secretion. The testes contained no ovarian tissue. The tubular apparatus was completely atrophied, had no lumina, and was hyalinized. No definite germ cells could be seen. There was a typical testicular capsule. The interstitial cells were uniformly hyperplastic and hypertrophied; many had lipofuscin pigmentation. Several small adenomas of interstitial cells and one tubular adenoma of Sertoli cells were present. The tubular apparatus of the epididymides was normal, often dilated, and contained inspissated secretion.

Gonadotrophin levels were measured using reagents used to quantify gonadotrophins in cattle. Luteotrophic hormone (LH) level was determined following the methods of Niswender et al. (1969); and follicle stimulating hormone (FSH) was

determined using the methods of L'Hermite et al. (1972). The gonadotrophin levels were: LH = 9.5 ng/ml, and FSH = 97.08 ng/ml; these values are typical of mean concentrations observed in ovariec-

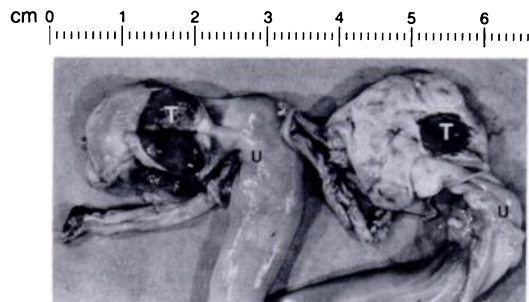


FIGURE 2. Uterine horns ("U") and sectioned and heavily pigmented testes ("T") of this pseudohermaphrodite bison. Note the more significant atrophy of the right testis.

tomized domestic cows or in steers (Walters and Schallenberger, 1984).

Abnormal sexual differentiation has not been recorded in bison, but it is a common condition in cattle where the freemartin condition of female twins commonly occurs. It is the result of masculinization and sterilization by the male co-twin's endocrine secretions that are transmitted through placental anastomoses (Lillie, 1917). The freemartin remains a life-long blood chimera, with circulating 60,XY lymphocytes and mixed blood groups (Basrur et al., 1970). A freemartin generally has no uterus, and its gonads are atrophied but not usually testis-like in their organization. This case does not meet the criteria for freemartinism but appears to be a case of typical male pseudohermaphroditism, with testes and a completely female external and internal ductal organization.

The bison was placed in the S3 (full maturity) age class of Skinner and Kaisen (1947) based on tooth wear patterns, which corresponds with the age of >13 yr estimated for this animal in the field. Data from the skull of this bison were compared with samples of skulls from normal *B. bison bison*. The number of samples per measure ranged from 22 to 142 for males and 2 to 38 for females. Skulls are sexually dimorphic in most of the conspicuous cranial characters that are easily observed and measured. All measurements reported here were based on McDonald (1981).

Most characters from the bison were within the range of small male or large female skulls. The linear dimensions of the dorsal surface of the skull were usually smaller than ranges observed in males and were in the middle and upper end of ranges observed in females. Most dimensions of the occipital region were within ranges observed for both males and females, but collectively were nearer the size of large females than small males. All dimensions of horn cores, however, were within ranges observed for males and larger than ranges observed for females. The horn cores on

the specimen were *absolutely* larger than any horn cores observed in female bison and were *relatively* larger than other characters in the specimen.

Qualitatively, the skull had the general appearance of a young adult male bison. The typical male-like configuration, as accentuated by the large horn cores, the prominent and relatively heavily-rimmed orbits, and the well-developed facial tubers, was enhanced by accumulation of secondary bone that formed thickened and roughened surfaces over the lateral parts of the frontal bones and around the orbits. The pattern of fusion along the frontal sutures was similar to skulls of both young (subadult to early adult) males and fully adult female bison. The horn cores, however, were distinctly mature in configuration and development and were distinctly male-like in morphology. Horn cores normally show greater sexual dimorphism than any other character of the skull.

The skull measurements did not fit well with patterns documented for adult individuals from free-ranging populations of either sex. The reasons for the differences in measurements are probably complex, but the intersex status of the bison could have influenced development of the skull.

The bison was observed regularly during 1975 through 1979. It was found in mixed cow and subadult bull groups which were present all year. By 1981 the bison had become essentially solitary in all seasons except during part of the rut; this is a behavior characteristic of mature ≥ 6 -yr-old bulls (Lott, 1974, 1979).

During the 1975 to 1979 breeding season the bison alternated between typically male and typically female behavior (Lott, 1974, 1979), depending on its immediate social context. Sometimes it would approach cows and behave like a typical mature male by standing close in a tending pattern and not eating. The cows behaved as though they were being tended by a bull. They brushed the bison back with their horns if it came extremely close but otherwise were tolerant of exceptional

proximity. It was never observed to mount a cow.

When approached by a mature bull, the bison behaved like a mature cow and tolerated very close proximity and investigation of its genitalia. Mature bulls were attracted to and regularly tended the bison. If the bull came extremely close, the animal would brush him back with its horns. Bulls would never have tolerated this gesture from a young bull. Even when the subject was no longer gregarious it remained attractive to mature bulls which tended and defended it.

The pseudohermaphroditic bison was donated by the Santa Catalina Island Conservancy. The Conservancy's president, D. Propst, and his staff also contributed valuable information about the subject and logistical support in handling it. The study was supported by federal funds administered through the Agricultural Research Station as Hatch projects 3222 and 3815.

LITERATURE CITED

- BASRUR, P. K., S. KOSAKA, AND H. KANAGAWA. 1970. Blood cell chimerism and freemartinism in heterosexual bovine quadruplets. *Journal of Heredity* 61: 15-18.
- BENIRSCHKE, K., A. T. KUMAMOTO, J. H. OLSEN, M. M. WILLIAMS, AND J. OOSTERHUIS. 1984. On the chromosomes of *Gazella soemmerringi* cretzenschmar, 1826. *Zeitschrift für Säugetierkunde* 49: 368-373.
- L'HERMITE, M., G. D. NISWENDER, L. E. REICHERT, JR., AND A. R. MIDGLEY, JR. 1972. Serum follicle stimulating hormone in sheep as measured by radioimmunoassay. *Biology of Reproduction* 6: 325-332.
- LILLIE, F. R. 1917. The free martin; a study of the action of sex hormones in the foetal life of cattle. *Journal of Experimental Zoology* 23: 371-452.
- LOTT, D. F. 1974. Sexual and aggressive behavior of adult male American Bison (*Bison bison*). In *The behaviour of ungulates and its relation to management*, V. Geist and F. Walther (eds.). New Series #24, International Union for the Conservation of Nature and Natural Resources, Morges, Switzerland, pp. 382-394.
- . 1979. Dominance relations and breeding rate in mature male bison. *Zeitschrift für Tierpsychologie* 49: 418-432.
- MCDONALD, J. N. 1981. North American bison: Their classification and evolution. University of California Press, Berkeley, California, 316 pp.
- NISWENDER, G. D., L. E. REICHERT, JR., A. R. MIDGLEY, JR., AND A. U. NALBANDOV. 1969. Radioimmunoassay for bovine and ovine luteinizing hormone. *Endocrinology* 84: 1166-1173.
- POLANI, P. E. 1981. Abnormal sex development in man. 1. Anomalies of sex determining mechanisms. In *Mechanisms of sex differentiation in animals and man*, C. R. Austin and R. G. Edwards (eds.). Academic Press, London, England, pp. 465-554.
- SKINNER, M. F., AND O. C. KAISEN. 1947. The fossil *Bison* of Alaska and preliminary revision of the genus. *Bulletin of the American Museum of Natural History* 89: 123-256.
- STORMONT, C. 1954. Erythrocyte mosaicism in a heifer recorded as a single born. *Journal of Animal Science* 13: 94-98.
- WALTERS, D. L., AND E. SCHALLENBERGER. 1984. Pulsatile secretion of gonadotrophins, ovarian steroids and ovarian oxytocin during the preovulatory phase of the oestrous cycle in the cow. *Journal of Reproduction and Fertility* 71: 503-512.

Received for publication 17 September 1991.