



Lobo's Disease in a Bottlenose Dolphin (*Tursiops truncatus*) from Matagorda Bay, Texas

Author: Cowan, Daniel F.

Source: Journal of Wildlife Diseases, 29(3) : 488-489

Published By: Wildlife Disease Association

URL: <https://doi.org/10.7589/0090-3558-29.3.488>

BioOne Complete (complete.BioOne.org) is a full-text database of 200 subscribed and open-access titles in the biological, ecological, and environmental sciences published by nonprofit societies, associations, museums, institutions, and presses.

Your use of this PDF, the BioOne Complete website, and all posted and associated content indicates your acceptance of BioOne's Terms of Use, available at www.bioone.org/terms-of-use.

Usage of BioOne Complete content is strictly limited to personal, educational, and non - commercial use. Commercial inquiries or rights and permissions requests should be directed to the individual publisher as copyright holder.

BioOne sees sustainable scholarly publishing as an inherently collaborative enterprise connecting authors, nonprofit publishers, academic institutions, research libraries, and research funders in the common goal of maximizing access to critical research.

Lobo's Disease in a Bottlenose Dolphin (*Tursiops truncatus*) from Matagorda Bay, Texas

Daniel F. Cowan, Department of Pathology, University of Texas Medical Branch, Galveston, Texas 77555-0588, USA

ABSTRACT: Lobo's disease was diagnosed in a free-ranging male bottlenose dolphin *Tursiops truncatus* examined as part of a live-capture and release program conducted in Matagorda Bay, Texas, USA, during July 1992. Diagnosis was based on typical presentation of a raised skin lesion, with sub-epidermal granuloma and demonstration of typical features of the organism by light microscopy, using hematoxylin and eosin, and methenamine silver stains. This is the first instance of Lobo's disease found in a dolphin on the western coast of the Gulf of Mexico.

Key words: Lobo's disease, lobomycosis, dolphin, *Tursiops truncatus*, Texas Gulf coast.

In July 1992, a live-capture, sample and release program sponsored by the National Marine Fisheries Service, aimed at identifying the cause of a substantial episode of mortality among bottlenose dolphins (*Tursiops truncatus*) was conducted in the Port O'Connor area, Matagorda Bay, Texas, approx 96°18'N; 28°29'W. During this study a skin lesion was observed on an otherwise healthy animal. Lobo's disease was suspected. One of 35 bottlenose dolphins examined, the animal was a 257 cm long, 188.7 kg male, age unknown, but estimated to be old. The lesion was located on the leading edge of the left pectoral fin, near its insertion. It measured approximately 5 × 5 cm, and had a raised knobby surface. A biopsy was taken under local anesthesia with 2% Lidocaine (Astra Pharmaceutical Products, Inc., Westboro, Massachusetts, USA) and fixed in 10% neutral buffered formalin. The tissue was embedded in paraffin and sections were cut at 5 μm and stained with hematoxylin and eosin. The lesion was composed of a subepidermal non-caseating granuloma with many multinucleate giant cells containing round refractile organisms. Using the methenamine silver stain (Luna, 1968) we identified 5 to 10 μm yeast-like organisms occurring singly, in pairs and short chains,

occasionally connected by short tubes (Fig. 1). These features are typical of the causative organism of Lobo's disease (Binford and Dooley, 1976).

Lobo's disease or keloidal blastomycosis is a relatively superficial infection of the skin caused by a fungus, *Loboa lobi* (Binford and Dooley, 1976). This organism has yet to be grown in vitro, and identification is based on typical morphological features displayed in lesions. In humans, Lobo's disease occurs among inhabitants of tropical forests, especially in northern South America, Brazil, French Guiana, and Surinam (Migaki and Jones, 1983), but also in Cen-

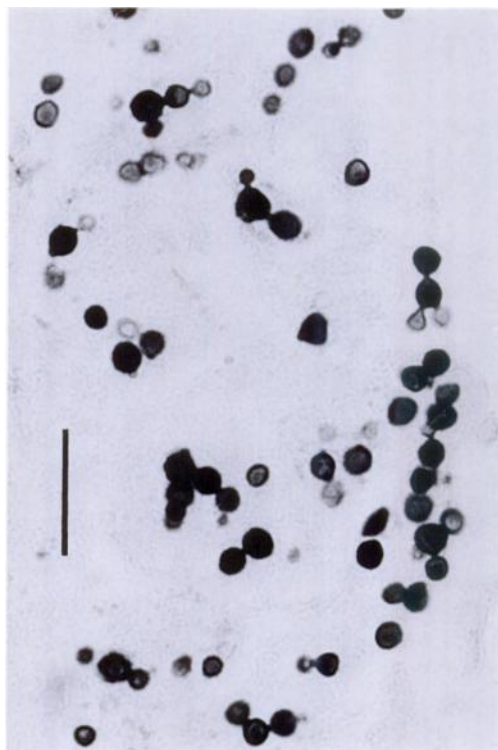


FIGURE 1. Typical appearance of *Loboa lobi*. Note pairs and short chains of organisms and connecting tubes. Methenamine silver stain. Bar = 40 μm.

tral America and the Yucatan region of Mexico (Pradinaud, 1984). A case in an aquarium attendant, possibly acquired from a *Tursiops* has been reported from Europe (Symmers, 1983). It has been recognized in at least two species of dolphins, *Tursiops truncatus* and the Guiana dolphin, *Sotalia guianensis* (Migaki and Jones, 1983). Except for the Guiana dolphin, and a *Tursiops* from the Bay of Biscay (Symmers, 1983), all reported instances are in *Tursiops* collected from Florida waters (Pradinaud, 1984). To the best of our knowledge, this is the first reported case from the western or Texas coast of the Gulf of Mexico.

The specimen has been deposited into the Marine Pathology Laboratory reference collection of the Department of Pathology, University of Texas Medical Branch at Galveston, Texas, number FB 532.

This work was supported in part by Grant #NA16RG0457-01 from the National Oceanic and Atmospheric Administration through the National Sea Grant College Program. The views expressed

herein are those of the author and do not necessarily reflect the view of NOAA or any of its sub-agencies.

LITERATURE CITED

- BINFORD, C. H., AND J. R. DOOLEY. 1976. Lobo's disease. *In* Pathology of tropical and extraordinary diseases, Vol. 2, C. H. Binford and D. H. Connor (eds.). Armed Forces Institute of Pathology, Washington, DC, pp. 583-584.
- LUNA, L. G. 1968. Manual of histological staining methods of the Armed Forces Institute of Pathology. McGraw-Hill, Inc., New York, New York, pp. 230-231.
- MIGAKI, G., AND S. R. JONES. 1983. Mycotic diseases in marine mammals. *In* Pathobiology of marine mammal diseases, E. B. Howard (ed.). CRC Press, Boca Raton, Florida, pp. 8-9.
- PRADINAUD, R. 1984. Entre le Yucatan, la Floride et la Guyane Francais, la Lobomycose existe-t-elle aux Antilles? Bulletin de la Societe de Pathologie Exotique et de ses Filiales 77: 392-400.
- SYMMERS, W. S. 1983. A possible case of Lobo's disease acquired in Europe from a bottle-nosed dolphin (*Tursiops truncatus*). Bulletin de la Societe de Pathologie Exotique et de ses Filiales 76: 777-784.

Received for publication 8 December 1992.