

## **Hepatic Capillariasis in Muskrats (*Ondatra zibethicus*)**

Authors: Borucinska, J. D., and Nielsen, S. W.

Source: Journal of Wildlife Diseases, 29(3) : 518-520

Published By: Wildlife Disease Association

URL: <https://doi.org/10.7589/0090-3558-29.3.518>

---

BioOne Complete ([complete.BioOne.org](https://complete.BioOne.org)) is a full-text database of 200 subscribed and open-access titles in the biological, ecological, and environmental sciences published by nonprofit societies, associations, museums, institutions, and presses.

Your use of this PDF, the BioOne Complete website, and all posted and associated content indicates your acceptance of BioOne's Terms of Use, available at [www.bioone.org/terms-of-use](https://www.bioone.org/terms-of-use).

Usage of BioOne Complete content is strictly limited to personal, educational, and non - commercial use. Commercial inquiries or rights and permissions requests should be directed to the individual publisher as copyright holder.

---

BioOne sees sustainable scholarly publishing as an inherently collaborative enterprise connecting authors, nonprofit publishers, academic institutions, research libraries, and research funders in the common goal of maximizing access to critical research.

## Hepatic Capillariasis in Muskrats (*Ondatra zibethicus*)

J. D. Borucinska and S. W. Nielsen, Northeastern Research Center for Wildlife Diseases, Department of Pathology, University of Connecticut, Storrs, Connecticut 06269, USA

**ABSTRACT:** We present the first prevalence data of hepatic capillariasis in muskrats in Pennsylvania and Connecticut (USA). The prevalence of hepatic capillariasis in five groups of muskrats coming from different locations and numbering 81, 229, 11, 19, and 20 animals, was 42%, 78%, 36%, 16%, and 0%, respectively. Liver lesions varied from minimal to severe multifocal granulomatous hepatitis, often containing adult worms or eggs.

**Key words:** *Capillaria hepatica*, muskrat, *Ondatra zibethicus*.

Hepatic capillariasis is caused by a liver-inhabiting nematode *Capillaria hepatica*, order Trichurata, family Capillaridae. *Capillaria hepatica* has been documented in over 20 mammalian species including humans (Banzon, 1983), and its life cycle was described by Luttermoser (1937, 1938).

Warwick (1936) reported a case of hepatitis from Great Britain in a muskrat infected with *C. hepatica*, but he did not elaborate on the histopathological features of the lesions that he found. Hepatic capillariasis first was reported in muskrats in North America by Price (1931) in Kirkfield, Ontario, Canada. Later, Penn (1952) found prevalences ranging from 0 to 50% among muskrats trapped along the Louisiana (USA) coast. To our knowledge there are no other reports on the geographical distribution of hepatic capillariasis among muskrats of North America.

We studied 360 animals from five different localities in Connecticut and Pennsylvania (USA). Eighty-one animals were collected from 1988 to 1989 from Geneva Swamp in Crawford County, (41°35'N, 80°14'W) Pennsylvania; formalin-fixed livers were submitted to our laboratory. Two-hundred-twenty-nine skinned muskrat carcasses were trapped by a licensed trapper during trapping seasons from a marsh near North Haven (41°24'N, 72°52'W), Connecticut, in 1970 and be-

tween 1989 and 1990. Eleven skinned carcasses were obtained from licensed trappers in 1991 also near North Haven, in the Quinnipiag Marsh (41°26'N, 72°50'W), Connecticut. Twenty skinned carcasses were from animals trapped during the trapping seasons of 1990 and 1991 near Farmington (41°43'N, 72°49'W), Connecticut. Nineteen animals were collected between November 1989 and March 1991 near Storrs (41°48'N, 72°15'W), Connecticut. Twelve of these 19 were composed of formalin-fixed liver specimens donated by Dr. Janine Caira, University of Connecticut, Storrs, Connecticut. The animals in this collection were submitted by local trappers or were road kills. The remaining seven animals from Storrs were intact road-killed muskrats collected between 1989 and 1991.

All fresh specimens were examined grossly and tissues with lesions were fixed in 10% buffered formalin and embedded in paraffin; 5  $\mu$ m thick sections were stained with hematoxylin and eosin. In addition touch smear preparations were made from fresh livers.

None of the 20 muskrats collected from Farmington had evidence of *C. hepatica* infection. In Storrs, three (16%) of 19 collected animals harbored *C. hepatica*. Combining the two groups from North Haven, 184 (77%) of 240 muskrats were infected with *C. hepatica*. In Pennsylvania, 34 (42%) of 81 muskrats were infected.

Gross and histopathological findings were similar in all muskrats. Fresh livers from infected muskrats had curled whitish tracts, 0.1 to 0.5 mm wide, under the liver capsule (Fig. 1). In addition there were small (1 to 3 mm), white foci on both the surface of the liver and in cut sections. *Capillaria hepatica* eggs often were seen in touch smears from the white tracts.

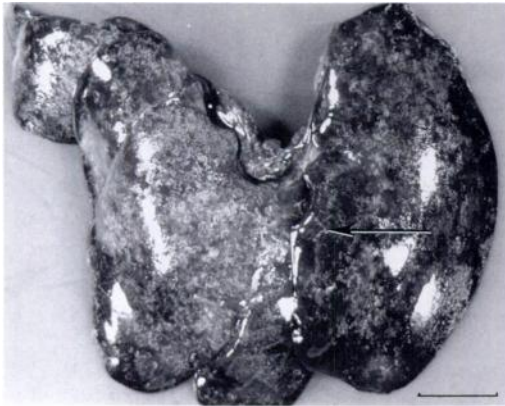

FIGURE 1. Liver of a muskrat with massive infection with *Capillaria hepatica*. Serpiginous necrotic tracts are seen under the liver capsule (arrow). Bar = 1 cm.

Histologically, infected livers had multifocal areas of *C. hepatica* infection, varying in severity. In mild cases single eggs or small groups of eggs were found among hepatocytes, without inflammation or with a minimal mononuclear infiltrate surrounding them. In more severe infections there was a marked, multifocally coalescent granulomatous, eosinophilic hepatitis replacing the normal hepatic parenchyma; eggs were found within these granulomatous lesions (Fig. 2). Most eggs were intact and in the four- to eight-cell morula stage. Eggshell disruption and dystrophic calcification were present in some. In a few cases adult gravid females occurred within the liver (Fig. 3). These were found either between intact hepatocytes, with no inflammatory infiltrate, or within foci of severe, eosinophilic, granulomatous hepatitis. In general, the most severe hepatic necrosis and granulomatous response was associated with disintegrating adult worms. In cases with dead, disintegrating adult worms and associated granulomatous hepatitis, there was fibrosis, but no liver regeneration was observed.

Hepatic capillariasis is a zoonosis; thus collection of zoepidemiological data, especially in highly populated areas, is important. This is the first published report of the prevalence of hepatic capillariasis

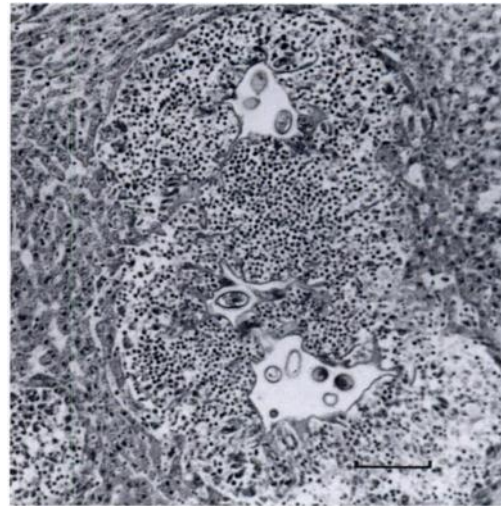


FIGURE 2. Granulomatous hepatitis surrounding clusters of *Capillaria hepatica* eggs. The infiltrate is composed of lymphocytes, eosinophils, and macrophages. H&E stain. Bar = 150 µm.

in freshwater and saltwater marsh muskrats in Connecticut and Pennsylvania. In this study we recorded the highest prevalence (184 (77%) of 240 animals) of this infection ever reported in muskrats. Among the 184 infected animals were 45 animals whose livers had histopathological lesions

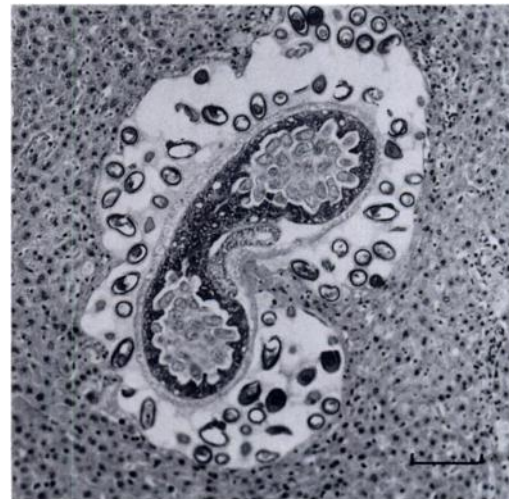


FIGURE 3. An adult gravid *Capillaria hepatica* and surrounding eggs free in liver parenchyma of a muskrat. There is no evidence of inflammation. H&E stain. Bar = 150 µm.

of granulomatous hepatitis, but with no discernible eggs or adult worms found in the examined sections. Because these lesions closely resembled those in which *C. hepatica* was found, they were considered to represent the final stage of infection in which the parasitic remnants had been phagocytized or missed by plane of tissue section.

There appeared to be a great variation in the inflammatory response to the infection in muskrats. In some individuals there was no inflammatory reaction to the infection and in others a severe granulomatous hepatitis was present. It is unclear whether this difference was caused by the stage of infection or concurrent infection of the host or if it depended on host-parasite interactions. Hypersensitivity reactions in repeated experimental infections in mice were reported by Raybourne and Solomon (1984). Perhaps hypersensitivity occurs in wild muskrats where repeated infections are very likely; this could account for the more severe lesions occasionally found.

Spratt and Singleton (1986), Singleton and Spratt (1986), and Singleton and McCallum (1990) reported a high pathogenic potential of experimental infection with high doses of *C. hepatica* eggs in laboratory mice. Because of the severity of lesions found in many of the animals in this study we believe, that hepatic capillariasis can be a population limiting factor in wild muskrat populations.

We thank Mr. Arnold Hayden from the Pennsylvania Game Commission, Dr. Janine Caira, Department of Ecology and Evolutionary Biology, University of Connecticut and Mr. Paul Rego from the Connecticut Department of Environmental

Protection for submitting muskrats. We also thank Dr. Janine Caira and Dr. Herb VanKruiningen, Department of Pathobiology, University of Connecticut for help on the manuscript and Ms. Joyce Chikowsky for her technical assistance.

#### LITERATURE CITED

- BANZON, T. 1983. *Capillaria hepatica* infection. In CRC handbook series in zoonoses, Section C: Parasitic zoonoses, Volume II, Myron G. Schultz (ed.). CRC Press Inc., Boca Raton, Florida, pp. 67-71.
- LUTTERMOSER, G. W. 1937. Factors influencing the development and viability of the eggs of *Capillaria hepatica*. American Journal of Hygiene 25: 275-289.
- . 1938. An experimental study of *Capillaria hepatica* in the rat and the mouse. American Journal of Hygiene 27: 321-340.
- PENN, G. H. 1952. Parasitological survey of Louisiana muskrats. The Journal of Parasitology 28: 348-349.
- PRICE, E. W. 1931. Note: *Hepaticola hepatica* in liver of *Ondatra zibethica*. The Journal of Parasitology 18: 44-56.
- RAYBOURNE, R., AND G. B. SOLOMON. 1984. Granulomatous hypersensitivity and antibody production in response to antigens of *Capillaria hepatica* eggs. International Journal of Parasitology 14: 371-375.
- SINGLETON, G. R., AND H. I. MCCALLUM. 1990. The potential of *Capillaria hepatica* to control mouse plagues. Parasitology Today 6: 190-192.
- , AND D. M. SPRATT. 1986. The effects of *Capillaria hepatica* (Nematoda) on natality and survival to weaning in BALB/c mice. Australian Journal of Zoology 34: 677-681.
- SPRATT, D. M., AND G. R. SINGLETON. 1986. Studies on the life cycle, infectivity and clinical effects of *Capillaria hepatica* (Bancroft) (Nematoda) in mice, *Mus musculus*. Australian Journal of Zoology 34: 633-675.
- WARWICK, T. 1936. The parasites of the muskrat (*Ondatra zibethica* L.) in the British Isles. Parasitology 28: 395-402.

Received for publication 30 December 1991.