



Physocephalus sp. (Spirurida, Spirocercidae) Larvae in Stomach Granulomas of the Blue Spiny Lizard, *Sceloporus serrifer* (Phrynosomatidae) from Texas

Authors: Goldberg, Stephen R., Bursey, Charles R., and Holshuh, H. J.

Source: Journal of Wildlife Diseases, 30(2) : 274-276

Published By: Wildlife Disease Association

URL: <https://doi.org/10.7589/0090-3558-30.2.274>

BioOne Complete (complete.BioOne.org) is a full-text database of 200 subscribed and open-access titles in the biological, ecological, and environmental sciences published by nonprofit societies, associations, museums, institutions, and presses.

Your use of this PDF, the BioOne Complete website, and all posted and associated content indicates your acceptance of BioOne's Terms of Use, available at www.bioone.org/terms-of-use.

Usage of BioOne Complete content is strictly limited to personal, educational, and non - commercial use. Commercial inquiries or rights and permissions requests should be directed to the individual publisher as copyright holder.

BioOne sees sustainable scholarly publishing as an inherently collaborative enterprise connecting authors, nonprofit publishers, academic institutions, research libraries, and research funders in the common goal of maximizing access to critical research.

***Physocephalus* sp. (Spirurida, Spirocercidae) Larvae in Stomach Granulomas of the Blue Spiny Lizard, *Sceloporus serrifer* (Phrynosomatidae) from Texas**

Stephen R. Goldberg,¹ Charles R. Bursey,² and H. J. Holshuh,³ ¹ Department of Biology, Whittier College, Whittier, California 90608, USA; ² Department of Biology, Pennsylvania State University, Shenango Valley Campus, 147 Shenango Avenue, Sharon, Pennsylvania 16146, USA; ³ Comparative Medical and Veterinary Services, County of Los Angeles, 3015 Roxanne Avenue, Long Beach, California 90808, USA

ABSTRACT: Prevalence of larval nematodes (*Physocephalus* sp., Spirurida, Spirocercidae) and associated cysts are reported from the blue spiny lizard, *Sceloporus serrifer*, from Texas (USA). Prevalence of infection was 29%, with seven of 24 animals infected. Larvae were found in gastric submucosal and occasionally mucosal cysts with a mean (\pm SE) of $287 \pm 9.04 \mu\text{m}$ in diameter. The nematodes evoked a chronic granulomatous response including cyst formation with focal destruction of gastric glands. Cysts resolved into areas of fibrosis. *Sceloporus serrifer* is a new host record for *Physocephalus* sp.

Key words: *Physocephalus* sp., larval nematode, *Sceloporus serrifer*, blue spiny lizard, granuloma, pathology.

As part of a helminth survey of Texas (USA) sceloporine lizards, we examined the blue spiny lizard, *Sceloporus serrifer*. This lizard ranges from southern Texas to northeastern Mexico (Conant and Collins, 1991). To our knowledge, there are no previous accounts of nematodes from this lizard. We report the occurrence of *Physocephalus* sp. within stomach granulomas of *S. serrifer* and describe the histopathology associated with this infection.

Twenty-four *Sceloporus serrifer* from Texas were examined. Ten were borrowed from the herpetology collection at Sul Ross State University, Alpine, Texas (SRSU). Six were borrowed from the herpetology collection at the Texas Memorial Museum, University of Texas, Austin (TNHC). Eight were borrowed from the herpetology collection at the Museum of Natural Sciences, Louisiana State University (LSUMZ). Museum accession numbers and locality data are: Starr County, SRSU 3974, 3986 (26°30'N, 99°05'W; elevation 76 m), LSUMZ 17092, 18629, 18631, 33818 to 33819 (26°33'N, 99°09'W; elevation 81 m),

LSUMZ 23397 (26°21'N, 98°45'W; elevation 53 m), LSUMZ 33822 to 33823 (26°41'N, 98°51'W; elevation 120 m), TNHC 13585 (26°20'N, 98°45'W; elevation 61 m); Webb County, SRSU 1016, 1019 to 1020, 1022 to 1023, 1034, (27°16'N, 99°00'W; elevation 228 m), TNHC 22554, 22558, 22560 (28°05'N, 99°32'W; elevation 238 m); Zapata County, SRSU 3332 to 3333 (27°04'N, 99°26'W; elevation 107 m), TNHC 4608, 23087 (27°56'N, 99°13'W; elevation 107 m). The lizards had been collected alive in the 1970's, fixed in 10% formalin and stored in ethanol (SRSU) or isopropanol (LSUMZ, TNHC). Portions of infected stomachs were embedded in paraffin, sectioned at 5 μm and stained with hematoxylin and eosin. Individual nematode larvae were dissected from granulomas and examined as glycerol wet-mounts for taxonomic identification. Voucher specimens were deposited in the U.S. National Parasite Collection (Beltsville, Maryland, USA; accession number 83279).

On dissection, granulomas containing nematode larvae were grossly visible as raised nodules in the stomach wall of seven of the 24 animals (prevalence 29%). Each granuloma contained a third stage *Physocephalus* sp. Larvae had a mean length (\pm SE) of $1.64 \pm 0.05 \text{ mm}$ ($n = 12$). Since the larvae were coiled within the cysts, measurements of width were not made. The distinguishing features of third stage larvae of *Physocephalus* sp. are the tip of the tail possesses a knoblike process supporting approximately 20 digitiform processes and the esophagus extends to mid-body (Alicata, 1935). Both features were observed in larvae taken from stomach

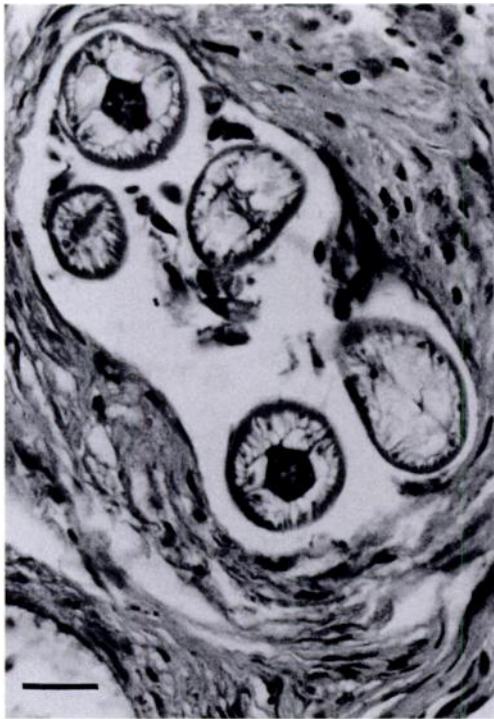


FIGURE 1. Larval *Physocephalus* sp. within a chronic granulomatous cyst in the stomach of the blue spiny lizard, *Sceloporus serrifer*. H&E. Bar = 100 μ m.

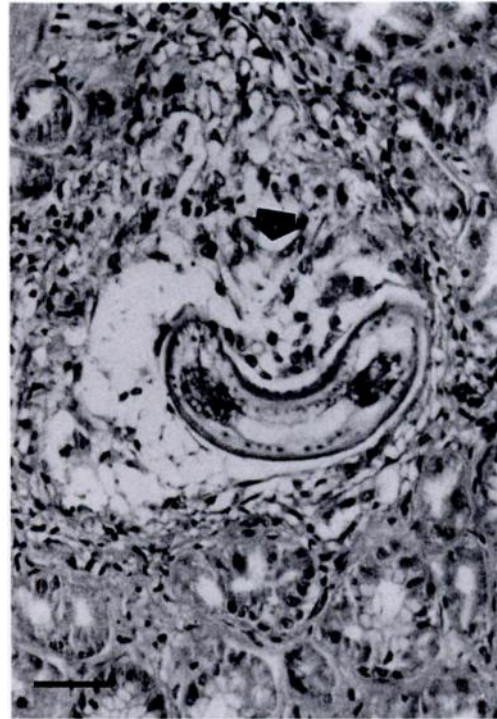


FIGURE 2. Larval *Physocephalus* sp. within gastric mucosa of the blue spiny lizard, *Sceloporus serrifer*. Note focal destruction of gastric glands (arrow). H&E. Bar = 40 μ m.

granulomas of *S. serrifer*. These features can be used to separate larvae of *Physocephalus* sp. from the closely related *Ascarops* sp. which has a smooth knoblike tail process, and from larvae of *Gongylo-nema* sp. which has four digitiform processes arising from a knobless tail process (Alicata, 1935). Fourth stage larvae or mature nematodes were not present, thus identification to species of *Physocephalus* was not possible.

On microscopic examination, the cysts were observed to be thin-walled and composed of macrophages and fusiform fibrocytes. The cysts had a mean diameter (\pm SE) of $287 \pm 9.04 \mu\text{m}$ ($n = 15$) and were located primarily in the gastric submucosa (Fig. 1). The presence of encysted parasites caused thickening of the submucosa and displacement of the muscularis externa. The few parasites that had migrated into the mucosa caused focal gastric gland de-

struction (Fig. 2). Host reactions ranged from granulomatous inflammation (Fig. 2) to fibrous-walled cysts (Fig. 1) reflecting chronicity of the host response. In early stages, the inflammatory cells present were small groups of lymphoid cells and macrophages, whereas late in the reaction, fibroblasts predominated. Cysts eventually resolved into areas of fibrosis.

Adult nematodes of *Physocephalus sexalatus* are known to occur in the stomachs (rarely the small intestines) of a number of wild and domestic pigs and are less commonly known from tapirs, equines, cattle and lagomorphs (Anderson, 1992). Infective larvae have been recovered from tissues of twenty different genera of dung beetles (Anderson, 1992) and encapsulated larvae have been found in birds (Cram, 1930), bats (Alicata, 1931, 1935) and armadillos (Chandler, 1946). The life cycles of the closely related *Ascarops strongylina*

and *Gongylonema pulchrum* are similar in that infective larvae occur in dung beetles; mammals, birds and lizards that habitually feed on insects become infected (Olsen, 1974).

Goldberg and Bursey (1988) observed third stage *Ascarops* sp. within liver granulomas of the western fence lizard (*Sceloporus occidentalis*) and also within stomach granulomas of the sagebrush lizard (*Sceloporus graciosus*) (Goldberg and Bursey, 1989). McAllister et al. (1993) found encysted third stage *Ascarops* sp. in the stomach, pancreas, small intestine and liver of the Mediterranean gecko, *Hemidactylus turcicus*. The histopathology of gastric infection by *Ascarops* sp. in *S. graciosus* and *H. turcicus* was very similar to that caused by *Physocephalus* sp. in *S. serrifer* with encysted larvae of *Ascarops* sp. present in thin-walled granulomas, consisting of macrophages and fibrocytes. No other infections of lizard species by *Physocephalus* sp. have been reported, but infection is possible wherever lizards feed on infected dung beetles.

We thank David Canatella (Texas Memorial Museum, University of Texas, Austin), James F. Scudday (Department of Biology, Sul Ross State University) and Douglas Rossman (Museum of Natural Science, Louisiana State University) for permission to examine specimens from their institutions.

LITERATURE CITED

- ALICATA, J. E. 1931. Infective larvae of *Physocephalus sexalatus* in bats. *The Journal of Parasitology* 18: 47.
- . 1935. Early developmental stages of nematodes occurring in swine. Technical Bulletin Number 489, U.S. Department of Agriculture, Washington, D.C., 96 pp.
- ANDERSON, R. C. 1992. Nematode parasites of vertebrates. Their development and transmission. CAB International, Wallingford, Oxon, England, 578 pp.
- CHANDLER, A. C. 1946. Helminths of armadillos, *Dasypus novemcinctus*, in eastern Texas. *The Journal of Parasitology* 32: 237–241.
- CONANT, R., AND J. T. COLLINS. 1991. A field guide to reptiles and amphibians of eastern and central North America, 3rd ed. Houghton Mifflin Company, Boston, Massachusetts, 450 pp.
- CRAM, E. B. 1930. Aberrant larvae of *Physocephalus sexalatus* in birds. *The Journal of Parasitology* 17: 56.
- GOLDBERG, S. R., AND C. R. BURSEY. 1988. Larval nematodes (*Ascarops* sp., Spirurida, Spirocercidae) in liver granulomata of the western fence lizard, *Sceloporus occidentalis* (Iguanidae). *Journal of Wildlife Diseases* 24: 568–571.
- , AND ———. 1989. Larval nematodes (*Ascarops* sp.) in stomach granulomas of the sagebrush lizard, *Sceloporus graciosus*. *Journal of Wildlife Diseases* 25: 630–633.
- MCALLISTER, C. T., S. R. GOLDBERG, C. R. BURSEY, P. S. FREED, AND H. J. HOLSHUH. 1993. Larval *Ascarops* sp. (Nematoda: Spirurida) in introduced Mediterranean geckos, *Hemidactylus turcicus* (Sauria: Gekkonidae), from Texas. *Journal of the Helminthological Society of Washington* 60: 280–282.
- OLSEN, O. W. 1974. Animal parasites: Their life cycles and ecology. University Park Press, Baltimore, Maryland, 562 pp.

Received for publication 4 October 1993.