

## **SUBCLINICAL AVIAN MALARIA INFECTIONS IN AFRICAN BLACK-FOOTED PENGUINS (SPHENISCUS DEMERSUS) AND INDUCTION OF PARASITE RECRUDESCENCE**

Authors: Cranfield, Michael R., Graczyk, Thaddeus K., Beall, Frederick B., Ialeggio, Donna M., Shaw, Melvin L., et al.

Source: Journal of Wildlife Diseases, 30(3) : 372-376

Published By: Wildlife Disease Association

URL: <https://doi.org/10.7589/0090-3558-30.3.372>

---

BioOne Complete ([complete.BioOne.org](https://complete.BioOne.org)) is a full-text database of 200 subscribed and open-access titles in the biological, ecological, and environmental sciences published by nonprofit societies, associations, museums, institutions, and presses.

Your use of this PDF, the BioOne Complete website, and all posted and associated content indicates your acceptance of BioOne's Terms of Use, available at [www.bioone.org/terms-of-use](https://www.bioone.org/terms-of-use).

Usage of BioOne Complete content is strictly limited to personal, educational, and non-commercial use. Commercial inquiries or rights and permissions requests should be directed to the individual publisher as copyright holder.

---

BioOne sees sustainable scholarly publishing as an inherently collaborative enterprise connecting authors, nonprofit publishers, academic institutions, research libraries, and research funders in the common goal of maximizing access to critical research.

## SUBCLINICAL AVIAN MALARIA INFECTIONS IN AFRICAN BLACK-FOOTED PENGUINS (*SPHENISCUS DEMERSUS*) AND INDUCTION OF PARASITE RECRUDESCENCE

Michael R. Cranfield,<sup>1</sup> Thaddeus K. Graczyk,<sup>2</sup> Frederick B. Beall,<sup>1</sup> Donna M. Ialeggio,<sup>1</sup> Melvin L. Shaw,<sup>1</sup> and Mary L. Skjoldager<sup>1</sup>

<sup>1</sup> The Baltimore Zoo, Druid Hill Park, Baltimore, Maryland 21217

<sup>2</sup> The Johns Hopkins University, School of Hygiene and Public Health, Department of Immunology and Infectious Diseases, 615 North Wolfe Street, Baltimore, Maryland 21205

**ABSTRACT:** The subclinical and clinical *Plasmodium elongatum* and *Plasmodium relictum* infections of captive-reared African black-footed penguins (*Spheniscus demersus*) were evaluated in nine adult and 29 juvenile penguins in the Baltimore Zoo (Maryland, USA) during summer 1988 and winter 1989. Two diagnostic methods were used: Giemsa-stained thin blood films, and subinoculation of penguin blood into 1-day-old Peking ducklings. Chloroquine and primaquine treatment was applied to all parasitemic juvenile penguins. Twenty-nine parasite-free, juvenile penguins were monitored for parasitemia by Giemsa-stained thin blood films every two weeks for 26 weeks of their first outdoor exposure. Eighteen of 29 penguins experienced naturally acquired malaria; 14 were infected with *P. elongatum*, three with *P. relictum*, and one bird had a mixed *P. relictum* and *P. elongatum* infection. Eleven of 18 juveniles became parasitemic again after chloroquine and primaquine treatments. Based on Giemsa-stained thin blood smears and subinoculation of penguin blood into 1-day-old ducklings, performed in a mosquito-free environment in winter, nine adult penguins had no evidence of *Plasmodium* spp. infection. After dexamethasone-induced immunosuppression, four of six of these nonparasitemic adult penguins were found to be infected with *P. relictum* by the blood inoculation method.

**Key words:** Avian malaria, parasite recrudescence, parasite relapse, *Plasmodium relictum*, *Plasmodium elongatum*, African black-footed penguins, *Spheniscus demersus*.

### INTRODUCTION

Avian malarial parasites cause significant mortality in captive penguins in open-air colonies (Fleischman et al., 1968). Due to the persistence of pre-erythrocytic and exoerythrocytic schizogonies, even after inoculation of infected blood (Garnham, 1966), the pathology and clinical signs of disease in *Plasmodium relictum* and *Plasmodium elongatum* infections are associated with the exoerythrocytic infection (Fix et al., 1988). Because of the low parasitemia, the destruction of red blood cells usually does not cause clinical anemia in penguins (Cranfield et al., 1990), and penguins often die without detectable parasitemia (Griner, 1974). In such cases, parasites can be detected by the blood passage from an infected donor to experimental domestic ducklings; this causes the amplification of parasites to detectable levels (Herman et al., 1966).

Cranfield et al. (1990) reported that if

a penguin survives the first infection with avian malaria, its immune system appears to be capable of reducing the number of parasites to subpatent levels. The recrudescence and relapses of malarial parasites have been reported by many workers in various species of wild birds (Bennett et al., 1976; Pierce and Mead, 1978); however, causes of these phenomena were not given. There are no studies on recrudescence or relapses of *P. elongatum* or *P. relictum* in African black-footed penguins (*Spheniscus demersus*). Our objective was to determine whether African black-footed penguins (*S. demersus*) remained subclinically infected with naturally acquired avian malarial parasites after the parasitemia dropped below detection by blood smear.

### MATERIALS AND METHODS

We conducted three experiments: 29 juvenile, captive-reared African black-footed penguins were selected for Experiment I, nine adult pen-

guins were chosen for Experiment II, and six of nine birds from Experiment II were selected for Experiment III. All birds were marked individually by a metal flipper tag with an attached color-coded plastic tape for identification. Juvenile birds selected for Experiment I were hatched in the Baltimore (Maryland, USA) Zoo's hatchery from September 1987 to April 1988, and were kept in controlled mosquito-free conditions until exposure in the open-air colony in early May 1988. The vector-free conditions were maintained according to the protocol of Graczyk et al. (1994a). The 29 penguins were bled every two weeks from mid-May to late October 1988 (Fig. 1) between 1000 and 1100 hr (Stoskopf and Beier, 1979) according to the protocol of Graczyk et al. (1994b). Collection of blood samples and blood processing protocols (slide preparation, staining, examination, parasite identification) followed the procedures of Graczyk et al. (1993). The first three birds diagnosed as parasitemic were transferred from the outdoor exhibition to the vector-free indoor environment. These penguins received chloroquine and primaquine treatment according to the protocol of Graczyk et al. (1994a). Penguins were returned to the main colony in early November 1988. Although in an indoor environment, the three penguins were bled on the same schedule as the penguins in the open-air colony. The same medical treatment also was applied to all the parasitemic penguins in the outdoor exhibition.

For Experiment II, nine adult penguins (6- to 9-yr-old) were randomly selected from the flock of 30 adult birds exposed in the outdoor colony during all summers, and bled every 2 wk during their first outdoor exposure season. Six of nine selected penguins were diagnosed by Giemsa-stained thin film as parasitemic during their first open-air exposure season. Five birds were infected with *Plasmodium elongatum*, and one bird had a mixed *P. elongatum* and *Plasmodium relictum* infection. In December 1988, we tested for avian malarial infections in these adult penguins by Giemsa-stained thin blood smear, and by multiple blood subinoculations (Herman et al., 1966). The subinoculation method was used only when the thin smear method was negative. Two milliliters of jugular blood from each penguin were injected intravenously into each of two ducklings. Ducklings were housed in controlled mosquito-free conditions. After 7 days, 2.0 ml of blood were drawn from each of the ducklings for a blood smear and for a second blood transfer to a second group of 18 1-day-old ducklings. The second group was bled at day 7 post-inoculation (PI) for preparation of thin blood smears. A thin blood smear also was prepared from the first group of ducklings at this time.

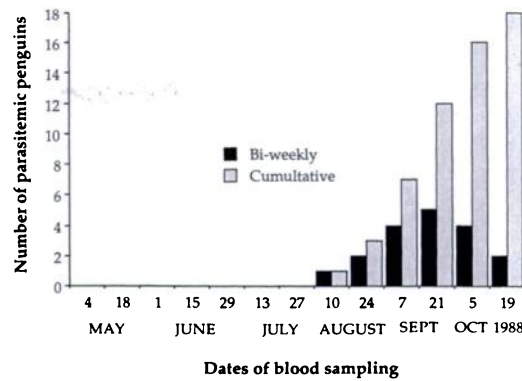


FIGURE 1. Temporal distribution of parasitemia episodes in juvenile African black-footed penguins (*Spheniscus demersus*) during the first outdoor season. Bi-weekly refers to number of penguins parasitemic on a given date when they were bled every two weeks. Cumulative refers to the total numbers of penguins parasitemic up to that date.

In January 1989, six of nine adult penguins from Experiment II were selected at random for Experiment III. Three of the six penguins were parasitemic, and three birds were not parasitemic as determined by Giemsa-stained blood smear during their first outdoor season. One of the three parasitemic penguins had a mixed *P. relictum* and *P. elongatum* infection; two birds were infected with *P. elongatum* (Table 1). All three birds were injected intramuscularly with dexamethasone 21-phosphate (Sigma Chemical Co., St. Louis, Missouri, USA) and 30 mg/per animal of amikacin sulphate (Fort Dodge Laboratories, Inc., Fort Dodge, Iowa, USA) for five consecutive days. Three penguins diagnosed as parasitemic during their first outdoor exposition were injected with 1.0 mg/kg body weight of dexamethasone, and the other three birds received 2.0 mg/kg of dexamethasone. Dexamethasone was used because of its properties for induction of immunosuppression in birds (Isobe and Lillehoj, 1992). Amikacin sulphate was administered to reduce the risk of clinical disease resulting from opportunistic bacterial infection (Brummett, 1983) during the immunosuppression. Seven days after initiation of the dexamethasone treatment, 4.0 ml of blood were drawn from each of the six penguins for the preparation of thin blood smear and for inoculation into two 1-day-old ducklings (2 ml/animal). After 7 days, 2.0 ml of blood from each duckling were drawn for thin blood smears and for inoculation of a second group of 12 ducklings. This procedure also was repeated after 7 days for inoculation of a third group of ducklings. If the thin blood smear from the second

TABLE 1. The results of isodiagnostic blood subinoculation method for nonparasitemic and dexamethasone-immunosuppressed, adult African black-footed penguins (*Spheniscus demersus*).

Parasite species in penguin <sup>a</sup>	Dose of dexamethasone (mg/kg)	Blood passage			Parasite species in ducklings <sup>c</sup>
		First <sup>b</sup>	Second <sup>b</sup>	Third <sup>b</sup>	
<i>P. elongatum</i>	1.0	— <sup>d</sup> —	+ +	ND	<i>P. relictum</i>
<i>P. elongatum</i>	1.0	— —	+ +	ND	<i>P. relictum</i>
<i>P. elongatum</i>					
<i>P. relictum</i>	1.0	— —	+ +	ND	<i>P. relictum</i>
—	2.0	— —	+ —	+ +	<i>P. relictum</i>
—	2.0	— —	— —	— —	—
—	2.0	— —	— —	— —	—

<sup>a</sup> Naturally acquired during the first outdoor summer season and diagnosed by Giemsa-stained thin blood film method.

<sup>b</sup> Two one-day-old Peking ducklings used for each blood transfer.

<sup>c</sup> Diagnosed by Giemsa-stained thin blood film method.

<sup>d</sup> —, no *Plasmodium* spp. observed; +, *Plasmodium* spp. observed; ND, not done.

group of ducklings did not contain parasites, a third blood passage was performed (Table 1). The six dexamethasone-treated penguins were bled for blood smears on the same schedule and in the same manner as experimental ducklings.

### RESULTS

In Experiment I, during the 26-wk outdoor period, 18 of 29 juveniles experienced malaria, while 11 of 29 juveniles remained nonparasitemic. All avian malaria episodes occurred from 10 August to 19 October with the peak of malaria cases in mid-September (Fig. 1). Fourteen of 29 juveniles were infected with *Plasmodium elongatum*, three with *Plasmodium relictum*, and one with both.

In Experiment I, two of the first three parasitemic penguins which were moved from the outdoor exposition to the mosquito-free environment were infected with *P. elongatum*; one bird had a mixed *P. elongatum* and *P. relictum* infection. All three penguins, nonparasitemic after administration of chloroquine became parasitemic again with *P. elongatum* in  $\leq 4$  wk. Fifteen of the remaining 26 juveniles in outdoor exhibition had parasitemia (Fig. 1); eight of them became parasitemic again within 4 wk after the initiation of medical treatment. Thus, 11 of 18 juveniles became parasitemic again after chloroquine and primaquine treatments.

In Experiment II, all nine adults were

negative for *Plasmodium* spp. by the thin blood smear method. All nine adults were *Plasmodium* spp. negative based on two blood passages to the 1-day-old ducklings.

The blood smears from all six penguins injected with dexamethasone (Experiment III) remained negative for 21 days. Also, the first group of ducklings injected with 2.0 ml of blood from six adult penguins were nonparasitemic at day 7 PI, and remained negative through the experiment (Table 1). Three pairs of ducklings in the second blood passage group became parasitemic by day 7 PI with *P. relictum*, and the blood passage to the third group of ducklings was not done (Table 1); one of the remaining ducklings from this group became parasitemic by day 14 PI with *P. relictum* (Table 1). Based on the blood subinoculation method, *Plasmodium* spp. occurred in four of six dexamethasone-treated penguins. Ducklings inoculated with the blood from two penguins which acquired *P. elongatum* infections during the first outdoor season had only *P. relictum* parasitemia. The ducklings inoculated with blood from the penguin with mixed *P. elongatum* and *P. relictum* infection also had only a *P. relictum* parasitemia.

### DISCUSSION

The recurrent recrudescences and relapses of malarial parasites in birds has

been reported by many researchers (Atkinson and van Riper, 1991). We observed that naturally acquired parasites survived chloroquine and primaquine therapy, and under the corticosteroid stimulus they recrudescence into the erythrocytes. Brown (1969) and Garnham (1970) suggested three hypotheses to explain this phenomenon: 1) erythrocytic stages persist and multiply in deep vascular sites and subpatent parasite populations may emerge during the decline of nonsterilizing immunity (Sergent and Sergent, 1956) causing parasite relapses; 2) exoerythrocytic stages continuously release merozoites into the circulating blood, and these allow parasite populations to recover when premunition to them declines (parasite recrudescence); and 3) dormant sporozoites or pre-erythrocytic forms survive in endothelial tissues and later cause parasite recrudescence under a specific stimulus (Griner, 1974). We observed that penguins naturally infected and medically treated for malarial parasites were negative by thin blood smear and blood subinoculation; we observed no parasites after two blood passages to 1-day-old ducklings. However, according to the sensitivity of the Giemsa-stained blood film (Stoskopf and Beier, 1979), and blood subinoculation method (Herman et al., 1966) we should have observed *Plasmodium* spp. if the second hypothesis was true. Therefore, it seems more likely that infected erythrocytes persisted in deep vascular sites in penguins or dormant sporozoites and pre-erythrocytic forms of malarial parasites survived in the endothelial tissues of African penguins. Upon corticosteroid therapy, the parasites may have recrudescence in the penguin hemopoietic tissue, and multiplied in experimentally infected ducklings. Persistence of pre-erythrocytic (post-sporozoite) forms of *Plasmodium relictum* in pigeons (*Columba livia*) has been suggested by Huff (1951).

Based on the positive blood subinoculation results for four of six dexamethasone-treated penguins, we conclude that

the invasion of red blood cells is an effect associated with the glucocorticoid-mediated immunosuppression. Dexamethasone-treated birds exhibit a marked decrease in the number of lymphocytes and monocytes (Gross et al., 1979) and decreases of cell-mediated immunity (CMI) (Isobe and Lillehoj, 1992). Rank and Weidanz (1976) demonstrated that immunity to reinfection of chickens with *Plasmodium gallinaceum* occurred in the absence of detectable B-cell function indicating that nonsterilizing immunity (Sergent and Sergent, 1956) is an antibody-independent phenomenon and requires CMI. Thus the effect of dexamethasone on subclinically infected penguins can be explained by debilitating the processes of CMI controlling the pre-erythrocytic parasites in the endothelial tissues. The results of the present study indicate that African black-footed penguins can be subclinically infected with *P. relictum* and clinically infected with *Plasmodium elongatum*.

One striking observation in our study was that penguins which experienced the recrudescence of malarial parasites had been treated for ten days with primaquine. Primaquine inhibits mitochondrial respiration of the primary and secondary liver stages of human malarial parasites (Contacos, 1973). However, pre-erythrocytic and exoerythrocytic stages of *P. relictum* and *P. elongatum* inhabit the endothelial tissue of all organs of penguins (Fleischman et al., 1968). As seen, the parasites may survive the primaquine therapy. Based on our results, we believe that antimalarial therapy based on human infant treatment schedules (Stoskopf and Beier, 1979) is not adequate to eliminate the exoerythrocytic stages of *Plasmodium* spp. parasites.

#### ACKNOWLEDGEMENTS

We gratefully acknowledge the staff at the African penguin facility: Steven Sarro, Katharine Bennett, Shelby Strickler, Gina Johnson, and Danielle Heyl for their dedication to this study. We thank William L. Nicholson for consultation. This study received financial support from

the Baltimore Zoo Executive Director, Brian A. Rutledge (The Maryland Zoological Society) and from the AKC Fund of New York.

#### LITERATURE CITED

- ATKINSON, C. T., AND C. VAN RIPER III. 1991. Pathogenicity and epizootiology of avian hematozoa: *Plasmodium*, *Leucocytozoon*, and *Haemoproteus*. In *Bird-parasite interactions; ecology, evolution and behavior*, J. L. Loye, and M. Zuk (eds.). Oxford University Press, New York, New York, pp. 20–48.
- BENNETT, G. F., E. C. GREINER, M. F. CAMERON, AND C. M. HERMAN. 1976. Hematozoos de aves paseriformes silvestres muestradas en años sucesivos. *Boletín de la Dirección de Malariología y Saneamiento Ambiental* 16: 313–319.
- BROWN, I. N. 1969. Immunological aspects of malaria infection. *Advances in Immunology* 11: 267–349.
- BRUMMETT, R. 1983. Animal model of aminoglycoside antibiotic ototoxicity. *Review of Infectious Diseases, Supplement 2*: 294–303.
- CONTACOS, P. G. 1973. Five day primaquine therapy—An evaluation of radical curative activity against vivax malaria infection. *American Journal of Tropical Medicine and Hygiene* 22: 693–695.
- CRANFIELD, M. R., M. L. SHAW, F. B. BEALL, M. L. SKJOLDAGER, AND D. M. IALEGGIO. 1990. A review and update of avian malaria in the African penguin (*Spheniscus demersus*). *Proceedings of the American Association of Zoo Veterinarians*, pp. 234–248.
- FIX, A. S., C. WATERHOUSE, E. C. GREINER, AND M. K. STOSKOPF. 1988. *Plasmodium relictum* as a cause of avian malaria in wild-caught Magellanic penguins (*Spheniscus magellanicus*). *Journal of Wildlife Diseases* 24: 610–619.
- FLEISCHMAN, R. W., W. J. L. SLADEN, AND E. C. MELBY. 1968. Malaria (*Plasmodium elongatum*) in captive African penguins (*Spheniscus demersus*). *Journal of the American Veterinary Medical Association* 153: 928–935.
- GARNHAM, P. C. C. 1966. *Malaria parasites and other Haemosporidia*. Blackwell Scientific Publications, Oxford, England, 1114 pp.
- . 1970. Primate malaria. In *Immunity to parasitic animals*, Vol. 2., G. J. Jackson and I. Singer (eds.). Appleton-Century-Crofts, New York, New York, pp. 767–791.
- GRACZYK, T. K., M. C. CRANFIELD, AND C. J. SHIFF. 1993. ELISA method for detecting anti-*Plasmodium relictum* and anti-*Plasmodium elongatum* antibody in infected duckling sera using *Plasmodium falciparum* antigens. *The Journal of Parasitology* 79: 879–885.
- , M. L. SHAW, M. R. CRANFIELD, AND F. B. BEALL. 1994a. Hematologic characteristics of avian malaria cases in African black-footed penguins (*Spheniscus demersus*) during the first outdoor exposure season. *The Journal of Parasitology* 80: 302–308.
- , M. R. CRANFIELD, M. L. SKJOLDAGER, AND M. L. SHAW. 1994b. An ELISA for detecting anti-*Plasmodium* spp. antibodies in African black-footed penguins (*Spheniscus demersus*). *The Journal of Parasitology* 80: 60–66.
- GRINER, L. A. 1974. Avian malaria in penguins. *Advances in Veterinary Science and Comparative Medicine* 18: 251–271.
- GROSS, W. B., P. B. STEGEL, AND R. T. DUBOIS. 1979. Some effects of feeding corticosterone to chickens. *Poultry Science* 59: 516–522.
- HERMAN, C. M., J. O. KNISLEY, AND E. L. SNYDER. 1966. Subinoculation as a technique in the diagnosis of avian *Plasmodium*. *Avian Diseases* 10: 541–547.
- HUFF, C. G. 1951. Observation on the pre-erythrocytic stages of *Plasmodium relictum*, *Plasmodium cathemertum*, and *Plasmodium gallinaceum* in various birds. *The Journal of Infectious Diseases* 88: 17–26.
- ISOBE, T., AND H. S. LILLEHOJ. 1992. Effect of corticosteroids on lymphocyte subpopulations and lymphokine secretion in chickens. *Avian Diseases* 36: 590–596.
- PIERCE, M. A., AND C. J. MEAD. 1978. Hematozoa of British birds III. Spring incidence of blood parasites of birds from Hertfordshire, especially returning migrants. *Journal of Natural History* 12: 337–340.
- RANK, R. G., AND W. P. WEIDANZ. 1976. Nonsterilizing immunity in avian malaria: An antibody-independent phenomenon. *Proceedings of the Society for Experimental Biology and Medicine* 151: 257–259.
- SERGEANT, E., AND E. SERGENT. 1956. History of the concept of “relative immunity” or “premunition” correlated to latent infection. *Indian Journal of Malariology* 10: 53–80.
- STOSKOPF, M. K., AND J. R. BEIER. 1979. Avian malaria in African black-footed penguins. *Journal of the American Veterinary Medical Association* 175: 944–947.

Received for publication 10 September 1993.