



## **Lentivirus Infection in an African Lion: A Clinical, Pathologic and Virologic Study**

Authors: Poli, Alessandro, Abramo, Francesca, Cavicchio, Paolo, Bandecchi, Patrizia, Ghelardi, Emilia, et al.

Source: Journal of Wildlife Diseases, 31(1) : 70-74

Published By: Wildlife Disease Association

URL: <https://doi.org/10.7589/0090-3558-31.1.70>

---

BioOne Complete ([complete.BioOne.org](https://complete.BioOne.org)) is a full-text database of 200 subscribed and open-access titles in the biological, ecological, and environmental sciences published by nonprofit societies, associations, museums, institutions, and presses.

Your use of this PDF, the BioOne Complete website, and all posted and associated content indicates your acceptance of BioOne's Terms of Use, available at [www.bioone.org/terms-of-use](https://www.bioone.org/terms-of-use).

Usage of BioOne Complete content is strictly limited to personal, educational, and non - commercial use. Commercial inquiries or rights and permissions requests should be directed to the individual publisher as copyright holder.

---

BioOne sees sustainable scholarly publishing as an inherently collaborative enterprise connecting authors, nonprofit publishers, academic institutions, research libraries, and research funders in the common goal of maximizing access to critical research.

## Lentivirus Infection in an African Lion: A Clinical, Pathologic and Virologic Study

Alessandro Poli,<sup>1</sup> Francesca Abramo,<sup>1</sup> Paolo Cavicchio,<sup>3</sup> Patrizia Bandecchi,<sup>1</sup> Emilia Ghelardi,<sup>2</sup> and Mauro Pistello,<sup>2</sup> <sup>1</sup> Department of Animal Pathology, University of Pisa, 56124 Pisa, Italy; <sup>2</sup> Department of Biomedicine, University of Pisa, 56127 Pisa, Italy; and <sup>3</sup> Zoological Garden of Pistoia, 51123 Pistoia, Italy.

**ABSTRACT:** In May 1991, clinical, pathologic, and virologic investigations were carried out on an 8-yr-old male lion (*Panthera leo*), with recurrent infections, in captivity with two lionesses in the Zoological Garden of Pistoia, Tuscany, Italy. The lion had severe pneumonia, neutropenia, thrombocytopenia, and an increase in blood urea nitrogen and creatinemia; in spite of therapy, it died within 3 months. At necropsy, the animal had a lymphoma and other lesions similar to those described in feline immunodeficiency virus-infected cats. We identified FIV *gag*-sequence using PCR amplification of lymph node tissues.

**Key words:** African lion, *Panthera leo*, lentivirus infection, FIV-related virus, case report.

Retroviruses infect nondomestic felids. Feline leukemia virus (FeLV) infection has been reported in wild felids (Citino, 1986) and antibodies against feline syncytium forming virus (FeSFV) were detected in 14 of 124 serum samples from captive nondomestic felids (Lutz et al., 1992).

Cross-reactive antibodies to feline immunodeficiency virus (FIV) have been found in captive wild felids (Barr et al., 1989; Lutz et al., 1992; Olmsted et al., 1992), and in free-ranging populations of large cats including lions (*Panthera leo leo*) from East Africa, cheetahs (*Acinonyx jubatus*) of the Serengeti ecosystem, and in free roaming bobcat (*Felis rufus*) and puma (*Felis concolor*) populations throughout North America (Barr et al., 1989; Olmsted et al., 1992).

Puma lentiviruses (PLV) were isolated from several Florida (USA) panthers (*F. concolor coryi*), confirming the existence of these viruses among wild felids (Olmsted et al., 1992). Unsuccessful transmission experiments from two FIV-seropositive lions into specific pathogen-free domestic cats is evidence that the lion virus may be highly adapted to their hosts (Lutz et al., 1992).

We report the clinical and pathologic findings observed in an FIV-seropositive lion that died in captivity, and detection of FIV *gag*-sequence from its tissues.

An 8-yr-old male African lion (*Panthera leo*) was housed in captivity with two lionesses, in the Zoological Garden of Pistoia, Tuscany, Italy, since May 1991. The lion developed progressive wasting initially characterized by anorexia, depression, and weight loss. Blood samples obtained by vena cephalica antebanchii puncture were collected into tubes with or without potassium ethylenediaminetetraacetic acid and subjected to clinical tests carried out with a cellcounter (Hemacomp 10, SEAC, Florence, Italy). Blood urea nitrogen (BUN), serum creatinine, aspartate aminotransferase (AST), and alanine aminotransferase (ALT) concentrations were determined by spectrophotometric analysis (LKB Biochrom Ltd., Cambridge, United Kingdom) with commercial assays (Texas International Laboratories, Inc., Houston, Texas (USA)). Serum protein electrophoresis was done on cellulose acetate strips (Cellogel, Chemetron, Milan, Italy) at pH 9.0. Serum samples of 1.5  $\mu$ l volume were analyzed at 200 V for 35 min, stained with ponceau S (Sigma Chemical Company, St. Louis, Missouri, USA) in 5% acetic acid and rinsed with 5% acetic acid. After clearing the strips with 35% diacetone alcohol and 5% citric acid the strips were dried at 80 C for 6 min and the separated proteins were quantified using a Multipolar scanning densitometer (Chemetron). The lion had a leukopenia (3,700 cells/mm<sup>3</sup>) and thrombocytopenia (41,000 platelets/mm<sup>3</sup>), while red blood cell count was in normal range (8,340,000 cells/mm<sup>3</sup>) (Fowler, 1986). Marked increases in BUN (285 mg/dl) and creatinine (5.3 mg/dl)

values were observed, as well as increased AST (209 mU/ml) and ALT (75 mU/ml) concentrations. In spite of repeated treatment with 10% glucose and amino acid (Freamine 3, Baxter Lab, Trieste, Italy) infused subcutaneously, the signs progressively worsened, and the lion developed a severe pneumonia after 2 mo. A hemolytic Gram-positive bacterium was isolated on blood agar plates (Becton Dickinson, Oxford, United Kingdom) from blood samples and then identified as *Streptococcus pneumoniae* (Carter and Cole, 1990); it was ampicillin-sensitive as determined with Kirby-Bauer test (Bauer et al., 1966). The lion was treated with 4 g/day of ampicillin (Farmitalia, Carlo Erba, Milan, Italy) and in spite of antibiotic therapy it died 20 days later.

Presence of anti-FIV, anti-FeLV, and anti-feline infectious peritonitis (FIP) virus antibodies was determined in sera collected by vena cephalica antebanchii puncture from the sick lion and the two lionesses, using commercially available enzyme-linked immunosorbent (ELISA) kits for anti-FIV and anti-FeLV antibodies (CITE Combo FIV-FeLV; Agritech Systems, Portland, Maine, USA), and for anti-FIP antibodies (Diasystems Celisa FIP, Tech America, Omaha, Nebraska, USA), at 6-mo-intervals. Western blotting (WB) analysis for FIV antibody was performed using cell-free FIV antigen produced from supernatant of persistently infected FL4 cells (Yamamoto et al., 1991) and horseradish peroxidase-conjugated rabbit anti-cat IgG serum (Bethyl Laboratories, Montgomery, Texas) (Poli et al., 1992). Controls included standard FIV-antibody positive and FIV-antibody negative cat sera. Virus neutralization assays were performed with two-fold serum dilutions from the lion and lionesses in duplicate wells of 24-well plates (Tozzini et al., 1992).

Complete necropsy was conducted and tissues samples from axillary, popliteal, hepatic, mediastinic lymph nodes, as well as the kidneys, spleen, liver, intestine, adrenal glands, pancreas, lung, heart, bone

marrow, and central nervous system were fixed in 10% buffered formalin and embedded in paraffin. Four- $\mu$ m thick sections, were stained with hematoxylin-eosin, Masson's trichrome, Jones' periodic-acid silver methenamine, periodic-acid Schiff, and Grocott stains (Luna, 1960).

Polymerase chain reaction (PCR) using FIV *gag* primers was carried out on spleen, kidney, salivary glands, lung, hepatic, mesenteric, inguinal, and axillary lymph node tissues as described by Matteucci et al. (1993). The primers used, deduced from the FIV Petaluma strain (Pedersen et al., 1987), spanned the whole FIV *gag* 24 region, 675 base pairs (bp) long, which is both conserved and specific of the FIV isolates. This was consistently demonstrated by the PCR positivity of DNA from cells infected by several FIV isolates, and by the lack of amplification of DNA from cells infected by caprine arthritis encephalitis virus, equine infectious anemia virus and human immunodeficiency virus (data not shown).

At necropsy, the lion had poor nutritional condition and there was severe periodontitis and oral ulcerations. Axillary, mediastinal, and hepatic lymph nodes were markedly enlarged, while the other lymph nodes appeared normal or smaller than normal; the spleen also was reduced in size. A mild catarrhal enteritis was observed, the kidneys were slightly reduced in volume and the liver was slightly swollen and dark. Pleural thickening, large areas of pulmonary alveolar emphysema, and areas of consolidation were observed. The bone marrow was infiltrated by adipose tissue, while all the other organs appeared normal.

The enlarged lymph nodes had a uniform population of lymphoid cells with a small amount of cytoplasm, small round nuclei with uniform chromatin and scanty mitosis infiltrating the lymph node capsule. According to the cell architecture, mitotic rate, and cell type, this lymphoma was classified as a diffuse small lymphocytic lymphoma (Carter et al., 1986). For-

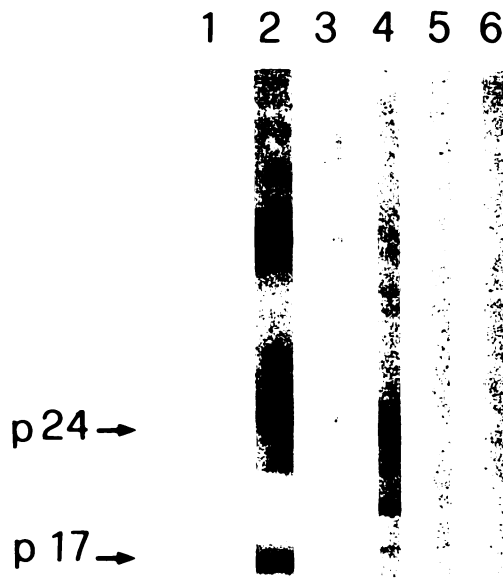


FIGURE 1. Western blot analysis of serum from a noninfected domestic cat (lane 1), FIV-infected domestic cats (lanes 2 and 3), male lion (lane 4), and two lionesses (lanes 5 and 6).

malin-fixed tissue specimens have been deposited into the archives of the Armed Forces Institute of Pathology, Washington, D.C. (No. 2419064).

In other lymph nodes some lymphoid follicles were reduced in size, while others contained hyalinized eosinophilic material. Histiocytic cells and hemosiderin-containing macrophages frequently were present in collapsed cortical sinuses and in medullary areas, where numerous plasma cells also occurred. Splenic changes were characterized by marked depletion of periarteriolar lymphoid sheaths, while the red pulp contained numerous histiocytic cells, hemosiderin-containing macrophages, and plasma cells. Diffuse interstitial infiltration of lymphocytes and plasma cells, mesangial increase with occasional glomerulosclerosis, tubular epithelial cells degeneration, and foci of mineralization were present in the kidney. In the liver sinusoidal engorgement, periportal infiltrates of lymphocytes and plasma cells, biliary stasis, and fibrosis were observed. Infiltrates also were present in the intestinal

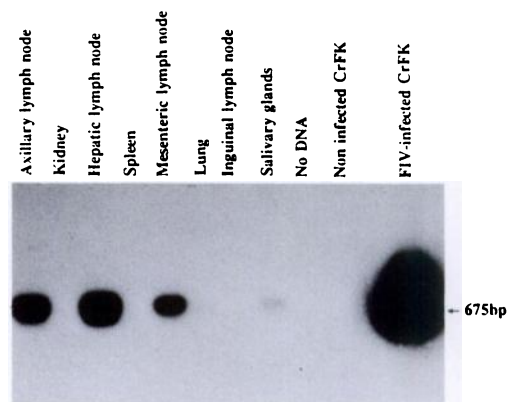


FIGURE 2. Southern blot analysis of PCR of FIV-*gag* p24 amplified products.

wall between mucosa and muscularis mucosa, and around oral ulcers. Myeloid precursors, erythroblasts and megakaryocytes were markedly reduced in the bone marrow and, in some cases, replaced by a uniform population of lymphoid cells. In the lung, there were large areas of intraalveolar fibrinous exudate, red cells, frequent hyaline membranes and scanty alveolar macrophages. These areas were surrounded by areas of emphysema. Widespread interstitial fibrosis, hyperplasia of smooth muscle, thickening of septa by lymphocytes and plasma cells, and presence of foci of necrosis with calcification also were observed.

Antibodies to FIV were detected in the male lion by immunoenzymatic assay and confirmed by WB analysis. Based on the WB pattern, the lion serum had antibodies against the p24 antigen and, to a lesser extent, for p17 (Fig. 1). The immunoenzymatic assays used were positive for anti-FIV antibodies and negative for p27 FeLV antigen and anti-FIP virus antibodies. Sera from the two lionesses were positive to the commercial assay for FIV, but negative by WB analysis. No FIV-neutralizing antibodies were detected in any examined lions.

Hepatic, axillary, and mesenteric lymph nodes were strongly positive for PCR, while a weak positive signal also was obtained

from parotid gland (Fig. 2). The other tissue specimens examined were negative.

The clinical signs and hematologic abnormalities observed in the sick lions, even if nonspecific, resembled those frequently reported in FIV infection of cats; these include leukopenia, generalized lymphadenopathy, and recurrent infections (Pedersen, 1993). Furthermore, the male lion had a lymphoid neoplasm, histologic changes observed in lymph nodes not involved in the proliferative disorders, and diffuse interstitial lymphocyte and plasma cells infiltrates in his kidneys, liver, and lungs. These features, although not pathognomonic, frequently are reported in advanced FIV-infections (Pedersen, 1993). The detection of FIV *gag*-sequence by PCR analysis in different organs and FIV-seropositivity further support the infection of the male lion by FIV or a related agent.

Olmsted et al. (1992) and Lutz et al. (1992) described the presence of cross-reactive antibodies to FIV in several free ranging population of East African lions as well as in lions from zoos. To our knowledge, this is the first report in a lion of clinical and pathological features resembling those described in FIV-infected cats. There was a close relationship between the *gag* p24 protein of the putative lion virus and of FIV both for nucleotide sequence as demonstrated by the successful PCR amplification with FIV *gag*-specific primers in tissues and for protein structure, as demonstrated by serologic cross-reactivity.

Recently Olmsted et al. (1992) reported the isolation of a lentivirus from Florida panthers. This virus, called puma lentivirus (PLV) was sequenced in the *pol* gene and the divergence from other viruses in the lentivirus genus was estimated. Phylogenetic analysis demonstrated a close relationship between FIV and PLV (Olmsted et al., 1992) and it is compatible with the idea of a radiation from a hypothetical common ancestral felid progenitor into different localities which subsequently evolved into separate species.

Based on serological findings exposure

to FIV-related virus is widespread in non-domestic felid species and the incidence is as high as 90% in certain populations of African lion (Lutz et al., 1992). More extensive investigations are needed to study the consequence of FIV related virus infection in nondomestic felidae in nature.

This research was supported by grants from Ministero della Sanità-Istituto Superiore di Sanità "Progetto Allestimento Modelli Animali per l'AIDS," Rome, Italy.

#### LITERATURE CITED

- BARR, M. C., P. P. CALLE, M. E. ROELKE, AND F. W. SCOTT. 1989. Feline immunodeficiency virus infection in nondomestic felids. *Journal of Zoo and Wildlife Medicine* 20: 265-272.
- BAUER, A. W., W. M. KIRBY, J. C. SHERRIS, AND M. TURK. 1966. Antibiotic susceptibility testing by standardized single disk method. *American Journal of Clinical Pathology* 45: 493.
- CARTER, G. R., AND J. R. COLE. 1990. Diagnostic procedures in veterinary bacteriology and mycology, 5th ed. Academic Press, Inc., San Diego, California, pp. 213-217.
- CARTER, R. F., V. E. O. VALLI, AND J. H. LUMSDEN. 1986. The cytology, histology and prevalence of cell types in canine lymphoma classified according to the National Cancer Institute working formulation. *Canadian Journal of Veterinary Research* 50: 154-164.
- CITINO, S. B. 1986. Transient FeLV viremia in a clouded leopard. *Journal of Zoo Animal Medicine* 17: 5-7.
- FOWLER, M. E. 1986. Felidae. In *Zoo and wild animal medicine*, 2nd ed., M. E. Fowler (ed.). W. B. Saunders Company, Philadelphia, Pennsylvania, pp. 831-841.
- LUNA, L. G. 1960. Manual of histologic and special staining techniques of the Armed Forces Institute of Pathology, 2nd ed. McGraw-Hill Book Company, New York, New York, pp. 31, 63, 132, 190.
- LUTZ, H., E. ISENBUGEL, R. LEHMANN, R. H. SABAPARA, AND C. WOLFENBERGER. 1992. Retrovirus infections in non-domestic felids: Serological studies and attempts to isolate a lentivirus. *Veterinary Immunology and Immunopathology* 35: 215-224.
- MATTEUCCI, D., F. BALDINOTTI, P. MAZZETTI, M. PISTELLO, P. BANDECCHI, R. GHILARDUCCI, A. POLI, F. TOZZINI, AND M. BENDINELLI. 1993. Detection of feline immunodeficiency virus in saliva and plasma by cultivation and polymerase chain reaction. *Journal of Clinical Microbiology* 31: 494-501.
- OLMSTED, R. A., R. LANGLEY, M. E. ROELKE, R. M. GOEKEN, D. ADGER JOHNSON, J. P. GOFF, J. P.

- ALBERT, C. PACKER, M. K. LAURENSEN, T. M. CARO, L. SCHEEPERS, D. E. WILDT, M. BUSH, J. S. MARTENSON, AND S. J. O'BRIEN. 1992. Worldwide prevalence of lentivirus infection in wild feline species: Epidemiologic and phylogenetic aspects. *Journal of Virology* 66: 6008-6018.
- PEDERSEN, N. C. 1993. Feline immunodeficiency virus infection. *In* *The retroviruses*, Y. A. Levy (ed.). Plenum Press, New York, New York, pp. 181-188.
- , E. W. HO, M. L. BROWN, AND J. K. YAMAMOTO. 1987. Isolation of a T-lymphotropic virus from domestic cats with an immunodeficiency-like syndrome. *Science* 235: 790-793.
- POLI, A., C. GIANNELLI, M. PISTELLO, L. ZACCARO, D. PIERACCI, M. BENDINELLI, AND G. MALVALDI. 1992. Detection of salivary antibodies in cats infected with feline immunodeficiency virus. *Journal of Clinical Microbiology* 30: 2038-2041.
- TOZZINI, F., D. MATTEUCCI, P. BANDECCHI, F. BALDINOTTI, A. POLI, M. PISTELLO, K. H. J. SIEBELINK, L. CECCHERINI-NELLI, AND M. BENDINELLI. 1992. Simple *in vitro* methods for titrating feline immunodeficiency virus (FIV) and FIV neutralizing antibodies. *Journal of Virological Methods* 37: 241-252.
- YAMAMOTO, J. K., C. D. ACKLEY, H. ZOCHLINSKI, H. LOUIE, E. PEMBROKE, M. TORTEN, H. HANSEN, R. MUNN, AND T. OKUDA. 1991. Development of IL-2-independent feline lymphoid cell lines chronically infected with feline immunodeficiency virus: Importance for diagnostic reagents and vaccines. *Intervirology* 32: 361-375.

*Received for publication 17 September 1993.*