

Notoedric Mange in an Ocelot (*Felis pardalis*) from Southern Texas

Authors: Pence, Danny B., Tewes, Michael E., Shindle, David B., and Dunn, Dale M.

Source: Journal of Wildlife Diseases, 31(4) : 558-561

Published By: Wildlife Disease Association

URL: <https://doi.org/10.7589/0090-3558-31.4.558>

BioOne Complete (complete.BioOne.org) is a full-text database of 200 subscribed and open-access titles in the biological, ecological, and environmental sciences published by nonprofit societies, associations, museums, institutions, and presses.

Your use of this PDF, the BioOne Complete website, and all posted and associated content indicates your acceptance of BioOne's Terms of Use, available at www.bioone.org/terms-of-use.

Usage of BioOne Complete content is strictly limited to personal, educational, and non - commercial use. Commercial inquiries or rights and permissions requests should be directed to the individual publisher as copyright holder.

BioOne sees sustainable scholarly publishing as an inherently collaborative enterprise connecting authors, nonprofit publishers, academic institutions, research libraries, and research funders in the common goal of maximizing access to critical research.

Notoedric Mange in an Ocelot (*Felis pardalis*) from Southern Texas

Danny B. Pence,^{1,3} Michael E. Tewes,² David B. Shindle,² and Dale M. Dunn,¹ ¹ Department of Pathology, Texas Tech University Health Sciences Center, 3601 4th Street, Lubbock, Texas 79430, USA; ² Caesar Kleberg Wildlife Research Institute, Texas A&M University, Campus Box 218, Kingsville, Texas 78363, USA; ³ Author to whom reprint requests should be addressed

ABSTRACT: Notoedric mange was diagnosed in a free-ranging adult male ocelot (*Felis pardalis*) found dead in April 1994 in southern Texas (USA). The emaciated carcass had no body fat. The heart was enlarged and flaccid. There was a nonpurulent serosanguineous pericardial and peritoneal exudate. Severe encrusted skin lesions and alopecia extended from the head posteriorly to the shoulders. The forelegs and feet were less severely affected. We observed a massive infection of *Notoedres cati* in skin scrapings. Epidermal lesions included hyperkeratosis and parakeratosis with necrotic debris and foci of acute inflammatory cells surrounding mites and their eggs in the stratum corneum. There was mild acanthosis and spongiosis of the stratum germinativum, but no chronic inflammation in the dermis. This is the first confirmed case in the ocelot, but notoedric mange has been reported from the bobcat (*Felis rufus*) in southern Texas. Thus, notoedric mange could pose an additional threat to the already endangered remnant population of the ocelot.

Key words: Case report, *Felis pardalis*, mortality, *Notoedres cati*, notoedric mange, ocelot.

The ocelot (*Felis pardalis*) is a 7 to 11 kg spotted cat primarily distributed in tropical Latin American barely ranging into the United States (Tewes and Schmidly, 1987). Because its preferred habitat of dense chaparral has been reduced to <5% of the Lower Rio Grande Valley (LRGV) of Texas (USA), there remains only an endangered remnant of the ocelot population, estimated at 80 to 120 individuals (Tewes and Everett, 1982). In Latin America, the ocelot is endangered because its spotted pelt is of commercial value (Tewes and Schmidly, 1987).

The reported diseases of ocelots, mostly from captive individuals, are listed in Tewes and Schmidly (1987). Whereas captive animals have a number of common feline diseases, we found no reports of in-

cidents of mortality in free-ranging animals. Herein, we document a case history in a free-ranging ocelot from the southern Texas brushlands that we believe died of severe emaciation and other factors secondary to notoedric mange resulting from a naturally acquired infection of *Notoedres cati*.

An adult male (age estimated at >5 yr) ocelot was found dead beside a dirt road on the Yturria Ranch in Kenedy County, Texas (26°38'N, 97°43'W) on 2 April 1994 within hours of death. The animal had been radio-collared 19 April 1991 by the junior author (MET) as part of the Feline Research Program (Texas A&M University-Kingsville, Kingsville, Texas), and still wore the nonfunctional radio collar. At the time of radio-collaring in 1991 the cat weighed 9.85 kg, measured 1,110 mm in total length, and had no evidence of mange or other diseases.

The carcass was frozen and stored at -5 C at Texas A&M University-Kingsville. It then was transported to Texas Tech University (Health Sciences Center, Lubbock, Texas) where it was thawed and necropsied. Activities in regard to movement and handling of this carcass were under the authority of Federal Fish and Wildlife Permit PRT-676811 for endangered/threatened species (U.S. Fish and Wildlife Service, Region 2, Albuquerque, New Mexico, USA) and Texas Parks and Wildlife Department Scientific Permit SPR0190-600 (Texas Parks and Wildlife Department, Austin, Texas).

Skin scrapings were treated with 10% KOH and examined microscopically for mites, or preserved in 70% ethyl alcohol for later study. Small (1 cm²) skin biopsies were removed and preserved in 10% for-

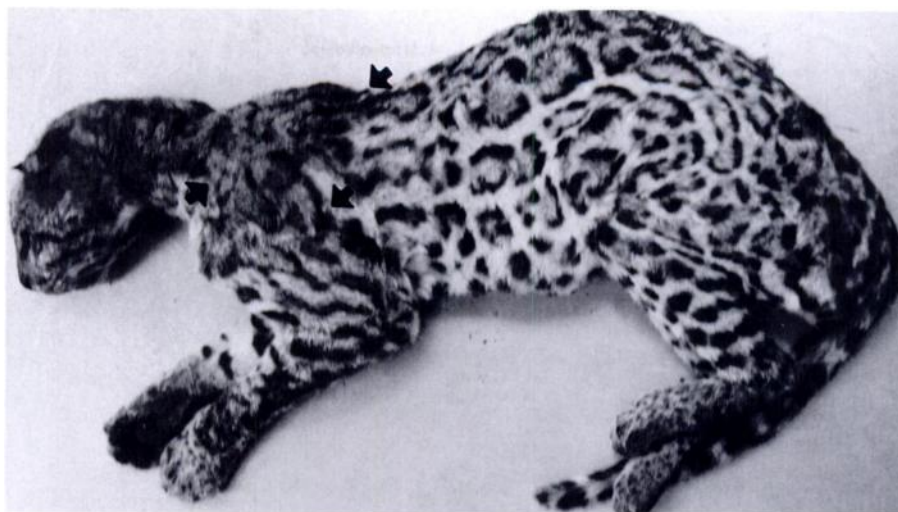

FIGURE 1. Carcass of a mature male ocelot from southern Texas infected with notoedric mange on the head, neck, shoulders, and forepaws. Note the line of demarkation between normal and infected areas (arrows) and the apparent emaciation.

malin buffered at pH 7.2. After fixation for 24 hr, tissue was embedded in paraffin; sections were cut at 4 to 6 μm , stained with hematoxylin and eosin and mounted on glass slides. Mites were examined as whole mounts in Hoyer's medium (Krantz, 1971) and identified according to the description in Pence (1984). Specimens of *N. cati* from the ocelot are deposited in the U.S. National Museum and U.S. Department of Agriculture Acari Collection (Systematic Entomology Laboratory, U.S. Department of Agriculture, Agriculture Research Service, Beltsville, Maryland, USA).

The severely emaciated carcass (Fig. 1) weighed 7.92 kg. Fly eggs were deposited about the mouth, eyes, ears, and abdomen. The eyes were sunken into the sockets and dehydrated, but without post mortem tympany. There was no external evidence of traumatic injury. Because of the minimal post mortem changes in the warm weather of the LRGV, we believe that the animal was dead only a few hours prior to its discovery.

The dorsal and lateral aspects of the head (muzzle, face, crown, and scalp) and neck extending posteriorly to the scapular level of the apex of the shoulders had partial to

almost complete alopecia (Fig. 1) and thickened wrinkled skin with dense gray encrustations (Fig. 2). Skin lesions and alopecia were less severe but noticeable on the ventral aspects of the head, neck, forepaws, feet, and lateral aspects of the shoulders (Fig. 1). Surface excoriation or exudative lesions of the affected skin were not seen (Fig. 2). A pungent odor reminiscent of mercaptans emanated from the carcass. A dry blood-tinged exudate occurred in the ears and nose. Many of the teeth were extensively damaged, badly worn, or missing, especially the canines and insisors. The entire carcass was extremely emaciated with no external evidence of any body fat and with some indication of muscle atrophy in the large muscles of the fore and hind limbs. The feet appeared normal and all the claws were intact.

The skinned carcass had some muscle atrophy, but had no body fat, and no evidence of traumatic injuries. Cervical lymph nodes were slightly enlarged.

Aside from post mortem autolysis and except for an enlarged and flaccid heart, the remainder of the visceral organs appeared normal, and without any omental, mesenteric, or other visceral fat deposits.



FIGURE 2. Lesions of notoedric mange on the neck of an infected ocelot; note thickened wrinkled gray skin encrustations and marked alopecia.

There was a serosanguineous nonpurulent pleural and peritoneal effusion. The stomach was empty. Except for numerous small granulomatous lesions in the stomach, the remainder of the gastrointestinal tract appeared normal; the posterior small and large intestines contained formed fecal masses consisting mostly of rodent bones and hair. Because of the low species richness and intensities, helminth infections were considered incidental; these results will be reported elsewhere.

Histologically, the skin had extensive hyperkeratosis and parakeratosis of the stratum corneum appearing as excoriated accumulations of whorles and layers of keratin interspersed with sheets of degenerate keratinocytes. These surface exfoliations were honeycombed with patches of spongiform or amorphous necrotic debris, degenerating remnants of extruded hair follicles and sebaceous glands, focal masses of acute inflammatory cells (mostly neutrophils), and numerous living and calcified mites and their eggs (Fig. 3). Acari were identified in skin scrapings of areas adjacent to tissue biopsies as *N. cati*. Mites rarely invaded past the stratum germinativum. The stratum germinativum was compressed and atrophic, often with mild acanthosis and spongiosis adjacent to mites

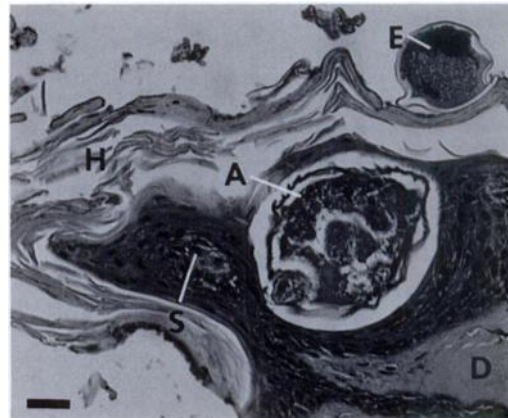


FIGURE 3. Skin lesions of notoedric mange in the ocelot with an adult (A) and egg (E) of *Notoedres cati* localized in the stratum germinativum. Note the layers of keratin (H) resulting from hyperkeratosis of the stratum corneum, spongiosis (S) of the stratum germinativum adjacent to the mite, and absence of inflammation in the dermis (D). Bar = 25 μ m.

and their eggs (Fig. 3). Although the distal parts of the hair shaft in the epidermis was damaged or destroyed, the hair follicles and adnexal structures in the dermis appeared normal. A secondary bacterial infection was not established because only an occasional neutrophil was observed in the upper dermis. In the absence of chronic dermal inflammation, we believe that hair shafts damaged and broken at the epidermal surface probably accounted for the alopecia.

Lesions found incidentally in this cat's stomach were old healed submucosal granulomas, usually covered with normal surface mucosa. Whorles of collagen surrounded remnants of foreign material of plant origin and, in one instance, the embedded proboscises of two acanthocephalans.

We believe that the extensive loss of epidermal function due to infection with *N. cati* on the anterior part of the body was contributory, if not ultimately responsible for the death of this ocelot. Extreme emaciation, peritoneal and pleural effusions, and enlarged flaccid heart are lesions consistent with neurogenic and hypovolemic shock attendant to excessive skin losses, such

as occurs in hyperthermic injuries (Cotran et al., 1994).

The location on the body, pathology, and clinical symptoms of notoedric mange in the ocelot closely resemble that described in a fatal case of *N. cati* infection in the bobcat (*Felis rufus*) from southern Texas by Pence et al. (1982). Both cases and others from bobcats (Pollack, 1951) and captive snow leopards (*Felis uncia*) (Fletcher, 1978) resemble the disease described in domestic cats (Pence, 1984). However, mange lesions seemed unique in the cases reported from wild free-ranging felids because they did not progress past the shoulders before the animals died. Lesions in domestic cats sometimes extend into the ventral abdomen and genital region, with most of the body becoming involved before the cat dies from dehydration (Pence, 1984). An intense pruritis, leading to excoriation of the skin due to self-inflicted trauma from scratching and resulting in secondary pyoderma, also develops in domestic cats (Pence, 1984). This did not occur in the ocelot or bobcat (Pence et al., 1982).

Notoedric mange is a potentially epizootic disease that could result in high mortality in bobcat populations (Penner and Parke, 1954; Pence et al., 1982). High mortality from mange in species with high population abundances, such as sarcoptic mange in the coyote (*Canis latrans*) population from southern Texas, may be compensatory only with other mortality factors, with no net temporal effect on overall population abundance (Pence and Windberg, 1994). Such may be the case with notoedric mange in the bobcat, an abundant species in southern Texas. However, the effects of a notoedric mange epizootic in the remnant ocelot population of southern Texas may not be so benign, because the loss of only a few individuals could be devastating to such a small population.

The Feline Research Program appreciates the support provided by G. C. Hix-

on, the James R. Dougherty, Jr. Foundation, the Rachael and Ben Vaughan Foundation, Texas Parks and Wildlife Department, and the U.S. Fish and Wildlife Service. Technical assistance was provided by M. A. Asleson, J. F. Beltran, and G. T. M. Schildwachter. We are grateful to F. Yturria for providing researchers with access to his ranch.

LITERATURE CITED

- COTRAN, R. S., V. KUMAR, AND S. L. ROBBINS. 1994. Robbins pathologic basis of disease. W. B. Saunders Company, Philadelphia, Pennsylvania, 1,400 pp.
- FLETCHER, K. C. 1978. Notoedric mange in a litter of snow leopards. *Journal of the American Veterinary Medical Association* 173: 1231-1232.
- KRANTZ, G. W. 1971. A manual of acarology. Oregon State University Book Stores, Inc., Corvallis, Oregon, 335 pp.
- PENCE, D. B. 1984. Diseases of laboratory animals. *In* Mammalian diseases and arachnids, W. B. Nutting (ed.). CRC Press, Inc., Boca Raton, Florida, pp. 129-187.
- , AND L. A. WINDBERG. 1994. Impact of a sarcoptic mange epizootic on a coyote population. *The Journal of Wildlife Management* 58: 624-633.
- , F. D. MATTHEWS III, AND L. A. WINDBERG. 1982. Notoedric mange in the bobcat, *Felis rufus*, from south Texas. *Journal of Wildlife Diseases* 18: 47-50.
- PENNER, L. R., AND W. N. PARKE. 1954. Notoedric mange in the bobcat, *Lynx rufus*. *Journal of Mammalogy* 35: 458.
- POLLACK, E. M. 1951. Observations on New England bobcats. *Journal of Mammalogy* 32: 356-358.
- TEWES, M. E., AND D. D. EVERETT. 1982. Status and distribution of the endangered ocelot and jagundi in Texas. *In* Cats of the world: Biology, conservation and management, S. D. Miller and D. D. Everett (eds.). National Wildlife Federation, Washington, D.C., pp. 147-158.
- , AND D. J. SCHMIDLY. 1987. The neotropical felids: Jaguar, ocelot, margay and jagundi. *In* Wild furbearer management and conservation in North America, M. Novak, J. A. Baker, M. E. Obbard, and B. Malloch (eds.). Ontario Ministry of Natural Resources, Toronto, Ontario, Canada, pp. 696-712.

Received for publication 27 February 1995.