

SHORT COMMUNICATIONS

Journal of Wildlife Diseases, 32(1), 1996, pp. 105-108
© Wildlife Disease Association 1996

Osteoporotic Skull Lesions in Moose at Isle Royale National Park

Mary Hindelang and Rolf O. Peterson, School of Forestry and Wood Products, Michigan Technological University, Houghton, Michigan 49931, USA

ABSTRACT: Osteoporotic lesions were evaluated in the skulls of moose (*Alces alces*) collected in Isle Royale National Park, Michigan (USA), from 1958 to 1994. Circular lesions which penetrated the outer table of the skull were distributed over the frontal and nasal bones asymmetrically in both sexes. About 32% of skulls recovered had some porotic lesions with slightly greater prevalence among males.

Key words: *Alces alces*, Isle Royale, moose, osteoporosis, porotic lesions, skulls.

Moose (*Alces alces*) skeletal remains have been collected in Isle Royale National Park, Michigan (USA), (47°55'N, 89°05'W) from 1958 to 1994 during a long term study of wolf (*Canis lupus*)-moose dynamics (Peterson, 1977). Moose carcasses, mostly from wolf-kills, were located in winter by aerial search and in summer during extensive coverage of the island on foot. Recovery of skeletal remains is estimated at about one-third of the total number of dead moose (R. O. Peterson, unpubl.). In many cases only partial skeletons were available for inspection.

Skeletal samples and an autopsy database comprise data from over 2400 moose. Throughout the study, lower mandibles and any bones with lesions were collected. Since 1979, all skulls found have been collected. Sex of each moose was determined by the presence or absence of antlers or antler pedicles. Age was estimated from counts of cementum annuli (Wolfe, 1969). Skeletal remains were examined for osteoarthritis, osteoporosis, periodontal disease, and other bone abnormalities.

Osteoporotic lesions have been observed in the skulls throughout the collection period. The lesions were of various sizes and shapes and were distributed over

the frontal or nasal bones asymmetrically. Of 480 skulls, 87 of 265 males (33%) and 69 of 215 females (32%) had lesions (Fig. 1). Abnormal skulls had generalized porosity of the bone with one to several areas of thinning and pitting on the dorsal surface. Many lesions were circular or ellipsoid in shape measuring 4 mm to 21 mm across and 1 to 5 mm deep. Lesions penetrated the outer table of the skull exposing the underlying cancellous bone or diploë (Fig. 2). In males, lesions often were concentrated on the posterior frontal bone or around the pedicles, while in females they generally occurred on the lacrimal and nasal bones, around the orbits, or on the frontal bone anterior to the supra-orbital foramen.

Skulls with representative lesions were scanned on a Phillips Tomoscan LXC (Phillips Medical Systems, Itasca, Illinois, USA) quantitative computed tomography (QCT) bone mineral densitometry unit (Image Enhancements, San Francisco, California, USA) at Portage View Hospital in Hancock, Michigan. Because QCT permits precise estimates of bone mass and is particularly useful in the diagnosis of osteoporosis, QCT was used rather than histologic examination of the lesions (Palmer, 1993). Scans were taken of full skull lateral aspect and cross-sections at 10 mm intervals operating at 130-kilovolt potential, 175 milliampereseconds, with a calibration phantom of known concentrations of dipotassium hydrogen phosphate for reference to minimize scanner drift (Cann et al., 1985). Using QCT scans of skulls, we noted increased lucency and decreased numbers and thickness of trabeculae; in

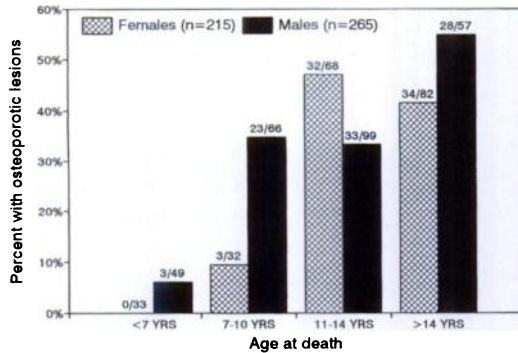


FIGURE 1. Prevalence of osteoporotic lesions in skulls of 480 moose in Isle Royale National Park, Michigan, from skeletal remains collected 1958 to 1994. Proportion of each sex and age group with lesions noted above bar.

cross-sections, we observed regions of very low density bone surrounding and underlying the lesions. Using QCT scans, we also observed low bone mineral content in the metatarsus of a bull moose with osteoporotic skull lesions (Hindelang et al., 1992).

Possible etiologies for the lesions include cyclic physiologic osteoporosis due to bone turnover during pregnancy and antler growth, nutritional deficiencies, and genetic or environmental factors. The term osteoporosis means increased porosity of the bone, reduced bone mineral content, and reduced bone mass (Jackson and Kleerekoper, 1990) which occurs when the rate of bone resorption (destruction of bone by osteoclasts) accelerates while the rate of bone formation (production of bone by osteoblasts) decreases (Parfitt, 1976). Osteoporotic lesions result when resorption predominates, occurring mainly in bones with a large component of cancellous tissue, such as the flat bones of the skull, the vertebrae, and the trabeculae of long bones (Palmer, 1993).

Net loss of bone is often a progressive, irreversible process, but Parfitt (1976) described temporary reversible mineral deficit as the result of an increase in bone turnover that occurs naturally in pregnancy and antler growth. During pregnancy, calcium required for deposition in the fetal

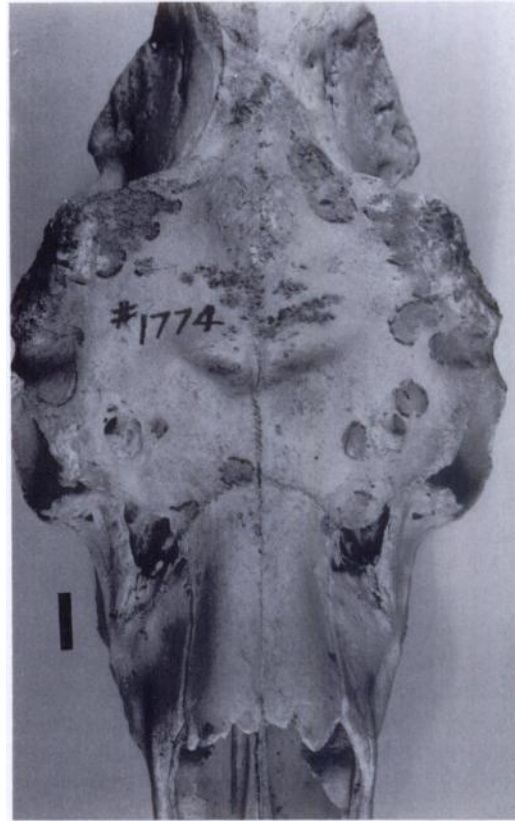

FIGURE 2. Osteoporotic lesions in the skull of an adult male moose from Isle Royale National Park, Michigan. Similar lesions occur in 32% of the skulls collected from 1958 to 1994. Bar = 2 cm.

skeleton is provided partly by an increase in intestinal calcium absorption and also by temporary mobilization of mineral from bone with increased bone turnover; if nutritional intake is adequate, reversible mineral deficit is replenished. In antler growth, a cyclic physiologic osteoporosis (Parfitt, 1976) occurs during the most rapid period of growth with a large increase in the number of resorption spaces which return to normal when the antlers are fully grown. The cyclic increase in porosity enables intestinal mineral absorption to be spread out over most of the year instead of concentrated into a few months with no net loss of bone during the complete cycle if nutrition is adequate (Banks et al., 1968).

Consequently, the differences in prevalence of osteoporotic lesions between males and females in the Isle Royale moose population may be related to different processes in their life cycles. Because moose calves must be large and well developed at birth to be able to follow adults and escape predation, cows minimize postnatal vulnerability by devoting large quantities of nutrients and energy to their offspring during pregnancy and lactation (Robbins, 1983). When dietary intake of calcium is not sufficient to meet these demands, contribution of the maternal skeleton to her young is increased through bone resorption, and bone demineralization occurs (Garel, 1987, Van Soest, 1987). In males, bone mineral loss may be related to annual antler growth. Antlers are highly sensitive to nutrition and are symbols of metabolic and functional efficiency indicative of ability to find and use nutrients for maintenance and growth (Geist, 1991). Because antler morphology is very close to that of skeletal bone, antler growth typifies the physiology and pathology of bone formation and mineralization; like bone, antlers are dependent upon hormones for their growth and calcification (Bubenik et al., 1975).

We found no other reports of lesions resembling those described in this study. Osteoporosis and cranial asymmetry were reported by Bleich et al. (1990) in the skull of a mountain sheep (*Ovis canadensis*), associated with reduced horn size and malocclusion of the mandibles. Bunch and Allen (1981) described skull lesions in desert bighorn sheep *Ovis canadensis nelsoni* associated with chronic frontal sinusitis and focal osteomyelitis which were unlike the lesions in this study. The lesions we observed were confined to the outer table of the skull without evidence of concurrent osteomyelitis within the frontal sinuses. However, we found six (30%) of twenty skulls in the University of Michigan Museum of Zoology collection from Isle Royale in the early part of this century (Murie,

1934) that had lesions in the frontal bone similar to the lesions we observed.

Prevalence of osteoporotic skull lesions in the Isle Royale moose population differed significantly by sex and age ($P < 0.01$). Lesions generally increased with age and were rare in animals that died before age seven, consistent with the concept that net loss of both trabecular and cortical bone with age is physiologic (Palmer, 1993). Cows showed a modest increase in the 7 to 10-yr-old group and a marked increase in the 11 to 14-yr-old group, the years following peak calf-bearing years, reflecting the cumulative effects of gestation and lactation, but a decrease in later years when reproduction and mineral depletion declines (Grasman and Hellgren, 1993). Because replacement of resorbed bone is not completely efficient, bone deficit persists at the completion of each cycle; the cumulative effects may not be seen immediately but are profound over time (Marcus, 1991). Males had high prevalence of lesions throughout adulthood with even greater prevalence in those that live to be very old. Deciduous antlers put severe demands on bone metabolism causing an annual physiologic osteoporosis (Banks et al., 1968). Because senior bulls continue to grow antlers into old age (Bubenik et al., 1975), increased mineral cost and reduced metabolic efficiency may account for the increase in osteoporotic lesions.

We gratefully acknowledge the work of Gilbert Daniel, M.D. and John Jokela, Radiological Technician, from the Radiology Department of Portage View Hospital, Hancock, Michigan; Tom Drummer for his statistical advice; the staff of the University of Michigan Museum of Zoology for their assistance; and Ed Addison and an anonymous reviewer, for their helpful suggestions on the manuscript.

LITERATURE CITED

- BANKS, W. J., G. P. EPLING, R. A. KAINER, AND R. W. DAVIS. 1968. Antler growth and osteoporosis. *Anatomical Record* 162: 387-398.

- BLEICH, V. C., J. G. STAHMANN, R. T. BOWYER, AND J. E. BLAKE. 1990. Osteoporosis and cranial asymmetry in a mountain sheep. *Journal of Wildlife Diseases* 26: 372-376.
- BUBENIK, G. A., A. B. BUBENIK, G. M. BROWN, AND D. A. WILSON. 1975. The role of sex hormones in the growth of antler bone tissue. *Journal of Experimental Zoology* 194: 349-358.
- BUNCH, T. D., AND S. D. ALLEN. 1981. Survey of chronic sinusitis-induced skull anomalies in desert bighorn sheep. *Journal of the American Veterinary Medical Association* 179: 1150-1152.
- CANN, C. E., H. K. GENANT, F. O. KOLB, AND B. ETTINGER. 1985. Quantitative computed tomography for prediction of vertebral fracture risk. *Bone* 6: 1-7.
- GAREL, J. M. 1987. Hormonal control of calcium metabolism during the reproductive cycle in mammals. *Physiological Reviews* 67: 1-66.
- GEIST, V. 1991. Bones of contention revisited: Did antlers enlarge with sexual selection as a consequence of neonatal security strategy? *Animal Behavior Science* 29: 453-469.
- GRASMAN, B. T., AND E. C. HELLGREN. 1993. Phosphorus nutrition in white-tailed deer: Nutrient balance, physiological responses, and antler growth. *Ecology* 74: 2279-2296.
- HINDELANG, M., R. O. PETERSON, AND A. L. MACLEAN. 1992. Osteoporosis in moose on Isle Royale: A pilot study of bone mineral density using CT scans. *Alces* 28: 35-39.
- JACKSON, J. A., AND M. KLEEREKOPER. 1990. Osteoporosis in men: Diagnosis, pathophysiology, and prevention. *Medicine* 69: 137-152.
- MARCUS, R. 1991. Skeletal aging: Understanding the functional and structural basis of osteoporosis. *Trends in Endocrinological Metabolism* 2: 53-58.
- MURIE, A. 1934. The moose of Isle Royale. Miscellaneous Publications No. 25, Museum of Zoology, The University of Michigan, Ann Arbor, Michigan. 44 pp.
- PALMER, N. 1993. Metabolic diseases of bone. In *Pathology of domestic animals*, K. V. F. Jubb, P. C. Kennedy, and N. Palmer (ed.). Vol. 1. 4th ed. Academic Press, Orlando, Florida, pp. 55-93.
- PARFITT, A. M. 1976. The integration of skeletal and mineral homeostasis. *Metabolism* 25: 1033-1069.
- PETERSON, R. O. 1977. Wolf ecology and prey relationships on Isle Royale. Scientific Monograph Series Number 11, National Park Service, U.S. Government Printing Office, Washington, D.C., 210 pp.
- ROBBINS, C. T. 1983. *Wildlife feeding and nutrition*. Academic Press, New York, New York, 343 pp.
- VAN SOEST, P. J. 1987. *Nutritional ecology of the ruminant*. Comstock Publishing Associates, Ithaca, New York, 373 pp.
- WOLFE, M. L. 1969. Age determination in moose from cementum layers of molar teeth. *The Journal of Wildlife Management* 33: 428-431.

Received for publication 27 January 1995.