

## **FORENSIC (MEDICO-LEGAL) NECROPSY OF WILDLIFE**

Author: Wobeser, G.

Source: Journal of Wildlife Diseases, 32(2) : 240-249

Published By: Wildlife Disease Association

URL: <https://doi.org/10.7589/0090-3558-32.2.240>

---

BioOne Complete ([complete.BioOne.org](https://complete.BioOne.org)) is a full-text database of 200 subscribed and open-access titles in the biological, ecological, and environmental sciences published by nonprofit societies, associations, museums, institutions, and presses.

Your use of this PDF, the BioOne Complete website, and all posted and associated content indicates your acceptance of BioOne's Terms of Use, available at [www.bioone.org/terms-of-use](https://www.bioone.org/terms-of-use).

Usage of BioOne Complete content is strictly limited to personal, educational, and non - commercial use. Commercial inquiries or rights and permissions requests should be directed to the individual publisher as copyright holder.

---

BioOne sees sustainable scholarly publishing as an inherently collaborative enterprise connecting authors, nonprofit publishers, academic institutions, research libraries, and research funders in the common goal of maximizing access to critical research.

## FORENSIC (MEDICO-LEGAL) NECROPSY OF WILDLIFE

**G. Wobeser**

Canadian Cooperative Wildlife Health Centre, Department of Veterinary Pathology,  
Western College of Veterinary Medicine, University of Saskatchewan,  
52 Campus Drive, Saskatoon, Saskatchewan, Canada S7N 5B4

**ABSTRACT:** Post-mortem examination of wild animals for legal purposes has become increasingly common. Special procedures are necessary during such necropsies to ensure that the information collected is suitable for use in a court of law. Forensic necropsies should be performed by pathologists with formal training and experience, because these credentials will be examined if a case reaches court. There must be strict attention to maintaining a chain of custody when specimens are received from the field and in all subsequent procedures, so that the identity of specimens and information resulting from the necropsy is beyond question. A complete record must be kept of all procedures and observations. The necropsy report must be detailed, clear and, as far as possible, written in non-technical language. Photography should be used to preserve visual evidence. Special precautions are required for collecting specimens, such as bullets, suspected toxins, and material for DNA analysis, and for sending these specimens to other laboratories.

**Key words:** Pathology, forensic, medico-legal, techniques, enforcement.

### INTRODUCTION

The potential for profit from crimes involving wild animals, including trade in animal parts, such as bear (*Ursus* sp.) gall bladders and paws, and poaching of protected or endangered species has increased, as have penalties imposed on those convicted of these crimes. There is also rising interest in establishing culpability for the death of wild animals as a result of pollution or poisons. These developments have resulted in greater need for evidence obtained by examination of dead wildlife that will be acceptable in a court of law. Forensic (pertaining to or applied in legal proceedings) pathology is a well-established discipline in human medicine and most examinations are done by forensic specialists. There is no comparable recognized speciality dealing with wildlife pathology and workers have had to extrapolate from reference texts developed for humans, such as Di Maio and Di Maio (1989). General forensic laboratories have been developed to assist wildlife enforcement personnel in several jurisdictions and a recent forensic manual (Adrian, 1992) contains detailed information on many techniques for use by enforcement officers in the field. However, there are few guidelines available for wildlife pathologists who

may be required to perform necropsies on such cases. When evidence regarding a necropsy is required in court, there is usually examination of both the pathologist's formal training (academic credentials) and experience in forensic examination to establish his or her ability to serve as an expert witness. Thus, whenever possible, forensic necropsies should be performed by a trained pathologist who has experience with the species being examined. My objective is to present general guidelines to assist pathologists. There are differences in specific legal requirements among jurisdictions, and pathologists who perform forensic necropsies must be familiar with those that apply in their area.

The principal purpose of a forensic necropsy is to determine the cause and nature of death of the animal being examined. Determination of the time sequence in which events occurred, the general health of the animal, and the presence of preexisting conditions that may have influenced its death may also be important. It is often necessary to collect information and perform ancillary tests to rule out alternate explanations, for example, to show that the animal was in good health and was not suffering from an infectious disease at the time of its death. Identification of the animal as to species, sex, and age may also

be important for enforcement purposes, and the pathologist may need to seek assistance in these matters. The pathologist may also be required to recover physical evidence such as bullet fragments or toxic residues.

At the outset of any forensic examination, it is important that the pathologist and the person requesting the examination discuss what can and what cannot be accomplished by a necropsy, and the tests that the laboratory is equipped to provide. For example, we have been asked to examine coyotes (*Canis latrans*) and foxes (*Vulpes vulpes*) allegedly killed by being run over by snow machines. In these cases, we have explained that while a necropsy will help to rule out alternate causes of death, such as gunshot wounds, leg-hold traps, and common poisons, and may provide evidence of death as a result of blunt trauma, it is often not possible to identify the cause of that trauma.

#### MAINTAINING CUSTODY

An overriding feature of any forensic examination is maintenance of continuous control over all specimens and information, so that one can testify with certainty as to their identity. This control is referred to as maintaining a chain of evidence or chain of custody. Adrian and Moore (1992) explained chain of custody to mean "that every individual who has sole custody of the evidence must appear to testify that the evidence gathered in the field is the same exact evidence examined in the laboratory." The chain of evidence usually begins with the enforcement officer who first encountered the animal(s) in the field. It is his or her responsibility to maintain custody over the animal until it reaches the laboratory, when it becomes the pathologist's responsibility. Specimens should be brought to the laboratory by the enforcement officer and turned over directly to the pathologist who will perform the necropsy, whenever this is possible. Specimens for forensic examination should never be left at a laboratory without being re-

ceived by a responsible individual, as this breaks the chain of custody. Specimens can be submitted through a receiving clerk or technician rather than directly to the pathologist but this may complicate the chain of custody. Specimens must be kept in a secure manner and transfers of custody within the laboratory must be recorded, as each individual involved may be required to testify. Each specimen must be clearly identified with well attached labels or tags at the time of submission. In our laboratory, the pathologist receiving the specimen from the officer notes the time of receipt on the evidence tag or chain of custody form attached to the animal(s), and then signs the tag in the presence of the submitting officer. This tag remains with the animal until the necropsy is performed.

The pathologist and enforcement officer must discuss and agree on what specimens need to be retained for potential use as evidence, how these specimens will be maintained and returned to the enforcement officer, and how and when one should dispose of portions that are not required. Normally, physical evidence that may be used in court is returned to the enforcement officer who signs for receipt of any specimens when they are returned to his or her custody. In some cases, it may be advantageous for the enforcement officer to attend the necropsy and collect specimens, such as bullets or suspected poisons, directly.

#### RECORD KEEPING

A major difference between an ordinary necropsy, as done in a wildlife disease diagnostic laboratory, and a forensic necropsy relates to the completeness of records that are kept about the procedures and the results obtained. The value of complete records cannot be over-emphasized. Most forensic cases do not reach court until months after the necropsy was completed and several years may elapse before the pathologist is required to testify. When the pathologist appears in court, details of an

individual necropsy may be only a very faint memory, and he or she must depend on the written report and be confident to swear that it represents a true and complete record of what was done and found.

The first step is to ensure that a complete history is recorded and that the identity of the animal or specimen submitted corresponds to that specified on the history. This is usually not a problem if the specimen passes directly from the enforcement officer to the pathologist. The pathologist should be fully familiar with the circumstances in which the animal was found and the nature of the problem that is suspected by the enforcement officer. In cases of suspicious human death, the forensic specialist usually visits the scene of death before the body is removed; this is normally not possible in wildlife work.

The next step is to ensure that all features and results of the examination, including the history submitted with the animal, descriptions, diagrams and photographs produced during the necropsy, the results of subsequent ancillary tests, (such as histology, microbiology and toxicology), and physical specimens are clearly linked together in the record-keeping system used. Usually this is done by assigning a unique number to each case and then using that number in all matters related to the case. If more than one animal is involved, individual numbers should be assigned to each. The pathologist must be scrupulous in recording the connection between any identification applied by the enforcement officer and the identifying number used in the laboratory. Before beginning the necropsy, the pathologist should make a final check to ensure that all numbers correspond. One further safeguard is to always begin the written necropsy report, which must bear the laboratory number, together with the date and time of the necropsy, with a sentence such as: "The specimen was a mature male coyote received from [submitter's name] on [date] to which was affixed a label with the following information: Specimen A-93-

102, and bearing the signature of [enforcement officer]."

The final necropsy report will form the basis of any examination that occurs in court. Descriptions of necropsy findings must be complete, clear, and, as far as possible, phrased in non-technical language that will be easily understood by the non-medical persons who will have to deal with it in court. The animal's sex, age, and body condition should always be recorded, together with the criteria used to establish these facts, for example, "the animal was judged to be less than 1 year of age based on the presence of deciduous incisors." It is essential that all abnormalities, no matter how trivial they may appear, are recorded. Negative, as well as positive, findings also must be recorded, so there is no question as to whether an organ that was not described was a) examined and found to be normal or b) was not examined. Abnormalities or lesions should be described in absolute units (centimeters, grams) rather than in relative terms (enlarged, smaller than normal). The location of injuries and abnormalities should be measured and recorded in relation to readily identified anatomic landmarks. Outline drawings (Fig. 1), prepared in advance or at the time of necropsy, are particularly useful for recording the location of lesions such as traumatic wounds. These drawings become part of the permanent record of the case.

Photographs are an invaluable record of what was observed, and are useful in court for explaining the nature of lesions. Photographs are usually prepared as large format color prints. Most laboratories use color or transparency film to photograph pathologic lesions and suitable color prints can be prepared from color transparencies; however, when possible, forensic cases should be photographed directly on print (color negative) film as the quality of the resulting photographs may be better. Unless certain of obtaining a suitable photograph from a single exposure, it is wise to take a range of exposures to ensure a suit-

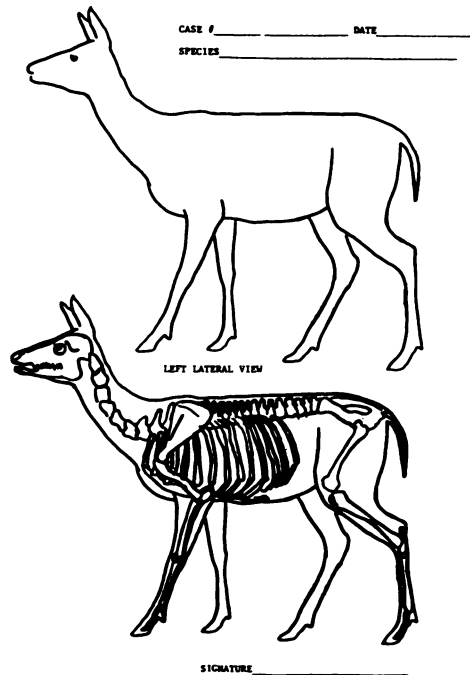


FIGURE 1. Simple outline drawings suitable for recording the location of lesions found during necropsy. The drawings have space for the case number and for the pathologist's signature. These drawings become part of the permanent record for a case.

able photograph results. If possible, the pathologist should take the photographs or, at least, be present when they are taken, as this reduces complications as to the identity of the specimens shown when the photographs are used in court.

It is desirable to photograph the intact animal, including its identification tags, before beginning the necropsy. This should be followed by a series of photographs that are increasingly focused on the area of interest, so that the location and orientation of lesions can be demonstrated. Every photograph should contain information that clearly identifies the subject animal, the date, a size reference scale, and the identity of the pathologist. It is convenient to have cards prepared in advance that have a reference scale, and spaces for the appropriate information. These should be made of matt paper and of a mid-range color such as medium grey, green, or

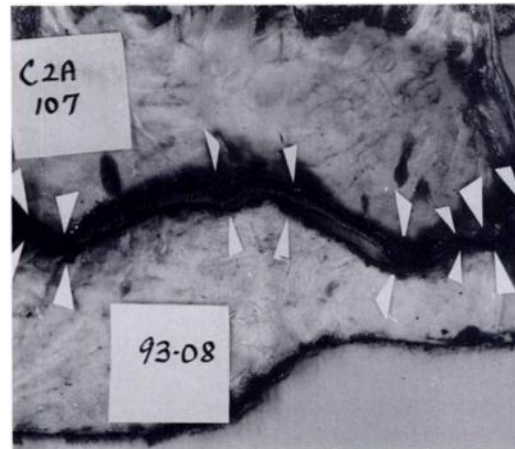


FIGURE 2. Markers should be placed directly on tissues during photography to identify the location of items of interest. In this case, arrows are used to mark points of similarity on the apposing sides of two portions of skin alleged to be from the same animal.

brown; white cards are usually over-exposed and illegible. Markers or symbols (numbers, letters) should be placed directly on the specimens during photography to clearly indicate areas of interest such as bullet wounds or corresponding points on body parts (Fig. 2). Pointers can be used to identify the connection between lesions, such as the path of a bullet through the body. Aluminum gun-cleaning rod is useful for this purpose, because sections can be joined together as needed to make a straight pointer of the required length. Each photograph should be accompanied by a clear description of what is illustrated, prepared by the pathologist, when it is turned over to the enforcement officer. This information should be attached permanently to the back of the photograph.

Rough notes or dictation made during the necropsy should be used by the pathologist to prepare the necropsy report immediately after the necropsy is completed; any delay may result in details being forgotten. The original notes should be retained by the pathologist until all possible court proceedings are completed. If ancillary tests are to be done, a preliminary

necropsy report is prepared that includes a list of samples retained for analysis, as well as a list of radiographs and photographs taken. The final report, prepared when all results are available, should contain the pathologist's observation and the results of ancillary tests, a list of diagnoses, a list of all specimens taken and their disposition, as well as the pathologist's interpretation of the meaning and significance of the findings. If there are inconsistencies, or if some of the results are equivocal, this should be pointed out and alternative explanations should be discussed. After typing, the final report must be read carefully by the pathologist and each page signed before it is sent. The report is confidential and should only be given to the authority who requested the necropsy examination.

All documentation relating to each case that is not returned to the enforcement officer, including copies of the necropsy report, photographs and results of ancillary tests, and physical specimens, must be retained in the pathologist's custody, in a secure manner, until the case goes to court or until the enforcement officer advises that the case has been closed and the information is no longer required.

#### EXTERNAL EXAMINATION

In human forensic autopsies, external examination of the body is of great value because injuries are readily visible on the skin of the subject. In animal necropsies, superficial features often are obscured by pelage or plumage. Penetrating wounds, such as gunshot wounds caused by a small caliber rifle bullet or shotgun pellets, may be almost impossible to find externally. Any evidence of skin abnormalities, bleeding from body orifices or, soiling with blood, exudate, excreta, or foreign material should be recorded. Samples of foreign material, such as oil, on the pelage or plumage should be collected and preserved in suitable containers for possible analysis. In large birds, the entire body surface must be examined very carefully

for burned or singed feathers or skin as a result of electrocution. The animal should be weighed prior to necropsy and the weight recorded. If the carcass is incomplete, as is often the case, the portions that are present should be described and the absence of the remainder noted. The limbs should be manipulated to assess the state of rigor mortis and the presence of fractures or dislocations. Time of death (TOD) determination is an important part of forensic examination of human deaths. Techniques have been developed to estimate TOD in various wild species in the field but these are of limited use in the laboratory (Oates, 1992). Forensic entomology, which may be used to estimate TOD in human deaths, has not been used widely in wildlife forensic cases.

If traumatic injuries, particularly gunshot wounds, are suspected, the intact carcass of birds and smaller mammals and affected portions of the carcass of large animals should be radiographed. Correct identification must appear on the radiographs.

#### INTERNAL EXAMINATION

In most forensic cases, it is advantageous to carefully skin the entire animal as the first step in the internal examination, because traumatic injuries, such as projectile and bite wounds, and trap or snare marks, are much more readily visible on the flesh side than on the furred side of the hide. Care must be taken in skinning animals with suspected gunshot wounds because bullets that have lost energy in passing through the body are often unable to exit through the tough elastic hide. This should be suspected if subcutaneous hemorrhage with no skin perforation is found on the side of the body opposite a puncture wound. The bullet is usually lodged immediately under the skin and is easily lost during skinning. In fur-bearers and large raptors, the distal limbs should be skinned carefully to examine for marks caused by leg-hold traps, which often may be subtle. If trap injury is suspected, the

foot area should be radiographed to detect fracture of small foot-bones. Skinning also allows a complete assessment of the amount of subcutaneous fat and condition of the musculature.

The remainder of a forensic necropsy follows standard necropsy technique and consists of systematic examination of the positional relationship among organs, and of the size, color, shape, and texture of all organs, including the brain and spinal cord. All hollow organs should be opened to inspect the lumen and contents; parenchymatous organs should be incised. The process of opening and examining body cavities and organs alters their relationship and appearance, so that observations must be made and recorded as the process proceeds. For example, if the interior of the thorax is not examined immediately after opening, it may be impossible later to determine if blood was present initially or seeped in from other tissues during the necropsy. Because the appearance of tissue changes and lesions may be destroyed during the necropsy procedure, abnormalities should be photographed as soon as possible.

Traumatic injuries, particularly gunshot and predator wounds, form an important part of forensic examination of wild animals. Pathologists engaged in this type of work should understand basic ballistics and be familiar with the type of injury produced by different firearms, as well as those caused by arrows, the predators in their area, and various forms of blunt trauma. Examination of hunter-killed animals is useful for gaining this experience. Adrian (1992) provides methods and illustrations for differentiating between arrow, gunshot, and other wounds; Fattah (1976) is a general reference on gunshot wounds. It is often necessary to trace the path of a projectile through the body, as this may indicate the relative position of the animal and the shooter. Bullets usually pass in a relatively straight line through tissue, but impact with bone may change the direction dramatically. If a bullet fragments, there

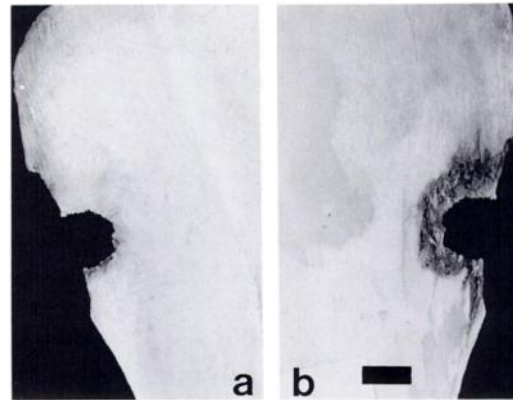


FIGURE 3. Scapula of a deer shot transversely through the body with a center-fire rifle. The lateral surface (a) has a smooth rimmed puncture typical of an entry wound into a flat bone; the medial surface (b) has a radial fracture with loss of fragments of bone about the perimeter of the puncture, typical of an exit wound. The bullet passed from lateral to medial through the scapula. Bar = 1 cm.

may be several diverging paths. Radiographs are invaluable for understanding gunshot wounds. Small fragments of metal may mark the path of a bullet through tissue and the nature of the projectile is often clearly visible on a radiograph. Entrance wounds, the point where a bullet entered tissue, are often smaller in diameter than exit wounds, because of distortion of the bullet as it passes through tissue. However, if a bullet fragments, the individual exit wounds may be very small. The diameter of bullet wounds in skin and soft tissue is not a reliable indicator of the size (caliber) of the causative bullet. Special attention should be paid to any site where a bullet passes through a flat bone, such as the skull, pelvis, or scapula, because the resulting fracture may provide evidence of direction of travel of the projectile (Fig. 3). Because many wild animals have bullets or shotgun pellets embedded in their tissues as a result of earlier and unrelated events, it is very important to relate the location of bullets in wild animals to the presence of appropriate recent wounds.

It may be necessary to establish the re-



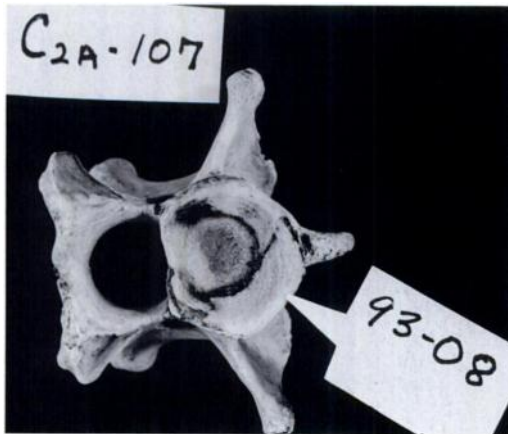


FIGURE 4. Cervical vertebral body from a deer (same case as Fig. 2). The small fragment labelled 93-08 was recovered from the severed neck of a deer head found in a field; the vertebral body labelled C2A-107 was from the headless carcass of a deer found in the possession of an individual.

relationship between separated portions of tissue, for example, to determine if the head of a game animal recovered at one site, the viscera recovered at a second site, and a carcass found at a third location, belong to a single animal. This often can be established satisfactorily by careful matching of structures using radiography and dissection of the parts, and by features such as apposing cuts and fractures on the two portions (Figs. 2, 4). Bones often have to be cleaned of flesh to demonstrate fractures or cut marks. If bones are cleaned of flesh by boiling, the individual portions must be carefully wrapped in cheesecloth and labelled so there is no possibility of intermixing of specimens during the boiling process. Adrian (1992) provides detailed instructions for matching portions. Direct comparison of DNA extracted from individual portions can also be used to establish the relationship of portions and provides strong evidence that portions came from a single animal (Kirby, 1992). A very useful critical overview of the use of DNA technology in human forensic science is provided by the National Research Council (U.S.) (1992).

#### SPECIMENS FOR ANCILLARY TESTS

The types of specimens collected at necropsy for subsequent examination will depend on the circumstances of the particular case. Ancillary tests used commonly in forensic work include histology, toxicologic analyses, ballistics and, recently, DNA tests to establish identity of individual animals. The laboratory that will perform the analysis should be consulted in advance to determine the appropriate specimens, amount of specimen required, and how it should be preserved. Care must be taken that specimens do not become contaminated. This is critical for toxicological and DNA analyses. Clean instruments must be used for each specimen to prevent cross-contamination and each tissue must be placed in a separate container. The containers used for specimens may cause problems, either because of possible contamination or through adsorption of toxins into the container material. In general, specimens for toxicological analysis should be preserved in glassware that has been acid-rinsed. Specially cleaned glassware intended for environmental sampling is available from scientific suppliers. In cases where there is a suspicion of possible intoxication but the toxin involved is unknown, samples of stomach content, intestinal content, liver, kidney, brain, and fat should be collected in individual containers and held frozen for possible analysis. All specimens must be carefully labelled, sealed, and kept in a manner that preserves the chain of custody.

Because rifled firearms leave characteristic markings on the projectile, bullets recovered from carcasses are useful for establishing the identity of the gun responsible for the injury. Shotgun pellets can not be linked back to a particular gun. Recovering bullets or bullet fragments can be tedious, particularly in large animals, and radiology or fluoroscopy is very useful. Once the presence of a bullet has been established in a portion of tissue by radiography, careful dissection is necessary.



During this process, no tissue should be discarded until the bullet has been found. As each portion is examined visually and by palpation, it should be set aside in a container for possible re-examination. It may be necessary to radiograph dissected tissue several times until, eventually, a bullet is recovered. The markings used for identifying the gun of origin are fragile, so care must be taken that the bullet is not cut while dissecting tissue. For the same reason, bullets should never be handled with metal forceps; they should be handled either with gloved fingers or rubber-covered forceps. Bullets must be washed free of blood and tissue after recovery or these will harden onto the surface and obscure the markings. Washing should be done while holding the bullet in the hand under running water over a strainer, (so that the projectile is not lost down the drain). After the bullet has dried, it should be placed in a padded container that is clearly labelled with the case number, sealed, and initialled.

#### SHIPPING SPECIMENS TO OTHER LABORATORIES

Analytical procedures may not be available locally and specimens may have to be sent to other laboratories. It is important to establish in advance that the laboratory chosen has experience with forensic or legal analyses, understands chain of custody, and that the analytical scientists involved are suitably qualified to serve as witnesses. Specimens should never be sent to an analytical laboratory without making specific prior arrangements for the examination. The specimens must be packaged in such a manner that the analytical scientist receives the specimen in a sealed container, as it was packed by the pathologist. Appropriate precautions must be taken to ensure that specimens do not decompose during transit and the packaging and labelling must comply with restrictions on hazardous materials. Specimens, individually labelled and in appropriate containers, are placed within a box, envelope, or



FIGURE 5. Method of packaging specimens for shipment to another laboratory. Labelled specimens are placed within a container that is sealed with tape, signed and clearly marked "Evidence." The covering letter and request for analysis are sealed in an envelope, labelled "Documents," that is attached to the *outside* of the container. The entire package, as shown, is ready to be wrapped in a separate outer wrapping that will be addressed to the laboratory.

freezer chest that is sealed carefully with tape and marked clearly as "Evidence." It is useful for the pathologist to sign across the tape so the consignee is assured that the parcel was unopened when received. A covering letter and a request for analytical services in which each specimen is listed, together with the specific test required, are placed within a sealed envelope, labelled "Documents," that is attached to the outside of the sealed specimen box (Fig. 5). The sealed box, complete with document envelope, is then wrapped or placed in a final outer container. The outer wrapping is addressed and the parcel should be sent by registered mail or by bonded courier. The analytical laboratory should be notified of the method of shipment, waybill number, and expected delivery time, as soon as the specimens are sent. When the parcel is received at the laboratory, the outer wrap-

ping can be removed and the documents recovered, without breaking the seals on the box containing the specimens.

### DISCUSSION

Jaffe (1991) listed common errors that occur during forensic autopsy of humans, principally because of inexperience of the pathologist. Most of these also apply to forensic necropsies of wildlife, including:

1. Performing an incomplete examination; for example, failure to examine the brain.
2. Inadequate documentation; for example, failure to record weights or measurements, or to take appropriate photographs.
3. Recording findings too long after the necropsy.
4. Failure to collect samples for ancillary analyses, or collecting samples improperly; these include inappropriate samples, unsuitable containers or preservation, and inadequate labelling.
5. Accidents during the necropsy, such as contaminating tissues with ingesta.
6. Mistaking changes caused by autolysis or other artifacts for significant lesions.
7. Failure to enlist assistance of experts in other disciplines.
8. Relying too much on the history and information received at the time of submission concerning the cause of death.

Most errors can be avoided by careful thought prior to the necropsy and by following a protocol with strict attention to detail during the necropsy.

The pathologist is usually requested to perform a necropsy by enforcement personnel and, hence, is usually asked to appear in court by the prosecution. However, one must remember that his or her obligation is to provide medical opinion to the court, rather than to be an advocate for either the prosecution or the defense. There is an obligation to be objective both during the investigation and when testifying in court. "Truth, or the nearest reasonable approach to it that is possible from

what is observed, is the sole aim" (Knight, 1991) of the forensic necropsy. It is the pathologist's responsibility to have reviewed and to be thoroughly familiar with all matters pertinent to the case prior to appearing in court. Copies of all records from a case should be available for reference. In the adversarial system of the courtroom, one should expect to have one's qualifications, memory, observations, and opinions challenged. Any difference or deviation between the written necropsy report and the pathologist's testimony may create a problem of credibility. In presenting information, the pathologist must take care to differentiate between observations and interpretations drawn from the observations, and must always be very careful to define those matters on which a conclusion could not be reached. "No matter how skilled and experienced the investigator, the biological material with which he has to deal often will not yield the information which the police or the courts require, or yield it with the desired degree of precision" (Jaffe, 1991).

Forensic necropsies can be tedious and require rigid attention to detail but they provide a necessary service and will likely become an increasingly common part of the work of the wildlife pathologist.

### LITERATURE CITED

- ADRIAN, W. J. 1992. Wildlife forensic manual. Association of Midwest Fish and Game Law Enforcement Officers, Colorado Division of Wildlife, Fort Collins, Colorado, 179 pp.
- , AND T. D. MOORE. 1992. Evidence submission, *In* Wildlife forensic field manual, W. J. Adrian (ed.). Association of Midwest Fish and Game Law Enforcement Officers, Colorado Division of Wildlife, Fort Collins, Colorado, pp. 3–23.
- DI MAIO, D. J., AND V. J. M. DI MAIO. 1989. Forensic pathology. Elsevier, New York, New York, 503 pp.
- FATTEH, A. 1976. Medicolegal investigation of gunshot wounds. J. B. Lippincott Company, Philadelphia, Pennsylvania, 272 pp.
- JAFFE, F. A. 1991. A guide to pathological evidence for lawyers and police officers, 3rd ed. Thomson Professional Publishing Canada, Scarborough, Ontario, Canada, 246 pp.

- KIRBY, L. T. 1992. DNA fingerprinting: An introduction. W. H. Freeman and Company, New York, New York, 365 pp.
- KNIGHT, B. 1991. Simpson's forensic medicine, 10th ed. Edward Arnold, London, United Kingdom, 324 pp.
- NATIONAL RESEARCH COUNCIL (U.S.). 1992. DNA technology in forensic science. Committee on DNA Technology in Forensic Science, National Academy Press, Washington, D.C., 185 pp.
- OATES, D. 1992. Time of death. *In* Wildlife forensic field manual, W. J. Adrian (ed.). Association of Midwest Fish and Game Law Enforcement Officers, Colorado Division of Wildlife, Fort Collins, Colorado, pp. 82–111.

*Received for publication 5 May 1995.*