



RENAL COCCIDIOSIS AND OTHER PARASITOLOGIC CONDITIONS IN LESSER SNOW GOOSE GOSLINGS AT THA-ANNE RIVER, WEST COAST HUDSON BAY

Authors: Gomis, S., Didiuk, A. B., Neufeld, J., and Wobeser, G.

Source: Journal of Wildlife Diseases, 32(3) : 498-504

Published By: Wildlife Disease Association

URL: <https://doi.org/10.7589/0090-3558-32.3.498>

BioOne Complete (complete.BioOne.org) is a full-text database of 200 subscribed and open-access titles in the biological, ecological, and environmental sciences published by nonprofit societies, associations, museums, institutions, and presses.

Your use of this PDF, the BioOne Complete website, and all posted and associated content indicates your acceptance of BioOne's Terms of Use, available at www.bioone.org/terms-of-use.

Usage of BioOne Complete content is strictly limited to personal, educational, and non - commercial use. Commercial inquiries or rights and permissions requests should be directed to the individual publisher as copyright holder.

BioOne sees sustainable scholarly publishing as an inherently collaborative enterprise connecting authors, nonprofit publishers, academic institutions, research libraries, and research funders in the common goal of maximizing access to critical research.

RENAL COCCIDIOSIS AND OTHER PARASITOLOGIC CONDITIONS IN LESSER SNOW GOOSE GOSLINGS AT THA-ANNE RIVER, WEST COAST HUDSON BAY

S. Gomis,¹ A. B. Didiuk,² J. Neufeld,³ and G. Wobeser⁴

¹ Department of Veterinary Pathology, Western College of Veterinary Medicine, University of Saskatchewan, 52 Campus Drive, Saskatoon, Saskatchewan, Canada S7N 5B4

² Canadian Wildlife Service, 115 Perimeter Road, Saskatoon, Saskatchewan, Canada, S7N 0X4

³ Veterinary Services Branch, Manitoba Agriculture, 545 University Crescent, Winnipeg, Manitoba, Canada R3T 2N2

⁴ Canadian Cooperative Wildlife Health Centre, Department of Veterinary Pathology, Western College of Veterinary Medicine, University of Saskatchewan, 52 Campus Drive, Saskatoon, Saskatchewan, Canada S7N 5B4

ABSTRACT: Lesser snow goose (*Chen caerulescens caerulescens*) goslings, approximately 5 weeks of age, were collected near the mouth of Tha-anne River, Northwest Territories, Canada, during mid-August 1991. Many dead goslings had been observed in the area from 1988 to 1990. Goslings from near the coast, where habitat degradation by grazing geese was severe, were smaller, weighed less, and had a greater prevalence of renal coccidiosis (*Eimeria truncata*) and cecal nematode (*Trichostrongylus* spp.) infection than did goslings from inland areas, where habitat destruction was not evident. Prevalence of infection with intestinal cestodes was greater at inland than at coastal sites. Prevalences of gizzard nematodes (*Epomidiostomum* spp.) and *Leucocytozoon* spp. were not significantly different at the two sites. Histological examination of kidneys and examination of kidney homogenates for oocysts were more sensitive methods than gross examination of the kidneys for detecting renal coccidial infection. The number of oocysts present in droppings was not a good indicator of the severity of renal coccidial infection in individual birds; however, the average number of oocysts in droppings was indicative of the average severity of infection among groups of goslings.

Key words: Lesser snow goose, *Chen caerulescens*, goslings, renal coccidiosis, parasites, habitat degradation, condition.

INTRODUCTION

The number of lesser snow geese (*Chen caerulescens caerulescens*) in North America increased from the mid-1960's to the mid-1980's (Kerbes, 1973; MacInnes and Kerbes, 1987). This was evident both in increased number of breeding geese at arctic nesting colonies and in increased numbers of geese in the vicinity of nesting colonies while enroute to more northern nesting areas. Progressive degradation of coastal habitats due to foraging activities of geese has been documented at several large nesting colonies along the western shore of Hudson Bay in the Northwest Territories of Canada (Kerbes et al., 1990). Of particular concern is damage to freshwater sedge (*Carex aquatilis*) fens during spring, when nesting geese and geese in passage to more northern nesting areas concentrate their feeding in areas free of snow. Grubbing for graminoid roots and rhizomes by geese has disrupted and de-

stroyed large areas of sedge fen. This has resulted in large expanses of exposed peat and, over time, erosion and ice action has removed the shallow remnant peat cover and exposed underlying marine clays. Some of these clay areas have become increasingly saline with limited potential for recovery (Kerbes et al., 1990).

The population of snow geese declined more than 50% between 1985 and 1990 in breeding colonies on the west coast of Hudson Bay (R. Kerbes, unpubl.). The relationship between habitat degradation and the population decline is not well defined although nutritional stress may be occurring among geese that nest and attempt to raise broods in the vicinity of degraded areas (Williams et al., 1993). Growth and survival of goslings reared in degraded areas were less than in goslings reared distant from these sites (Cooch et al., 1991). Many dead snow goose goslings were observed along the Hudson Bay coast between the Geillini (60°11'N,

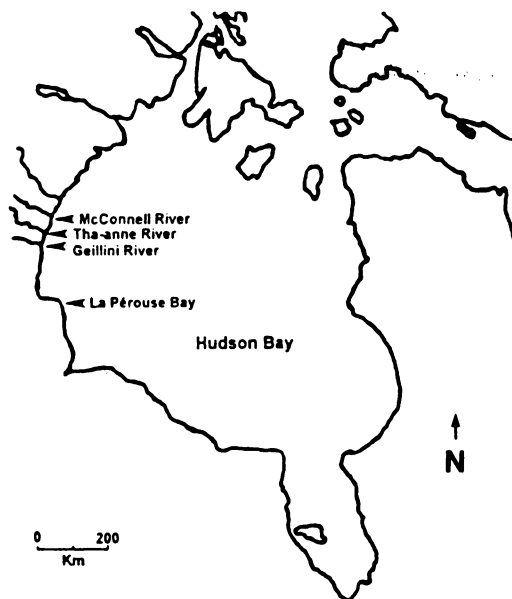


FIGURE 1. Location of the Tha-anne River study site and of some other lesser snow goose colonies on the west coast of Hudson Bay.

94°45'W) and McConnell Rivers (60°50'N, 94°20'W) (Fig. 1) during banding operations for Canada geese (*Branta canadensis hutchinsii*) in August of each year from 1988 to 1990. The greatest concentration of dead goslings, more than 5,000 in 1990, was near the mouth of the Tha-anne River (60°29'N, 94°22'W) (Fig. 1), where habitat destruction was severe (A. Didiuk, unpubl.). Dead goslings were seen only in the coastal area where habitat degradation was most severe and not in more inland areas where habitat degradation was not evident. Our objective was to compare the body condition and prevalence of renal coccidiosis (*Eimeria truncata*), cecal nematodes (*Trichostrongylus* spp.), gizzard nematodes (*Epomidiostomum* spp.), intestinal cestodes, and *Leucocytozoon* spp. in goslings along the coast to those further inland near the mouth of the Tha-anne River.

MATERIALS AND METHODS

Goslings were collected at eight sites near the mouth of Tha-anne River. Four sites were within a 10-km-wide strip along the coastline

where habitat damage was extensive. The other four were 15 to 25 km inland from the coast, in areas where habitat damage was minimal or not detectable. On 12 and 13 August 1991, groups of goslings and flightless molting adults at each site were captured by drive-trapping, using a helicopter (Pakalak and Schmidt, 1973). At each site, nine goslings were selected arbitrarily from within the group of captured geese, except at one coastal capture site where 11 birds were sampled. At capture, goslings were weighed, and mid-wing, tarsus, and ninth primary feather length were measured; blood was collected from the axial vein of the wing, and a blood film was prepared. Each gosling was placed in a clean cardboard box for 15 to 30 min so that droppings could be collected. Droppings were preserved in 2.5% aqueous potassium dichromate for parasitological evaluation. Goslings were killed by cervical dislocation, placed on ice, then frozen at -20°C within 12 hr and held frozen until necropsied at the Western College of Veterinary Medicine, University of Saskatchewan, Saskatoon, Saskatchewan, Canada. Each gosling was assigned a code number and goslings from all collection sites were mixed together so that the pathologist was unaware of the origin of individual birds.

At necropsy, the color-phase and sex of each gosling were determined, and culmen length, skull length, total length, thickness of fat in subcutaneous tissues and within the abdomen, and thickness of the pectoral muscle in the middle of the muscle were measured. The body condition was measured by the body weight, thickness of fat in subcutaneous tissues and within the abdomen, and thickness of the pectoral muscle. Liver (after emptying the gallbladder), intestine (after removal of ingesta) and kidneys were weighed. The bursa of Fabricius, thymic lobules, and spleen were removed intact and fixed in 10% neutral buffered formalin; later, these tissues were removed from formalin, blotted dry, and weighed. Tissues for histological examination (thymus, right kidney, bursa of Fabricius, spleen, trachea, lung, esophagus, proventriculus, duodenum, cecum, pancreas, liver, heart, and left tibiotarsus from all birds; salt glands from 20 birds) were fixed in 10% neutral buffered formalin, embedded in paraffin, sectioned at 5 µm thickness and stained with hematoxylin and eosin (H&E) (Luna, 1968). The left kidney from each bird was preserved in 2.5% aqueous potassium dichromate for parasitological evaluation.

Renal coccidial infection was assessed by three methods in addition to gross examination of the kidneys. Transverse sections through an-

terior, middle and caudal portions of the right kidney were examined histologically. A score from 0 to 3+ was assigned on the presence of lesions in none, one, two or all sections of kidney. The left kidney was homogenized and placed in the Modified Sheather's Sugar Solution for flotation of oocysts (Sloss and Kemp, 1978). The number of oocysts under a single 22 × 22 mm cover slip was counted and a score was assigned: 0 (no oocysts seen), 1+ (1 to 50 oocysts), 2+ (51 to 250 oocysts), 3+ (251 to 1,000 oocysts), 4+ (over 1,000 oocysts). Oocysts were counted in droppings using the Modified McMaster technique (Ministry of Agriculture, Fisheries and Food, 1977). Oocysts in kidney homogenates were identified by the description of Gajadhar et al. (1982).

The intestine was opened and examined for tapeworms. Gizzard worm infection was assessed by gross examination of the transversely sectioned gizzard musculature and by microscopic examination of one H&E-stained, transverse section through the posterior-half of the each gizzard. Prevalence of cecal nematodes was determined by gross examination of ceca and by microscopic examination of one H&E-stained, transverse section through the middle of one cecum. Blood films were stained with Wright's Giemsa and examined for the presence of hematozoa in the laboratory of the Veterinary Service Branch, Manitoba Agriculture, Winnipeg, Manitoba.

Chi-square (χ^2) with Yates correction for continuity (Zar, 1984) was used to determine differences in prevalence of conditions in birds from coastal and inland areas, and to compare the sensitivity of techniques for detecting parasites. Oocyst counts in droppings, body and organ weight, and linear measurements of goslings were compared using the Mann-Whitney test (Zar, 1984). Statistical significance was assumed at $P \leq 0.05$.

RESULTS

Goslings were approximately 5-wk old when collected. The sex ratio in the entire sample of 74 birds was 66% male: 34% female. Most (76%) goslings were in the white phase. There was no significant difference in sex or color ratio between samples from coastal and inland areas. Body and organ weights were not significantly different between sexes within either the coastal or inland areas; so, for analysis of these parameters, the 38 birds from coastal sites were treated as one pool and the 36 birds from inland sites were treated as

a second pool. The mean (\pm SD) body weight of goslings was greater in the inland area (1289 ± 145 g) than in the coastal area ($1,118 \pm 169$ g) ($P < 0.0001$). Mean (\pm SD) weights of the bursa of Fabricius and spleen were greater in goslings from inland sites than in those from the coast (0.75 ± 0.19 g versus 0.64 ± 0.24 g, $P = 0.03$; 2.3 ± 2.7 g versus 1.1 ± 0.8 g, $P = 0.01$, respectively). Mean weights of the liver, thymus, and intestine were not significantly different between the groups. There was no significant difference in the proportion of liver weight to body weight between goslings from inland and coastal areas. The mean (\pm SD) ratio of intestine weight to body weight was significantly less ($P < 0.008$) in goslings from inland (0.053 ± 0.005) than from coastal (0.058 ± 0.010) areas. Birds from inland sites were significantly larger than birds of the same sex from the coastal area in all linear measurements, except length of the ninth primary feather (males and females) and total length (females). No measurable fat was found in any of the goslings; the average thickness of pectoral muscle was not significantly different in birds from the two sites. Based on the ratio of body weight to tarsus length, goslings from inland sites were in better body condition than those from the coast (16.2 ± 1.5 vs. 14.8 ± 1.9 , $P = 0.0008$).

Gross lesions associated with renal coccidia were observed in 28 (74%) of 38 goslings from the coast. Affected kidneys were enlarged to double or triple their normal size and were friable, mottled, and brown-beige (Fig. 2). None of 36 goslings from inland sites had grossly visible renal lesions. The mean (\pm SD) weight of the left kidney of goslings from the coast (9.8 ± 3.1 g) was almost double that of goslings from inland (5.5 ± 0.9 g) ($P < 0.0001$). Microscopic lesions of coccidial infection were found in significantly more birds from the coast (35 of 38, 92%) than in birds from inland (12 of 36, 33%) ($P < 0.0001$). Microscopic parasite stages from gamonts to oocysts were found in renal tu-

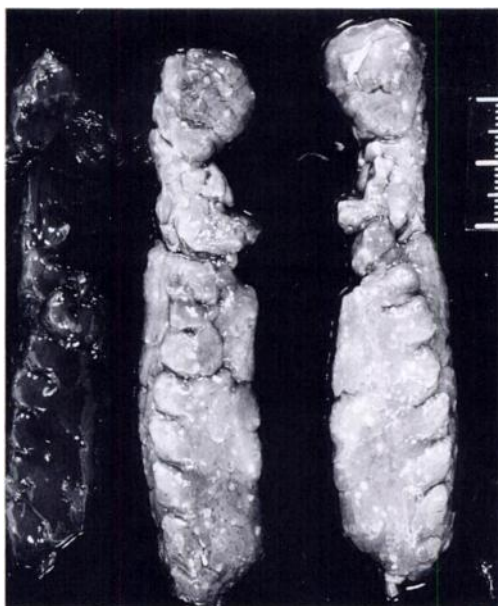

FIGURE 2. Kidneys from a gosling from the coastal area with renal coccidiosis (center, right) and from an uninfected lesser snow goose gosling from the inland area (left). The infected kidneys are swollen, pale and contain many 1 to 2 mm white foci. Scale is in mm.

bular epithelial cells of infected birds. Renal tubular epithelium was hyperplastic in association with parasite infection and moderate numbers of mononuclear inflammatory cells were present in the renal parenchyma. Granulomas were observed occasionally surrounding collections of oocysts. Morphologically, oocytes found in the kidney homogenates were similar to those of *Eimeria truncata*. Histology was more sensitive than gross examination for detection of coccidial infection ($P < 0.003$). Oocysts were detected in homog-

enates of the left kidney of 34 of (90%) 38 birds from coastal areas and 19 (53%) of 36 birds from inland sites. The sensitivity of histology and examination of kidney homogenates for oocysts were not different in severely affected birds, but more birds with mild renal coccidial infections were detected by the homogenization-oocyst count method than by histology. Oocysts were found in droppings from 37 (97%) of 38 goslings from the coast and 23 (64%) of 36 from inland sites. The mean (\pm SD) number of oocysts in droppings was greater in the coastal area ($66,054 \pm 115,236$) than in the inland area ($2,953 \pm 9,046$) ($P < 0.0001$). The mean number of oocysts found in droppings generally paralleled the number seen in the kidney homogenates; however, there was considerable overlap among groups (Table 1). Coccidia were not detected histologically in the intestine of any gosling.

Nematode infection of the gizzard was associated with 1 to 2 mm, brown-black foci in the muscle, approximately 1 to 2 cm below the koilin layer. No intact worms were recovered for identification. Microscopically, the foci consisted of inflammation about intact or degenerate worms. Gross or microscopic lesions were observed in the gizzard of 34 (89%) of 38 goslings from the coast and in 26 (72%) of 36 birds from inland sites. The prevalence was not significantly different.

Infection of the ceca with an unidentified nematode, possibly *Trichostrongylus* sp., was represented by severe distention of cecae with a white-yellow necrotic core (Fig. 3). Microscopically, nematodes were

TABLE 1. Relationship between the number of coccidial oocysts detected in homogenates of the kidneys and in the droppings of snow goose goslings, west coast of Hudson Bay, Canada, August 1991.

Number sampled	Oocysts in kidney homogenate	Oocysts in droppings	
		Mean	Range
21	None seen	1.3×10^3	0 to 1.7×10^3
22	1 to 50	2.0×10^4	0 to 3.3×10^5
6	51 to 250	6.5×10^4	2.0×10^2 to 3.0×10^5
4	251 to 1,000	4.4×10^4	3.5×10^3 to 5.2×10^5

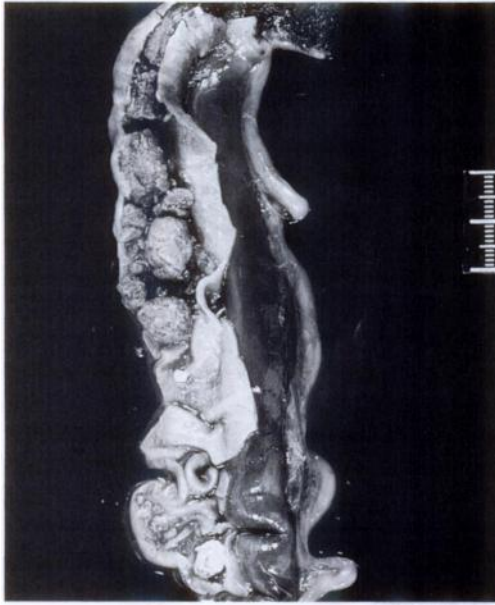


FIGURE 3. Cecum from a lesser snow goose gosling infected with probable *Trichostongylus* spp. nematodes. The cecal wall has been partially reflected to reveal the caseous core filling the lumen. Scale is in mm.

found in the lumen and deep in the mucosa. Gross lesions were present in ceca of 24% of the 74 birds and microscopic lesions were found in 57% of birds. Sensitivity of the two techniques was different ($P < 0.0002$). More birds from the coast (29 of 38, 76%) had cecal lesions than did birds in the inland (13 of 36, 36%) ($P < 0.001$).

Tapeworms (not identified) were found more often in the intestine of birds from the inland area (34 of 38, 89%) than in birds from the coastal area (19 of 36, 53%) ($P < 0.001$). Gamonts of an intracellular protozoan parasite resembling *Leucocytozoon* spp. (Springer, 1991) were found in blood smears, within leukocytes, from 23 (64%) of 36 birds from inland sites and 14 (39%) of 36 birds from coast. The prevalences were not significantly different. No consistent lesions were detected in other tissues (examined microscopically) from goslings from either site.

DISCUSSION

The cause of the mortality of goslings that occurred near the Tha-anne River in the summers prior to this study is unknown. A marked long-term decrease in survival of lesser snow goose goslings has been documented in a colony at La Pérouse Bay (58°43'N 93°27'W), further south along the west coast of Hudson Bay (Fig. 1), in association with habitat degradation (Francis et al., 1992; Williams et al., 1993). The decline in gosling survival at that colony paralleled a decline in gosling growth rate and final body size (Cooch et al., 1991) and there was a marked decrease in gosling survival at about the fifth week after hatch (Williams et al., 1993). Mortality of goslings at La Pérouse Bay may have occurred as a direct result of starvation or through increased vulnerability of undernourished goslings to predation (Williams et al., 1993). The prevalence and effects of parasitism were not assessed, although renal coccidiosis occurs in goslings on that colony (Gajadhar et al., 1982). In our sample, goslings from the degraded coastal habitat not only were smaller and in poorer condition but also had a greater prevalence of renal coccidiosis and cecal nematodes than did goslings from inland. Lesions of renal coccidiosis also were more severe in the coastal birds. Either or both of these parasites could exacerbate effects of malnutrition. Renal coccidiosis can cause severe mortality among domestic goslings (Reid, 1972) and wild waterfowl (Mendenhall, 1976; Tuggle and Crites, 1984a). The lesions caused by the nematodes were similar to those reported for *Epomidiostomum* spp. in lesser snow geese (Tuggle and Crites, 1984b).

The greater prevalence of renal coccidiosis and cecal worm infection in goslings in the coastal area compared to those inland might be related to differences in exposure to infective stages or to diminished resistance to infection. *Coccidia* and *Trichostongylus* spp. have a direct life-cycle and increased exposure to oocysts and eggs

might result from intense grazing on the depleted vegetation in the coastal area. The vegetation in these areas may be heavily contaminated with oocysts and eggs, as Williams et al. (1993) reported a ten-fold increase in the density of droppings on the ground as the population of geese increased over a 9-yr period at La Pèrouse Bay. Alternatively, parasites may flourish in malnourished hosts (Watson, 1984). Habitat degradation resulting in reduced availability of food might act concurrently with parasitism to result in poor growth and mortality of goslings, particularly in the coastal area. We believe that the physiological costs of parasitism need to be considered in assessing this situation.

The severity of renal infection with coccidia could not be assessed accurately in individual birds by counting oocysts in droppings but the average number of oocysts from the inland and coastal areas generally reflected the severity of coccidial infection in the two areas. Determination of the number of oocysts in droppings may be a practical, non-invasive method for monitoring the relative severity of renal coccidial infection among groups of goslings. However, the number of oocyst in droppings might be influenced by factors, such as diet or time since eating or drinking, that cause variable dilution of the droppings. Oocyst counts in droppings might be misleading if intestinal coccidia were present. No coccidia were observed in histologic sections of intestine from any of the goslings from the Tha-Anne River and we assumed that the oocysts found in droppings were of renal origin.

ACKNOWLEDGMENTS

We thank Brent Wagner, Department of Veterinary Microbiology, University of Saskatchewan for parasitological evaluations; Jazeem Wahab, Department of Horticulture Science, University of Saskatchewan, for assistance in statistical analysis; Donna Bigelow, Arctic College, Arviat, Northwest Territories; Rob Mulders, Renewable Resources, Government of the Northwest Territories, Arviat; Brian Shrock and Steve Miller, Midwest Helicopters, for assistance with field collections; and technical staff,

Department of Veterinary Pathology, University of Saskatchewan, for histology and photographic services.

LITERATURE CITED

- COOCH, E. G., D. B. LANK, R. F. ROCKWELL, AND F. COOKE. 1991. Long-term decline in body size in a snow goose population: Evidence of environmental degradation. *Journal of Animal Ecology* 60: 483–496.
- FRANCIS, C. M., M. H. RICHARDS, AND F. COOKE. 1992. Long-term changes in survival rates of lesser snow geese. *Ecology* 73: 1346–1362.
- GAJADHAR, A. A., R. J. CAWTHORN, AND D. J. RAINNIE. 1982. Experimental studies on the life cycle of a renal coccidium of lesser snow geese (*Anser c. caerulescens*). *Canadian Journal of Zoology* 60: 2085–2092.
- KERBES, R. H. 1973. The nesting population of lesser snow geese in the eastern Canadian Arctic: A photographic inventory. Report series. No. 35, Canadian Wildlife Service, Saskatoon, Canada. pp. 5–39.
- , P. M. KOTANEN, AND R. L. JEFFERIES. 1990. Destruction of wetland habitats by lesser snow geese: A keystone species on the west coast of Hudson Bay. *Journal of Applied Ecology* 27: 242–258.
- LUNA, L. G. 1968. Manual of histologic staining methods of the Armed Forces Institute of Pathology, 3rd ed. McGraw-Hill Book Co., New York, New York, 258 pp.
- MACINNES, C. D., AND R. H. KERBES. 1987. Growth of the snow goose (*Chen caerulescens caerulescens*) colony at McConnell River, NWT, 1940–1980. *Canadian Field-Naturalist* 101: 33–39.
- MENDENHALL, V. 1976. Survival and causes of mortality in eider ducklings on the Ythan Estuary, Aberdeenshire. *Wildfowl* 27: 160.
- MINISTRY OF AGRICULTURE, FISHERIES AND FOOD. 1977. Manual of veterinary parasitological laboratory techniques, 2nd ed. Technical Bulletin No. 18, London, England, pp. 5–7.
- PAKALAK, A. J., AND R. K. SCHMIDT. 1973. A helicopter drive-trap technique for capturing Canada geese. M.S. Report 73-3, Manitoba Department of Mines, Resources, and Environmental Management, Winnipeg Manitoba, 15 pp.
- REID, W. M.. 1972. Coccidiosis. In *Diseases of poultry*, 6th ed., M. S. Hofstad, B. W. Calnek, C. F. Helmboldt, W. M. Reid, and H. W. Yoder, Jr. (eds.). Iowa State University Press, Ames, Iowa, pp. 944–989.
- SLOSS, M. W., AND L. KEMP. 1978. *Veterinary clinical parasitology*, 5th. ed. Iowa State University Press, Ames, Iowa, pp. 7–19.
- SPRINGER, W. T. 1991. In *Diseases of poultry*, 9th ed., B. W. Calnek (ed.). Iowa State University Press, Ames, Iowa, pp. 814–817.

- TUGGLE, B. N., AND J. L. CRITES. 1984a. Renal coccidiosis in interior Canada geese, *Branta canadensis interior* Todd, of the Mississippi Valley population. *Journal of Wildlife Diseases* 20: 272-278.
- , AND ———. 1984b. The prevalence and pathogenicity of gizzard nematodes of the genera *Amidostomum* and *Epomidiostomum* (Trichostrongylidae) in the lesser snow goose (*Chen caerulescens caerulescens*). *Canadian Journal of Zoology* 62: 1849-1852.
- WATSON, R. R. 1984. Clinical and experimental nutrition/Nutrition, disease resistance, and immune function. Marcel Dekker, Inc., New York, New York, pp. 3-32.
- WILLIAMS, T. D., E. G. COOCH, R. L. JEFFERIES, AND F. COOKE. 1993. Environmental degradation, food limitation and reproductive output: Juvenile survival in lesser snow geese. *Journal of Animal Ecology* 62: 766-777.
- ZAR, J. H. 1984. *Biostatistical analysis*, 2nd ed. Prentice Hall, Englewood Cliffs, New Jersey, 718 pp.

Received for publication 8 May 1995.