

Acute Gastric Dilatation with Volvulus in a Northern Fur Seal (*Callorhinus ursinus*)

Authors: Frasca, S., Dunn, J. Lawrence, and Van Kruiningen, Herbert J.

Source: Journal of Wildlife Diseases, 32(3) : 548-551

Published By: Wildlife Disease Association

URL: <https://doi.org/10.7589/0090-3558-32.3.548>

BioOne Complete (complete.BioOne.org) is a full-text database of 200 subscribed and open-access titles in the biological, ecological, and environmental sciences published by nonprofit societies, associations, museums, institutions, and presses.

Your use of this PDF, the BioOne Complete website, and all posted and associated content indicates your acceptance of BioOne's Terms of Use, available at www.bioone.org/terms-of-use.

Usage of BioOne Complete content is strictly limited to personal, educational, and non - commercial use. Commercial inquiries or rights and permissions requests should be directed to the individual publisher as copyright holder.

BioOne sees sustainable scholarly publishing as an inherently collaborative enterprise connecting authors, nonprofit publishers, academic institutions, research libraries, and research funders in the common goal of maximizing access to critical research.

Acute Gastric Dilatation with Volvulus in a Northern Fur Seal (*Callorhinus ursinus*)

S. Frasca, Jr.,¹ J. Lawrence Dunn,² and Herbert J. Van Kruiningen,^{1,1} Northeastern Research Center for Wildlife Diseases, Department of Pathobiology, University of Connecticut, Storrs, Connecticut 06269-3089, USA; ² Mystic Marinelife Aquarium, 55 Coogan Boulevard, Mystic, Connecticut 06355-1997, USA

ABSTRACT: Acute gastric dilatation with volvulus occurred in a 4-year-old female northern fur seal (*Callorhinus ursinus*). The animal had been maintained in an outdoor exhibit at Mystic Marinelife Aquarium (Mystic, Connecticut, USA) from June 1989 to March 1994. On necropsy, we observed a 360° clockwise rotation of the stomach about its mesenteric axis as viewed ventrodorsally. The stomach was markedly distended with gas, fluid, and partially digested fish. The spleen followed the rotation of the stomach 360° and was enlarged and congested with twisted mesentery. This is the first reported case of acute gastric dilatation with volvulus in a pinniped.

Key words: Acute gastric dilatation, *Callorhinus ursinus*, gastric, northern fur seal, otariid, pinniped, stomach.

Acute gastric dilatation (AGD) is an infrequently occurring, life-threatening disease of humans and other mammals (Van Kruiningen et al., 1974) and is characterized by voluminous gas and fluid distention of the stomach, respiratory and cardiac compromise, collapse, and death (Stein et al., 1981). There are four morphologic variations: AGD; AGD with volvulus; AGD with rupture; and AGD with volvulus and rupture (Van Kruiningen et al., 1974). The cause involves the interaction of a susceptible individual, an abnormal stomach, readily fermentable feeds (Rogolsky and Van Kruiningen, 1978), and gas-producing gastric flora (Rogolsky and Van Kruiningen, 1978). We report the diagnosis of AGD with volvulus in a subadult female northern fur seal (*Callorhinus ursinus*) maintained at the Mystic Marinelife Aquarium, Mystic, Connecticut (USA) from June 1989 to March 1994. This animal had a 3-yr history of foreign body ingestion, intermittent mild to moderate abdominal distention accompanied by flatulence, and intermittent vomiting. To our

knowledge, this is the first report of AGD with volvulus in a pinniped. Intestinal volvulus has been reported in a bowhead whale (*Balaena mysticetus*) (Heidel and Albert, 1994) and two captive Australian fur seals (*Arctocephalus pusillus doriferus*) (Reddacliff, 1988).

The subject was a 4-yr-old, 29 kg, captive-born, female northern fur seal that had been maintained along with other conspecifics in an outdoor exhibit (Spotte, 1980). Its daily ration consisted of 2.8 kg of whole Atlantic herring (*Clupea harengus harengus* Linnaeus), capelin (*Mallotus villosus*), and squid (*Loligo pealei*) which was provided in two feedings, mid-morning and mid-afternoon.

This animal had a 3-yr history of intermittent vomiting punctuated by three episodes (August 1990, January 1991, and June 1992) of moderate abdominal distention observed during feedings. In each instance, the fur seal was removed from the exhibit for closer observation in an indoor pool. No vomiting nor changes in passed feces were observed, and, each time, administration of 262 mg of bismuth subsalicylate (Guardian Drug Co., Trenton, New Jersey, USA) per os (PO) every 8 hr and 80 mg of simethicone (IDE Interstate, Inc., Amityville, New York, USA) PO every 8 hr resulted in mild decreases in abdominal distention and flatulence. On each occasion, hemograms and serum biochemical analyses of blood samples taken from the interdigital veins of the hindflippers were within the Aquarium's reference ranges for this species.

This animal had a propensity for swallowing objects that were carelessly dropped or tossed into the exhibit by aquarium visitors. In July 1993, in prepa-

ration for survey radiography, it was anesthetized by inhalation in an anesthetic chamber (Mystic Marinelife Aquarium) using isoflourane (Anaquest, Madison, Wisconsin, USA) as the induction and maintenance agent. Induction was accomplished using 5% isoflourane at 5 liters/min, and the animal was intubated with a 7.5 mm in diameter endotracheal tube (Rusch, Inc., Duluth, Georgia, USA). Based on radiographs of the abdomen, the stomach was moderately distended with gas and contained several coins in the antrum and pylorus. Based on hemograms, serum biochemical analyses, and zinc and copper analysis (Diagnostic Laboratory, New York State College of Veterinary Medicine, Ithaca, New York) of a venous blood sample, there were no abnormalities.

The animal continued swallowing objects before they could be retrieved from the pool, and there were intermittent episodes of vomiting, flatulence, and abnormal swimming postures over the next 6 mo. In January 1994, preparatory to an endoscopic examination of the esophagus and stomach, the animal was premedicated with 5 mg diazepam (Steris Laboratories, Inc., Phoenix, Arizona, USA) administered intramuscularly (IM) into the superficial gluteal muscle and anesthetized by inhalation using isoflourane. Based on endoscopic examination of the stomach, there were no mucosal abnormalities nor foreign materials.

On the morning of 4 March 1994, the animal was found dead in its pool (water temperature 8 C) 15 hr after it had consumed its normal ration. No abnormal postures nor behaviors had been observed prior to death. The carcass was maintained at 4 C until necropsy.

Necropsy was conducted 6 hr after the animal was found dead. The stomach was markedly distended, measuring 30 cm in length and 18 cm in width. The thoracic viscera were compressed into the cranial one-third of the thorax. As viewed ventrodorsally, there was a 360° clockwise rota-

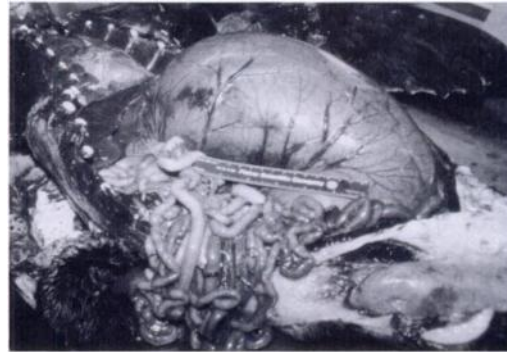


FIGURE 1. Acute gastric dilatation with volvulus in a subadult northern fur seal. The stomach is severely distended and turgid with prominent serosal blood vessels. A 15 cm rule is included for size reference.

tion of the stomach and spleen about the gastric mesenteric axis. The spleen lay in the left cranioventral abdominal quadrant, and the duodenum was between the cardia of the stomach and the liver, entwined around the distal esophagus. The stomach was greatly enlarged and tense; its serosal surface was smooth and uniformly gray-purple with prominent blood vessels (Fig. 1). It contained a large amount of gas, fluid, and partially digested fish and squid. Seven coins measuring up to 2 cm in diameter were present within the antrum. The gastric mucosa was diffusely purple. The spleen was enlarged, soft, and smooth with rounded edges and twisted mesentery.

Tissue samples of the thoracic and abdominal viscera were fixed in 10% neutral buffered formalin (Spartan Chemical Co., Inc., Toledo, Ohio, USA), embedded in paraffin, sectioned at 3 μ m, and stained with hematoxylin and eosin. Based on a histologic examination, the stomach had marked mucosal congestion with proprial hemorrhage and moderate submucosal edema. A mixed bacterial population including stout, rod-shaped organisms consistent morphologically with *Clostridium* spp was evident in gland lumina and amongst the ingesta adherent to the mucosal surface. The spleen had marked con-

gestion of the red pulp. Pulmonary congestion and edema, adrenocortical hemorrhages, and hepatic hyperemia were also evident.

Acute gastric dilatation with volvulus is multifactorial in origin (Van Kruiningen et al., 1974). The feeding pattern imposed upon domesticated animals is a significant factor determining the likelihood of AGD. Oxen, horses, and dogs, animals that overconsume regularly or intermittently, suffer an increased risk of AGD (Van Kruiningen et al., 1974). In big dogs, large meals consumed once daily appear to predispose the stomach to malfunction, either through chronic stretching and dilatation or through the production of a delayed gastric emptying time (Van Kruiningen et al., 1974). Delayed gastric emptying has been demonstrated in dogs that have recovered from AGD and may contribute to the high frequency of recurrence (Funquist and Garmer, 1967). Although diets are monitored at the aquarium, fur seals consume their ration rapidly with periods of 4 to 20 hr between meals.

The nature of the gastric flora is a second factor that is important in AGD. Animals with abundant gas-producing bacteria, such as clostridia, are prone to develop AGD (Van Kruiningen et al., 1974). In this case, bacteriological culture of stomach contents was not done; however, the large rod-shaped bacteria present within gastric glands and on the surface of the stomach were morphologically consistent with *Clostridium* spp. The history of recurrent abdominal distention and flatulence is evidence for the accumulation or cultivation of a gas-producing gastric flora in this animal over time.

A third factor contributing to AGD is the fermentability of the diet. In domestic animals AGD is attributed to overconsumption of diets high in readily digestible carbohydrates (Van Kruiningen et al., 1974). This was not the case here. The fur seal was fed a diet of whole fish and squid, low in carbohydrates and high in protein and animal roughage such as bone, carti-

lage, scales, fins, and teeth. Indigestible roughage is important for normal gastrointestinal motility (Van Kruiningen et al., 1987), and, as such, this type of diet should not have been conducive to AGD. Diets high in fat could delay gastric emptying (Bolt, 1969); some fish, such as herring (*Clupea harengus*), can significantly elevate the fat content of a diet (Stoddard, 1968).

Antecedent gastric disease is an additional factor contributory to AGD (Van Kruiningen et al., 1974). It is hard to ignore the possible role of ingested coins in the initiation of recurrent gastrointestinal distention and flatulence in this case. Such foreign objects may have resulted in intermittent outflow obstruction and delayed gastric emptying, allowing for the possibility of bacterial overgrowth and subsequent excessive gas production. No gastric disease was documented by radiography and endoscopy; however, function tests using contrast media to evaluate gastric emptying and pyloric activity were not performed.

This case of AGD with volvulus was most likely the result of intermittent gastric malfunction and generation of a gas-producing gastric flora. It seemed unusual that AGD would occur in an animal fed a diet high in protein and roughage and low in fermentable carbohydrates. Nevertheless, such a diet will support abundant growth of bacteria. The mixed bacterial population present in the ingesta adherent to the gastric mucosa of this animal is evidence for such a possibility. Bacteria consistent morphologically with clostridia were identified, although they were outnumbered by other species. The episodes of retching and abdominal distention with flatulence may be interpreted as coin-induced, or, alternatively, they may be taken as prodromal signs of AGD, as seen in dogs (Andrews, 1970). It is most unlikely that the coins found in the stomach were the direct cause of this AGD. Coins in the gastrointestinal tract usually turn sufficiently to allow gas to pass, and there is no

correlation between coins in the stomach and AGD in dogs or children. This case report should alert those caring for pinnipeds of the prodromal features of AGD so that dietary, medical, or surgical measures may be taken preventively.

We acknowledge Dr. David J. St. Aubin and Mr. Robert Nawojchik of Mystic Marinelife Aquarium (Mystic, Connecticut, USA) for editorial comments on the manuscript. This is contribution No. 97 from the Sea Research Foundation. This is Scientific Contribution 1646 from the Storrs Agricultural Experiment Station.

LITERATURE CITED

- ANDREWS, A. H. 1970. A study of ten cases of gastric torsion in the bloodhound. *The Veterinary Record* 86: 689–693.
- BOLT, R. J. 1969. Gastric evacuation and clinical syndromes. *Medical Clinics of North America* 53: 1403–1411.
- FUNQUIST, B., AND L. GARMER. 1967. Pathogenic and therapeutic aspects of torsion of the canine stomach. *Journal of Small Animal Practice* 8: 523–532.
- HEIDEL, J. R., AND T. F. ALBERT. 1994. Intestinal volvulus in a bowhead whale, *Balaena mysticetus*. *Journal of Wildlife Diseases* 30: 126–128.
- REDDACLIFF, G. 1988. Fatal intestinal torsion in two captive fur-seals. *In* *Marine Mammals of Australia: Field biology and captive management*, M. L. Augée (ed). Royal Zoological Society, New South Wales, Mosman, Australia, pp. 135–136.
- ROGOLSKY, B., AND H. J. VAN KRUININGEN. 1978. Short chain fatty acids and bacterial fermentation in the normal canine stomach and in acute gastric dilatation. *Journal of the American Animal Hospital Association* 14: 504–515.
- SPOTTE, S. 1980. Seal Island, a new pinniped exhibit at Mystic Marinelife Aquarium. *In* *International zoo yearbook*, P. J. S. Olney (ed). Zoological Society of London, Regents Park, United Kingdom, pp. 286–295.
- STEIN, F. J., D. H. LEWIS, G. G. SCOTT, AND R. F. SIS. 1981. Acute gastric dilatation in common marmosets (*Callithrix jacchus*). *Laboratory Animal Science* 31: 522–523.
- STODDARD, J. H. 1968. Fat contents of Canadian Atlantic herring. Technical Report No. 79. Fisheries Research Board of Canada, St. Andrews, New Brunswick, Canada, pp. 1–23.
- VAN KRUININGEN, H. J., K. GREGOIRE, AND D. J. MEUTEN. 1974. Acute gastric dilatation: A review of comparative aspects, by species, and a study in dogs and monkeys. *Journal of the American Animal Hospital Association* 10: 294–324.
- , L. D. WOJAN, P. E. STAKE, AND P. F. LORD. 1987. The influence of diet and feeding frequency on gastric function in the dog. *Journal of the American Animal Hospital Association* 23: 145–153.

Received for publication 19 September 1995.