



Avian Pox in Eastern Screech Owls and Barred Owls from Florida

Authors: Deem, Sharon L., Heard, Darryl J., and Fox, Jonathan H.

Source: Journal of Wildlife Diseases, 33(2) : 323-327

Published By: Wildlife Disease Association

URL: <https://doi.org/10.7589/0090-3558-33.2.323>

BioOne Complete (complete.BioOne.org) is a full-text database of 200 subscribed and open-access titles in the biological, ecological, and environmental sciences published by nonprofit societies, associations, museums, institutions, and presses.

Your use of this PDF, the BioOne Complete website, and all posted and associated content indicates your acceptance of BioOne's Terms of Use, available at www.bioone.org/terms-of-use.

Usage of BioOne Complete content is strictly limited to personal, educational, and non - commercial use. Commercial inquiries or rights and permissions requests should be directed to the individual publisher as copyright holder.

BioOne sees sustainable scholarly publishing as an inherently collaborative enterprise connecting authors, nonprofit publishers, academic institutions, research libraries, and research funders in the common goal of maximizing access to critical research.

Avian Pox in Eastern Screech Owls and Barred Owls from Florida

Sharon L. Deem,^{1,3} Darryl J. Heard,¹ and Jonathan H. Fox,^{2,4,1} Department of Small Animal Clinical Sciences, College of Veterinary Medicine, Veterinary Medical Teaching Hospital, Box 100126, Health Science Center, Gainesville, Florida 32610-0126, USA; ² Department of Pathobiology, College of Veterinary Medicine, Veterinary Medical Teaching Hospital, Box 100103, Health Science Center, Gainesville, Florida 32610-0103, USA; ³ Author for reprint requests; ⁴ Present address: Texas Veterinary Medicine Diagnostic Laboratory, PO Drawer 3040, College Station, Texas 77841, USA

ABSTRACT: Avian pox was diagnosed in two eastern screech owls (*Otus asio*) and two barred owls (*Strix varia*) living in different regions of Florida (USA) between November 1994 and October 1995. Avian poxvirus infection was confirmed by the presence of eosinophilic intracytoplasmic epidermal inclusions (Bollinger bodies) on light microscopy of tissue from all four owls. Additionally, typical poxvirus particles were demonstrated by electron microscopy of a lesion from one of the eastern screech owls. These are the first published case reports of avian pox in eastern screech owls and barred owls.

Key words: *Otus asio*, *Strix varia*, avian poxvirus, owl pox virus, screech owls, barred owls.

Members of the family Poxviridae are large double-stranded DNA viruses (up to 400 nm) which infect mammals, reptiles, and birds (Jacobson et al., 1979; Mohanty and Dutta, 1981; Gerlach, 1994). Seventeen types of *Avipoxvirus* spp. have been classified based on isolates from different bird species (Gerlach, 1984). Most members of the *Avipoxvirus* spp. are species-specific; however, some have been reported to cross genus, species, or family barriers (Ritchie and Carter, 1995). Sixty species of birds in over 20 families, including members of the order Falconiformes, are known to be susceptible to avian pox (Graham and Halliwell, 1986; Ritchie and Carter, 1995). However, there are no reports in the English literature of similar infections in any members of the order Strigiformes (Graham and Halliwell, 1986; Ritchie and Carter, 1995). To our knowledge only one case report of avian pox, occurring in a long-eared owl (*Asio otus*), has been published (Chiocco, 1992). Here we describe cases of natural avian pox in two eastern screech owls (*Otus asio*) and two barred owls (*Strix varia*) in Florida (USA).

Case 1, a hand-raised adult, 118.5 g eastern screech owl of unknown sex was evaluated in November 1994 at the Central Florida Zoological Park (28°47'N, 81°17'W) because of a single lesion, 2 to 3 mm diameter, on the proximal interphalangeal joint of digit three on the left foot. The bird was housed in an outdoor flight cage for 3.5 yr prior to evaluation. During this period no other skin lesions were observed.

An abscess was suspected and the owl was treated with an oral trimethoprim/sulfamethoxazole antibiotic combination (Biocraft Laboratories, Inc., Elmwood Park, New Jersey, USA) (30 mg/kg) twice a day for 14 days. On evaluation of the foot 2 wk later, there were multiple raised, 3 to 4 mm diameter, lesions on both feet. The owl was anesthetized with isoflurane (Ohmeda Pharmaceutical Products Division, Inc., Liberty Corner, New Jersey) in oxygen and surgical biopsies from three lesions were submitted for histological examination and electron microscopy. The antibiotic combination was continued postoperatively for 14 days. All foot lesions regressed over the next 3 to 4 mo with no recurrence.

Case 2, an adult, 114 g, eastern screech owl of unknown sex was presented to the Veterinary Medical Teaching Hospital (VMTH) in September 1995 for suspected pox lesions on both feet and the cere. The bird had been permanently captive at a rehabilitation center in Elkton, Florida (29°46'N, 81°25'W) in an outdoor flight cage for 1 yr prior to presentation. The owl had no known past medical problems with the exception of unilateral blindness associated with trauma. On physical examina-

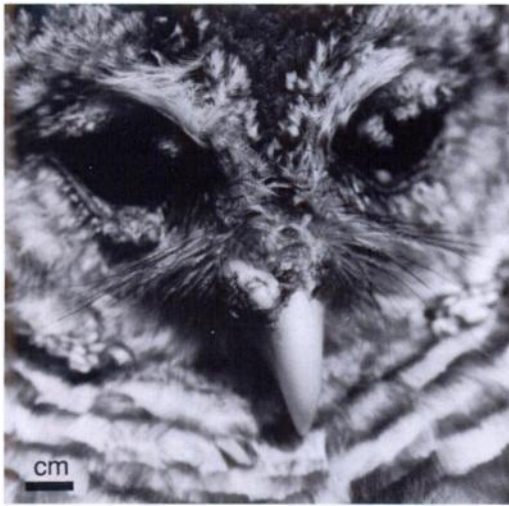

FIGURE 1. Multiple raised pox lesions on the eyelids and cere of a barred owl (*Strix varia*) (Case 3).

tion of the owl, there were multiple raised lesions 2 to 3 mm in diameter associated with ulceration on both feet and one similar lesion on the left naris.

The owl was anesthetized with isoflurane in oxygen. Two lesions on the left foot were surgically excised and submitted for histological examination. The owl was administered an oral trimethoprim/sulfamethoxazole antibiotic combination (30 mg/kg) twice daily for 5 days postoperatively. Two wk after admission the owl was discharged to the rehabilitation center. The owl had no observable lesions 4 wk after the initial examination.

Case 3, was a juvenile, 664-g barred owl of unknown sex presented to the VMTH on 31 August 1995 because of probable pox lesions. The owl had been housed at a rehabilitation center in Silver Springs, Florida (29°13'N, 82°4'W) since 1 May 1995 when it had been admitted as an orphaned fledgling. On 31 July 1995 the referring veterinarian had noted lesions on both eyelids, the third eyelids, and feet. Two other rehabilitated barred owls housed with this bird had no lesions and were released to the wild at this time. Over the next 30 days the owl was treated with oral enrofloxacin (Mobay Corporation Animal Health Division, Shawnee, Kansas,

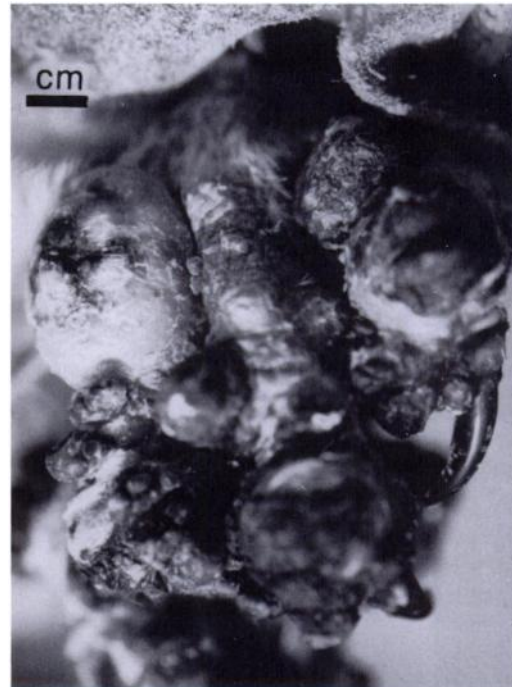

FIGURE 2. Pox lesions on the foot of a barred owl (*Strix varia*) (Case 3).

USA) (15 mg/kg) twice daily and oral itraconazole (Janssen Pharmaceutica, Titusville, New Jersey) (10 mg/kg) once a day to control secondary bacterial infection and to prevent aspergillosis, respectively. The referring veterinarian noted regression of all lesions during this time, but elected to send the bird to the VMTH for definitive diagnosis of a pox virus infection.

On physical examination, the owl was thin with lesions on the cere, partially occluding both nares, and both eyelids (Fig. 1); it also had lesions on the feet (Fig. 2). The owl was anesthetized with isoflurane in oxygen and tissue from two lesions on the left foot and a lesion on the left eyelid was surgically excised and submitted for histological examination. The owl was treated with an oral trimethoprim/sulfamethoxazole antibiotic combination (30 mg/kg) twice daily and oral itraconazole (5 mg/kg) for 10 days postoperatively. The owl was returned to the referring veterinarian in early September. On 3 Novem-

ber 1995 no gross lesions were present and the owl was released to the wild.

Case 4, in October 1995 an adult, 558-g, barred owl of unknown sex was admitted to the VMTH after being hit by a car in Alachua County, Florida (29°39'N, 82°19'W). On initial physical examination there were no cutaneous lesions. A comminuted fracture of the left tibiotarsus was diagnosed radiographically and surgically corrected using a type II external fixator. The owl was then discharged to a local rehabilitator with instructions to re-evaluate in 3 wk.

One wk after discharge the owl was returned to the VMTH with the history of spontaneous development of growths on both eyelids. We observed multiple lesions 2 to 3 mm in diameter, consistent with avian pox on both eyelids, the right third eyelid, and the medial aspect of the left fourth digit. The owl was anesthetized with isoflurane in oxygen and representative tissue from lesions on both eyelids was surgically excised and submitted for histological examination. The rehabilitator was instructed to treat the owl with an ophthalmic triple antibiotic ointment (Smithkline Beecham Animal Health, West Chester, Pennsylvania, USA) in both eyes two to three times a day for 14 days and with an oral trimethoprim/sulfamethoxazole antibiotic combination (30 mg/kg) twice daily for 5 days.

Four wk after initial presentation, the owl was returned to the VMTH for radiographs of the left tibiotarsus. The periocular lesions were resolving on that date (3 wk after initial diagnosis) and completely absent 2 wk later.

Tissues collected from all four owls for light microscopy were fixed in 10% neutral buffered formalin, embedded in paraffin, sectioned at 5 μ m, and stained with hematoxylin and eosin (H & E). Tissue from the first owl used for electron microscopy was diced into 1 mm cubes, fixed in 4% glutaraldehyde, postfixed in 1% osmium tetroxide, dehydrated in alcohol, and embedded in Epon (Electron Microscopy

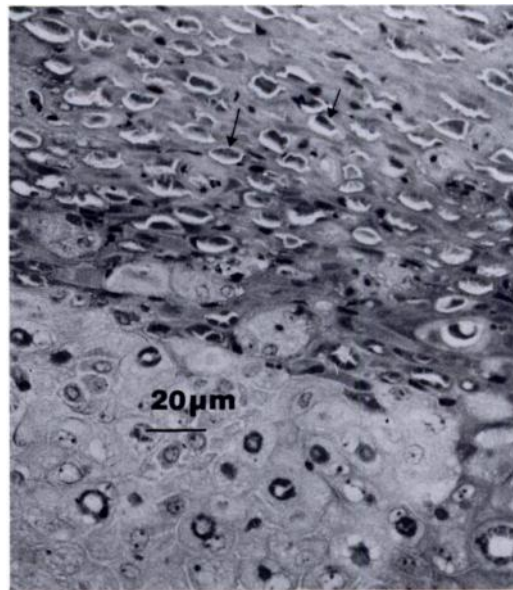


FIGURE 3. Lesion from the foot of an eastern screech owl (*Otus asio*). There is prominent epidermal hyperplasia. Keratinocytes are enlarged, rounded and frequently contain eosinophilic cytoplasmic inclusion bodies (Bollinger bodies) (arrows). H + E. Bar = 20 μ m (Case 1).

Supplies, Fort Washington, Pennsylvania) (University of Florida, Electron Microscopy Core Laboratory, Gainesville, Florida, USA). Thin sections were stained with uranyl acetate and lead citrate and examined using a Hitachi H7000 transmission electron microscope (Hitachi Ltd., Tokyo, Japan).

In the biopsy samples, keratinocytes from each owl contained eosinophilic cytoplasmic inclusions consistent in appearance with Bollinger bodies (Fig. 3). Varying degrees of diffuse epidermal hyperplasia and abnormally enlarged and rounded keratinocytes with pale vacuolated cytoplasm were also present. Additionally, there were moderate superficial dermal infiltrates of heterophils that often extended into the overlying epidermis and several areas of ulceration with overlying serocellular crusting.

On electron microscopic examination, tissue from Case 1 had swollen keratinocytes. There was marked intercellular edema of epidermal tissue. Cytoplasmic inclu-

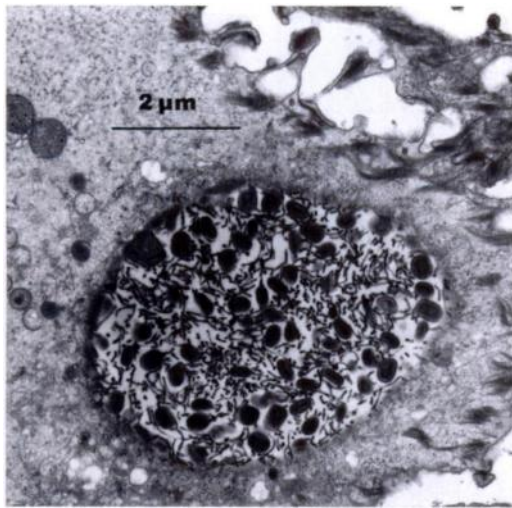


FIGURE 4. Electron micrograph of a lesion from the foot of an eastern screech owl (*Otus asio*) showing a swollen keratinocyte containing a large aggregate of pox virus particles. There is marked intercellular edema with dissociation of intercellular bridges. Bar = 2 μ m (Case 1).

sions were numerous and consisted of arrays of virions ranging in size from 200 to 290×110 to 180 nm (Fig. 4). Virions had a central electron-dense dumbbell shaped biconcave core, lateral bodies and an outer envelope. In some inclusions they were enmeshed with outer coat tubules. Low numbers of virions were noted budding through the plasma membrane.

The clinical, histologic, and electron microscopic findings of these four owls were consistent with poxvirus infection as described in mammals and other avian species (Mohanty and Dutta, 1981; Gerlach, 1994). Grossly, the lesions were representative of self-limiting cutaneous pox infection. This presentation was similar to that reported in other raptor species; no cases of wet (diphtheritic) pox lesions have been reported in raptors (Graham and Halliwell, 1986). The rapid development of pox lesions on one barred owl (Case 4) following a traumatic incident and surgery may support the theory that pox can remain latent and be activated following a stressful incident, as suggested by Garner (1989). However, it is more likely that it repre-

sented a primary infection because latency of avian poxvirus infection has not been confirmed in any avian species.

Although these are the first owl poxvirus case reports in the English literature to our knowledge, pox infections have been observed in various owl species in North America. For example, at the Center for Birds of Prey in Maitland, Florida, poxvirus infection has been confirmed in eastern screech owls and great horned owls (*Bubo virginianus*) by the presence of Bollinger bodies on light microscopy of tissues (C. V. Gilliland, pers. comm.).

In past experimental and natural infections, pox virus was not transmitted to various owl species (Irons, 1934; Wheeldon et al., 1985). Irons (1934) could not experimentally infect monkey-faced owls (*Tyto alba*) and screech owls with mixtures of fowl and pigeon poxviruses. During a poxvirus epornitic, four of the 15 species of raptors housed at a California rehabilitation center developed pox lesions (Wheeldon et al., 1985). None of the six owl species (species not reported) present at the facility became infected. Additionally, an attempt to experimentally infect a great horned owl with material from an unidentified bird naturally infected during the epornitic was unsuccessful.

The four owls we evaluated were housed in outdoor flight cages for varying periods prior to developing pox lesions. Avian poxvirus is resistant to environmental factors, but is incapable of penetrating intact epithelium (Ritchie and Carter, 1995). Two common modes of transmission in birds are traumatic injuries and mosquito bites. Housing owls in outdoor flight cages in captivity could increase exposure by both these modes.

The most important questions in regards to avian poxvirus infection in owls are to determine whether owls represent a new host species; the geographical regions in which owl pox occurs; the routes of transmission; whether high density housing such as rehabilitation centers increases the incidence of infection; and

how owl pox virus is related to other avian poxviruses.

We gratefully acknowledge the zoological staff at the Central Florida Zoo, Sue Billiar, Melanie Cain-Stage, and Leslie Straub for referring these patients to the VMTH. Karen Vaughn provided electron microscopy technical support and Pamela Ginn gave advice on histologic and electron micrograph results. Avery Bennett, Don Forrester, Jack Gaskin, and Elliott Jacobson provided editorial input. This manuscript is published as College of Veterinary Medicine, University of Florida, Journal Series #462.

LITERATURE CITED

- CHIOCCO, D. 1992. Pox virus del gufo: Isolamento e prove di immunità crociata nei polli. *Acta Medica Veterinaria* 38: 261–266.
- GARNER, M. M. 1989. Bumblefoot associated with poxvirus in a wild golden eagle (*Aquila chrysaetos*). *Companion Animal Practice* 19: 17–20.
- GERLACH, H. 1984. Virus diseases in pet birds. *The Veterinary Clinics of North America: Small Animal Practice* 14: 299–316.
- . 1994. Viruses. In *Avian medicine: Principles and applications*, B. W. Ritchie, G. J. Harrison, and L. R. Harrison (eds.), Wingers Publishing, Incorporated, Lake Worth, Florida, pp. 862–948.
- GRAHAM, D. L., AND W. H. HALLIWELL. 1986. Viral diseases of birds of prey. In *Zoo and wild animal medicine*, M. E. Fowler (ed.), W. B. Saunders, Philadelphia, Pennsylvania, pp. 408–413.
- IRONS, V. 1934. Cross-species transmission studies with different strains of bird-pox. *American Journal of Hygiene* 20: 329–351.
- JACOBSON, E. R., J. POPP, R. P. SHIELDS, AND J. M. GASKIN. 1979. Poxlike virus associated with skin lesions in captive caimans. *Journal of the American Veterinary Medical Association* 175: 937–940.
- MOHANTY, S. B., AND S. K. DUTTA. 1981. *Veterinary virology*. Lea and Febiger, Philadelphia, Pennsylvania, pp. 18–21.
- RITCHIE, B. W., AND K. CARTER. 1995. *Avian viruses: Function and control*. Wingers Publishing, Incorporated, Lake Worth, Florida, pp. 285–311.
- WHEELDON, E. B., C. J. SEDGWICK, AND T. A. SCHULZ. 1985. Epornitic of avian pox in a raptor rehabilitation center. *Journal of the American Veterinary Medical Association* 187: 1202–1204.

Received for publication 14 May 1996.