



## **Demodex sp. in California Ground Squirrels**

Authors: Waggie, Kimberly S., and Marion, Patricia L.

Source: Journal of Wildlife Diseases, 33(2) : 368-370

Published By: Wildlife Disease Association

URL: <https://doi.org/10.7589/0090-3558-33.2.368>

---

BioOne Complete ([complete.BioOne.org](https://complete.BioOne.org)) is a full-text database of 200 subscribed and open-access titles in the biological, ecological, and environmental sciences published by nonprofit societies, associations, museums, institutions, and presses.

Your use of this PDF, the BioOne Complete website, and all posted and associated content indicates your acceptance of BioOne's Terms of Use, available at [www.bioone.org/terms-of-use](https://www.bioone.org/terms-of-use).

Usage of BioOne Complete content is strictly limited to personal, educational, and non - commercial use. Commercial inquiries or rights and permissions requests should be directed to the individual publisher as copyright holder.

---

BioOne sees sustainable scholarly publishing as an inherently collaborative enterprise connecting authors, nonprofit publishers, academic institutions, research libraries, and research funders in the common goal of maximizing access to critical research.

## Demodex sp. in California Ground Squirrels

Kimberly S. Waggle<sup>1</sup> and Patricia L. Marion,<sup>2</sup> <sup>1</sup> Department of Comparative Medicine, Stanford University School of Medicine, Stanford, California 94305-5410, USA; <sup>2</sup> Division of Gastroenterology, Department of Medicine, Stanford University School of Medicine, Stanford, California 94305-5487, USA

**ABSTRACT:** An undescribed species of *Demodex* (Acari: Demodecidae) was observed in hair follicles and ducts of sebaceous glands in the ear canals of seven California ground squirrels (*Spermophilus beecheyi*) from Santa Clara County, California (USA). The animals had died of unrelated causes and were submitted for necropsy between September 1994 and February 1996. Similar mites were observed in the lumens of hair follicles and ducts of Meibomian glands in the eyelids of two of these squirrels. Microscopic changes in the epithelium and surrounding dermis, when present, were minimal. No associated clinical signs of disease or macroscopic lesions were observed. To our knowledge, this is the first report of *Demodex* sp. in a ground squirrel.

**Key words:** *Demodex* sp., Acari, Demodecidae, California ground squirrel, *Spermophilus beecheyi*, Sciuridae, rodent.

The California, or Beechey, ground squirrel (*Spermophilus beecheyi*) inhabits the grasslands and fields of the Pacific coast states from southern Washington (USA) to the northern Baja peninsula of Mexico (Burt and Grossenheider, 1976). A hepadnavirus closely related to human hepatitis B virus has been found in these animals, and individuals have been trapped and studied as an animal model of hepatitis B (Marion, 1988).

From September 1994, to February 1996, nine animals from a captive ground squirrel hepadnavirus study colony at Stanford University died unexpectedly and were submitted for necropsy. The animals had been in captivity from 2 days to slightly under 3.5 yr and were adults ranging in age from approximately 1- to 6-yr-old. All had been live trapped (Tomahawk Live Traps, Tomahawk, Wisconsin, USA) from locations in Santa Clara County, California, USA (37°25'N, 122°14'W and 37°24'N, 121°56'W). Upon examination, the index case had a subcutaneous abscess

which paralleled the left external ear canal. The ear canal and surrounding tissues were fixed in 10% buffered formalin, embedded in paraffin, sectioned at 5  $\mu$ m, stained with hematoxylin and eosin, and examined with a light microscope. The ducts of the sebaceous glands associated with the epidermis of the canal were dilated and contained multiple cross and longitudinal sections of an undescribed species of *Demodex*. Mites were found in the lumens of hair follicles and ducts of sebaceous glands in the ear canals of six of eight ground squirrels examined subsequently (Fig. 1). The eyelids of two of these ground squirrels also were examined microscopically and *Demodex* sp. found in the lumens of hair follicles and Meibomian gland ducts. Mites were not observed in hair follicles or adnexa of adjacent skin. In addition to dilatation of the lumens of hair follicles and ducts of sebaceous glands there was mild to moderate compression of the epithelium subjacent to the mites. Additional changes varied between animals and included moderate hyperplasia (orthokeratotic hyperkeratosis) of the stratum corneum of the epithelium of the sebaceous gland ducts and hair follicles, loss of occasional hair shafts, and low numbers of mononuclear cells and rare neutrophils scattered through the adjacent dermis. In intensely infected ear canals there was also hyperkeratosis of the epithelium lining the canal. Cross and longitudinal sections of *Demodex* sp. were admixed with the keratin of the lining epithelium.

A skin scraping of the ear canal of one ground squirrel yielded numerous adult mites. These ranged from 190 to 280  $\mu$ m in length and 30 to 40  $\mu$ m in width (mean from 18 mites = 236.2  $\mu$ m by 34.4  $\mu$ m) (Fig. 2).

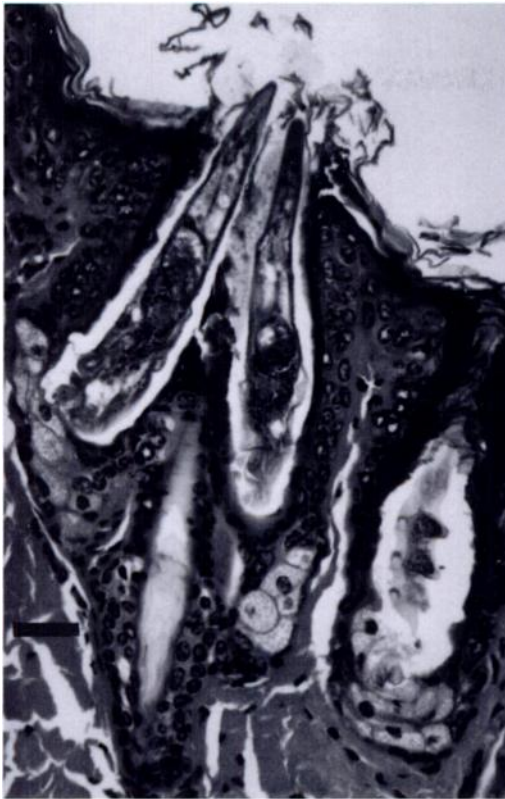


FIGURE 1. Ground squirrel ear canal. The lumens of hair follicles and sebaceous gland ducts are expanded by the undescribed *Demodex* sp. Note the lack of associated inflammation. H&E stain. Bar = 30  $\mu$ m.

*Demodex* spp. have been described in a wide variety of wild and domestic mammals as well as in humans (Nutting, 1964). They inhabit hair follicles and adnexal glands in numerous locations on the bodies of their hosts. These mites are generally species specific; however, several species of *Demodex* may parasitize the same host. In such cases, each species is restricted to a particular habitat. An example of this is human infection with *D. folliculorum*, which lives in the hair follicles of the face, and *D. brevis*, which inhabits the sebaceous glands (Bowman, 1995). *Demodex* spp. are believed to be transmitted between hosts by direct contact and usually do not cause clinical signs of disease. In some species, such as dogs infected with *Demodex canis*, *De-*

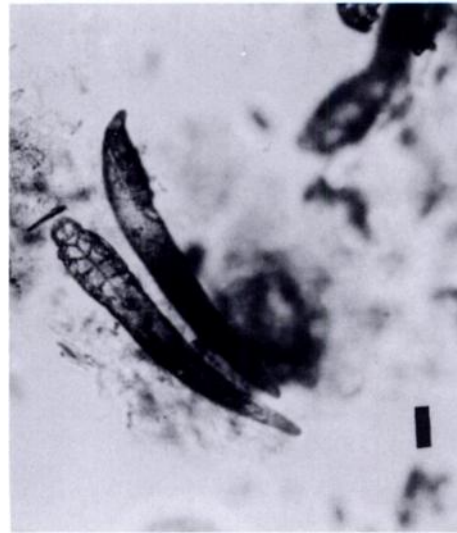

FIGURE 2. Whole mount *Demodex* sp. in skin scraping from ground squirrel ear canal. Bar = 28.4  $\mu$ m.

*modex* spp. can produce mild to severe dermatitis (McDaniel, 1979).

No clinical signs of disease related to *Demodex* sp. infection were observed in the ground squirrels of this report and microscopic changes related to the mites were minor. It is not known if the *Demodex* sp. which inhabits the pilosebaceous complexes of the ear canal of *S. beecheyi* is the same as that found in the Meibomian glands of the eyelids. This answer, as well as detailed description and classification of the organisms and determination of prevalence in wild populations awaits further study. To our knowledge, this is the first report of a species of *Demodex* in *S. beecheyi*. Specimens of this mite have been deposited in the U.S. National Parasite Collection, Beltsville, Maryland (USNPC No. 86897).

#### LITERATURE CITED

- BOWMAN, D. D. 1995. Georgis' parasitology for veterinarians, 6th ed. W. B. Saunders Co., Philadelphia, Pennsylvania, pp. 71-72.
- BURT, W. H., AND R. B. GROSSENHEIDER. 1976. A field guide to the mammals of America north of Mexico. Houghton Mifflin Co., Boston, Massachusetts, pp. 96-97.
- MARION, P. L. 1988. Use of animal models to study

- hepatitis B virus. *In* Progress in medical virology, Vol. 35, J. L. Melnick (ed.). S. Karger AG, Basel, Switzerland, pp. 43-75.
- MCDANIEL, B. 1979. How to know the mites and ticks. Wm. C. Brown Co., Dubuque, Iowa, pp. 192-193.
- NUTTING, W. B. 1964. Demodicidae-status and prognostics. *Acarologia* 6: 441-454.

*Received for publication 4 June 1996.*