

## **Giardiasis in Ringed Seals from the Western Arctic**

Authors: Olson, Merle E., Roach, Patrick D., Stabler, Matt, and Chan, Wendy

Source: Journal of Wildlife Diseases, 33(3) : 646-648

Published By: Wildlife Disease Association

URL: <https://doi.org/10.7589/0090-3558-33.3.646>

---

BioOne Complete ([complete.BioOne.org](https://complete.BioOne.org)) is a full-text database of 200 subscribed and open-access titles in the biological, ecological, and environmental sciences published by nonprofit societies, associations, museums, institutions, and presses.

Your use of this PDF, the BioOne Complete website, and all posted and associated content indicates your acceptance of BioOne's Terms of Use, available at [www.bioone.org/terms-of-use](https://www.bioone.org/terms-of-use).

Usage of BioOne Complete content is strictly limited to personal, educational, and non - commercial use. Commercial inquiries or rights and permissions requests should be directed to the individual publisher as copyright holder.

---

BioOne sees sustainable scholarly publishing as an inherently collaborative enterprise connecting authors, nonprofit publishers, academic institutions, research libraries, and research funders in the common goal of maximizing access to critical research.

## Giardiasis in Ringed Seals from the Western Arctic

Merle E. Olson,<sup>1</sup> Patrick D. Roach,<sup>2</sup> Matt Stabler,<sup>3</sup> and Wendy Chan<sup>1</sup> <sup>1</sup> Gastrointestinal Research Group, Faculty of Medicine, University of Calgary, Calgary, Alberta Canada; <sup>2</sup> Indian and Northern Affairs, Whitehorse, Yukon Territory, Canada; and <sup>3</sup> Joint Secretariat, Inuvik, Northwest Territories, Canada

**ABSTRACT:** Sixteen beluga whales (*Delphinapterus leucas*) and fifteen ringed seals (*Phoca hispida*) from the western arctic region of Canada were examined for giardiasis and cryptosporidiosis. Intestinal contents from the rectum and colon were collected from animals slaughtered by Inuit hunters. A fluorescent monoclonal antibody identified *Giardia* sp. cysts in three of 15 (20%) seals. Thus, ringed seals are implicated as a potential reservoir for this zoonosis in the arctic.

**Key words:** Beluga whale, *Cryptosporidium* sp., *Delphinapterus leucas*, *Giardia* sp., *Phoca hispida*, ringed seal, survey.

*Giardia* spp. and *Cryptosporidium* spp. have been reported in a number of wild mammals and birds. Cysts of *Giardia* spp. are prevalent in water and in the feces of land mammals in arctic and subarctic regions of Canada (Roach et al., 1993). Northern waters provide an ideal environment for sustaining this parasite. A high percentage of native Inuit (30%) on Baffin Island have giardiasis (Eaton and White, 1976) and epidemics of giardiasis in northern communities such as Kodiak and Ketchikan (Alaska, USA) have been reported (Pugh, 1985; Dean et al., 1990). The source of these infections is unknown, but marine mammals may be important reservoirs. In addition, cysts of *Giardia* sp. and oocysts of *Cryptosporidium* sp. have recently been identified in marine waters (Johnson et al., 1995).

Although numerous gastrointestinal parasites have been described in marine mammals, there are no reports of *Giardia* sp. or *Cryptosporidium* sp. (Johnston and Ridgeway, 1969; Margolis and Dailey, 1972; Wazura et al., 1986; Geraci and St. Aubin, 1987; Onderka, 1989). The objective of this study was to determine if two common marine mammals of the western arctic region of Canada, the beluga whale (*Delphinapterus leucas*) and ringed seal

(*Phoca hispida*), had giardiasis and/or cryptosporidiosis.

All samples were collected throughout the spring, summer and fall of 1994 and 1995. Beluga whales (n = 16) were harpooned by Inuit hunters off the coast of Shingle Point, Yukon (Canada; 69°00'N, 137°21'W) and Hendrickson Island, Northwest Territories (Canada; 69°28'N, 133°38'W). Samples were collected within 2 hr of death, when the animals were brought to shore for slaughter. A 5 to 10 cm length of the colon and rectum, including the intestinal contents, were removed from each animal and placed in a vial containing 10% neutral buffered formalin. Samples from the duodenum, jejunum and ileum also were collected for histological examination and fixed in 10% neutral buffered formalin. Ringed seals were shot by local hunters in the area of Holman, Northwest Territories (70°44'N, 117°45'W) and along the Yukon North Slope, near Shingle Point (68°59'N, 137°21'W), by local hunters. These samples were collected within 1 hr of death. The abdomen was opened and the rectum was identified. The feces within the rectum were removed as for the beluga whale samples and placed in a vial containing 10% neutral buffered formalin.

Each fecal sample was filtered through a surgical gauze sponge (4 Ply Nu-gauze, Johnson and Johnson, Montreal, Quebec, Canada), washed with PBS, and expressed from the gauze to yield approximately 7 ml of filtrate. In order to clarify the sample, the filtrate was layered over 5 ml of 1M sucrose (specific gravity = 1.18). The sample was then centrifuged at 800 × g for 5 min to concentrate cysts at the sucrose/water interface. The interface and the upper layer of liquid were transferred by pipette

to a separate clean tube and re-centrifuged at  $800 \times g$  for 5 min. The supernatant was decanted, and the pellet was suspended in PBS to a volume of 1 ml.

Two samples (0.015 ml) of the concentrate were distributed over the frosted rings (1.5 cm diameter) of a fluorescent microscope slide (Erie Scientific Company, Portsmouth, New Hampshire, USA) and air dried for at least 30 min on a 37 C slide warmer. Next, the slide was fixed with acetone for 1 min and air dried. A fluorescein isothiocyanate (FITC)-labelled monoclonal antibody solution (0.02 ml) which detects the cysts of *Giardia* sp. (Giardi-a-glo, Waterborne Inc., New Orleans, Louisiana, USA), was placed on one of the sample sites of the slide. An additional 0.02 ml of FITC-labelled monoclonal antibody to oocysts of *Cryptosporidium* sp. (Crypt-o-glo, Waterborne Inc., New Orleans, Louisiana, USA), was placed on the other sample site. These antibodies have been shown to be highly specific for *Giardia* sp. cysts and *Cryptosporidium* sp. oocysts (Stibbs, 1989). The slide was then incubated in a humidity chamber at 37 C for 30 min. After incubation, excess antibody was washed off with PBS, and the slide was left to air dry. Slides were mounted with glycerol and a cover slip, examined using an epifluorescence microscope (Leica DMRB, Willowdale, Ontario, Canada). The intestinal samples from the beluga whales were imbedded in paraffin, sectioned and examined under a light microscope for intestinal parasites.

*Giardia* sp. cysts and *Cryptosporidium* sp. oocysts were not found in the whale tissues or intestinal contents. *Giardia* sp. cysts were identified in three of 15 fecal samples from seals, representing a prevalence of 20% of animals examined. *Giardia* sp. cysts were readily stained with the specific FITC monoclonal antibody (Fig. 1) and had characteristic dimensions ( $8.1 \pm 0.5 \mu\text{m}$  wide and  $11.8 \pm 0.5 \mu\text{m}$  long), as measured using a calibrated ocular micrometer of the microscope. The cysts contained characteristic internal structures

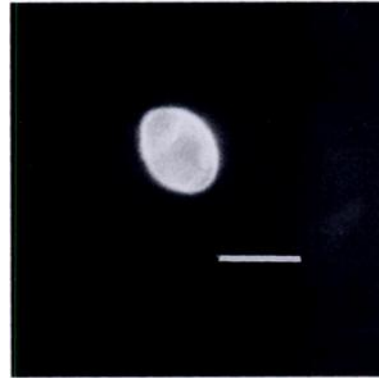


FIGURE 1. Fluorescein isothiocyanate-labelled monoclonal antibody staining a *Giardia* sp. cyst from the feces of a ringed seal. Bar = 10  $\mu\text{m}$ .

such as nuclei, axonemes of flagella and ventral disc fragments. All positive animals were from Holman, Northwest Territories. *Cryptosporidium* sp. was not identified in any samples we examined.

To our knowledge, this study is the first report of giardiasis in marine mammals. Future studies on the source of the parasite, the effect of this infection on marine mammals and the zoonotic potential of seal giardiasis are required.

#### LITERATURE CITED

- DEAN, L., B. ERICKSON, A. RONEMUS, D. SPALINGER, AND A. SULLIVAN. 1990. Public health advice, *Giardia* and the Kodiak Water System. State of Alaska Epidemiology Bulletin, No. 4, Department of Health and Social Services Publication, Anchorage, Alaska, 1 p.
- EATON, R. D. P., AND F. WHITE. 1976. Endemic Giardiasis—Northern Canada. Disease Weekly Report 2: 125–126.
- GERACL, J. R., AND D. J. ST. AUBIN. 1987. Effects of parasites on marine mammals. International Journal of Parasitology 17: 407–414.
- JOHNSTON, D. G., AND S. H. RIDGWAY. 1969. Parasitism in some marine mammals. Journal of the American Veterinary Medical Association 155: 1064–1072.
- JOHNSTON, D. C., K. A. REYNOLD, C. P. GERBA, I. L. PEPPER, AND J. P. ROSE. 1995. Detection of *Giardia* and *Cryptosporidium* in marine waters. Water Science and Technology 5–6: 439–442.
- MARGOLIS, L., AND M. D. DAILEY. 1972. Revised Annotated List of Parasites from Sea Mammals Caught Off the West Coast of North America. NOAA Technical Report NMFS SSRF-647, US

- Department of Commerce Publication, Seattle, Washington, 23 pp.
- ONDERKA, D. K. 1989. Prevalence and pathology of nematode infections in the lungs of ringed seals (*Phoca hispida*) of the Western Arctic of Canada. *Journal of Wildlife Diseases* 25: 218–224.
- PUGH, J. 1985. Follow-up investigation allays fears of second Ketchikan water system outbreak. *State of Alaska Epidemiology Bulletin*. No. 5, Department of Health and Social Services Publication, Anchorage, Alaska, 1 p.
- ROACH, P. D., M. E. OLSON, G. WHITLEY, AND P. M. WALLIS. 1993. Waterborne giardiasis and cryptosporidiosis in the Yukon, Canada. *Applied and Environmental Microbiology* 59: 67–73.
- STIBBS, H. H. 1989. Monoclonal antibody-based enzyme immunoassay for *Giardia lamblia* antigen in human stool. *Journal of Clinical Microbiology* 27: 2582–2588.
- WAZURA, K. W., J. T. STRONG, C. L. GLENN, AND A. O. BUSH. 1986. Helminths of the Beluga Whale (*Delphinapterus leucas*) from the Mackenzie River Delta, Northwest Territories. *Journal of Wildlife Diseases* 22: 440–442.

*Received for publication 10 December 1996.*