

## **ULTRASTRUCTURE OF THE CYST WALL OF SARCOCYSTIS SP. IN ROE DEER**

Authors: Santini, S., Mancianti, F., Nigro, M., and Poli, A.

Source: Journal of Wildlife Diseases, 33(4) : 853-859

Published By: Wildlife Disease Association

URL: <https://doi.org/10.7589/0090-3558-33.4.853>

---

BioOne Complete ([complete.BioOne.org](https://complete.BioOne.org)) is a full-text database of 200 subscribed and open-access titles in the biological, ecological, and environmental sciences published by nonprofit societies, associations, museums, institutions, and presses.

Your use of this PDF, the BioOne Complete website, and all posted and associated content indicates your acceptance of BioOne's Terms of Use, available at [www.bioone.org/terms-of-use](https://www.bioone.org/terms-of-use).

Usage of BioOne Complete content is strictly limited to personal, educational, and non - commercial use. Commercial inquiries or rights and permissions requests should be directed to the individual publisher as copyright holder.

---

BioOne sees sustainable scholarly publishing as an inherently collaborative enterprise connecting authors, nonprofit publishers, academic institutions, research libraries, and research funders in the common goal of maximizing access to critical research.

## ULTRASTRUCTURE OF THE CYST WALL OF *SARCOCYSTIS* SP. IN ROE DEER

S. Santini,<sup>1</sup> F. Mancianti,<sup>1</sup> M. Nigro,<sup>2</sup> and A. Poli<sup>1</sup>

<sup>1</sup> Department of Animal Pathology, Veterinary Medicine School, University of Pisa, I-56124 Pisa, Italy

<sup>2</sup> Department of Biomedicine, University of Pisa, I-56100 Pisa, Italy

**ABSTRACT:** Samples of heart, tongue, oesophagus and diaphragm muscle from twenty-two naturally infected roe deer (*Capreolus capreolus*) harvested in central Italy were examined for sarcosporidiosis. The structure of *Sarcocystis* spp. muscle cysts was examined by light and electron microscopy. Only one type of thin-walled cyst was distinguished by light microscopy. Electron microscopy showed cysts having a thin highly folded primary cyst wall, without fibrillar material, that formed thin hair-like protrusions often having a T-form, especially close to host cell mitochondria. The cysts appeared to belong to a single *Sarcocystis* sp. so that all the animals had monospecific infections. This cyst was compared with cysts described in other cervid in an attempt to determine if single or multiple species of the genus *Sarcocystis* occur in the Cervidae. Apparently, a single *Sarcocystis* sp. with a low specificity for the intermediate host can infect the Cervidae.

**Key words:** *Capreolus capreolus*, roe deer, *Sarcocystis* sp., sarcosporidiosis, ultrastructure.

### INTRODUCTION

*Sarcocystis* spp. are apicomplexan protozoa having an obligate two host life-cycle. The sarcocyst stage is in striated muscle cells of wild and domestic herbivore intermediate hosts. The produced oocyst is in the intestine of definitive host carnivores which become infected by ingestion of meat containing sarcocysts; sporocysts are infective stages passed in the feces of carnivore. Mature sarcocysts contain bradyzoites and few merozoites. A number of *Sarcocystis* spp. are found in domestic and wild herbivores. In Europe, *Sarcocystis* spp. have been described in wild sheep, *Ovis montanus* (Nigro et al., 1991; Odening et al., 1995); red deer, *Cervus elaphus* (Hernandez-Rodriguez et al., 1981a, b; Entzeroth et al., 1983); fallow deer, *Cervus dama* (Entzeroth et al., 1985; Poli et al., 1988); roe deer, *Capreolus capreolus* (Erber et al., 1978; Entzeroth, 1982); and reindeer, *Rangifer tarandus tarandus* (Gjerde, 1985a, b, c, d, e, f, 1986).

In the roe deer, light microscopic studies demonstrated the presence of three different types of muscle cysts (types I to III) in the muscle tissue (Erber et al., 1978). Additionally, a fourth type of sarcocyst also has been described (Entzeroth, 1982). The purpose of the present study is

to accurately describe the ultrastructure of the cyst wall of a *Sarcocystis* sp. from roe deer in Italy. We compare these cysts with those described in fallow and red deer from the same geographic areas in order to determine whether or not the same or multiple species infect different species of Cervidae in southern Europe.

### MATERIALS AND METHODS

From August to September 1994, 22 adult roe deer from Mugello hunting district, in the central part of Italy (Florence, Italy; 43°48'N, 10°20'E) were examined for sarcosporidiosis. Samples of muscle tissue from tongue, heart and diaphragm musculature of each roe deer were examined for *Sarcocystis* sp. bradyzoites by pepsin digestion technique (Entzeroth et al., 1985) modified as described: 5 g of muscle samples were broken into small pieces and digested for 60 min at 37 °C in a solution containing 0.2% of pepsin (Sigma, St. Louis, Missouri, USA) and 1% HCl. After filtration, the digest was centrifuged and examined for bradyzoites by phase contrast microscopy. For light microscopy, 1 cm<sup>3</sup> samples of tongue, oesophagus, diaphragm muscle and heart were fixed in 10% buffered formalin (pH 7.4) and embedded in paraffin. Five µm sections were stained with haematoxylin and eosin or periodic acid Schiff (PAS) stain (Luna, 1968). For electron microscopy, 1 mm<sup>3</sup> pieces of heart, diaphragm muscle and tongue were collected from each roe deer, fixed in 2.5% glutaraldehyde in 0.1 M cacodylate buffer solution for 2 hr, rinsed overnight in 0.1M cacodylate buffer and post-

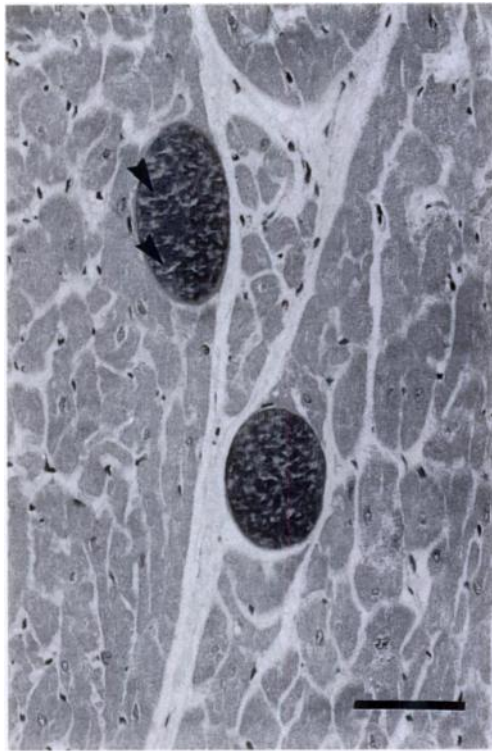


FIGURE 1. Light micrograph of sarcocysts from the muscle of roe deer. The cysts are located within the muscle cells and divided by this septa (arrows) into compartments. H&E stain. Bar = 10  $\mu\text{m}$ .

fixed in 1% (w/v)  $\text{OsO}_4$  in the same buffer for 2 hr at 4 C, partially dehydrated in ethanol, and prestained in 1% (w/v) uranyl acetate and 1% (w/v) phosphotungstic acid in 70% (v/v) ethanol at 4 C for 12 hr. Tissues were further dehydrated in a graded series of ethanol and three changes in propylene oxide, and embedded in epon-araldite mixture. Thick (1  $\mu\text{m}$ ) and ultrathin sections were cut using a Ultracut E (Reichert-Jung, Wien, Austria) microtome. Thick sections were stained with toluidine blue. Ultrathin sections were stained with uranyl acetate and lead citrate and examined in a Philips EM400 (Philips, Eindhoven, Holland) transmission electron microscope operating at 80 Kev.

Representative specimens (histological slides and formalin fixed tissues) of *Sarcocystis* sp. from this study are deposited in the U.S. National Parasite Collection (U.S. Department of Agriculture, Beltsville, Maryland, USA; Accession Number 87018).

## RESULTS

Using pepsin digestion, sarcosporidiasis was diagnosed in all 22 roe deer examined.

Mean size ( $\pm$ Standard deviation) of banana-shaped bradyzoites was  $15 \pm 2.4 \mu\text{m}$  long and  $3.4 \pm 0.4 \mu\text{m}$  wide (range =  $13.3\text{--}20.8 \mu\text{m}$  long,  $3.1\text{--}4.9 \mu\text{m}$  wide;  $n = 25$ ). Metrocytes measured  $11.1 \pm 0.3 \mu\text{m}$  long and  $3.3 \pm 0 \mu\text{m}$  wide (range  $11\text{--}11.4 \mu\text{m}$  long,  $3.3 \mu\text{m}$  wide  $n = 15$ ).

All the sarcocysts examined were microscopic, located within the sarcoplasm of the host cells and differentiated to the stage which contained mostly bradyzoites and few metrocytes. By light microscopy they appeared elongated and thin-walled (Fig. 1). The cyst walls were characterized by the absence of fibrillary structures in the cyst ground substance. Therefore, they appeared smooth by light microscopy. The cysts measured  $158.8 \pm 44.6 \mu\text{m}$  long and  $60 \pm 14.8 \mu\text{m}$  wide ( $87\text{--}304 \mu\text{m}$  long,  $30\text{--}102 \mu\text{m}$  wide;  $n = 50$ ). All the cysts examined ultrastructurally were intracellular. Immediately adjacent to the cyst, there was a thin layer of host cell material consisting of sarcoplasm with mitochondria and partially degenerated and disoriented myofibrils. The sarcocysts showed a structurally unique primary cyst wall (PCW). Sarcocysts collected from heart, diaphragm muscle and tongue appeared ultrastructurally similar. The PCW was 20 to 35 nm thick, consisted of a unit membrane and had a parasitophorous vacuolar membrane (PVM) and an osmiophilic dense layer on the inside. There was no secondary cyst wall. The PCW was highly folded forming hair-like protrusions over the entire surface of the cyst (Fig. 2). In longitudinal sections, these protrusions appeared as elongated digitations at variable lengths of  $2.5 \pm 0.09 \mu\text{m}$  ( $2.2\text{--}2.9 \mu\text{m}$  long;  $n = 25$ ), although the determination of the total length of the protrusions was difficult due to their tangential orientation and folding. These protrusions were wider at the base, arising as evaginations of the PVM and having a length ranging from 16 to 26 nm and a width from 180 to 290 nm. Distally they became narrowed, measuring  $30.0 \pm 0.05 \mu\text{m}$  long ( $25\text{--}45 \text{ nm}$ ;  $n = 25$ ) in width and consisted of parallel mem-

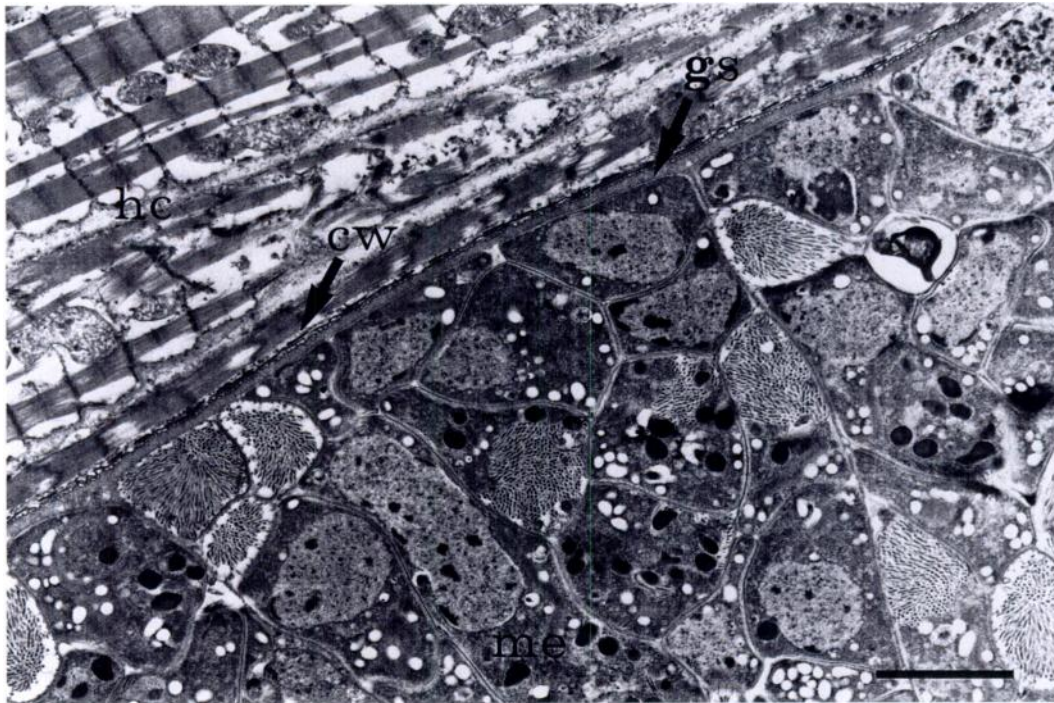


FIGURE 2. Electron micrograph of roe deer heart muscle showing a marginal part of a cyst of *Sarcocystis* sp. The cyst is situated in the host cell sarcoplasm (hc) and is limited by a folded cyst wall (cw). Clusters of merozoites (me), each containing a nucleus and dense granules are surrounded by ground substance (gs) forming septa. Bar = 3  $\mu$ m.

branes without a central core (Fig. 3). Many of the projections were T-shaped and were in close contact with host cell mitochondria and myofibrillae. The thickness of the terminal ends was the same as

hair-like protrusions from which they emerged. Tangential sections of the PCW demonstrated that these hair-like projections had a laminar arrangement running in parallel with the cyst surface and folding

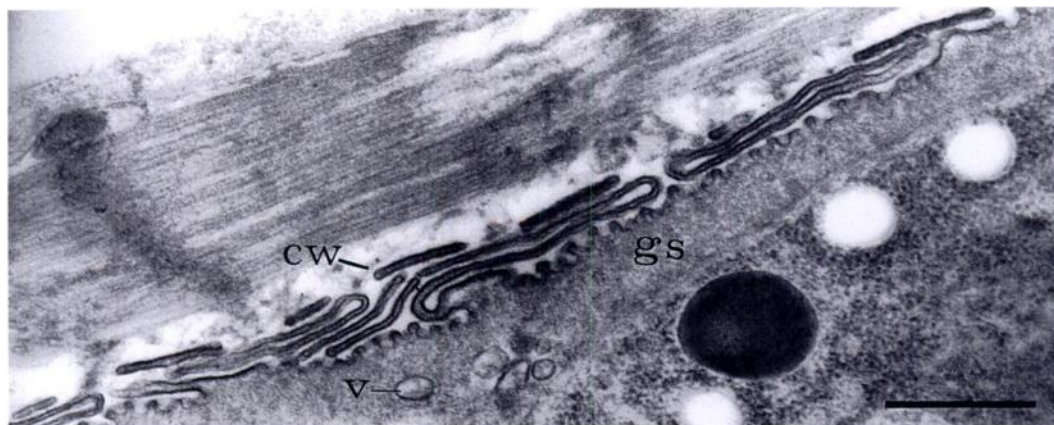


FIGURE 3. Electron micrograph showing higher magnification of a portion of cyst wall of *Sarcocystis* sp. from roe deer. Note the highly folded cyst wall (cw) which forms numerous projections branched at the tip adjacent to host cell myofibrils and the ground substance (gs) containing vesicles (v). Bar = 0.5  $\mu$ m.



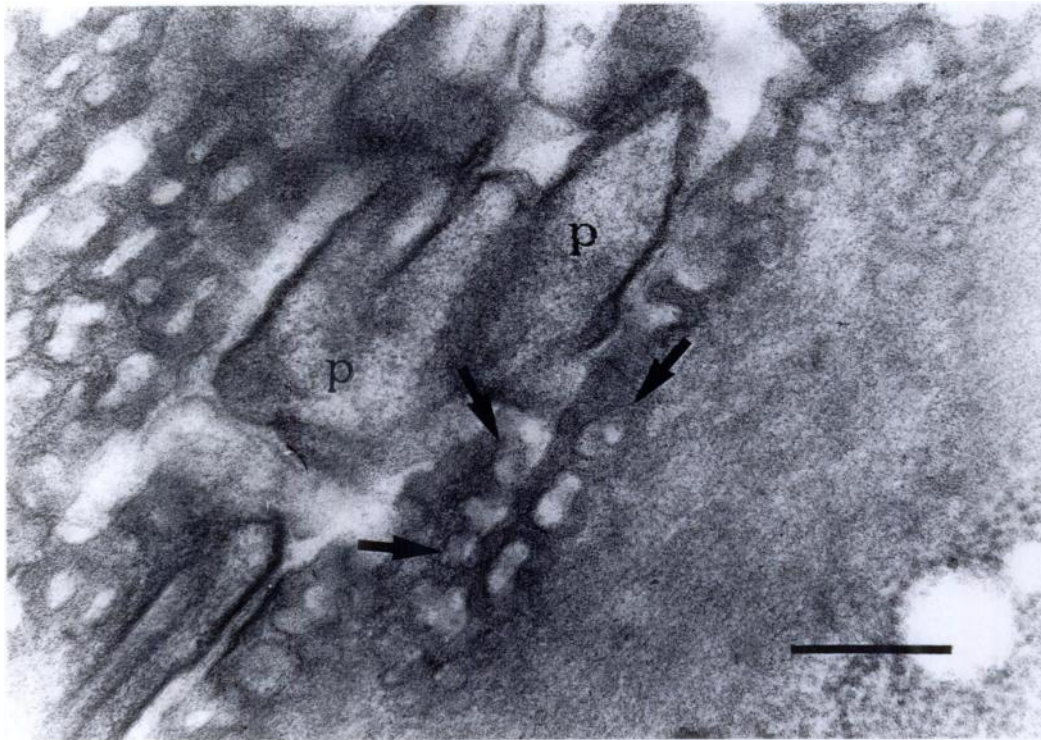


FIGURE 4. Transmission electron micrograph of peripheral portion of a transversally sectioned sarcocyst from roe deer: note the flattened sac appearance of the primary cyst wall projections and the presence of pit-like invaginations (arrows) in to the cyst surface between the protrusions which appear as lucid spots (notitle) projections (P). Bar = 50 nm.

upon or overlapping each other to form 3 to 4 layers (Fig. 3). Examination of transversal ultrathin sections of peripheral portions of sarcocyst demonstrated that these elongated protrusions were not simply hair-like projections, but more like a series of flattened digitations (Fig. 4). The zone of the PCW projections, corresponding to the "thin wall" observed by light microscopy, had a thickness ranging from 0.5 to 0.6  $\mu\text{m}$ . In the space between the projections, the cyst membrane formed numerous pit-like invaginations appearing in tangential sections as lucent spots (Fig. 4). These invaginations were 36 to 61 nm deep and 35 to 56 nm wide and were regularly distributed (Fig. 5). Immediately beneath the PCW there was a moderately electron-dense fibrogranular layer of ground substance which formed a band, 0.4 to 0.6  $\mu\text{m}$  thick, filling the core of the projections and extended into septa. This

divided the interior of the cyst into compartments containing numerous bradyzoites, few metrocytes, and spheroid masses of degenerated material. Bradyzoites shared all the morphological characteristics of the Sarcocystidae such as a three membrane pellicle, an apical complex, a dense cytoplasm with abundant free ribosomes, amylopectin, dense granules and mitochondria with tubular cristae. The nucleus was located posteriorly, contained a prominent nucleolus and a few clumps of condensed chromatin. Metrocytes were ovoid and had low electron density of their cytoplasm due to a moderate number of ribosomes.

#### DISCUSSION

These preliminary results indicate that the prevalence of sarcosporidiosis in roe deer in central Italy is very high (100%). The high prevalence of infection observed

in this area is not unusual in cervids (Mahrt and Colwell, 1980; Crum and Prestwood, 1982) and confirms previous observations on adult roe deer in Europe. Sedlacek and Wesemeir (1995) found *Sarcocystis* sp. in 29 of 35 roe deer from Germany and 30 of 31 roe deer from Poland. Entzeroth (1982) found sarcosporidiasis in only 74 of 103 roe deer in Germany, but 95% of >3-yr-old animals were infected. *Sarcocystis* spp. also occur in other cervids living in other areas of south or central Europe. Ninety-eight % of 45 fallow deer in Italy had *Sarcocystis* sp. (Poli et al., 1988) and in red deer with a prevalence ranging from 90 to 95% (Hernández Rodríguez et al., 1981a) to 30% (Entzeroth et al., 1983) depending on the methods used (digesting or histological method) to determine presence of the infection.

Our results suggested that all the animals were infected with a single *Sarcocystis* sp. All the cysts had a thin wall (<1  $\mu$ m) and shared a unique wall ultrastructure characterized by hair-like protrusion terminating with a T-shaped extension and numerous pit-like invaginations regularly distributed in the space between the projections. In the roe deer four *Sarcocystis* spp. have been described by light and electron microscopy (Erber et al., 1978; Entzeroth, 1982). Sedlacek and Wesemeir (1995) listed *Sarcocystis gracilis* (Rátz, 1909), *Sarcocystis capreolicanis* (Erber et al., 1978), *Sarcocystis hofmanni* (Odening et al., 1994) and *Sarcocystis* sp. (Schramlová and Blazek, 1978) as parasites of the roe deer.

The sarcocysts observed in our study coincide with that of *Sarcocystis* sp. described by Schramlová and Blazek (1978) which is synonymous with the "cyst wall type 4" of Entzeroth (1982) and *Sarcocystis* sp. of Dubey et al. (1989). The other three *Sarcocystis* sp. (*S. gracilis*, *S. capreolicanis*, *S. hofmanni*) were not seen in our samples, whereas they are observed frequently in roe deer from central Europe (Erber et al., 1978; Entzeroth, 1982; Sedlacek and Wesemeier, 1995).

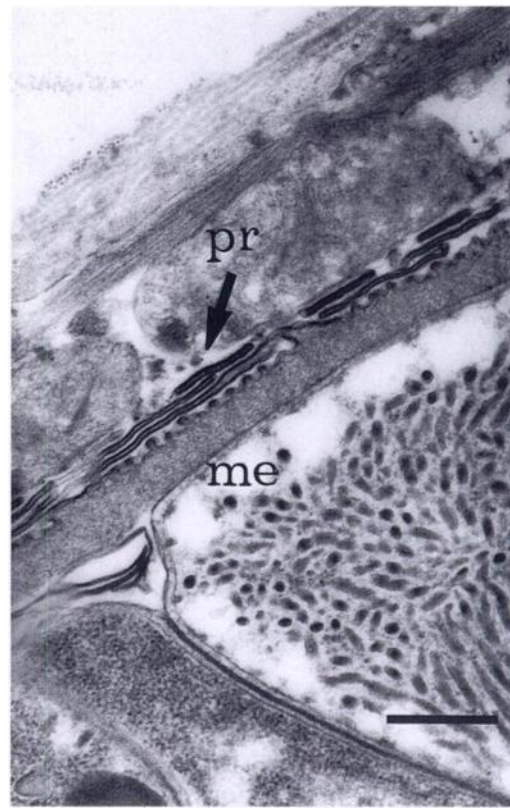


FIGURE 5. Details of the cyst wall of *Sarcocystis* sp. from roe deer showing the morphology of the primary cyst wall. Small invaginations of the cyst surface are visible in the space between the projections of the cyst wall (pr). Beneath the ground substance merozoites (me) are shown. Bar = 0.5  $\mu$ m.

The sarcocysts we observed are the same of those described in fallow deer by Entzeroth et al. (1985) and Poli et al. (1988), *S. grueneri* in reindeer (*Rangifer tarandus tarandus*) by Gjerde (1985a), *S. cervicanis* in red deer by Hernández-Rodríguez et al. (1981a, b), *S. grüneri* by Entzeroth et al. (1983), and *S. wapiti* in American elk (*Cervus elaphus*) by Speer and Dubey (1982). There is no agreement in the nomenclature of cervid *Sarcocystis* spp. Entzeroth et al. (1983) after reexamining *Sarcocystis* spp. from red deer concluded that *S. grüneri*, *S. cervicanis* and *S. wapiti* are synonymous and that *S. grüneri* has priority. We believe that we are dealing with a single species that has low specificity for the intermediate host, infecting roe

deer, fallow deer and red deer. This is supported by the fact that cross-transmission between intermediate hosts is possible (Fayer et al., 1982; Matuschka, 1983; Balbo et al., 1988). The alternative hypothesis is that the described *Sarcocystis* spp. could belong to sibling species, or almost morphologically identical species that do not interbreed.

#### ACKNOWLEDGMENTS

This research was financed by a grant from the Regione Toscana, Florence (Italy).

#### LITERATURE CITED

- BALBO, T., L. ROSSI, P. LANFRANCHI, P. G. MENE-  
GUZ, D. DEMENEGHI, AND M. G. CANESE. 1988. Experimental transmission of a sarcosporidian from alpine ibex to domestic sheep and goats. *Parassitologia* 30: 241–247.
- CRUM, J. M., AND A. K. PRESTWOOD. 1982. Prevalence and distribution of *Sarcocystis* spp. among white-tailed deer of the southeastern United States. *Journal of Wildlife Diseases* 18: 195–203.
- DUBEY, J. P., C. A. SPEER, AND R. FAYER. 1989. *Sarcocystis* of animals and man. CRC Press, Inc., Boca Raton, Florida, 224 pp.
- ENTZEROTH, R. 1982. A comparative light and electron microscope study of the cyst of *Sarcocystis* species of roe deer (*Capreolus capreolus*). *Zeitschrift für Parasitenkunde* 66: 281–292.
- , L. NEMESÉRI, AND E. SCHOLTYSECK. 1983. Prevalence and ultrastructure of *Sarcocystis* sp. from the red deer (*Cervus elaphus* L.) in Hungary. *Parasitologia Hungarica* 16: 47–52.
- , B. CHOBOTAR, E. SCHOLTYSECK, AND L. NEMESÉRI. 1985. Light and electron microscope study of *Sarcocystis* sp. from fallow deer (*Cervus dama*). *Zeitschrift für Parasitenkunde* 71: 33–39.
- ERBER, M., J. BOCH, AND D. BARTH. 1978. Drei Sarkosporidienarten des Rehwildes. *Berliner und Münchener Tierärztliche Wochenschrift* 91: 482–486.
- FAYER, R., J. P. DUBEY, AND R. G. LEEK. 1982. Infectivity of *Sarcocystis* spp. from bison, elk, moose and cattle for cattle via sporocysts from coyotes. *The Journal of Parasitology* 68: 681–685.
- GJERDE, B. 1985a. Ultrastructure of the cyst of *Sarcocystis grueneri* from cardiac muscle of reindeer (*Rangifer tarandus tarandus*). *Zeitschrift für Parasitenkunde* 71: 189–198.
- . 1985b. Ultrastructure of the cyst of *Sarcocystis rangi* from skeletal muscle of reindeer (*Rangifer tarandus tarandus*). *Rangifer* 2: 43–53.
- . 1985c. Ultrastructure of the cyst of *Sarcocystis tarandivulpes* from skeletal muscle of reindeer (*Rangifer tarandus tarandus*). *Acta Veterinaria Scandinavica* 26: 91–104.
- . 1985d. Ultrastructure of the cyst of *Sarcocystis rangiferi* from skeletal muscle of reindeer (*Rangifer tarandus tarandus*). *Canadian Journal of Zoology* 63: 2669–2675.
- . 1985e. Ultrastructure of the cyst of *Sarcocystis hardangeri* from skeletal muscle of reindeer (*Rangifer tarandus tarandus*). *Canadian Journal of Zoology* 63: 2676–2683.
- . 1985f. Ultrastructure of the cyst of *Sarcocystis tarandi* from skeletal muscle of reindeer (*Rangifer tarandus tarandus*). *Canadian Journal of Zoology* 63: 2913–2918.
- . 1986. Scanning electron microscopy of the sarcocystis of six species of *Sarcocystis* from reindeer (*Rangifer tarandus tarandus*). *Acta Pathologica et Microbiologica Scandinavica Sect. B* 94: 309–317.
- HERNANDEZ-RODRIGUEZ, S., I. NAVARRETE, AND F. MARTINEZ-GOMEZ. 1981a. *Sarcocystis cervicanis*, nueva especie parásita del ciervo (*Cervus elaphus*). *Revista Iberica de Parasitología* 41: 43–51.
- , F. MARTINEZ-GOMEZ, I. NAVARRETE, AND I. ACOSTA-GARCIA. 1981b. Estudio al microscopio óptico y electrónico del quiste de *Sarcocystis cervicanis*. *Revista Iberica de Parasitología* 41: 351–361.
- LUNA, L. G. 1968. Manual of histologic staining techniques of the Armed Forces Institute of Pathology, 3rd ed., McGraw-Hill Book Company, New York, New York, 258 pp.
- MAHRT, J. L., AND D. D. COLWELL. 1980. *Sarcocystis* in wild ungulates in Alberta. *Journal of Wildlife Diseases* 16: 571–576.
- MATUSCHKA, F. R. 1983. Infectivity of *Sarcocystis* from donkey for horse via sporocysts from dogs. *Zeitschrift für Parasitenkunde* 69: 299–304.
- NIGRO, M., F. MANCIANTI, P. ROSSETTI, AND A. POLI. 1991. Ultrastructure of the cyst and life cycle of *Sarcocystis* sp. from wild sheep (*Ovis musimon*). *Journal of Wildlife Diseases* 27: 217–224.
- ODENING, K., M. STOLTE, G. WALTER, AND I. BOCKHARDT. 1994. The European badger (*Carnivora: Mustelidae*) as intermediate host of further three *Sarcocystis* species (Sporozoa). *Parasite* 1: 23–30.
- , ———, ———, AND ———. 1995. Cyst wall ultrastructure of two *Sarcocystis* spp. from european mouflon (*Ovis ammon musimon*) in Germany compared with domestic sheep. *Journal of Wildlife Diseases* 31: 550–554.
- POLI, A., F. MANCIANTI, A. MARCONCINI, M. NIGRO, AND R. COLAGRECO. 1988. Prevalence, ultrastructure of the cyst wall and infectivity for the dog and cat of *Sarcocystis* sp. from fallow deer (*Cervus dama*). *Journal of Wildlife Diseases* 24: 97–104.
- RÄTZ, S. 1909. Die sarcosporidien und ihre in Ungarn vorkommenden Arten. *Allatani Kozlemen-*

- yek 8: 1–37 (Hungarian), Tab. I–III, 91–95 (German).
- SCHRAMLOVÁ, J., AND K. BLAZEK. 1978. Ultrastruktur der Zystenwand der Sarkosporidien des Rehes (*Capreolus capreolus* L.). *Zeitschrift für Parasitenkunde* 55: 43–48.
- SEDLACZEK, J., AND H.-H. WESEMEIER. 1995. On the diagnostics and nomenclature of *Sarcocystis* species (Sporozoa) in roe deer (*Capreolus capreolus*). *Applied Parasitology* 36: 73–82.
- SPEER, C. A., AND J. P. DUBEY. 1982. *Sarcocystis wapiti* sp. nov. from the North American wapiti (*Cervus elaphus*). *Canadian Journal of Zoology* 60: 881–888.

*Received for publication 1 October 1996.*