

SARCOSPORIDIASIS IN RODENTS FROM THAILAND

Authors: Jäkel, Thomas, Khoprasert, Yuvaluk, Sorger, Ingeborg, Kliemt, Damaris, Seehabutr, Viyada, et al.

Source: Journal of Wildlife Diseases, 33(4) : 860-867

Published By: Wildlife Disease Association

URL: <https://doi.org/10.7589/0090-3558-33.4.860>

BioOne Complete (complete.BioOne.org) is a full-text database of 200 subscribed and open-access titles in the biological, ecological, and environmental sciences published by nonprofit societies, associations, museums, institutions, and presses.

Your use of this PDF, the BioOne Complete website, and all posted and associated content indicates your acceptance of BioOne's Terms of Use, available at www.bioone.org/terms-of-use.

Usage of BioOne Complete content is strictly limited to personal, educational, and non - commercial use. Commercial inquiries or rights and permissions requests should be directed to the individual publisher as copyright holder.

BioOne sees sustainable scholarly publishing as an inherently collaborative enterprise connecting authors, nonprofit publishers, academic institutions, research libraries, and research funders in the common goal of maximizing access to critical research.

SARCOSPORIDIASIS IN RODENTS FROM THAILAND

Thomas Jäkel,^{1,2} Yuvaluk Khoprasert,³ Ingeborg Sorger,⁴ Damaris Kliebt,¹
Viyada Seehabutr,³ Kornkaew Suasa-ard,³ and Sermakdi Hongnark³

¹ Division of Parasitology, Department of Zoology, University of Hohenheim, Emil Wolff Strasse 34,
70599 Stuttgart, Germany

² German Technical Cooperation (GTZ), 65726 Eschborn, Germany

³ Agricultural Zoology Research Group, Entomology and Zoology Division, Department of Agriculture,
10900 Bangkok, Thailand

⁴ Department of Zoology, University of Hohenheim, Garbenstrasse 30, 70593 Stuttgart, Germany

ABSTRACT: One to six *Sarcocystis* spp. were identified in the skeletal muscles of 41 (33%) of 124 wild rodents (*Rattus* spp. and *Bandicota indica*) mainly captured in the central plains of Thailand throughout the year in 1995. Included were *S. singaporensis*, *S. villivillosi*, and *S. murinotechis*-like cysts all of which showed a striated cyst wall at the light microscopical level, and *Sarcocystis cymruensis*, *S. sulawesiensis*, and *S. zamani* which possessed smooth cyst walls. The ultrastructure of the cyst wall and other morphological characteristics used to distinguish species are described. By inoculation of muscle cysts from wild-caught rodents into coccidia-free pythons (*Python reticulatus*, *P. molurus bivittatus*), we confirmed that *P. reticulatus* is a suitable definitive host for *S. singaporensis* and *S. zamani* in Thailand. Furthermore, we showed by fecal examination of reticulated pythons collected in the wild and subsequent experimental infection of laboratory rats that these hosts also are naturally infected with both species. *Sarcocystis cymruensis* is reported for the first time from Southeast Asia. This parasite was prevalent in brown rats (*Rattus norvegicus*) and bandicoot rats (*B. indica*) which were captured near human habitations; it is likely to be transmitted to rats via cats. The definitive hosts of *S. sulawesiensis* and *S. murinotechis* are unknown. Hence, at least three *Sarcocystis* spp. (*S. singaporensis*, *S. zamani*, *S. villivillosi*) are likely to cycle between snakes and rodents in agricultural areas in Thailand. Among these, *S. singaporensis* appears to be the most prevalent species.

Key words: *Bandicota indica*, experimental transmission, prevalence, *Rattus* spp., rodents, *Sarcocystis* spp., sarcocyst ultrastructure.

INTRODUCTION

According to previous reports, cysts of *Sarcocystis* spp. are frequently found in skeletal muscles of rodents from Southeast Asia. The early studies solely concentrated on the light microscopical and ultrastructural descriptions of sarcocysts without designation of species (Holz and Sioe, 1965; Carlos and Schaeffer, 1972; Brown et al., 1974; Kan and Dissanaïke, 1977; Kan, 1979). Infection experiments with potential intermediate hosts performed by Beaver and Maleckar (1981) using sporocysts isolated from the reticulated python (*Python reticulatus*), a snake native to this geographical region, showed that three different *Sarcocystis* spp. develop in the snake and that these can be transmitted to laboratory rats (*Rattus norvegicus*). The cyst ultrastructure of two of these species, *Sarcocystis singaporensis* and *S. zamani*, is strikingly similar to that of naturally infected rodents from Malaysia and Indo-

nesia (Kan and Dissanaïke, 1977; Kan, 1979; O'Donoghue et al., 1987). Häfner and Frank (1984) demonstrated that a variety of *Rattus* spp. from Southeast Asia and Australia and *Bandicota* spp. could be experimentally infected with *S. singaporensis*. Although these observations suggest a wide distribution range of the parasites, transmission experiments to confirm definitive host specificity using sarcocysts (of a single species) obtained from wild rodents have not been performed.

Because we are particularly interested in *S. singaporensis* as a potential biocontrol agent of wild rats (Jäkel et al. 1996) we wanted to determine the prevalence of this species within its natural distribution range and what other *Sarcocystis* spp. occur sympatrically. We selected Thailand as a study site because preliminary data from our laboratory (Häfner, 1987) indicated that *S. singaporensis* occurs in rodents from this country. In order to identify a

Sarcocystis sp. we examined the muscles of wild rodents and where possible, we performed experimental transmission from the intermediate to potential definitive hosts and vice versa to confirm species identity.

MATERIALS AND METHODS

One hundred and twenty four rodents (*Rattus* spp. and *Bandicota indica*, Table 1) were captured in 1995 by live-trapping in Nakhon Pathom (Banglen, 14°00'N, 100°08'E), Pathum Thani (Thunyaburi, 14°03'N, 99°16'E), Suphan Buri (Bangprama, 14°24'N, 100°06'E), Bangkok Metropolis (Chatuchak, 13°49'N, 100°35'E), Chachoengsao (Bang Nam Prieo, 13°51'N, 101°04'E), and Prachin Buri province (Muang, 14°04'N, 101°22'E) in the central plain region of Thailand, except one *Rattus tiomanicus* which was collected in Satul province (Kuanqalung, 7°9'N, 99°57'E) in southern Thailand. The majority of rodents was captured in paddy fields or around small villages in rural areas. Brown rats (*Rattus norvegicus*) were trapped at Kasetsart University (Bangkok, Thailand; 13°49'N, 100°35'E). After killing the animals with ether, fresh preparations of the oesophagus, diaphragm, and skeletal muscles from each carcass were immediately examined for sarcocysts using a light microscope. When possible, macroscopic and microscopic cysts were dissected from the surrounding tissue with a scalpel under a microscope at 100-fold magnification and fixed in 2.5% glutaraldehyde in 0.1 M phosphate-buffer (pH 7.4) at 4 C for 24 hr. After washing the samples in phosphate-buffer, they were processed for electron microscopy as described previously (Jäkel, 1995).

Identification of the parasites was based on previously published data on the ultrastructural morphology of *Sarcocystis* spp. in rodents (Ashford, 1978; Kan, 1979; Beaver and Maleckar, 1981; Häfner, 1987; O'Donoghue et al., 1987) and on attempts of experimental transmission from intermediate to potential definitive hosts and vice versa (see below).

Eight reticulated pythons collected from canals within the city limits of Bangkok (Thailand) were kept alive at the Department of Agriculture (Bangkok) in 100 × 80 × 120 cm wire cages at ambient temperatures and humidity. They were fed laboratory-reared mice (*Mus musculus*) obtained from the central breeding colony of the Mahidol University (Bangkok). Fecal examination was performed as described by Jäkel (1995).

In order to determine the definitive host specificity of various sarcocyst-isolates from the

TABLE 1. Prevalence of *Sarcocystis* spp. in rodents from Thailand.

Host species	Number examined ^a	Number infected ^b	<i>S. cynmuriei</i>	<i>S. murino-teschus</i> -like	<i>S. singaporensis</i>	<i>S. sulawesiensis</i>	<i>S. villivilliosi</i>	<i>S. zamani</i>	<i>S. spp.</i> ^c
<i>Bandicota indica</i>	58	17	11	7	9	1	—	4	—
<i>Rattus argenticeus</i>	12	3	—	2	1	—	—	1	—
<i>Rattus exulans</i>	2	0	—	—	—	—	—	—	—
<i>Rattus losea</i>	6	4	—	4	—	—	—	—	—
<i>Rattus norvegicus</i>	36	9	6	—	1	—	—	1	1
<i>Rattus rattus</i>	9	7	—	—	7	—	—	5	—
<i>Rattus tiomanicus</i>	1	1	—	—	—	—	1	—	—
Total rodents	124	41 (33%)	17 (41%)	13 (11%)	18 (15%)	1 (<1%)	1 (<1%)	11 (9%)	2 (2%)

^a Examination of oesophagus, diaphragm, and skeletal muscles for presence of cysts.

^b Mixed infections by various species detected in various rodents, most frequently *S. singaporensis* in association with *S. zamani*.

^c Sarcocysts not recognized as a particular species.

muscles of wild-caught rodents, laboratory-reared snakes free of coccidia were force-fed pieces of muscle from infected rodents. Before inoculation, it was confirmed by extensive microscopic examination that the muscles fed to the snakes only contained cysts of a single *Sarcocystis* sp.

Cysts of *S. singaporensis* were isolated from the abdominal wall of a bandicoot rat (*B. indica*) and a brown rat from Thailand. Each isolate was orally administered to a 2-yr-old reticulated python. Both pythons received muscle pieces containing hundreds of cysts. They were kept under conditions as described earlier (Jäkel et al., 1996). In a parallel experiment, the same sarcocyst isolates also were administered to two 5-yr-old burmese pythons (*Python molurus bivittatus*). Further one adult (5-yr-old) reticulated and burmese python each received sarcocysts which were isolated from a bandicoot rat and showed a *Sarcocystis murinotechis*-like morphology (Fig. 4). In a third infection experiment, hundreds of sarcocysts of *S. zamani* dissected from the subcutaneous tissue of a wild-caught brown rat were orally inoculated into a 3-yr-old reticulated python. Fecal samples of all snakes were collected at biweekly intervals for 4 mo and examined for oocysts and sporocysts as described previously (Jäkel, 1995).

Sporocysts obtained from natural and experimental infections of snakes described above, were orally administered to female laboratory rats (*R. norvegicus*, strain F-344, Charles River, Sulzfeld, Germany) using a stomach tube. In each experiment three rats were used. Each rat received 1,000 sporocysts. After 4 to 6 mo the animals were killed with CO₂; the musculature was examined for sarcocysts, and these were subsequently fixed and processed for electron microscopy as described previously (Jäkel, 1995). Additionally, three rats in each experiment served as negative controls; they received phosphate-buffered saline (PBS) instead of parasites.

Voucher specimens of sarcocysts (resin-embedded for electron microscopy) were deposited at the Museum Senckenberg, Senckenberganlage 25, 60325 Frankfurt/Main, Germany; accession numbers SMF Prot-EM 5.001 (*S. sulawesiensis*), SMF Prot-EM 5.002 (*S. murinotechis*), SMF Prot-EM 5.003 (*S. singaporensis*), SMF Prot-EM 5.004 (*S. cymruensis*), and SMF Prot-EM 5.005 (*S. zamani*).

RESULTS

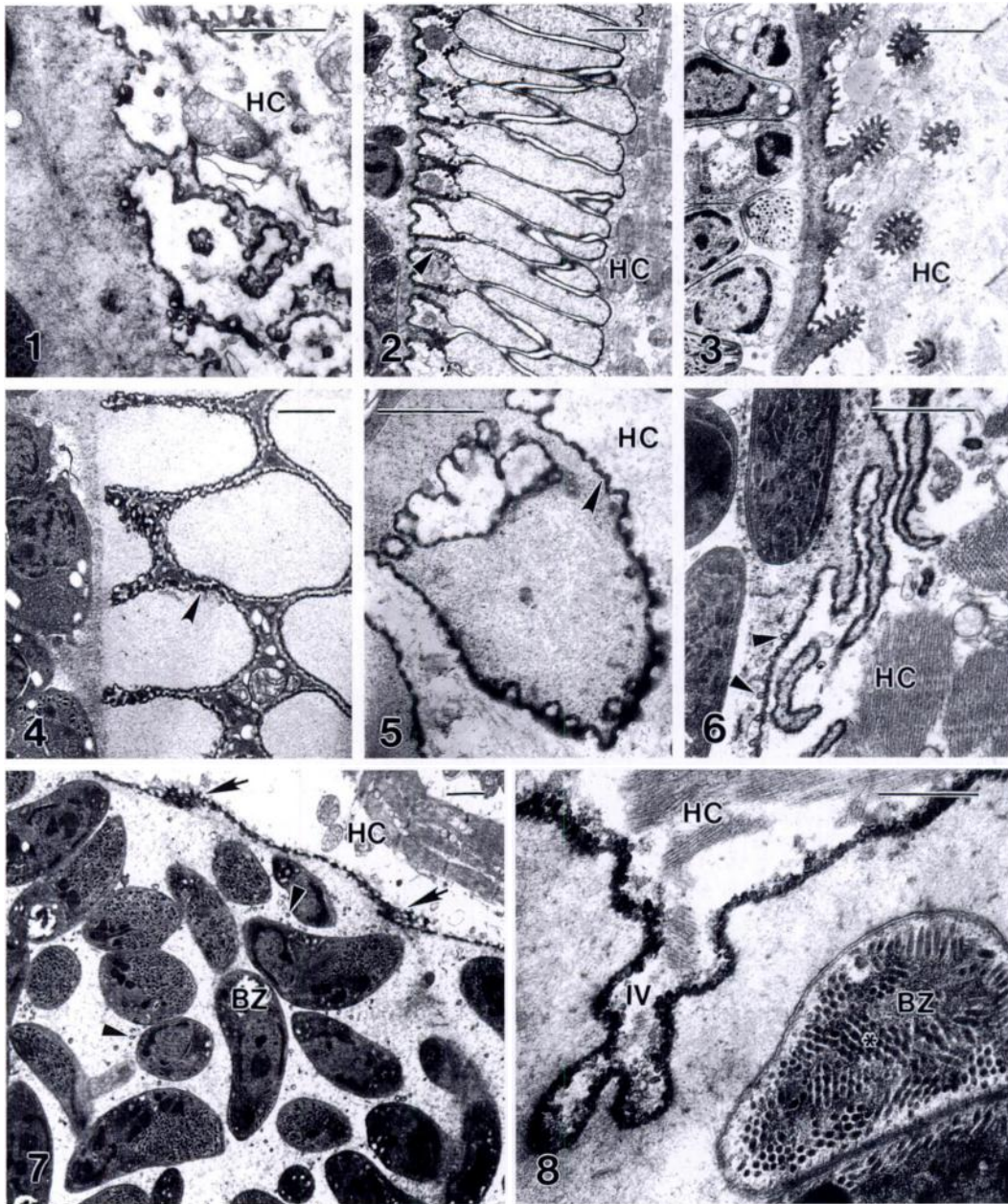
Six *Sarcocystis* spp. were identified in the skeletal muscles of the 124 rodents examined (Table 1). Sarcocysts with a thick

striated wall and large fingerlike protrusions that closely resembled *S. murinotechis* described by Munday and Mason (1980) were found in three rodent species (Table 1) captured in ricefields. As the recognized definitive host of *S. murinotechis*, an Australian elapid snake (*Notechis ater*), does not occur in Thailand, we will refer to our parasite isolates in the following text as *S. murinotechis*-like. At the light microscopic level, few sarcocysts showed a cyst wall morphology which was distinct to that of the species described here; their ultrastructure was not examined (Table 1, *Sarcocystis* spp.).

Wild rats frequently were infected with *Sarcocystis* spp.; 33% of all rodents examined contained cysts in their muscles (Table 1). The most prevalent species were *S. cymruensis*, *S. singaporensis*, *S. zamani*, and *S. murinotechis*-like cysts. The density of parasites in the muscles of rodents infected with *S. cymruensis* was low. Usually, not more than approximately 100 cysts were seen in one half of the abdominal wall. Similarly, the majority of infections with *S. singaporensis*, *S. zamani*, and *S. murinotechis* were associated with low cyst numbers; however, some rats were infected with thousands of cysts in the muscles. In heavy infections with *S. zamani*, numerous cysts also were seen in subcutaneous tissues.

In particular geographic localities, prevalence of *S. singaporensis* reached 100%, as was the case with the seven roof rats which were all trapped at the same area (Table 1). Remarkably, almost all rats infected with *S. cymruensis* were captured in close vicinity to human habitations.

Although most of the sarcocysts reached a considerable size, only *S. cymruensis* and *S. zamani* were clearly macroscopic. The former species appeared as whitish filiform cysts which were 1.1–3.2 mm long and 0.10–0.18 mm wide ($n = 22$) in fresh preparations of muscles. The latter could be easily recognized by its large stumpy cysts which also occurred in large numbers in subcutaneous muscles; their size was



FIGURES 1–8. Cyst ultrastructure of *Sarcocystis* spp. in skeletal muscles of rodents from Thailand. Scale bar = 1 μ m. Abbreviations are for bradyzoite (BZ), host cell (HC), and invagination of cyst wall (IV). 1. Cyst wall of *S. zamani* isolated from *Bandicota indica*. 2. *Sarcocystis singaporensis* in the abdominal wall of *Rattus argentiventer*; arrowhead points at a stalk which forms the basis of a spatula-like protrusion of the cyst wall. 3. Cyst wall of *S. villivillosi* isolated from *R. tiomanicus*. 4. Large, fingerlike protrusions near the tip of a *S. murinotechis*-like cyst in *R. argentiventer*; arrowhead points at the electron-dense wall of a protrusion. 5. Medium part of the same cyst as in 4; note the broadly branched lower portion of the protrusion. 6. Hair-like protrusions of the cyst wall of *S. sulawesiensis* in *B. indica*; arrowheads point at vesicle-like structures which seem to bud from the electron-dense primary wall of the cyst. 7. Same cyst as Fig. 6 showing the hair-like protrusions that occasionally were reduced to small elevations of the cyst wall (arrows); arrowheads point at the vesicle-like structures which also are found throughout the cyst matrix. 8. Cyst wall of *S. cynmurienis* isolated from *R. norvegicus* demonstrating a cross-section of the apical portion of a bradyzoite with numerous micronemes visible; note their cristalloid arrangement (star).

1.0–3.1 \times 0.21–0.43 mm ($n = 28$). *Sarcocystis murinotechis*-like cysts, *S. singaporensis*, and *S. villivillosi* measured 1.1–3.4 \times 0.07–0.22 mm ($n = 22$), 0.7–2.3 \times 0.07–0.16 mm ($n = 36$), and 1.1–1.7 \times 0.06–0.08 mm ($n = 2$), respectively. Mature cysts of *S. sulawesiensis* were the smallest measuring 260–500 \times 20–40 μ m ($n = 4$).

At the light microscopic level, sarcocysts could be further characterized as those with a radially striated or a smooth cyst wall. *Sarcocystis singaporensis*, *S. villivillosi*, and *S. murinotechis*-like cysts possessed striated walls with a diameter of 3–5 μ m, 1–2 μ m, and 3–17 μ m, respectively. The spatula- or sausage-like protrusions resting on short narrow stalks of the cyst wall seen in electron micrographs (Fig. 2), also were visible in fresh preparations of mature cysts of *S. singaporensis* with a light microscope at high magnification. Here, stalks and protrusions formed two distinct longitudinal layers. This was a marked difference to both of the other species where a bilayered cyst wall was not present (Fig. 3, 4).

Sarcocystis murinotechis-like sarcocysts appeared slender and sausage-shaped in fresh preparations and had a thick striated cyst wall. This type of cysts was found in *R. argentiventer*, *R. losea*, and *B. indica* (Table 1). They appeared quite similar to *S. singaporensis*, but unlike this species they often possessed sharply pointed ends. The cyst wall consisted of large fingerlike protrusions with a broad basis originating in the ground substance (Fig. 4). Occasionally, protrusions of a single sarcocyst appeared to be relatively polymorphic. Some cysts showed fingerlike protrusions at the tip, but had broadly-branched rectangular projections in the medium part (Fig. 5). In small cysts protrusions were shorter than in large ones; accordingly, the diameter of the cyst wall was highly variable. The ground substance contained numerous electron-dense vesicles; they were more numerous in smaller cysts.

The diameter of the cyst wall of the

smooth-walled species was $<1 \mu$ m, except for *S. zamani* where the wall was up to 3 μ m wide. At the ultrastructural level, these cysts were quite distinct. Small, knob-like elevations of the primary wall were seen in cysts of *S. cymruensis* (Fig. 8). The wall formed invaginations toward the interior of the cyst which occasionally became very deep. Bradyzoites of this species were densely packed in relatively small chambers of septated cysts and possessed long and slender micronemes which were often arranged in a cristalloid fashion (Fig. 8). Cysts of *S. zamani* had walls with highly-branched, dendritic projections (Fig. 1), whereas *S. sulawesiensis* possessed hair-like protrusions (Fig. 6) which occasionally were reduced to small elevations (Fig. 7). Bradyzoites of the latter species were loosely packed in large chambers of the cyst (Fig. 7) separated by highly visible septa. Vesicle-like structures appeared to bud from the thickened unit membrane of the primary cyst wall (Fig. 6); they also occurred in the cyst matrix (Fig. 7).

Bradyzoites of *S. cymruensis* released from freshly disrupted sarcocysts were the largest measuring 12.7 ± 0.5 (S.D.) \times $3.2 \pm 0.3 \mu$ m ($n = 12$). These stages were $<10 \mu$ m long in all other *Sarcocystis* spp.

Sarcocysts of *S. singaporensis* obtained from a bandicoot rat and a brown rat each were inoculated orally into reticulated pythons. Oocysts and sporocysts were first seen in the feces of both snakes at days 12 and 14 post infection (PI), respectively, and the snakes excreted large numbers of sporocysts during the first 3 mo PI. Sporocysts measured $10.0 \pm 0.5 \times 7.5 \pm 0.3 \mu$ m ($n = 20$). When the two sporocyst-isolates were inoculated into laboratory rats, all rats became infected. Four mo PI, the rats contained characteristic cysts of *S. singaporensis* in the skeletal muscles. The cyst ultrastructure was the same regardless of whether bandicoot or brown rats had served as the source of parasite material. Control rats were not infected. Sporocysts could not be detected in feces of the two

inoculated burmese pythons during an observation period of 4 mo.

A coccidia-free reticulated python which was administered cysts of *S. zamani* from a wild-caught brown rat, shed oocysts and sporocysts at day 20 PI. These sporocysts appeared spheroidal and measured $8.9 \pm 0.6 \times 6.2 \pm 0.6 \mu\text{m}$ ($n = 16$). They contained four sporozoites; the residual body consisted of a few small granules only or was not visible at all. After inoculation of laboratory rats with these sporocysts, mature sarcocysts of *S. zamani* were seen in the muscles at 4 mo PI. The cyst wall showed the same ultrastructure as in naturally infected rodents (Fig. 1). The control rats were not infected.

Attempts to infect a reticulated and a burmese python using *S. murinotechis*-like sarcocysts were negative. Examination of fecal samples of eight reticulated pythons collected from the wild revealed that seven were naturally infected with *Sarcocystis* spp. All positive fecal samples contained sporocysts which were similar in size to sporocysts of *S. singaporensis*. Two samples additionally contained sporocysts similar in size to those of *S. zamani*. Experimental infections of laboratory rats with sporocysts confirmed that two snakes were infected with both parasite species. Four mo after infection, all rats in the seven groups had sarcocysts of *S. singaporensis* in the muscles, two groups were superinfected with *S. zamani*. Control rats showed no infection.

DISCUSSION

Infections with *Sarcocystis* spp. were frequently observed in the musculature of rodents from Thailand. Compared to previous data from Indonesia where 40% of all rodents contained cysts (of two species) in the muscles (O'Donoghue et al., 1987), our data are quite similar with regard to prevalence (Table 1). However, parasite species diversity is apparently higher in Thailand where six *Sarcocystis* spp. were identified; there are probably additional species (Table 1). Kan (1979) found three

Sarcocystis spp. in five rodent species from Malaysia.

The data of O'Donoghue et al. (1987) and our study indicate, that *S. singaporensis* is highly prevalent in rodents from southeastern Asia and that the parasite probably is widely distributed. However, definitive host specificity has not been confirmed previously (Kan, 1979; O'Donoghue et al., 1987), or results were equivocal because the inoculated material contained more than one *Sarcocystis* spp. (Häfner and Frank, 1984). Here, we demonstrate by successful experimental infections of coccidia-free reticulated pythons with sarcocysts from wild-caught rodents, that the species in Thailand is *S. singaporensis*. The size of the resulting sporocysts corresponds well to earlier descriptions (Zaman and Colley, 1975; Häfner, 1987) and subsequent infection of laboratory rats resulted in development of ultrastructurally characteristic muscle cysts. Furthermore, we show that reticulated pythons often are infected naturally with *S. singaporensis*.

Other species seen in rodents from southeast Asia included *S. zamani* and *S. murinotechis*-like cysts (Kan, 1979; Häfner, 1987). Similar to our experiments with *S. singaporensis*, we confirmed the reticulated pythons as an experimental as well as natural definitive host of *S. zamani*. The ubiquity of the reticulated python throughout southeast Asia (Cox, 1991) might well explain the wide distribution range of both parasite species. However, ultrastructural data suggest that they also are found in Australia (Rzepczyk and Scholtyseck, 1976), a geographical region where reticulated pythons do not occur. *Sarcocystis murinotechis* was described to cycle between tiger snakes and various rats from Australia (Munday and Mason, 1980) and ultrastructurally similar cysts occurred in *Rattus lutreolus* from Tasmania (Mehlhorn et al., 1976; Munday et al., 1978). The status of this species in Asia still has to be clarified by transmission experiments using various Asian snakes; pythons were not suitable definitive hosts. Thus, at the

ultrastructural level, it seems that three *Sarcocystis* spp. may be in southeastern Asia and Australia.

Both *S. villivillosi* and *S. sulawesiensis* were found only once (Table 1). Considering the relatively low sample size of our survey, the former species is probably rarely found in the central plains, whereas it might occur more frequently in southern parts of Thailand. Due to scarcity of sarcocysts we were not able to perform transmission studies with *S. villivillosi*. However, it has been shown previously that the reticulated python is an experimental and natural definitive host of this species (Beaver and Maleckar, 1981; Häfner, 1987). Although the definitive host of *S. sulawesiensis* is unknown and intermediate hosts in Indonesia (O'Donoghue et al., 1987) were different from those in Thailand, we regard the parasites seen in *B. indica* identical with this species. The ultrastructure of the cyst wall was indistinguishable from the original description. Similarly, mature cysts (no metrocytes) were remarkably small and contained bradyzoites loosely packed in large chambers separated by highly visible septa on the light as well as electron microscope level.

Here, we report for the first time *S. cymruensis* from rats in southeast Asia. This indicates that the species has a cosmopolitan distribution. It was originally described from brown rats in England and successfully transmitted to domestic cats and vice versa (Ashford, 1978). We found this species also infected brown and roof rats (*Rattus rattus*) in Egypt (Jäkel et al., 1996). Ultrastructurally, cysts from Thailand were indistinguishable from those collected in Africa. It is likely that domestic and wild cats (Patton and Rabinowitz, 1994) are the definitive host. *Sarcocystis cymruensis* can be easily recognized by its large bradyzoites. Ultrastructurally, the type of cyst wall is not unique as it is shared among various *Sarcocystis* spp. (Dubey et al., 1989). However, the micronemes of bradyzoites are quite characteristic; they are long and slender and often

form crystalloid clusters (Fig. 8), a morphological feature also seen in *S. muris* (Sheffield et al., 1977).

ACKNOWLEDGMENTS

We thank H. Rahmann for the use of the electron microscope facility at the University of Hohenheim (Germany). Some laboratory-reared pythons were kindly provided by P. Youngprapakorn at the Samutprakarn Crocodile Farm and Zoo (Thailand).

LITERATURE CITED

- ASHFORD, R. W. 1978. *Sarcocystis cymruensis* n. sp., a parasite of rats *Rattus norvegicus* and cats *Felis catus*. *Parasitology* 72: 37–43.
- BEAVER, P. C., AND J. R. MALECKAR. 1981. *Sarcocystis singaporensis* Zaman and Colley, (1975) 1976, *Sarcocystis villivillosi* sp. n., and *Sarcocystis zamani* sp. n.: Development, morphology and persistence in the laboratory rat, *Rattus norvegicus*. *The Journal of Parasitology* 67: 241–256.
- BROWN, R. J., P. CARNEY, AND P. F. D. VAN PEENEN. 1974. *Sarcocystis* from rats in Sulawesi, Indonesia. *Southeast Asian Journal of Tropical Medicine and Public Health* 5: 451–452.
- CARLOS, E. R., AND B. T. SCHAEFFER. 1972. *Sarcocystis* in the Philippines: A histologic review of 202 cases in rats. *Southeast Asian Journal of Tropical Medicine and Public Health* 3: 371–375.
- COX, M. J. 1991. *The snakes of Thailand and their husbandry*. Krieger Publishing Company, Malabar, Florida, 526 pp.
- DUBEY, J. P., C. A. SPEER, AND R. FAYER. 1989. *Sarcocystosis of animals and man*. CRC Press, Boca Raton, Florida, 215 pp.
- HÄFNER, U., AND W. FRANK. 1984. Host specificity and host range of the genus *Sarcocystis* in three snake-rodent life cycles. *Zentralblatt für Bakteriologie, Mikrobiologie und Hygiene Originale A* 256: 296–299.
- . 1987. *Zystenbildende Coccidien mit Nager/Schlange-Zyklen unter besonderer Berücksichtigung der Wirtsspezifität der Gattung Sarcocystis*. Dissertation, University of Hohenheim, Stuttgart, Germany, 310 pp.
- HOLZ, J., AND L. J. SIOE. 1965. The parasites of rat in West Java. *Zeitschrift für Parasitenkunde* 25: 405–412.
- JÄKEL, T. 1995. Cyclic transmission of *Sarcocystis gerbilliechis* n. sp. by the Arabian saw-scaled viper, *Echis coloratus*, to rodents of the subfamily Gerbillinae. *The Journal of Parasitology* 81: 626–631.
- , H. BURGSTALLER, AND W. FRANK. 1996. *Sarcocystis singaporensis*: Studies on host specificity, pathogenicity, and potential use as a biocontrol agent of wild rats. *The Journal of Parasitology* 82: 280–287.

- KAN, S. P., AND A. S. DISSANAIKE. 1977. Ultrastructure of *Sarcocystis* sp. from the Malaysian house rat, *Rattus rattus diardii*. Zeitschrift für Parasitenkunde 52: 219–227.
- . 1979. Ultrastructure of the cyst wall of *Sarcocystis* spp. from some rodents in Malaysia. International Journal for Parasitology 9: 457–480.
- MEHLHORN, H., W. J. HARTLEY, AND A. O. HEYDORN. 1976. A comparative ultrastructural study of the cyst wall of 13 *Sarcocystis* species. Protistologica 12: 451–467.
- MUNDAY, B. L., R. W. MASON, W. J. HARTLEY, P. J. A. PRESIDENTE, AND D. OBENDORF. 1978. *Sarcocystis* and related organisms in Australian wildlife: I. Survey findings in mammals. Journal of Wildlife Diseases 14: 417–433.
- , AND R. W. MASON. 1980. *Sarcocystis* and related organisms in Australian wildlife: III. *Sarcocystis murinotechis* sp. n. life cycle in rats (*Rattus*, *Pseudomys*, and *Mastomys* spp.) and tiger snakes (*Notechis ater*). Journal of Wildlife Diseases 16: 83–87.
- O'DONOGHUE, P. J., C. H. S. WATTS, AND B. R. DIXON. 1987. Ultrastructure of *Sarcocystis* spp. (Protozoa: Apicomplexa) in rodents from North Sulawesi and West Java, Indonesia. Journal of Wildlife Diseases 23: 225–232.
- PATTON, S., AND A. R. RABINOWITZ. 1994. Parasites of wild Felidae in Thailand: A coprological survey. Journal of Wildlife Diseases 30: 472–475.
- RZEPCEZYK, C., AND E. SCHOLTYSECK. 1976. Light and electron microscope studies on the *Sarcocystis* of *Rattus fuscipes*, an Australian rat. Zeitschrift für Parasitenkunde 50: 137–150.
- SHEFFIELD, H. G., J. K. FRENKEL, AND A. RUIT. 1977. Ultrastructure of the cyst of *Sarcocystis muris*. The Journal of Parasitology 63: 629–641.
- ZAMAN, V., AND F. C. COLLEY. 1975. Light and electron microscopic observations of the life cycle of *Sarcocystis orientalis* sp. n. in the rat (*Rattus norvegicus*) and the Malaysian reticulated python (*Python reticulatus*). Zeitschrift für Parasitenkunde 47: 169–185.

Received for publication 16 January 1997.