

Surgical Plating of a Fractured Radius and Ulna in a Wild Canada Lynx

Authors: Poole, K. G., Elkin, B. T., Pisz, T., Elkin, K. E., Robertson, D., et al.

Source: Journal of Wildlife Diseases, 34(2) : 365-368

Published By: Wildlife Disease Association

URL: <https://doi.org/10.7589/0090-3558-34.2.365>

BioOne Complete (complete.BioOne.org) is a full-text database of 200 subscribed and open-access titles in the biological, ecological, and environmental sciences published by nonprofit societies, associations, museums, institutions, and presses.

Your use of this PDF, the BioOne Complete website, and all posted and associated content indicates your acceptance of BioOne's Terms of Use, available at www.bioone.org/terms-of-use.

Usage of BioOne Complete content is strictly limited to personal, educational, and non - commercial use. Commercial inquiries or rights and permissions requests should be directed to the individual publisher as copyright holder.

BioOne sees sustainable scholarly publishing as an inherently collaborative enterprise connecting authors, nonprofit publishers, academic institutions, research libraries, and research funders in the common goal of maximizing access to critical research.

Surgical Plating of a Fractured Radius and Ulna in a Wild Canada Lynx

K. G. Poole,^{1,4} B. T. Elkin,¹ T. Plisz,² K. E. Elkin,² D. Robertson,^{1,5} and M. L. Sabourin,³ Wildlife and Fisheries Division, Northwest Territories Department of Resources, Wildlife and Economic Development, 600-5102 50th Avenue, Yellowknife, Northwest Territories, Canada X1A 3S8; ² Great Slave Animal Hospital, Box 2255, Yellowknife, Northwest Territories, Canada X1A 2P7; ³ Box 59, Ft. Providence, Northwest Territories, Canada X0E 0L0; ⁴ Present address: Timberland Consultants Ltd., Fish and Wildlife Division, Box 171, Nelson, British Columbia, Canada V1L 5P9 (e-mail: Kpoole@timberland.org); ⁵ Present address: 15 Horton Crescent, Yellowknife, Northwest Territories, Canada X1A 3B8.

ABSTRACT: A free-ranging, adult male Canada lynx (*Lynx canadensis*) experienced a closed, complete, non-comminuted transverse fracture of the left radius and ulna when captured in a leg snare. A dynamic compression plate (DCP) attached to the anterior surface of the radius was used to stabilize the fracture. Radiographs 44 days post-surgery indicated advanced primary bone healing. The lynx was released 46 days post-surgery near the site of capture. Radiotelemetry indicated long-term survival and movements similar to other males monitored during the same period.

Key words: Fracture, lynx, *Lynx canadensis*, plating, radius, ulna.

Free-ranging wildlife may sustain injuries during capture operations conducted as part of research or management programs. It is morally and scientifically desirable to rehabilitate and release these animals back into their home ranges. Rehabilitation is not always feasible due to cost, logistics, access to treatment and holding facilities, and severity of the injuries. The successful release and survival of a wild animal in its original home range is the true measure of success in wildlife rehabilitation.

Fractures of the radius and ulna are commonly repaired using intramedullary pins, bone plates, cerclage wires, or external fixators. The type of fixation used depends on many factors including species, age of the animal, and the location and condition of the fracture. In this case, a dynamic compression plate (DCP) was used because it would be internal, did not have to be removed, and would require minimal post-surgical handling during recovery. While radius and ulnar fracture repair has been documented in a captive

Eurasian lynx (*Lynx lynx*) (Braut and Øen, 1981), no reports of fracture repair in free-ranging Canada lynx (*Lynx canadensis*) were found. This case report describes a successful fracture repair and release of a free-ranging Canada lynx.

Long term research on the ecology of the lynx has been conducted in the Mackenzie Bison Sanctuary (Northwest Territories, Canada; 61°35'N, 116°45'W) from 1989 to 1996 (Poole, 1994, 1995, 1997, Poole et al., 1996). Each winter, Fremont leg snares (Fremont Humane Traps, Candle Lake, Saskatchewan, Canada) were used to capture lynx (Mowat et al., 1994). Prior to 1994, five lynx (6% of captures) were euthanized by intravenous injection of 108 mg/kg pentobarbital (Euthanyl Forte, MTC Pharmaceuticals Ltd., Cambridge, Canada). All five lynx had fractures of the radius and ulna. Three of the five were <10-mo-old. Euthanasia was elected because rehabilitation was believed to be too costly, access to veterinary care and holding facilities was not readily available, and the success rate for the release and survival of wild felids following orthopedic surgery was unknown.

On 26 November 1995 a 11.0 kg previously untrapped adult male lynx was captured. Age was determined to be approximately 5 yr, using cementum analysis of an extracted lower 3rd incisor (Matson's Laboratory, Milltown, Montana, USA; B. Slough, Whitehorse, Yukon, Canada). The lynx was immobilized with the administration of 50 mg of Telazol (tiletamine hydrochloride (HCl) and zolazepam HCl; Fort Dodge Laboratories, Inc., Fort Dodge,

Iowa, USA) by blow-dart (Poole et al., 1993). Once immobilized, it was apparent that the left radius and ulna were fractured. Even though overnight temperatures were -21°C , the paw showed no evidence of swelling or frostbite. Thirteen min after the initial dose, an additional 50 mg Telazol was administered to provide safe transportation by snowmachine 20 km to base camp. The fractured leg was stabilized with a padded support bandage and an external splint to prevent additional trauma. The animal was then transported 20 km by snowmachine and 265 km by vehicle to the Great Slave Animal Hospital in Yellowknife (Northwest Territories, Canada).

On initial examination the animal appeared bright, alert, and stable. Anaesthesia was induced with Telazol (5 mg/kg intramuscularly (IM)). Following orotracheal intubation, gas anaesthesia was maintained with 1 to 2% isoflurane (ISO FLO, Solvay Animal Health Inc., Kitchener, Ontario, Canada) and oxygen. During the subsequent examination and surgery, 10 ml/kg/hr lactated Ringer's solution (Baxter Corporation, Pointe-Claire, Quebec, Canada) was administered intravenously (IV). Perioperative ampicillin (Penbritin, Ayerst Veterinary Laboratories, Guelph, Ontario, Canada) was administered at 80 mg/kg IV. A complete blood count and blood chemistry panel were within normal ranges reported for captive Canada lynx (Weaver and Johnson, 1995).

Radiographic examination from dorsoventral and lateral views confirmed a closed, complete, non-comminuted, transverse fracture of the radius and ulna approximately 6 cm from the radial carpal joint (Fig. 1). The animal was placed in right lateral recumbency, and the left forelimb was shaved and prepared for aseptic surgery. An anterior approach was used to access the radial fracture. A 15 cm incision was made to expose the fracture site. Soft tissue and vascular damage in the area appeared to be minimal. A DCP plate (87 mm \times 12 mm; Aesculap Instruments, San

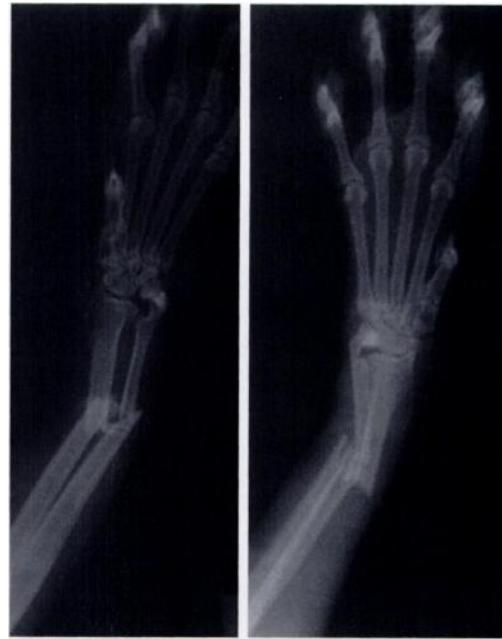

FIGURE 1. Radiograph of the left radius and ulna of a Canada lynx. Lateral and dorsoventral views show the fracture site.

Francisco, California, USA) was attached to the anterior surface of the radius with two 4.5 mm bone screws on each side of the fracture. No other fixation was applied to the ulna. Double layer closure with 3/0 Vicryl absorbable suture (Ethicon Ltd., Peterborough, Ontario, Canada) was used to close the incision. One injection of enrofloxacin (Baytril, Miles Canada Inc., Etobicoke, Ontario, Canada) was administered at 10 mg/kg IM and the lynx was allowed to recover in a plywood animal transportation cage. Recovery was uneventful, and the animal was weight bearing on its left foreleg by day two post-surgery.

On day one post-surgery, the lynx was placed in the end run of a row of indoor/outdoor kennels. A wooden transportation cage was anchored into the heated inside kennel facing out into an enclosed 3 m \times 1.5 m chainlink outdoor run. Human and domestic animal contact was restricted to minimize stress and potential disease transfer. Straw bedding was used in both the cage and outdoor run, and fresh snow was provided daily as a water source. The

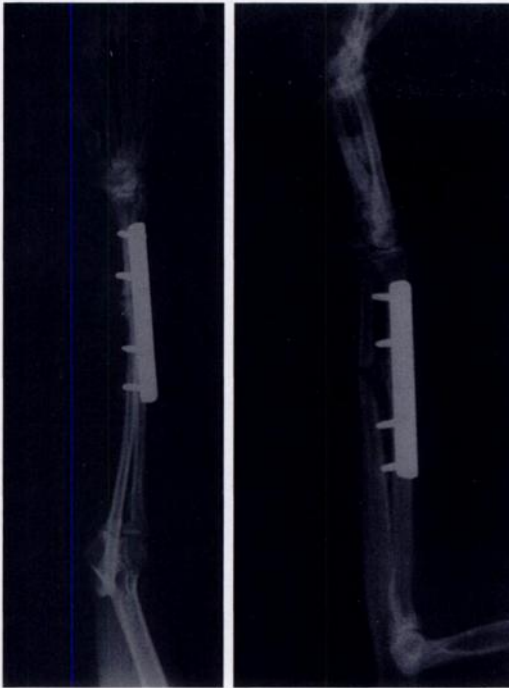


FIGURE 2. Lateral and dorsoventral views showing the plate and screw assembly and the degree of bone regeneration 44 days post operation in a Canada lynx with a fractured radius and ulna.

lynx was fed *ad libitum* whole snowshoe hares (*Lepus americanus*), spruce grouse (*Dendragapus canadensis*), and willow ptarmigan (*Lagopus lagopus*) provided in part by the public from hunting or by road-kills. This diet was supplemented with whole chicken and vitamin/mineral supplements when the lynx's normal prey species were not available. The animal began to eat regularly at four days post-surgery, consuming up to one hare, grouse or ptarmigan each day.

Due to temperatures of -40°C , release of the lynx to the capture site was delayed until adequate regrowth of the hair on the foreleg. On 9 January 1996 (44 days post-surgery), the lynx was anaesthetized with 85 mg Telazol IM. The skin incision had healed well, but hair growth was slower than expected. Radiographs indicated callus bridging and remodeling of the radial fracture, and a periosteal callus at the ulnar fracture site (Fig. 2). The lynx weighed

12.5 kg, and was in good body condition. Completion of clinical union via bone plating can take 5 months to 1 yr in adult animals (Brinker et al., 1990). The decision was made to release the lynx with the plate in situ and existing hair regrowth given the degree of bone healing, weight gain, and the anticipated stress of additional prolonged captivity. Concerns about prolonged captivity included physiological stress, potential disease transfer from domestic animals at the holding site, nutritional imbalance, activity restriction and subsequent muscle atrophy, and the behavioral impacts of prolonged human contact and dependency. A 150 g radio-collar (Telonics Inc., Mesa, Arizona, USA) was placed around the neck to monitor movements (Poole, 1995). On 11 January 1996 (46 days post-surgery) the lynx was released at the initial capture site.

There are several unique anatomical features of the radius and ulna in lynx that influence the surgical approach for fracture repair. In members of the genus *Lynx*, the radius and ulna are particularly flat and slender bones with extremely narrow medullary cavities (Braut and Øen, 1981). The dorsoplantar surface of the radius and the lateral/medial aspect of the ulna are the broadest surfaces available for plating. These surfaces are concave in the horizontal plane, except for the distal two-thirds of the dorsal radius which is convex. This is a consideration in bone plating, because commercially available plates are designed for use on bones with a convex surface. In lynx, only the distal two-thirds of the radius is convex. Plate attachment may be more difficult on the ulna and proximal radius.

The surgical device selected in this case was based on the type of fracture, the limited post-surgical patient contact, and desire for release as soon as possible following surgery. Casting the leg as either a primary treatment or secondary to internal fixation was not considered appropriate given the type of fracture, the limitations on subsequent re-examination for cast as-

assessment, and the tendency of lynx to chew off casts (Braut and Øen, 1981). Intra-medullary pinning was not considered because the fractures of the radius and ulna were transverse and the medullary cavities were extremely narrow. Bone plating was considered the most suitable method for fixation because it provides the advantage of rigid internal fixation and anatomical alignment without interfering with joint function, allowing early return to function (Bennet and Kuzma, 1992). The contact achieved between plate and bone in this case was satisfactory, and provided good bone apposition and stability for primary bone healing.

Follow-up physical and radiographic examinations were not possible to confirm the success of the corrective surgery; however, evidence of successful rehabilitation and resumption of normal activity was documented by radiotelemetry. Between 12 January and 13 December, 1996 the lynx was relocated 19 times using aerial or ground-based radiotelemetry. Movements between relocations and the resultant 95% minimum convex polygon home range derived from these locations was 45.7 km², a figure similar to other male lynx monitored during the same period in the snowshoe hare cycle (Poole, 1994; K. G. Poole, unpubl. data). Because the animal was newly captured, we were unable to compare its home range distribution before and after capture. However, the home range observed after release encompassed the initial capture location. In addition, in March 1996 a fresh set of lynx tracks were observed within 200 m of the estimated location of the lynx, as determined by radiotelemetry triangulation. These tracks were no different than other adult male lynx tracks.

Radial and ulnar fractures are possible whenever wild fields are being live-trapped with leg-holding devices. Treatment and surgical repair should be considered if the animal is likely able to return

to the wild. In the future, there may be pressure from the public, animal welfare organizations, and wildlife management agencies to consider rehabilitation for research related injuries. The actual costs for such cases is an important consideration in rehabilitation decisions and in research design and approval itself. Rehabilitation costs include personnel time, transportation of the animal, veterinary care, and hospitalization. In this case, the total costs of rehabilitation and release would have been approximately \$1,000 (Cdn), if services had not been subsidized or donated by the veterinary clinic, government staff and the public.

LITERATURE CITED

- BENNET, R. A., AND A. B. KUZMA. 1992. Fracture management in birds. *Journal of Zoo and Wildlife Medicine* 23: 5-38.
- BRINKER, W. O., D. L. PIERMATTEI, AND G. L. FLO. 1990. *Handbook of small animal orthopedics and fracture treatment*. 2nd Edition. W. B. Saunders Co., Philadelphia, Pennsylvania, 582 pp.
- BRAUT, T., AND E. O. ØEN. 1981. Neutralization bone-plating repair of a fractured radius and ulna in a lynx: A case report. *Nordisk Veterinaermedicin* 33: 374-376.
- MOWAT, G., B. G. SLOUGH, AND R. RIVARD. 1994. A comparison of three live capturing devices for lynx: Capture efficiency and injuries. *Wildlife Society Bulletin* 22: 644-650.
- POOLE, K. G., G. MOWAT, AND B. G. SLOUGH. 1993. Chemical immobilization of lynx. *Wildlife Society Bulletin* 21: 136-140.
- . 1994. Characteristics of an unharvested lynx population during a snowshoe hare decline. *The Journal of Wildlife Management* 58: 608-618.
- . 1995. Spatial organization of a lynx population. *Canadian Journal of Zoology* 73: 632-641.
- . 1997. Dispersal patterns of lynx in the Northwest Territories. *The Journal of Wildlife Management* 61: 497-505.
- , L. A. WAKELYN, AND P. N. NICKLEN. 1996. Habitat selection by lynx in the Northwest Territories. *Canadian Journal of Zoology* 74: 845-850.
- WEAVER, J. L., AND M. R. JOHNSON. 1995. Hematologic and serum chemistry values of captive Canadian lynx. *Journal of Wildlife Diseases* 31: 212-215.

Received for publication 24 March 1997.