



Isolation of *Brucella melitensis* from Alpine Ibex

Authors: Ferroglio, E., Tolari, F., Bollo, E., and Bassano, B.

Source: Journal of Wildlife Diseases, 34(2) : 400-402

Published By: Wildlife Disease Association

URL: <https://doi.org/10.7589/0090-3558-34.2.400>

BioOne Complete (complete.BioOne.org) is a full-text database of 200 subscribed and open-access titles in the biological, ecological, and environmental sciences published by nonprofit societies, associations, museums, institutions, and presses.

Your use of this PDF, the BioOne Complete website, and all posted and associated content indicates your acceptance of BioOne's Terms of Use, available at www.bioone.org/terms-of-use.

Usage of BioOne Complete content is strictly limited to personal, educational, and non - commercial use. Commercial inquiries or rights and permissions requests should be directed to the individual publisher as copyright holder.

BioOne sees sustainable scholarly publishing as an inherently collaborative enterprise connecting authors, nonprofit publishers, academic institutions, research libraries, and research funders in the common goal of maximizing access to critical research.

Isolation of *Brucella melitensis* from Alpine Ibex

E. Ferroglio,^{1,3} F. Tolari,¹ E. Bollo,² and B. Bassano,¹ ¹Department of Animal Productions, Epidemiology and Ecology, Faculty of Veterinary Medicine, Via Nizza 52 -10126- Turin, Italy; ² Department of Animal Pathology, Faculty of Veterinary Medicine, University of Turin, Via Nizza 52 -10126- Turin, Italy; ³ Corresponding author (e-mail: bigatti@bib.unito.it).

ABSTRACT: Eleven alpine ibex (*Capra ibex*) and 27 chamois (*Rupicapra rupicapra*) from Gran Paradiso National Park (Italy) were examined in March 1996. A 7-yr-old ibex buck had thick-walled carpal joints and enlargement of the right testicle characterized by necrosis and fibrosis. Microscopically, testicular lesions were characterized by large areas of necrosis, fibrosis with irregular aggregates of macrophages and lymphocytes, and scattered foci of suppuration. Specimens of the carpal bursae and testicle were cultured in serum dextrose agar and serum dextrose antibiotic plates. A Gram-negative coccobacillus was isolated from the testicle and subsequently identified as *Brucella melitensis* biotype 2. This is the first recognized case of brucellosis in alpine ibex.

Key words: Alpine ibex, *Brucella melitensis* biotype 2, brucellosis, *Capra ibex*, case report.

Brucellosis, a highly contagious disease, has been reported in the Palearctic Region from roe deer (*Capreolus capreolus*) (Schiel, 1936; Burgisser, 1954; Guiraud et al., 1984), chamois (*Rupicapra rupicapra*) (Bouvier et al., 1951, 1958; Garin-Bastuji et al., 1990), fallow deer (*Cervus dama*) (McDiarmid, 1951), maral deer (*Cervus elaphus maral*) (Tretyak, 1973), reindeer (*Rangifer tarandus*) (Golosov and Zabrodin, 1959), Sardinian moufflon (*Ovis musimon*), red deer (*Cervus elaphus hispanicus*) and Spanish ibex (*Capra pyrenaica hispanica*) (Leon-Vizcaino et al., 1985). However, while in North America brucellosis is endemic in some population of bison (*Bison bison*), elk (*Cervus elaphus nelsoni*) and caribou (*Rangifer tarandus tarandus*) (McCorquodale and Di Giacomo, 1985; Tessaro, 1986), cases of brucellosis in wild ruminants from Europe are sporadic.

Alpine ibex (*Capra ibex*) are considered susceptible to brucellosis (Couturier, 1962), but the infection has never been reported in this species (Tolari et al., 1987;

Gauthier et al., 1991). This paper describes the first report of brucellosis infection in this species.

At the end of the last century alpine ibex survived where the Gran Paradiso National Park (GPNP), Italy (45°31'N, 7°16'E), was established in 1922, and all existing populations originated from that location. In the first months of 1996 severe winter conditions in GPNP resulted in death of 612 ibex and 504 chamois. In March 1996 some of them, 11 ibex (10 males and 1 female) and 27 chamois (19 males and 8 females), were subjected to necropsy at the Faculty of Veterinary Medicine (Turin, Italy). All animals were diagnosed as death from starvation according to Dean and Thorn (1982). Enlargement and fibrosis of the right testicle (Fig. 1) was found in a 7-yr-old male ibex, collected from the Orco Valley of the GPNP. Cut surface of the testicle and epididymis was characterized by foci of necrosis, cystic cavities filled by purulent material surrounded by a connective tissue capsule, as well as diffuse fibrosis of the parenchyma. Both carpal joints were enlarged; cut surfaces contained necrotic and suppurative foci which were often confluent, and surrounded by a thick connective capsule. Other lesions were by small (0.5 cm in diameter) nodules in the spleen, catarrhal bronchopneumonia, pulmonary emphysema, and catarrhal tracheitis.

Microscopically, large areas of granulomatous inflammation characterized by necrosis, lymphocytic, macrophage and neutrophil infiltration, together with fibrosis, sperm stasis, and thickening of the tunica albuginea were in the testicle. Nodules in the spleen were characterized by necrosis, lymphocytic and macrophage infiltration. Catarrhal bronchopneumonia resulted

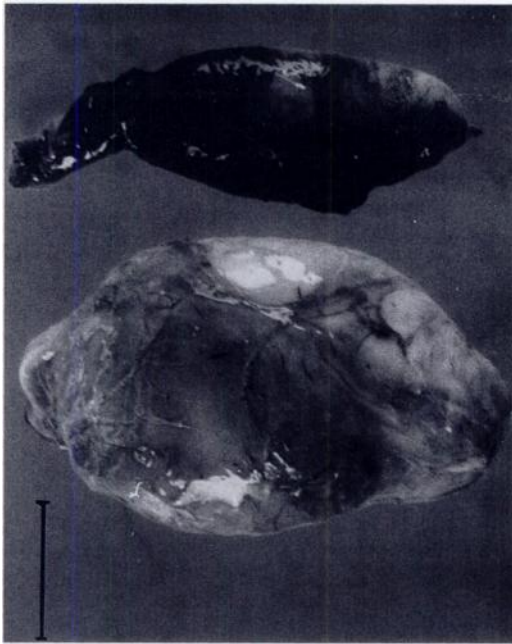


FIGURE 1. Enlargement of the right testicle in comparison to the left testicle of an alpine ibex with brucellosis from Italy. Bar = 3 cm.

from an infiltration by polymorphonuclear granulocytes, macrophages, as well as loss of bronchiolar epithelial cells.

Sections of affected testicular and epididymal tissues were stained by the immunoperoxidase method with a monoclonal antibody directed against the epitopes of A antigen of *Brucella* (Ciuchini et al., 1989). Scattered foci of positivity for *Brucella* sp. antigen were detected, mainly around the necrotic areas (Fig. 2).

Samples of testicular tissue close to the granulomatous lesions were homogenized in phosphate buffered saline pH 7.2 using a Stomacher 80 (Seward Medical, London, UK). The homogenate and synovial fluid from the carpal joints were cultured in duplicate on serum dextrose agar (SDA) and serum dextrose antibiotic plates (Farrel, 1974). Cultures were incubated at 37°C in air plus 10% v/v carbon dioxide for up to 2 wk.

Colonies resembling those of *Brucella* sp. were observed in testicle cultures, but not in the cultures of the synovial fluid.

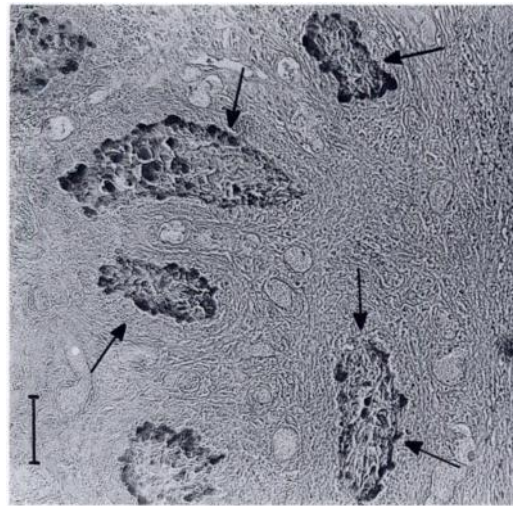


FIGURE 2. Foci of positivity of *Brucella* sp. antigens in the necrotic area of a testicular granuloma (arrows) in an alpine ibex from Italy with brucellosis. Immunoperoxidase. Bar = 50 μ m.

The isolate did not require CO₂ for growth, did not produce H₂S, was not inhibited by fucsin and thionin, was agglutinated by A monospecific antiserum and not by M monospecific antiserum and R specif serum, was sensitive to Berkeley and Izatnagar phages at RTD by the lawn-spot method, and not sensitive to Tbilisi, Weybridge, Firenze and R/C phages. According to Corbel and Brinley-Morgan (1984) and to Corbel et al. (1988) the isolate was identified as *Brucella melitensis* biotype 2. This biotype is the most common in infected sheep herds in Italy (Tolari and Farina, 1988).

Brucella melitensis is the major cause of ovine and caprine brucellosis in the Mediterranean area and it is highly pathogenic for humans (Alton, 1990). Ovine and caprine brucellosis eradication campaigns are in progress in northwestern Italy, but a relatively high seroprevalence (4%) is still present in the region including the area where the infected ibex was found (Regione Piemonte, 1995). More than 4,700 sheep graze G.P.N.P. in summer. Livestock herds share pastures with more than 4,600 ibex and 7,300 chamois, and this may allow transmission of *Brucella* sp. infection. Fur-

ther investigations are needed to assess the persistence of *B. melitensis* within the ibex colony and its potential transmission to other species.

The authors are grateful to V. Peracino and the gamekeepers of the Gran Paradiso National Park for providing the opportunity to conduct this survey. The authors also thank L. Rossi, A. Mannelli and two anonymous referees for helpful comments on the manuscript.

LITERATURE CITED

- ALTON, G. G. 1990. *Brucella melitensis*. In Animal brucellosis, K. Nielsen and J. R. Duncan (eds.). CRC Press, Boca Raton, Florida, pp. 383–411.
- BOUVIER G., H. BURGISSER, AND R. SCHWEIZER. 1951. Observations sur les maladies du gibier et des poissons en 1949 et 1950. Schweizer Archiv für Tierheilkunde 93: 275–281.
- , ———, AND P. A. SCNEIDER. 1958. Les maladies des ruminants sauvages de la Suisse. Fondation B. Galli Valerio (ed.), Lausanne, Suisse, 132 pp.
- BURGISSER, H. 1954. Premier cas de Brucellose du Chevreuil signalé en Suisse. Revue de pathologie générale et Comparée 654: 124–126.
- CIUCHINI, F., R. ADONE, L. MORELLI, C. PISTOIA, AND F. TOLARI. 1989. Produzione e caratterizzazione di anticorpi monoclonali verso epitopi del complesso "A" di *Brucella* spp. Atti Società Italiana Scienze Veterinarie 43: 971–975.
- CORBEL M. J., AND W. J. BRINLEY MORGAN. 1984. Genus *Brucella* Meyer and Shaw 1920. In: Bergey's Manual of Systematic Bacteriology, Vol. 1., N. R. Krieg, and J. G. Holt (eds.). Williams & Wilkins, Baltimore, Maryland, pp. 377–388.
- , F. TOLARI, AND V. K. YADAVA. 1988. Characterisation of phage lytic for smooth and non-smooth *Brucella* species. Research in Veterinary Science 44: 45–49.
- COUTURIER, M. A. J. 1962. Le Bouquetin des Alpes. Couturier M. A. J. (ed.). Grenoble, France, 1,564 pp.
- DEAN, R. E., AND E. T. THORNE. 1982. Starvation in wild ruminants. In Diseases of Wildlife in Wyoming, 2nd Edition. E. T. Thorne, N. Kingston, W. R. Jolley, and R. C. Bergstrom (eds.). Wyoming Game and Fish Department, Cheyenne, Wyoming, pp. 274–280.
- FARREL, I. D. 1974. The development of a new selective medium for the isolation of *Brucella abortus* from contaminated sources. Research in Veterinary Science 16: 280–286.
- GARIN-BASTUIJ, B., J. OUDAR, Y. RICHARD, AND J. GASTELLU. 1990. Isolation of *Brucella melitensis* biovar 3 from a chamois (*Rupicapra rupicapra*) in the Southern French Alps. Journal of Wildlife Diseases 26: 116–118.
- GAUTHIER, D., P. GILBERT, AND J. HARS. 1991. Sanitary consequences of mountain cattle breeding on wild ungulates. Ongules/Ungulates 91: 621–630.
- GOLOSOV, I. M., AND V. A. ZABRODIN. 1959. Brucellosis in reindeer. Veterinariya Moscow 36: 23–25 (in Russian).
- GUIRAUD, C., F. DE BASTARD, AND J. BARRANT. 1984. Brucellose du chevreuil. Deux observations dans les Hautes Pyénées. Bulletin d'Information sur la pathologie des animaux sauvages 2: 69–71.
- LEON-VIZCAINO, L., M. MOLERA, A. GASCA, F. GARRIDO, D. RODRIGUEZ, AND L. HIERRO. 1985. Serological survey of prevalence of antibodies to brucellosis in wild ruminants in Jaén (Spain). Verhandlungsbericht des 27 Internationalen Symposiums über die Erkrankungen der Zootiere 27: 455–461.
- MCCORQUODALE, S. M., AND R. F. DI GIACOMO. 1985. The role of wild North American ungulates in the epidemiology of bovine brucellosis: A review Journal of Wildlife Disease 21: 351–357.
- MCDIARMID, A. 1951. The occurrence of agglutinins for *Br. abortus* in the blood of wild deer in the south of England. The Veterinary Record 63: 469.
- REGIONE PIEMONTE. 1995. Relazione di attività 1994. Assessorato all' Assistenza sanitaria Settore Assistenza Veterinaria. Torino, Italy, 150 pp.
- SCHIEL, O. 1936. Abortus—Bang Bakteriennachweis im Hoden eines Rehbockes. Zeitschrift für Fleisch und Milchhygiene 47: 114–115.
- TESSARO, S. V. 1986. The existing and potential importance of brucellosis and tuberculosis in Canadian wildlife: A review. The Canadian Veterinary Journal 27: 119–124.
- TOLARI, F., P. G. MENEGUZZ, D. DE MENECHI, L. ROSSI, AND F. MANCIANTI. 1987. Indagini sieropidemiologiche su stambecchi, camosci ed ovini presenti nel Parco Naturale Argentera. Atti del Convegno Internazionale "Lo Stambecco delle Alpi; realtà attuale e prospettive" T. Balbo, D. De Meneghi, P. G. Meneguzzi, and L. Rossi (eds.). Valdieri, Italy, pp. 83–92.
- , AND R. FARINA. 1988. Methods for the identification of *Brucella* isolates in use at the Animal Pathology Department, University of Pisa, result of eight years activity. Annali della Facoltà di Medicina Veterinaria dell'Università di Pisa 41: 227–232.
- TRETYAK, N. T. 1973. Brucellosis in maral. Veterinariya Moscow. 1: 58–59 (in Russian).

Received for publication 19 February 1997.