

PATHOLOGY OF NEWCASTLE DISEASE IN DOUBLE-CRESTED CORMORANTS FROM SASKATCHEWAN, WITH COMPARISON OF DIAGNOSTIC METHODS

Authors: Kuiken, Thijs, Wobeser, Gary, Leighton, Frederick A., Haines, Deborah M., Chelack, Brian, et al.

Source: Journal of Wildlife Diseases, 35(1) : 8-23

Published By: Wildlife Disease Association

URL: <https://doi.org/10.7589/0090-3558-35.1.8>

BioOne Complete (complete.BioOne.org) is a full-text database of 200 subscribed and open-access titles in the biological, ecological, and environmental sciences published by nonprofit societies, associations, museums, institutions, and presses.

Your use of this PDF, the BioOne Complete website, and all posted and associated content indicates your acceptance of BioOne's Terms of Use, available at www.bioone.org/terms-of-use.

Usage of BioOne Complete content is strictly limited to personal, educational, and non - commercial use. Commercial inquiries or rights and permissions requests should be directed to the individual publisher as copyright holder.

BioOne sees sustainable scholarly publishing as an inherently collaborative enterprise connecting authors, nonprofit publishers, academic institutions, research libraries, and research funders in the common goal of maximizing access to critical research.

PATHOLOGY OF NEWCASTLE DISEASE IN DOUBLE-CRESTED CORMORANTS FROM SASKATCHEWAN, WITH COMPARISON OF DIAGNOSTIC METHODS

Thijs Kuiken,¹ Gary Wobeser,¹ Frederick A. Leighton,¹ Deborah M. Haines,² Brian Chelack,² Jaret Bogdan,² Lori Hassard,² Robert A. Heckert,^{3,4} and José Riva^{3,5}

¹ Canadian Cooperative Wildlife Health Centre, Department of Veterinary Pathology, Western College of Veterinary Medicine, University of Saskatchewan, 52 Campus Drive, Saskatoon, Saskatchewan S7N 5B4, Canada

² Department of Veterinary Microbiology, Western College of Veterinary Medicine, University of Saskatchewan, 52 Campus Drive, Saskatoon, Saskatchewan S7N 5B4, Canada

³ Virology Section, Animal Diseases Research Institute, Canadian Food Inspection Agency, 3851 Fallowfield Road, Nepean, Ontario K2H 8P9, Canada

⁴ Current address: Virginia-Maryland College of Veterinary Medicine, University of Maryland, 8075 Greenmead Drive, College Park, Maryland 20742, USA

⁵ Current address: National Centre for Foreign Animal Diseases, 1015 Arlington Street, Winnipeg R3E 3M4, Canada

ABSTRACT: Newcastle disease (ND) in juvenile double-crested cormorants (*Phalacrocorax auritus*) occurred several times since 1975, but there are relatively few studies on its pathology and diagnosis. In order to describe the distribution of Newcastle disease virus (NDV) and associated lesions in cormorants with ND and to compare diagnostic methods, 25 cormorants with nervous signs from a ND epizootic in Saskatchewan in 1995 (NDE cormorants) were compared with 18 negative control cormorants. Tissues of these birds were examined by necropsy, histology, virus isolation, immunohistochemistry, serology, and reverse transcriptase-polymerase chain reaction (RT-PCR) methods. The NDE cormorants had a characteristic non-suppurative encephalomyelitis, with a significantly higher prevalence of neuronal necrosis, gliosis, perivascular infiltration with mononuclear cells, and endothelial hypertrophy than control cormorants. These lesions were found more frequently in the cerebellum and brain stem than in other parts of the central nervous system. Immunohistochemically, NDV antigen was limited to neurons, glial and endothelial cells in the central nervous system, and to tubular epithelial cells in the kidney. Newcastle disease virus was isolated with the highest prevalence (4/5) and the highest concentration ($10^{4.8}$ ELD₅₀/g) from the kidney. The virus isolates often did not agglutinate erythrocytes in the standard hemagglutination test; the presence of NDV was confirmed by use of an indirect immunoperoxidase assay. By RT-PCR, NDV was detected in kidney and jejunum of a NDE cormorant. There was no significant difference between sensitivity of histology, virus isolation, and serology for detecting ND in NDE cormorants.

Key words: Avian paramyxovirus type 1, double-crested cormorant, immunohistochemistry, Newcastle disease, *Phalacrocorax auritus*, pathology, polymerase chain reaction, serology.

INTRODUCTION

Pathogenic Newcastle disease virus (NDV) caused severe nervous disease in juvenile double-crested cormorants, *Phalacrocorax auritus*, (hereafter referred to as cormorants) several times since 1975 (Cleary, 1977; Wobeser et al., 1993; Meteyer et al., 1997; Kuiken et al., 1998). Pathogenic NDV is here defined as a NDV isolate with an intracerebral pathogenicity index in chickens of >0.7 (Commission of the European Communities, 1993). Despite the importance of Newcastle disease (ND) both for wild birds and domestic poultry, there are few studies on its pathology and diagnosis in cormorants.

In past studies, cormorants suspected of ND were examined by necropsy, histology, virus isolation, immunofluorescence, and serology. Characteristic histological lesions were found in the brain and spinal cord, and included Purkinje cell necrosis, lymphoplasmacytic vasculitis, perivascular cuffs, and gliosis (Wobeser et al., 1993; Banerjee et al., 1994; Meteyer et al., 1997). Brain and intestine appeared to be the best tissues for virus isolation (Meteyer et al., 1997).

An epizootic of ND in cormorants on Doré Lake (Saskatchewan, Canada) in 1995 was monitored. Some aspects of this epizootic, including clinical signs, contact with other bird species, and mortality rate,

have been described previously (Kuiken et al., 1998). Herein, the pathological findings in 25 cormorants from this epizootic are compared with those in 18 cormorants without ND. The main objectives were (1) to describe the distribution of NDV and associated lesions, and (2) to evaluate different methods of ND diagnosis in cormorants.

MATERIALS AND METHODS

Birds

Twenty-five cormorants with clinical signs of nervous disease, hereafter referred to as ND epizootic (NDE) cormorants, were collected alive during a ND epizootic on Doré Lake (Saskatchewan, Canada; 54°46'N, 107°17'W), which was first noted on 23 July 1995. They were found between 23 July and 18 August 1995 on one of three colony sites on Doré Lake: Island A ($n = 19$), Island B ($n = 1$), and Rock Island ($n = 5$) (Kuiken et al., 1998). Ten cormorants were collected in the first week after onset of the epizootic, five in the second week, three in the third week, and seven in the fourth week.

Eighteen cormorants, hereafter referred to as control cormorants, were collected dead ($n = 12$) or alive ($n = 6$) from Island A, Doré Lake. They were young of the year in complete or nearly complete juvenile plumage, similar in age to NDE cormorants. They were found between 7 July and 1 September 1994 ($n = 14$), 16 June 1995 ($n = 2$), and on 29 July 1996 ($n = 1$), and 19 August 1996 ($n = 1$). The primary diagnoses were severe trauma, caused by coyote (*Canis latrans*) predation ($n = 12$), a fallen branch ($n = 1$), or an unknown cause ($n = 2$), starvation ($n = 1$), beak malformation ($n = 1$), and bilateral rotation of the carpal joint ($n = 1$).

Necropsy

Necropsies were done on all cormorants. Live birds were monitored for about 5 min to observe their clinical signs, then killed by cervical dislocation. Necropsies were performed by one person using a standard protocol. The birds were divided into three categories of body condition: birds in good body condition had well-developed musculature and visible fat in the coronary groove, mesentery and abdominal subcutis; birds in moderate body condition had moderately developed musculature, visible fat in the coronary groove but not in the mesentery or abdominal subcutis; and birds in poor body condition had atrophied musculature and

no visible fat in the coronary groove, mesentery, or abdominal subcutis. Samples for virological, bacteriological, and serological examination were stored in liquid nitrogen, and samples for histological examination were stored in 10% neutral-buffered formalin.

Serology

Sera from 20 NDE and eight control cormorants were held at 56 C for 30 min, adsorbed once with guinea pig erythrocytes to remove nonspecific hemagglutinins, and tested for hemagglutination inhibiting antibodies to NDV using guinea pig erythrocytes (Beard, 1989). Eight hemagglutination units of NDV B1 strain were used as antigen. A titer of $\geq 1:20$ was considered positive (Brown et al., 1990).

Histology

Formalin-fixed samples from all cormorants were embedded in paraffin, sectioned at 5 μ m, and stained with hematoxylin and eosin (H & E) for examination by light microscopy. Selected heart sections also were stained with hematoxylin-basic fuchsin-picric acid to detect muscle degeneration or oil red-O to detect fat (Luna, 1968). The following tissues were examined: brain (sagittal sections taken a few mm from the median plane), spinal cord (transverse sections at the level of the seventh cervical vertebra, third thoracic vertebra, and middle of the synsacrum), left and right brachial plexus (transverse sections), left and right lumbosacral plexus (transverse sections), left and right eye (sections including optic nerve), eyelid, bursa of Fabricius, thymus, spleen, femoral bone marrow, esophagus, stomach, duodenum, pancreas, liver, jejunum, ileum and ceca, colon, trachea, left and right lung, heart, thoracic aorta, pectoral muscle, quadriceps muscle, proximal tibia, left and right kidney, left and right thyroid and parathyroid, left and right adrenal gland, uropygial gland, ovary and oviduct or left and right testis.

Sections of cerebrum, cerebellum, brain stem, cervical, thoracic, and lumbar spinal cord, and brachial and lumbosacral plexus of all NDE cormorants were examined and a list of all lesions seen was prepared. Then, the identification numbers of sections of all cormorants were masked, the sections were re-examined in arbitrary order, and scored for the presence or absence of listed lesions without knowledge of the bird's origin.

Other organ systems of all NDE cormorants also were examined by light microscopy. Any tissue with lesions found in more than six NDE birds also was examined for the presence of similar lesions in all control cormorants.

Virus isolation

Virus isolation was attempted on pooled tissues of all cormorants. The tissues of each cormorant were treated separately. Samples of brain, trachea, lung, liver, kidney, spleen, jejunum, and femoral bone marrow were pooled and homogenized with 0.01 M phosphate-buffered saline solution (pH 7.4; PBS) in a Stomacher (Seward Medical, London, U.K.) to obtain a 1:10 dilution. After freezing at -80°C , samples were thawed in a 37°C water bath, centrifuged at 2,600 g at 4°C for 10 min, and the supernatant was filtered, the final filter having a pore size of $0.22\text{ }\mu\text{m}$. A 0.15 ml volume of filtrate was injected into each of five embryonated chicken eggs (Alexander, 1989) and three passages without 100% embryo mortality were carried out before a case was considered negative.

Allantoic fluid from eggs with dead embryos was tested for the presence of hemagglutinating agents with a hemagglutination (HA) test (Beard, 1989). Hemagglutination-positive samples were tested for the presence of NDV with a hemagglutination inhibition test (Beard, 1989), using polyclonal chicken antiserum to NDV. Because many of the allantoic fluid samples from dead embryos were negative in the HA test, an indirect immunoperoxidase assay (IPA), which does not depend on the hemagglutination activity of NDV, was used to determine whether NDV was present (see IPA below).

Virus isolation was attempted on individual tissues of five NDE cormorants (cases 1 to 5), found on Island A, Doré Lake, on 23 and 24 July, 1995, at the beginning of the ND epizootic. A sample of each tissue (brain, trachea, lung, liver, kidney, spleen, jejunum, and femoral bone marrow) was homogenized with bovine heart infusion (BHI) broth in a Ten Broeck tissue grinder (VWR Canlab, Mississauga, Ontario, Canada) to obtain a 1:10 dilution. The BHI broth consisted of 33.3 mg/ml BHI powder (BDH, Toronto, Ontario, Canada), 10% bovine serum, 10×10^3 U/ml penicillin (Ayerst, Montreal, Quebec, Canada), and 10 mg/ml streptomycin (ICN, Costa Mesa, California, USA) in distilled water. After centrifugation at 2000 g at 4°C for 20 min, the supernatant was harvested and diluted 9:10 with PBS containing gentamycin (5 mg/ml; Sigma, St Louis, Missouri, USA). The diluted supernatant was left for 1 hr at room temperature, centrifuged again, and the supernatant was used for virus isolation procedures as described above. Allantoic fluid samples from eggs with dead embryos were tested for the presence of NDV only with IPA (see IPA below). Samples were

considered negative if no embryo mortality occurred during two passages and allantoic fluid harvested at the end of the second passage tested negative in the IPA.

Indirect immunoperoxidase assay (IPA)

The method for this assay was adapted from Afshar et al. (1989). One ml of allantoic fluid sample was filtered through a $0.45\text{ }\mu\text{m}$ filter, and then diluted 1:10 in Earle's minimum essential medium supplemented with 20% fetal bovine serum and 50 $\mu\text{g/ml}$ gentamycin (MEM). Of this mixture, 25 μl was added to a well of a 96-well flat-bottom tissue culture microtiter plate (Nunc, Roskilde, Denmark), containing about 5×10^9 confluent Vero cells (National Veterinary Services Laboratory, Ames, Iowa, USA) in 75 μl MEM per well. The plate was incubated in a humidified atmosphere of 5% CO_2 and 95% air for 72 hr at 37°C , by which time an infected cell monolayer was formed. The plate was voided of its medium by gentle inversion. The monolayers were rinsed briefly with PBS, drained, and fixed for 10 min at room temperature with 20% acetone in PBS containing 0.02% bovine serum albumin. The plate was voided of acetone by gentle inversion and dried with a blow dryer. The monolayers were rehydrated by rinsing with PBS. Fifty μl of a 1:800 dilution of polyclonal chicken antiserum against NDV was added to each well and the plate was incubated at 25 to 30°C . After 30 min, the wells were drained of serum and rinsed with PBS containing 0.05% Tween (PBST) three times for 2 min each at room temperature. The wells were filled with 50 μl of a 1:1000 dilution of horseradish peroxidase-labelled rabbit anti-chicken IgG (Jackson Immunoresearch Laboratories, West Grove, Pennsylvania, USA) and incubated for 30 min at 25– 30°C . The wells were again emptied, rinsed in PBST, and filled with 50 μl of substrate solution containing H_2O_2 (Afshar et al., 1989). The enzymatic reaction was stopped after 12 min by emptying the wells and rinsing them with PBST and then with distilled water. Cells were examined with an inverted light microscope (Olympus CK-2, Olympus Corporation, Lake Success, New York, USA). Positive wells had red-brown staining of Vero cells. Wells containing Vero cells infected with NDV (B1 vaccine strain) were run concurrently as positive controls. Wells containing Vero cells, allantoic fluid samples, and serum from NDV-free chickens also were run as negative controls.

Virus titration

The virus concentration of NDV-positive tissue samples was determined by making serial

ten-fold dilutions of each sample in PBS, injecting 0.1 ml into the allantoic cavity of each of five chicken eggs containing 9 to 10-day-old embryos, and monitoring embryo death daily for 7 days post inoculation. The virus concentration was expressed as the negative exponent of the dilution at which 50% of the embryos died (ELD₅₀; Villegas and Purchase, 1989).

Immunohistochemistry

Immunohistochemical staining was performed on the tissues of five NDE cormorants (cases 1 to 5), collected on 23 and 24 July 1995. The same tissues were examined as for histological examination. Tissues were fixed in 10% neutral-buffered formalin for two days, embedded in paraffin, and immunohistochemical staining was conducted using an avidin-biotin complex immunoperoxidase method (Vectra Stain Elite [PK6100], Vector Laboratories, Burlington, Ontario, Canada; Haines and Chelack, 1991) adapted for a robotic stainer (Fisher Code-on Immunostainer, Fisher Scientific Co., Edmonton, Alberta, Canada; Brigati et al., 1988). A chicken polyclonal antiserum to NDV (Spafas, Preston, Connecticut, USA) was used as the primary antibody. Briefly, duplicate sections of each tissue block were stained with NDV antiserum diluted 1:2000. The enzyme reactions were developed in diaminobenzidine (Electronmicroscopic Laboratories, Fort Washington, Pennsylvania, USA) to produce a dark brown precipitate and the sections were counterstained with hematoxylin. The amount of staining was scored from negative to 3+ relative to that in the positive control tissue. Sections of cerebellum from a cormorant from which NDV had been isolated were used as a positive control. Tissue sections of a captive-raised cormorant, which was serologically and virologically negative for NDV, were used as a negative control. Tissue sections of a cormorant from which NDV had been isolated were processed as above, but omitting the primary antibody, as an omission control.

Reverse Transcriptase-polymerase chain reaction (RT-PCR) test and nucleotide sequencing

A RT-PCR test was used to determine the presence of NDV in kidney and jejunum of one NDE cormorant (case 2), collected on 23 July 1995. For each tissue, a 10% suspension in BHI broth was incubated with 0.02 mg/ml of proteinase K and 1% sodium dodecyl sulfate (final concentrations) for 2 hr at 56 C to extract the nucleic acid. After RNA extraction with phenol-chloroform-isoamyl alcohol and concentration with ethanol, the nucleic acid sample was centrifuged in vacuum and the result-

ing pellet was resuspended in 40 µl of distilled water per ml of 10% tissue suspension. Of this, 5 µl was used per RT-PCR test. The RT-PCR reaction was carried out essentially according to Harding et al. (1994). Primers 7 (5'-TTA-GAAAAACACGGGTAGAA-3') and 2 (5'-AGTCGGAGGATGTTGGCAGC-3') (Collins et al., 1996) were used to hybridize with the first part of the fusion gene, including the fusion gene cleavage site. The PCR protocol consisted of 40 cycles of denaturation for 1 min at 94 C, primer annealing for 1 min at 56 C, and elongation for 2 min at 72 C. Resultant RT-PCR products were purified by electrophoresis in LMP agarose (GibcoBRL, Burlington, Ontario, Canada) followed by DNA extraction using the Magic PCR-Prep system (Promega, Madison, Wisconsin, USA). To confirm the identity of the RT-PCR products, nucleotide sequencing was carried out by use of Amplitaq DNA polymerase (Perkin Elmer, Branchburg, New Jersey, USA), primer 7 (5'-TTA-GAAAAACACGGGTAGAA-3'), and an automated nucleic acid sequencer. Nucleotide sequence editing, analysis, prediction of amino acid sequences, and alignments were carried out with GeneWorks 2.5.1 software (Oxford Molecular Ltd., Oxford, UK).

Bacteriology

Samples of brain, trachea, lung, liver, spleen, kidney, jejunum, and femoral bone marrow from a NDE cormorant with multisystemic fibrino-suppurative inflammation were cultured on blood agar (Prepared Media Laboratory, Richmond, British Columbia, Canada). The inoculated media were incubated at 37 C in an aerobic atmosphere and examined daily for 2 days for bacterial growth. An isolated colony representative of each bacterial variant detected visually was selected and identified according to methods of Carter and Cole (1990).

Statistical analysis

The Fisher exact test was used to test the null hypothesis that the proportion of cormorants with a given lesion was the same in the NDE and control groups (Zar, 1996). Because this test was used 12 times to compare the two groups, a Bonferroni-corrected *P*-value of 0.05/12 = 0.004 was employed to maintain a study-wise *P*-value of 0.05 (Howell, 1987). The Cochran's Q test was used to test the null hypothesis that the probability of a ND-positive result in NDE cormorants was the same for histological, virological, and serological examination (Zar, 1996). The level of α was determined at *P* ≤ 0.05.

RESULTS

Clinical signs

All 25 NDE cormorants showed clinical evidence of central nervous system dysfunction. Twenty-two of the 25 had partial or complete paralysis of one or more limbs: one wing (one bird), both wings (four birds), one leg (two birds), both legs (six birds), one wing and one leg (two birds), one wing and both legs (one bird), both wings and one leg (one bird), and both wings and both legs (five birds). Other nervous signs included head tremors (seven birds), ataxia (four birds), standing on a foot with toes curled (two birds), walking in circles (one bird), and apparent blindness (one bird).

Necropsy

All 25 NDE cormorants were young of the year in complete or nearly complete juvenile plumage, and were no longer restricted to their nest. Ten were male and 15 were female. They were 7- to 9-wk-old, based on a median hatching date of 16 June 1995 (Kuiken et al., 1998), and their body weight ranged from 982 to 1,820 g. Twelve birds were in good, five in moderate, and eight in poor body condition.

Externally, one bird had a breast wound with surrounding hemorrhage at the level of the thoracic inlet, which perforated the body wall and trachea about 1 cm anterior to the bifurcation. Another bird had a featherless area of 2 cm diameter on the rump, with hemorrhage in the subcutis. These wounds were probably caused by gulls (*Larus* spp.). In two birds with leg paralysis, the legs were held tucked against the body with curled toes, and the knee, tarsometatarsal and digital joints were stiff and could only be extended with considerable force. In five birds with wing paralysis, the wings were held against the body and the elbow and carpal joints were stiff and could not be extended fully. In two birds with leg paralysis, the skin and feathers of the leading edges of both carpal joints were abraded, due to leaning on the ground with their wings. In one bird

with paralysis of all four limbs, the skin and feathers on the dorsal aspect of the right elbow joint were abraded due to wing movements while the bird was lying on its back.

Eye lesions were found in 11 birds. Excess watery fluid, wetting the surrounding plumage, exuded from the eye in six birds. Plaques of yellow-white friable material, which were easily dislodged, were present in the conjunctival sac of five birds. The cornea of one bird had a circumscribed white spot 2 mm in diameter, and the cornea of another bird was slightly opaque. The conjunctiva of the sclera (two birds), nictitating membrane (one bird) and eyelid (one bird) were reddened. The nictitating membrane in the bird with the reddened nictitating membrane also was thickened and opaque. Two birds had bilateral pupil dilation.

Internally, the brain parenchyma was edematous in two birds, and there was excess watery fluid in the subdural space of the cranium in three birds. One bird had generalized venous congestion. There was pallor of the middle layer of the myocardium of the left ventricle in three birds. The spleen appeared reduced in size in one bird, enlarged in three birds, and had miliumary subcapsular hemorrhages in one bird. One of the enlarged spleens had white nodules of 1 to 2 mm diameter. The pancreas had a white nodule of 1 mm diameter in the parenchyma in one bird. The liver of six birds had multiple white irregular tracts about 0.5 mm in diameter and up to 30 mm long, multiple white miliumary nodules, or both, in the parenchyma. The liver was reduced in size with sharp edges in five birds, and had a hemorrhage of 7 mm diameter on the surface in one bird. Nematodes were present in the stomach of 25 birds, either loose in the lumen or attached to the wall. The stomach of 24 birds contained no food, and the intestine of all 25 birds was empty.

Nervous system histopathology

Lesions in the brain and spinal cord of NDE cormorants included neuronal ne-

TABLE 1. Distribution of neurological lesions in double-crested cormorants with clinical signs consistent with Newcastle disease.

Tissue	n ^a	Number of cormorants with each lesion							
		Neuronal necrosis	Spongy change	Gliosis	Perivascular infiltration with mononuclear cells		Endothelial hypertrophy	Hemorrhage	Axonal degeneration
					Parenchyma	Meninges			
Cerebrum	25	8	4	13	20	9	12	7	NE ^b
Cerebellum	25	17	11	18	18	15	19	2	NE
Brain stem	25	13	11	15	21	11	21	1	NE
Spinal cord									
Cervical	23	2	3	2	8	7	8	1	NE
Thoracic	24	3	6	6	9	3	7	1	NE
Lumbar	24	10	8	8	6	5 ^c	7	0	NE
Plexus									
Brachial	22	NE	NE	NE	3	NE	5	0	7
Lumbosacral	25	NE	NE	NE	3	NE	12	0	14

^a Newcastle disease virus was isolated from 21 of 25 birds.^b Not examined or not applicable.^c Only 21 of 24 sections of lumbar spinal cord had meninges present.

crosis, spongy change, gliosis, perivascular infiltration with mononuclear cells, endothelial hypertrophy, and hemorrhage (Tables 1 and 2). These lesions often were found together in discrete foci. However, perivascular infiltration with mononuclear cells and endothelial hypertrophy were found regularly in the absence of other lesions.

Neuronal necrosis was most often seen as shrunken angular neurons with eosinophilic cytoplasm and no nucleus (Fig. 1). Less common lesions included cell swell-

ing, central chromatolysis, peripheral displacement of the nucleus, and pyknosis. Necrotic neurons were most often seen in the cerebellar nuclei and in the brain stem. Neuronal necrosis also was recognized by the decreased number or absence of neurons in the Purkinje cell layer of the cerebellum and in the ventral horn of the grey matter of the spinal cord.

Spongy change consisted of round, optically empty spaces in the parenchyma, and probably was caused by necrosis and loss of neurons and axons. It was found

TABLE 2. Prevalence of lesions in the central nervous system^a of double-crested cormorants with clinical signs consistent with Newcastle disease, compared to negative control cormorants.

Cormorant group	n	Number of birds with each lesion (%)						
		Neuronal necrosis	Spongy change	Gliosis	Perivascular infiltration with mononuclear cells		Endothelial hypertrophy	Hemorrhage
					Parenchyma	Meninges		
Newcastle disease epizootic	25 ^b	19 (76)	17 (68)	22 (88)	24 (96)	20 (80)	23 (92)	8 (32)
Negative control	17 ^c	2 (12)	9 (53)	0 (0)	1 (6)	0 (0)	3 (8)	7 (41)
<i>P</i> -value ^d		<0.001	0.35	<0.001	<0.001	<0.001	<0.001	0.78

^a Cerebrum, cerebellum, brain stem, and/or cervical spinal cord.^b Cervical spinal cord was available from only 23 cormorants.^c Brain stem was available from only 13 cormorants and cervical spinal cord from only 14 cormorants.^d Statistic of the Fisher exact test; a value of *P* < 0.004 indicates a statistically significant difference between the two groups.

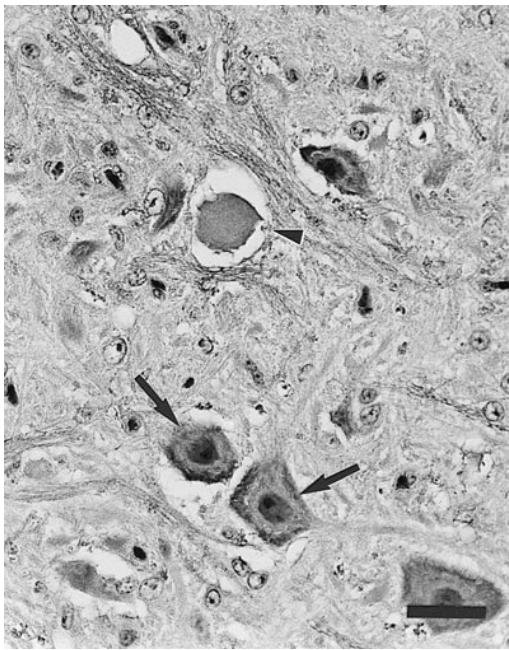


FIGURE 1. Neuronal necrosis in the brain stem of a double-crested cormorant with Newcastle disease. The necrotic neuron (arrowhead) is shrunken and has no nucleus. Adjacent neurons (arrows) are normal. H & E. Bar = 30 μ m.

most often as discrete foci in the cerebellar nuclei, in the brain stem, and in the ventral horn of the grey matter of the lumbar spinal cord (Fig. 2).

Gliosis consisted of a multifocal to diffuse increase of small cells in the parenchyma, usually around necrotic neurons. These gliotic foci were most easily visible in the molecular layer of the cerebellum, because it normally had few visible small cells (Fig. 3).

Perivascular infiltration with mononuclear cells in the parenchyma of brain and spinal cord usually consisted of a compact cuff, one to four cells thick (Fig. 4), but in some cases up to 15 cells thick. The cells were mainly medium-sized lymphocytes; plasma cells were regularly present, and heterophils were rarely found. The meninges usually had a more diffuse infiltration of mononuclear cells.

Endothelial hypertrophy usually was found in small blood vessels, and was characterized by large endothelial nuclei with

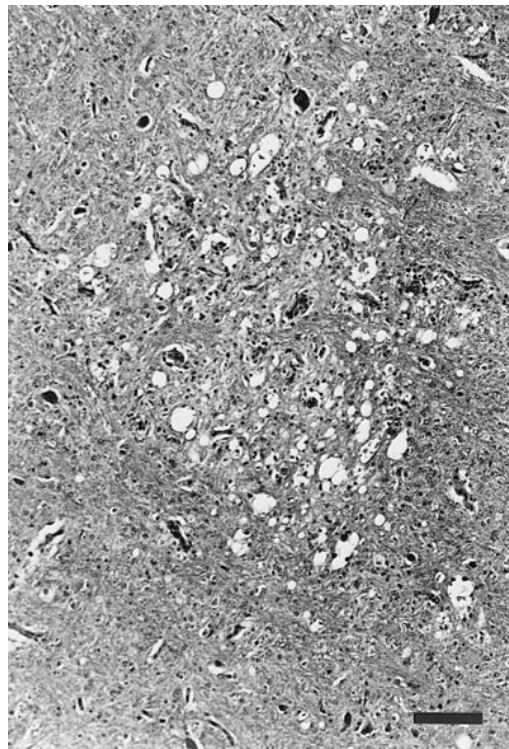


FIGURE 2. Spongy change in the brain stem of a double-crested cormorant with Newcastle disease. H & E. Bar = 100 μ m.

vesiculated chromatin protruding into the vascular lumen (Fig. 4). Hemorrhages, when present, were small and perivascular.

Lesions in the brachial and lumbosacral plexus of NDE cormorants consisted of axonal degeneration, endothelial hypertrophy, and perivascular infiltration with mononuclear cells. Axonal degeneration consisted of swelling and fragmentation of axons, and the formation of ellipsoids (Fig. 5).

Negative control cormorants also had some of the above lesions in the nervous system (Table 2). A necrotic neuron was found in a cerebellar nucleus of a cormorant killed by a coyote in 1994. Several necrotic Purkinje cells were found in a cormorant from 1995 with a bacterial meningoencephalitis associated with puncture wounds of the skull. Spongy change was found in nine cormorants killed by coyotes in 1994, and was usually more diffuse than

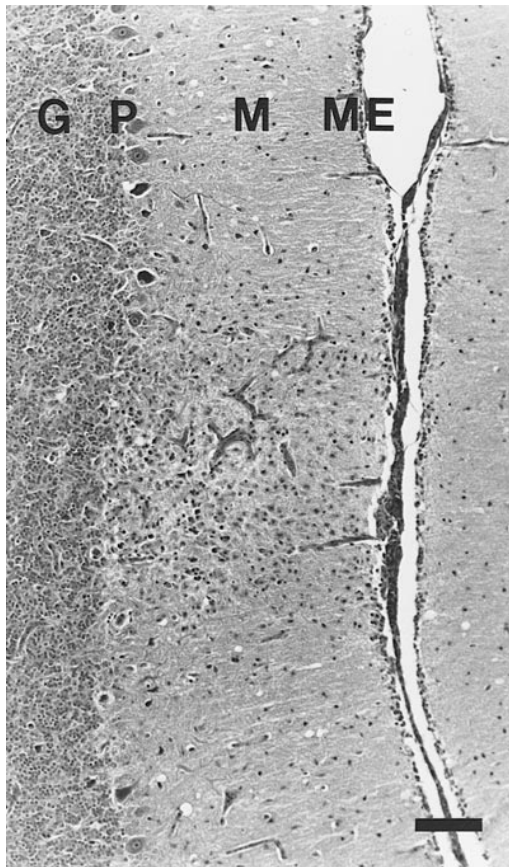


FIGURE 3. Gliosis in the cerebellum of a double-crested cormorant with Newcastle disease. The molecular layer (M) has a focal increase of small cells, and Purkinje cells in the subjacent Purkinje cell layer (P) are missing. The granular layer (G) and meninges (ME) are also shown. H & E. Bar = 50 μ m.

in NDE cormorants. A one to four-cell-thick cuff of mononuclear cells was found around three blood vessels in the white matter of the cerebellum of a cormorant killed by a coyote in 1994. Endothelial hypertrophy was found in three cormorants which died of starvation in 1994, coyote predation in 1994, and head trauma of unknown cause in 1996, respectively. Hemorrhage was found in seven cormorants which died of trauma, six of which were killed by coyotes in 1994 and one by a falling branch in 1996. The hemorrhage was usually more extensive than in NDE cormorants. Axonal degeneration, endothelial hypertrophy, and perivascular infiltration

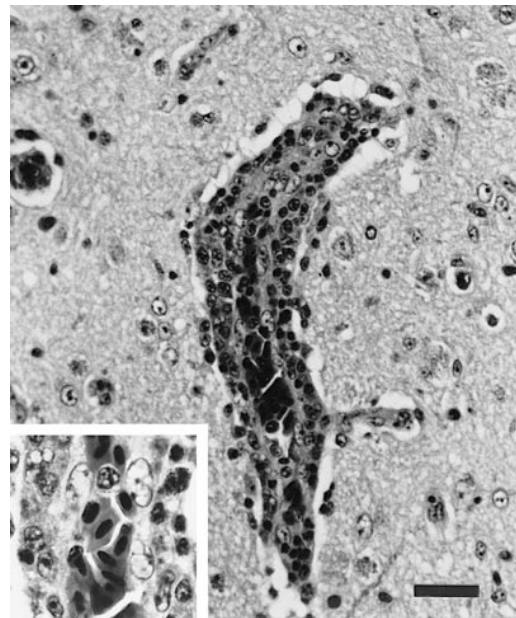


FIGURE 4. Perivascular infiltration with mononuclear cells in the cerebrum of a double-crested cormorant with Newcastle disease. The blood vessel has a compact cuff of mononuclear cells. Inset: The endothelial cells have large nuclei protruding into the vascular lumen. H & E. Bar = 30 μ m.

with mononuclear cells were not found in the brachial ($n = 1$) nor lumbosacral ($n = 6$) plexus of control cormorants.

There was a significant difference ($P < 0.001$) between NDE and control cormorants in the prevalence of neuronal necro-

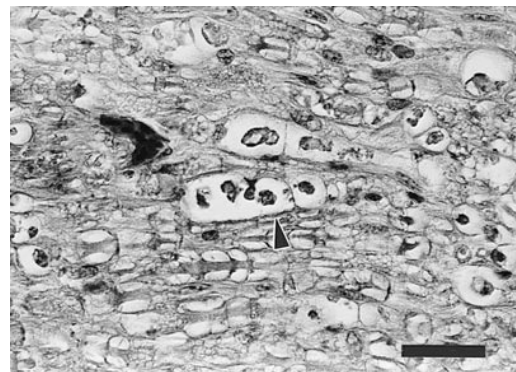


FIGURE 5. Axonal degeneration in the lumbosacral plexus of a double-crested cormorant with Newcastle disease. One axon is swollen and fragmented, and has formed an ellipsoid (arrowhead). H & E. Bar = 30 μ m.

TABLE 3. Prevalence of lesions in lung, pancreas, kidney and eyelid of double-crested cormorants with clinical signs consistent with Newcastle disease, compared to negative control cormorants.

Cormorant group	Number of cormorants with each lesion/number of cormorants tested(%)					
	Foci of mononuclear cells in the			Renal tubular necrosis	Suppurative conjunctivitis	Erosions or ulcers in the skin of the eyelid
	Lung	Pancreas	Kidney			
Newcastle disease epizootic	6/25 (24)	12/25 (48)	21/25 (84)	10/21 (48)	23/25 (92)	13/25 (52)
Negative control	5/18 (28)	7/11 (64)	11/17 (65)	2/11 (18)	9/10 (90)	4/12 (33)
<i>P</i> -value ^a	0.94	0.62	0.28	0.14	0.63	0.48

^a Statistic of the Fisher exact test; a *P*-value of <0.004 indicates a statistically significant difference between the two groups.

sis, gliosis, perivascular infiltration with mononuclear cells, and endothelial hypertrophy in the central nervous system (Table 2). The prevalence of lesions in the brachial and lumbosacral plexus between NDE and control cormorants was not compared statistically, because of the small number of samples from control cormorants.

Lymphoid system histopathology

Newcastle disease epizootic cormorants had lymphocyte necrosis and depletion in the thymus (25/25 birds), bursa of Fabricius (23/23 birds), and spleen (11/25 birds). Lymphocyte necrosis was seen as small cells with pyknosis or karyorrhexis, often within optically empty spaces; lymphocyte depletion was characterized by fewer lymphocytes than normal, or none. In one bird, the parenchyma of a thymic lobule was largely replaced by serous fluid admixed with erythrocytes and heterophils; in two birds, the spleen had pools of serous fluid and fibrin around necrotic sheathed capillaries.

The spleen in three of 25 birds had hyperplasia of large, round to oval cells around hypertrophic sheathed capillaries. These cells had large nuclei with finely stippled chromatin, a moderate amount of light blue vacuolated cytoplasm, and ≤ 1 mitotic figure per high power (400 \times) field, and were thought to be reticulum cells. The three birds were all from the first week of the ND epizootic and had enlarged spleens.

Histopathology in other organ systems

The prevalence of lesions consistent with ND and found in more than six NDE cormorants is compared to that in control cormorants in Table 3. In NDE birds, foci of mononuclear cells were found in the following tissues: lung, not associated with bronchi (6/25 birds); lamina propria, submucosa and serosa of proventriculus (5/25 birds); submucosa of gall bladder (3/21 birds); pancreas (12/25 birds); myocardium (2/24 birds); kidney (21/25 birds); submucosa of ureter (2/25 birds); wall of oviduct (1/14 birds); adrenal gland (2/25 birds); and uropygial gland (1/25 birds). There was necrosis of a few tubular epithelial cells adjacent to the foci in the kidneys in 10 of the above 21 birds.

There was suppurative conjunctivitis in 23 of 25 birds, varying from mild (nine birds) to moderate (11 birds) to severe (three birds), and characterized by diffuse heterophil infiltration in the epithelium and lamina propria; the lamina propria also had a variable number of lymphocytes and plasma cells. All 11 cormorants with gross eye lesions had a moderate to severe conjunctivitis histologically. The friable material found in the conjunctival sac at necropsy consisted of plaques of fibrin, heterophils, sloughed epithelial cells and bacterial colonies. There was mild to moderate suppurative keratitis in five of 25 birds, all of which had gross eye lesions. The keratitis was characterized by diffuse heterophil infiltration of the corneal stroma. In addition, the cornea had multiple

erosions (one bird), a corneal ulcer and neovascularisation (one bird), or epithelial hyperplasia (one bird). Three of the above birds also had mild to moderate suppurative anterior uveitis, characterized by diffuse heterophil infiltration in the filtration angle of the anterior chamber and the iris. The skin of the eyelid had multifocal epidermal erosions or ulcers in 13 of 25 birds. These lesions were covered by crusts of necrotic epithelial cells, heterophils, erythrocytes, fibrin, bacterial colonies, and debris. The underlying subcutis was infiltrated by heterophils.

There was mild to moderate superficial granulomatous proventriculitis, associated with the presence of nematodes in 22 of 25 birds. The liver (16/25 birds) and pancreas (1/25 birds) had mild to moderate multifocal granulomatous inflammation, associated with the presence of trematodes. The myocardium had locally extensive fatty change in three of 24 birds. These birds had pallor of the left ventricle on necropsy. The areas consisted of myocytes with variably sized small intracytoplasmic vacuoles, which stained positive for fat with oil red O. There was no evidence of myocyte degeneration in H & E stained sections nor in sections stained with hematoxylin-basic fuchsin-picric acid. The interrenal (cortical) cells of the adrenal gland were small and eosinophilic due to loss of lipid vacuoles in 14 of 25 birds. The chromaffin (medullary) cells of the adrenal gland were infiltrated by a few to moderate numbers of mature granulocytes in three of 25 birds. There was serous atrophy of fat, in which the fat was replaced by a network of fine eosinophilic fibrils, in six of 18 birds. One cormorant, which had generalized venous congestion on necropsy, had a fibrino-suppurative inflammation of the meninges, pericardium, myocardium, pleura, pectoral muscle, arteries, veins, ovary, liver, and uvea, associated with a generalized *Escherichia coli* infection.

There was no statistically significant difference between NDE and control cor-

morants in the prevalence of lesions in the lung, pancreas, kidney, or eyelid (Table 3).

Virus isolation

Newcastle disease virus was isolated from pooled tissues of 21 of 25 NDE cormorants. The allantoic fluid had a titre in the HA test of <1:2 in 19 cases, 1:32 in one case, and 1:64 in one case. The two HA test-positive allantoic fluid samples had titres of 1:240 in the hemagglutination inhibition test. The allantoic fluid of all 21 cases was positive in the IPA. The four NDV-negative NDE cormorants were found in the last two weeks of the ND epizootic. Newcastle disease virus was not isolated from pooled tissues of any of 18 control cormorants.

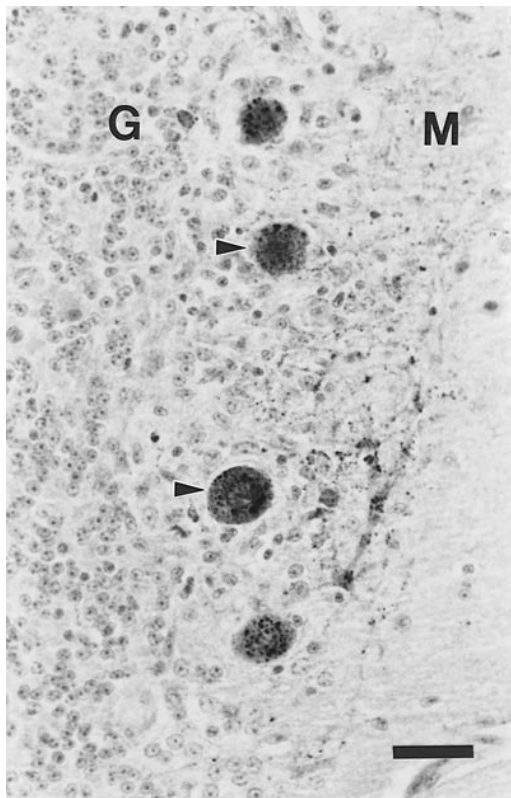
Newcastle disease virus was isolated from eight individual tissues in the five NDV-positive birds thus examined. Kidney was the tissue most frequently positive and had the highest virus concentration (Table 4). All eight samples were positive in the IPA.

Immunohistochemistry

Specific staining for NDV in the five cormorants tested was limited to the nervous system and the kidney (Table 4), and consisted of variably-sized distinct dark-brown granules in the cytoplasm. Specific staining in the nervous system was found in the cerebrum, cerebellum, and brain stem (5/5 cases), thoracic spinal cord (1/5 cases) and lumbar spinal cord (3/5 cases). The strongest staining was found consistently in the cerebellum. Specifically stained cells were neurons (including Purkinje cells and granule cells in the cerebellum; Fig. 6), glial cells, and, rarely, endothelial cells of small blood vessels. Areas of specific staining usually corresponded with foci of neuronal necrosis and inflammation. However, many marked histological lesions in the nervous system had no or weak specific staining. No specific staining was found in the cervical spinal cord (0/4 cases), brachial plexus (0/3 cases), or lumbosacral plexus (0/5 cases). Specific

TABLE 4. Virus isolation and immunohistochemical detection of Newcastle disease virus in individual tissues of five double-crested cormorants, collected on 23 and 24 July 1995.

Cormorant number	Brain ^a		Spinal cord ^b		Kidney		Jejunum	
	VI ^c	IHC ^d	VI	IHC	VI	IHC	VI	IHC
1	—	+	NE ^e	—	2.6	+	—	—
2	3.3	+++	NE	++	4.7	+++	2.2	—
3	—	++	NE	—	4.8	++	—	—
4	—	++	NE	+	<2.0	++	—	—
5	<2.0	+	NE	+	—	—	—	—

^a Cerebrum, cerebellum, and brain stem.^b Cervical, thoracic, and lumbar spinal cord. Cervical spinal cord of only four cormorants was examined.^c Virus isolation in embryonated chicken eggs. The result is expressed as negative (—) or, in positive tissues, as log Egg Lethal Dose 50% per g tissue.^d Immunohistochemical examination; the amount of staining scored from negative (—) to strongly positive (+++) relative to that in the positive control tissue.^e Not examined.FIGURE 6. Immunohistochemical staining of Newcastle disease virus in the cerebellum of a double-crested cormorant. Positive staining is visible as variably-sized granules in the cytoplasm of Purkinje cells (arrowheads), lying in between the granular layer (G) and the molecular layer (M). Hematoxylin counterstain. Bar = 20 μ m.

staining in the kidney was found in four of five cormorants tested. Specifically stained cells were tubular epithelial cells in cortex and medulla (Fig. 7), and usually corresponded with tubular epithelial necrosis adjacent to interstitial foci of mononuclear cells.

Non-specific staining consisted of diffuse light-brown staining of epithelial cells, most marked in the intestine, and dark-brown staining of granules of heterophils. This non-specific staining did not interfere with interpretation of the tissue sections, except in intestine and tissues with many heterophils, such as spleen, thymus, and eyelid. Although they were included in the study, specific staining in these tissues may have been masked by non-specific staining.

RT-PCR test and nucleotide sequencing

Kidney and jejunum samples from the one NDE cormorant tested (case 2) were positive for NDV by RT-PCR test. The nucleotide sequence of part of the RT-PCR products, which were about 500 base pairs long, was ³⁷⁰ATCTAGAGGAAGGAGACAGAAACGTTTTGTAGGTGCT⁴⁰⁶, with the predicted amino acid sequence ¹⁰⁹SRGRRQKRFGVGA¹²⁰, which corresponds to the fusion gene cleavage site of NDV (Seal et al., 1995).

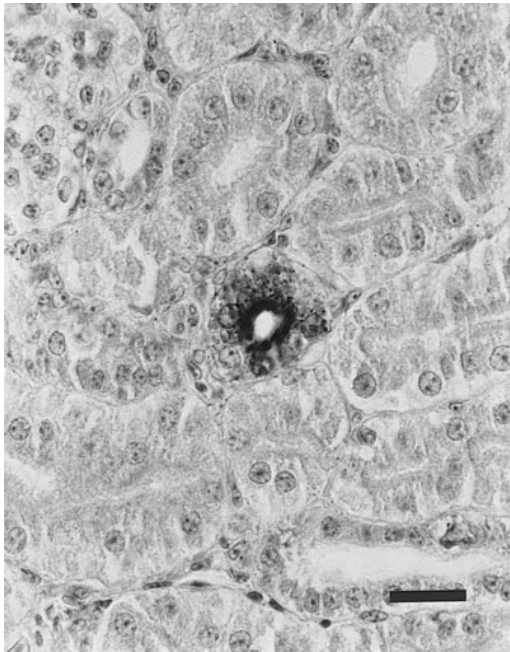


FIGURE 7. Immunohistochemical staining of Newcastle disease virus in the kidney of a double-crested cormorant. Positive staining is visible as variably-sized granules in the cytoplasm of tubular epithelial cells, and is strongest on the apical side. Hematoxylin counterstain. Bar = 20 μ m.

Serological examination

Fourteen of 20 NDE cormorant sera tested positive for hemagglutination inhibiting antibodies to NDV, with titres of 1:20 ($n = 9$) or 1:40 ($n = 5$). All eight control cormorant sera tested negative.

Comparison of methods for ND diagnosis

There was no significant difference in the probability of a ND-positive result be-

tween histological, virological, and serological examination ($Q = 4.22$, $P > 0.05$; Table 5).

DISCUSSION

Newcastle disease virus was isolated from 21 of 25 NDE cormorants, confirming that they had ND. A virus isolate from the same group of birds (PMV-1/cormorant/Saskatchewan-Canada/2035/95) was previously confirmed as pathogenic, with an intravenous pathogenicity index of 1.23 and an intracerebral pathogenicity index of 1.61 (Kuiken et al., 1998). The virus isolate had the same predicted amino acid sequence of the fusion gene cleavage site as those from ND epizootics in cormorants in 1990 and 1992 (Seal et al., 1995; Heckert et al., 1996). This sequence included the R-for-G substitution at position 110, which appears to be unique for NDV isolates obtained from cormorants and associated species since 1990, and suggests that this virus has been circulating in the cormorant population for several years.

The four NDE cormorants that were negative for NDV by virological examination had brain lesions characteristic for ND (Meteyer et al., 1997; this study); three of them also had hemagglutination inhibiting antibodies to NDV (Table 5). Together, these findings indicate that these four birds also had ND. One NDE cormorant, from which NDV was isolated, had no visible ND lesions in the brain. Wobeser et al. (1993) also found no microscopic lesions in the brain of one of

TABLE 5. Comparison of three methods used for the diagnosis of Newcastle disease in 25 double-crested cormorants with clinical signs consistent with this disease.

Diagnostic method	Number positive (%)	Test result combinations ^a					
		+	+	+	+	+	+
Histology ^b	24 (96)	+	+	+	+	+	+
Virus isolation	21 (84)	+	+	+	+	+	+
Serology	14 (70)	+	NE	+	+	+	+
Number of birds per combination		11	5	4	3	1	1

^a+ = positive, - = negative, NE = not examined.

^bHistology was considered positive if cerebrum, cerebellum, brain stem, and/or cervical spinal cord had neuronal necrosis, perivascular infiltration with mononuclear cells, and/or gliosis.

three cormorants from which NDV was isolated. However, Meteyer et al. (1997) found that all 16 NDV-positive cormorants had brain lesions.

Nineteen of the 21 virus isolates from the NDE cormorants were negative in the HA test, which is traditionally used as a screening test for NDV (Alexander, 1989). In a laboratory where only the HA test is used, therefore, ND would not have been diagnosed in these birds. Hemagglutination may not have occurred because these isolates were highly pathogenic to chicken embryos and killed them before reaching sufficient concentration in the allantoic fluid to cause hemagglutination. Alternatively, the virus isolates may have had no or little ability to cause hemagglutination. Although hemagglutination is considered a characteristic property of NDV (Alexander, 1997), exceptions are known; for example, Karzon and Bang (1951) isolated a velogenic NDV strain (CG 179) from an outbreak in California which did not consistently agglutinate erythrocytes. Whatever the reason, a test which did not depend on hemagglutination was necessary to identify reliably the isolates from these cormorants. In this study an IPA was used, which makes use of the specific binding between NDV and anti-NDV antibody. This assay was straightforward to use, inexpensive, and allowed the testing of many samples concurrently.

The distribution of NDV in five NDE cormorants, collected on the first 2 days after onset of the epizootic, was limited to brain, kidney, and jejunum (Table 4). Of these, the kidney had both the highest prevalence of infection and the highest concentration of NDV. This is comparable to chickens infected with neurotropic NDV, in which the virus concentration in the kidney was about 1×10^3 greater than in other tissues during clinical disease (Asdell and Hanson, 1960). Therefore, kidney should be included in the tissues collected for virus isolation in cases of suspected ND in cormorants. In previous studies (Wobeser et al., 1993; Banerjee et al.,

1994; Meteyer et al., 1997) this was not done, probably because kidney is not on the standard list of tissues for NDV isolation (Alexander, 1989) and because kidney lesions in cormorants with ND are not conspicuous (Banerjee et al., 1994; this study).

The brain of NDE cormorants had NDV antigen in neurons, glial cells, and endothelial cells, which corresponds with the localization of neurotropic NDV in chickens (Wilczynski et al., 1977). The presence of NDV antigen usually was associated with neuronal necrosis, gliosis, endothelial hypertrophy, and perivascular infiltration with mononuclear cells (Figs. 1–4). These lesions correspond with those found previously in cormorants with ND (Wobeser et al., 1993; Banerjee et al., 1994; Meteyer et al., 1997) and are considered characteristic for this disease in other bird species also (Kaleta and Baldauf, 1988; Alexander, 1997). However, although these lesions are useful to help establish a diagnosis of ND in cormorants, they are not pathognomonic. Other viral diseases, e.g., avian influenza and avian encephalomyelitis, although not reported in cormorants, cause similar lesions (Swayne, 1996). Also, in this study neuronal necrosis, endothelial hypertrophy, and perivascular infiltration with mononuclear cells were found in a few cormorants with no clinical or virological evidence of ND (Table 2). All but one of these control cormorants were young of the year found on Island A in 1994 or 1996, in which years there was no evidence of NDV infection in cormorants on Island A from virology, serology, or observation of clinical signs (Kuiken et al., 1998). Therefore, it is unlikely that these control cormorants had been in contact with NDV.

The kidney of NDE cormorants had NDV antigen in tubular epithelial cells, in both the cortex and medulla, which corresponds to its location in chickens with ND (Kölbl, 1978). The presence of NDV antigen was often associated with small foci of necrotic tubular epithelial cells and

interstitial infiltration with mononuclear cells; similar kidney lesions were found in ND in cormorants (Banerjee et al., 1994), pigeons (Barton et al., 1992), turkeys (Al-Sheikhy and Carson, 1975), chickens (Jungherr et al., 1946), and house sparrows (*Passer domesticus*) (Gustafson and Moses, 1952). The lesions in the kidney were mild in relation to the high concentration of NDV in that tissue, in contrast to the situation in the brain. The high prevalence of NDV in the kidney suggests that it may be an important source of excreted virus.

The lymphocyte depletion and necrosis in the lymphoid organs of the NDE cormorants are consistent with lesions found previously in cormorants (Wobeser et al., 1993; Banerjee et al., 1994; Meteyer et al., 1997) and domestic poultry (Alexander, 1997). Such lesions may have a variety of causes (Riddell, 1987), and therefore have little diagnostic value.

Comparison of histology, virus isolation, and serology to diagnose ND showed that each method was useful, but that none of them were positive in all 25 NDE cases (Table 5). In our opinion, diagnosis of ND in cormorants is best attempted with a combination of methods. Exposure to NDV may be ascertained by serology, both in live and dead birds. Cormorant carcasses may be screened for ND by histological examination of the central nervous system and kidneys; multiple locations should be examined, because lesions may have a restricted distribution. Lesions caused by ND may be differentiated from those caused by other diseases with immunohistochemistry. However, cross-reaction with other avian paramyxoviruses, particularly serotype 3, is possible in both immunohistochemistry—if a polyclonal antiserum is used—and serology (Alexander, 1997). Furthermore, it is not possible to determine the pathogenicity of the virus with these methods. Currently, the only unequivocal method of ND diagnosis, which also allows characterization of the infecting strain, is virus isolation (Alexander, 1997). Tissues for virus isolation should include

kidney, brain and intestine. Identification of isolated viruses should not depend only on the HA test, because NDV isolates from cormorants may be HA-negative. Because NDV virulence is related to the predicted amino acid sequence of the fusion gene cleavage site, the RT-PCR test, combined with nucleotide sequencing of the fusion gene cleavage site, may eventually result in a partial reduction in traditional live-animal testing for assessment of pathogenicity of NDV isolates (Seal et al., 1995). In addition, this test is useful to determine the epidemiological relationship between isolates. The RT-PCR test usually is done on viruses amplified in embryonated chicken eggs (e.g., Seal et al., 1995), but it can also be performed directly on tissues of diseased cormorants, as demonstrated in this study.

ACKNOWLEDGMENTS

This project was supported by the Canadian Co-operative Wildlife Health Centre, the Wildlife Health Fund of the Western College of Veterinary Medicine, Canadian Wildlife Service (Environment Canada), Canadian Food Inspection Agency, Saskatchewan Environment and Resource Management, Animal Health Trust of Canada, Alberta Sports, Recreation, Parks and Wildlife Foundation, and the University of Saskatchewan. We thank M. Harding and S. Vydelingum for advice and help with the RT-PCR test and nucleotide sequencing. V. Misra for help with analysis of the nucleotide sequences, and K. Caspell for preparing the figures.

LITERATURE CITED

- AFSHAR, A., G. C. DULAC, AND A. BOUFFARD. 1989. Application of peroxidase labelled antibody assays for detection of porcine IgG antibodies to hog cholera and bovine viral diarrhea viruses. *Journal of Virological Methods* 23: 253–262.
- ALEXANDER, D. J. 1989. Newcastle disease. In *A laboratory manual for the isolation and identification of avian pathogens*, 3rd ed., H. G. Purchase, L. H. Arp, C. H. Domermuth, and J. E. Pearson (eds.). Kendall/Hunt Publishing Company, Dubuque, Iowa, pp. 114–120.
- . 1997. Newcastle disease and other avian *Paramyxoviridae* infections. In *Diseases of poultry*, 10th Edition, B. W. Calnek, H. J. Barnes, C. W. Beard, L. R. McDougald, and Y. M. Saif (eds.).

- Iowa State University Press, Ames, Iowa, pp. 541–569.
- AL-SHEIKHLY, F. A., AND H. C. CARLSON. 1975. Pathology of velogenic Newcastle disease virus infection in turkeys. *Avian Diseases* 19: 397–407.
- ASDELL, M. K., AND R. P. HANSON. 1960. Sequential changes in the titer of Newcastle disease virus in tissues: A measure of the defense mechanism of the chicken. *American Journal of Veterinary Research* 21: 128–132.
- BANERJEE, M., W. M. REED, S. D. FITZGERALD, AND B. PANIGRAHY. 1994. Neurotropic velogenic Newcastle disease in cormorants in Michigan: pathology and virus characterization. *Avian Diseases* 38: 873–878.
- BARTON, J. T., A. A. BICKFORD, G. L. COOPER, B. R. CHARLTON, AND C. J. CARDONA. 1992. Avian paramyxovirus type 1 infections in racing pigeons in California. I. Clinical signs, pathology, and serology. *Avian Diseases* 36: 463–468.
- BEARD, C. W. 1989. Serologic procedures. In *A laboratory manual for the isolation and identification of avian pathogens*, 3rd Edition, H. G. Purchase, L. H. Arp, C. H. Domermuth and J. E. Pearson (eds.). Kendall/Hunt Publishing Company, Dubuque, Iowa, pp. 192–200.
- BRIGATI, D. J., L. R. BUDGEON, E. R. UNGER, D. KOEBLER, C. CUOMO, T. KENNEDY, AND J. M. PERDOMO. 1988. Immunocytochemistry is automated: development of a robotic workstation based upon the capillary action principle. *Journal of Histotechnology* 11: 165–183.
- BROWN, J., R. S. RESURRECCION, AND T. G. DICKSON. 1990. The relationship between the hemagglutination-inhibition test and the enzyme-linked immunosorbent assay for the detection of antibody to Newcastle disease. *Avian Diseases* 34: 585–587.
- CARTER, G. R., AND J. R. COLE, JR. (EDITORS). 1990. *Diagnostic procedures in veterinary bacteriology and mycology*, 5th Ed., Academic Press, San Diego, California, 620 pp.
- CLEARY, L. 1977. Succès de reproduction du cormoran à aigrettes, *Phalacrocorax auritus auritus*, sur trois îles du St-Laurent, en 1975 et 1976. M.Sc. Thesis, L'Université Laval, Ste-Foy, Quebec, 68 pp.
- COLLINS, M. S., I. STRONG, AND D. J. ALEXANDER. 1996. Pathogenicity and phylogenetic evaluation of the variant Newcastle disease viruses termed "pigeon PMV-1 viruses" based on the nucleotide sequence of the fusion protein gene. *Archives of Virology* 141: 635–647.
- COMMISSION OF THE EUROPEAN COMMUNITIES. 1993. Commission decision of 12 May 1993 laying down the criteria for classifying third countries with regard to avian influenza and Newcastle disease. *Official Journal of the European Communities L* 137: 24–30.
- GUSTAFSON, D. P., AND H. E. MOSES. 1952. Some effects of oral exposure of English sparrows to Newcastle disease virus. *American Journal of Veterinary Research* 13: 566–571.
- HAINES, D. M., AND B. J. CHELACK. 1991. Technical considerations for developing enzyme immunohistochemical staining procedures on formalin-fixed paraffin-embedded tissues for diagnostic pathology. *Journal of Veterinary Diagnostic Investigation* 3: 101–112.
- HARDING, M., C. LUTZE-WALLACE, I. PRUD'HOMME, X. ZHONG, AND J. ROLA. 1994. Reverse transcriptase-PCR assay for detection of hog cholera virus. *Journal of Clinical Microbiology* 32: 2600–2602.
- HECKERT, R. A., M. S. COLLINS, R. J. MANVELL, I. STRONG, J. E. PEARSON, AND D. J. ALEXANDER. 1996. Comparison of Newcastle disease viruses isolated from cormorants in Canada and the USA in 1975, 1990 and 1992. *Canadian Journal of Veterinary Research* 60: 50–54.
- HOWELL, D. C. 1987. *Statistical methods for psychology*, 2nd Edition. Duxbury Press, Boston, Massachusetts, 636 pp.
- JUNGHERR, E. L., E. E. TYZZER, C. A. BRANDLY, AND H. E. MOSES. 1946. The comparative pathology of fowl plague and Newcastle disease. *American Journal of Veterinary Research* 7: 250–288.
- KALETA, E. F., AND C. BALDAUF. 1988. Newcastle disease in free-living and pet birds. In *Newcastle disease*, D. J. Alexander (ed.). Kluwer Academic Publishers, Boston, Massachusetts, pp. 197–246.
- KARZON, D. T., AND F. B. BANG. 1951. The pathogenesis of infection with a virulent (CG 179) and an avirulent (B) strain of Newcastle disease virus in the chicken. I. Comparative rates of viral multiplication. *Journal of Experimental Medicine* 93: 267–283.
- KÖLBL, S. 1978. Untersuchungen über Anwendbarkeit und Aussagekraft der Immunofluoreszenz für die Diagnose der Newcastle-Disease bei Hühnern. *Wiener tierärztliche Monatsschrift* 65: 84–91.
- KUIKEN, T., F. A. LEIGHTON, G. WOBESER, K. L. DANESIK, J. RIVA, AND R. A. HECKERT. 1998. An epidemic of Newcastle disease in double-crested cormorants from Saskatchewan. *Journal of Wildlife Diseases* 34: 457–471.
- LUNA, L. G. (EDITOR). 1968. *Manual of histologic staining methods of the Armed Forces Institute of Pathology*, 3rd Edition, McGraw-Hill, New York, New York, 258 pp.
- METEYER, C. U., D. E. DOCHERTY, L. C. GLASER, J. C. FRANSON, D. A. SENNE, AND R. DUNCAN. 1997. Diagnostic findings in the 1992 epornitic of neurotropic velogenic Newcastle disease in double-crested cormorants from the upper mid-western United States. *Avian Diseases* 41: 171–180.
- RIDDELL, C. 1987. *Avian histopathology*. 1st Edition.

- American Association of Avian Pathologists, Kennett Square, Pennsylvania, 152 pp.
- SEAL, B. S., D. J. KING, AND J. D. BENNETT. 1995. Characterization of Newcastle disease virus isolates by reverse transcription PCR coupled to direct nucleotide sequencing and development of sequence database for pathotype prediction and molecular epidemiological analysis. *Journal of Clinical Microbiology* 33: 2624–2630.
- SWAYNE, D. E. 1996. Nervous system. *In* Avian histopathology, 2nd Edition, C. Riddell (ed.). American Association of Avian Pathologists, Kennett Square, Pennsylvania, pp. 183–201.
- VILLEGAS, P., AND H. G. PURCHASE. 1989. Titration of biological suspensions. *In* A laboratory manual for the isolation and identification of avian pathogens, 3rd Edition, H. G. Purchase, L. H. Arp, C. H. Domermuth and J. E. Pearson (eds.). Kendall/Hunt Publishing Company, Dubuque, Iowa, pp. 186–191.
- WILCZYNSKI, S. P., M. L. COOK, AND J. G. STEVENS. 1977. Newcastle disease as a model for paramyxovirus-induced neurologic syndromes. II. Detailed characterization of the encephalitis. *American Journal of Pathology* 89: 649–662.
- WOBESER, G., F. A. LEIGHTON, R. NORMAN, D. J. MYERS, D. ONDERKA, M. J. PYBUS, J. L. NEUFELD, G. A. FOX, AND D. J. ALEXANDER. 1993. Newcastle disease in wild water birds in western Canada, 1990. *Canadian Veterinary Journal* 34: 353–359.
- ZAR, J. H. 1996. Biostatistical analysis. 3rd Edition. Prentice Hall, Upper Saddle River, New Jersey, 662 pp.

Received for publication 23 March 1998.