

Adiaspiromycosis in a European Beaver from Sweden

Authors: Mörner, Torsten, Avenäs, Anders, and Mattsson, Roland

Source: Journal of Wildlife Diseases, 35(2) : 367-370

Published By: Wildlife Disease Association

URL: <https://doi.org/10.7589/0090-3558-35.2.367>

The BioOne Digital Library (<https://bioone.org/>) provides worldwide distribution for more than 580 journals and eBooks from BioOne's community of over 150 nonprofit societies, research institutions, and university presses in the biological, ecological, and environmental sciences. The BioOne Digital Library encompasses the flagship aggregation BioOne Complete (<https://bioone.org/subscribe>), the BioOne Complete Archive (<https://bioone.org/archive>), and the BioOne eBooks program offerings ESA eBook Collection (<https://bioone.org/esa-ebooks>) and CSIRO Publishing BioSelect Collection (<https://bioone.org/csiro-ebooks>).

Your use of this PDF, the BioOne Digital Library, and all posted and associated content indicates your acceptance of BioOne's Terms of Use, available at www.bioone.org/terms-of-use.

Usage of BioOne Digital Library content is strictly limited to personal, educational, and non-commercial use. Commercial inquiries or rights and permissions requests should be directed to the individual publisher as copyright holder.

BioOne is an innovative nonprofit that sees sustainable scholarly publishing as an inherently collaborative enterprise connecting authors, nonprofit publishers, academic institutions, research libraries, and research funders in the common goal of maximizing access to critical research.

Adiaspiromycosis in a European Beaver from Sweden

Torsten Mörner,^{1,4} Anders Avenäs,² and Roland Mattsson,^{3,1} Department of Wildlife, National Veterinary Institute, P.O. Box 7073, S-750 07 Uppsala, Sweden; ² Hovsgatan 30B, S-871 31 Härnösand, Sweden; ³ Department of Bacteriology, National Veterinary Institute, P.O. Box 7073, S-750 07 Uppsala, Sweden; ⁴ Author to whom reprint requests should be addressed (E-mail: Torsten.Morner@sva.se).

ABSTRACT: An infection with the rare mycosis *Chryso sporium parvum* was diagnosed in a European beaver (*Castor fiber*) shot in northern Sweden. The animal was in normal body condition and no signs of disease were observed. In the lungs a large number of nodules, up to 5 mm diameter, were observed. A large number of adiaspores were observed in the interstitium of the lungs and in the mediastinal lymph node. A chronic inflammatory reaction dominated by mononuclear leukocytes and giant cells was observed around the spores. This is the first report of adiaspiromycosis (*Chryso sporium parvum*) in the European beaver.

Key words: Adiaspiromycosis, case report, *Castor fiber*, *Chryso sporium parvum*, European beaver, mycosis.

The European beaver (*Castor fiber*) is found in most parts of Sweden and the population numbers about 100,000 animals, of which 5,000–10,000 are harvested annually (Swedish Hunters Association, 1991). A 5- to 6-yr-old female beaver weighing 23.4 kg was shot in early May in northern Sweden (62°40'N, 17°45'E). The animal was in normal body condition and showed no sign of disease. When eviscerated several small firm ≤ 5 mm diameter nodules in the lungs were the only macroscopical lesions observed. Lungs, heart and mediastinal lymph node were submitted to the National Veterinary Institute (Uppsala, Sweden) for further examination. Specimens from lung and mediastinal lymph nodes were removed for bacteriological examination and were cultivated on Blood Agar Base No 2 (Difco Manual, Difco Laboratories, Detroit, Michigan, USA) with 5% horse blood and Blue-agar Base with 1% glucose-plates in 37C for 48 hr. No specific mycological examination was performed. No pathogenic bacteria were isolated from lungs or lymph node. Specimens from lungs, heart, and mediastinal lymph node were fixed in 10% buffered,

neutral formalin. After fixation for 24 hr, tissues were embedded in paraffin; sections were cut at 5 μ m and stained with hematoxylin/eosin, PAS, and Grocott stain (Armed Forces Institute of Pathology, 1968) and mounted on glass slides.

Histological examination of the lungs demonstrated a large number of, 100 to 200 μ m large, thick-walled spores surrounded by a chronic granulomatous inflammatory reaction with presence of lymphocytes, macrophages, giant cells and connective tissue (Fig. 1). The spores were positively stained with Grocott stain and were identified as the fungi *Chryso sporium parvum* var. *crecens* (= *Haplo sporangium parvum* and *Emmonsia parva*) (Chandler et al., 1980). Spores also were observed in the mediastinal lymph node with a similar inflammatory reaction as in the lungs (Fig. 2).

Chryso sporium parvum is a fungus found in soil and infections occur worldwide (Dvorak et al., 1965) and have been reported from several mammalian species including representatives from the Rodentia, Carnivora, and Insectivora (Jellison, 1981), Marsupials (Smith and Lancaster, 1965) and in birds (Shaparov, 1975) and amphibians (Hill and Parnell, 1996). Adiaspiromycosis has been reported in several different species of small rodents (Dvorak et al., 1965). The fungi also has been observed previously in animals in Sweden (Jellison et al., 1961) including wood mice (*Apodemus* sp.), voles (*Microtus* sp), water shrews (*Neomys fodiens*) and the European otter (*Lutra lutra*). No significant clinical disease correlated to the fungi was found in the rodents, but emaciation observed in the otter was largely ascribed to the chronic granulomatous of the lungs caused by the spherules. Infec-

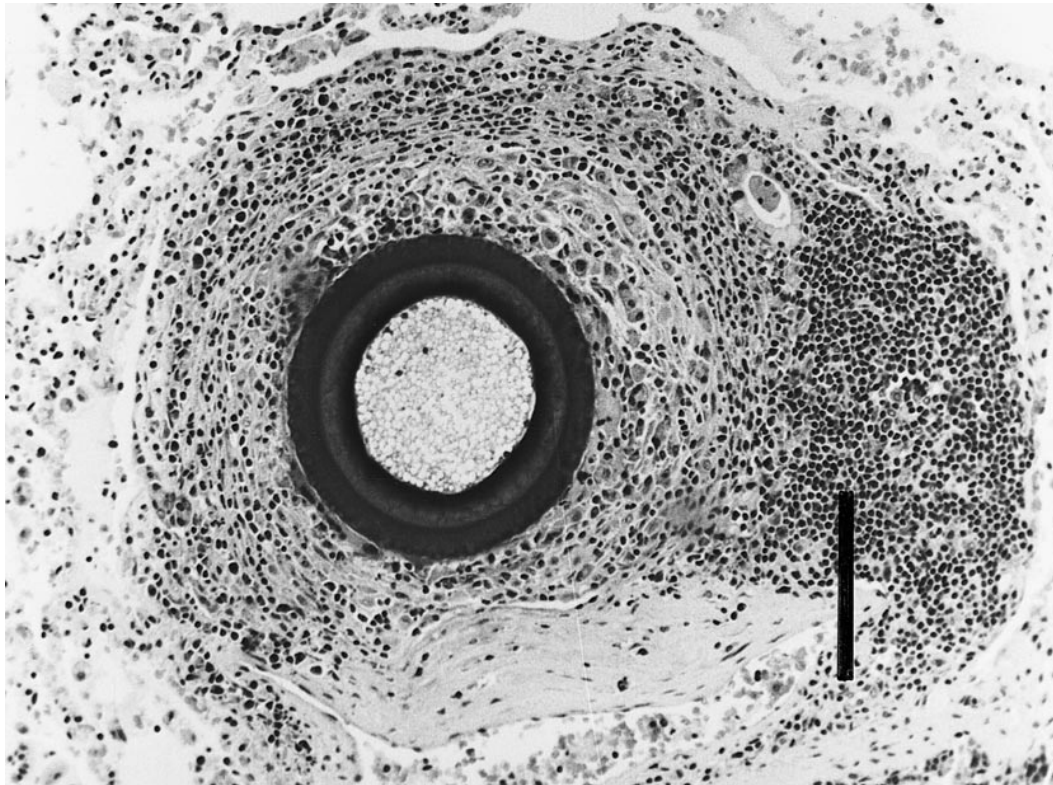


FIGURE 1. Histological section of lung from European beaver with thick-walled spore of *Chrysosporium parvum* surrounded by a chronic granulomatous reaction with presence of lymphocytes, monocytes, giant cells and connective tissue. Grocott stain. Bar = 100 μm .

tions in humans are rare but also have been reported worldwide (Salfelder, 1990).

The portal entry of the infectious spores in humans and animals is through the respiratory tract. The inhaled spores grow in size in the lung tissue without replicating and develop an adiaspore, and the disease is therefore named adiaspiromycosis (Chandler et al., 1980). In most cases the disease will be confined to the lungs since the infectious spores do not multiply in the host tissue, a phenomenon unique for *C. parvum* among pathogenic fungi (Chandler et al., 1980). In the present case, we did observe a single spore in the mediastinal lymph node, with an inflammatory reaction similar to that in the lungs. This finding is similar to some other reports of disseminated adiaspiromycosis to the lymphatic system and other organs, such as

isolation of the spores from pus, sputum and bone marrow in humans (Echavarría et al., 1993) and adiaspores in the tracheobronchial and mediastinal lymph nodes in skunks (*Mephitis mephitis*) (Albassam et al., 1986).

The laboratory diagnosis of adiaspiromycosis may be difficult. Histologically, the spores may at first sight resemble a parasite, but the internal protoplasm is undifferentiated and lacks structures and the spores resemble no other organism. The fungi also can be missed in cultures. The organism grows on most laboratory media at 25 C as a mycelial colony, but does not grow at 37 C (Rippon, 1982). This may explain why we did not isolate any fungi in culture from the beaver tissue.

According to Mörner (1992) the most common cause of death of beavers in Sweden is starvation and drowning. Infectious

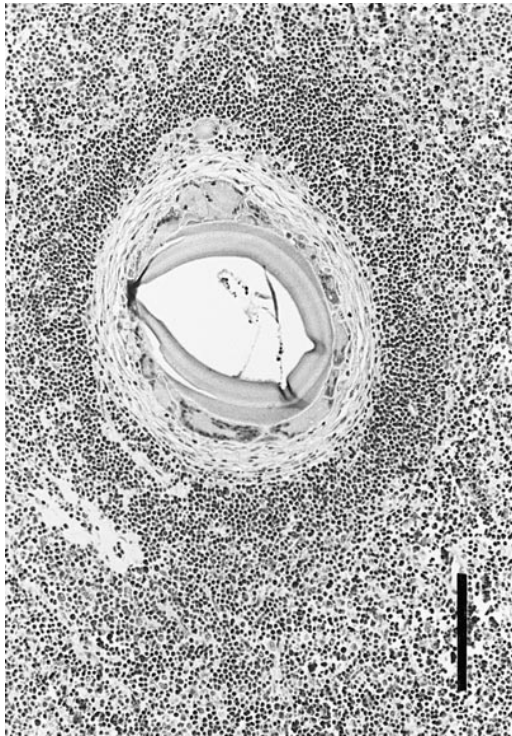


FIGURE 2. Histological section of mediastinal lymph node from European beaver with a adiaspor of *Chryso sporium parvum* surrounded by a chronic granulomatous reaction. H&E stain. Bar = 100 μ m.

disease of different origin was reported in 21% of the animals in this study, but no cases of adiaspiromycosis were diagnosed. Neither was adiaspiromycosis reported in a current review of diseases in the American beaver (*Castor canadensis*) (Addison et al., 1987) but it has previously been reported in this species by Erikson (1949). Infectious diseases such as yersiniosis and leptospirosis were reported to be the main mortality causes of 43 European beavers translocated from Germany to the Netherlands (Nolet et al., 1997) but no cases of adiaspiromycosis was observed. Neither were any macroscopical lesions like adiaspiromycosis were found in 110 beavers collected in Sweden for studies on antibody levels against *Francisella tularensis* (Mörner et al., 1988). The finding of adiaspiromycosis in a European beaver indicates that the fungus is present in the environment and occur sporadically.

LITERATURE CITED

- ADDISON, E. M., I. K. BARKER, AND D. B. HUNTER. 1987. Diseases and parasites of furbearers, In Wild furbearer management and conservation in North America, M. Novak (ed.). Ministry of Natural Resources, Ontario, Canada, pp. 893–909.
- ALBASSAM, M. A., R. BHATNAGAR, L. E. LILLIE, AND L. ROY. 1986. Adiaspiromycosis in striped skunks in Alberta, Canada. *Journal of Wildlife Diseases* 22: 13–18.
- ARMED FORCES INSTITUTE OF PATHOLOGY. 1968. Manual of histologic staining methods of the Armed Forces Institute of Pathology 3rd Edition. L. G. Luna (ed.). The Blakiston Division, McGraw-Hill Book Company, New York, New York, 258 pp.
- CHANDLER F. W., W. KAPLAN, AND L. AJELLO. 1980. Adiaspiromycosis. In *Histopathology of mycotic diseases*. C. B. Carruthers (ed.). Wolfe Medical Publications Ltd., Atlanta, Georgia, pp. 30–32, 141–143.
- DVORAK, J., M. OTCENASEK, AND J. PROPOVIC. 1965. The distribution of adiaspiromycosis. *Journal of Hygiene, Epidemiology, Microbiology and Immunology* 9: 510–514.
- ECHAVARRIA, E., E. L. CANO, AND A. RESTREPO. 1993. Disseminated adiaspiromycosis in a patient with AIDS. *Journal of Medical Veterinary Mycology* 31: 91–97.
- ERICKSON, A. B. 1949. The fungus (*Haplosporangium parvum*) in the lungs of the beaver (*Castor canadensis*). *The Journal of Wildlife Management* 13: 419–420.
- HILL, J. E., AND P. G. PARNELL. 1986. Adiaspiromycosis in bullfrogs (*Rana catesbeiana*). *Journal of Veterinary Diagnostic Investigation* 8: 496–497.
- JELLISON, W. L. 1981. Adiaspiromycosis. In *Infectious diseases of wild mammals*, 2nd Edition, J. W. Davis, L. H. Karstad, and D. O. Trainer (eds.). Iowa State University Press, Ames, Iowa, pp. 366–368.
- , V. VINSON, AND K. BORG. 1961. Adiaspiromycosis (Haplomyces) in Sweden, *Acta Veterinaria Scandinavica* 2: 178–184.
- MÖRNER T., G. SANDSTRÖM, AND R. MATTSON. 1988. Comparison of sera and lung extracts for surveys of wild animals for antibodies against *Francisella tularensis* biovar *palaearctica*. *Journal of Wildlife Diseases* 24: 10–14.
- . 1992. Liv och död bland vilda djur. Sellin & Partner, Stockholm, Sweden, 168 pp. (In Swedish).
- NOLET, B. A., S. BROEKHUIZEN, G. M. DORRENTSTEIN, AND K. M. REINKS. 1997. Infectious diseases as main causes of mortality to beavers *Castor fiber* after translocation to the Netherlands. *Journal of Zoology, London* 241: 35–42.
- RIPPON, J. W. C. 1982. Adiaspiromycosis. In *Medical mycology. The pathogenic fungi and the patho-*

- genic Actinomycetes. W.B. Saunders Co, Philadelphia, Pennsylvania, pp. 645–648.
- SALFELDER, K. 1990. Adiaspiromycosis. In Atlas of fungal pathology. G. A. Greshham (ed.), Kluwer Academic Publishers, London, UK, pp. 160–163.
- SHAPAROV, V. M. 1975. Is possible adiaspiromycosis of birds. Reports Siberian Division of Academy of Science U.S.S.R. Biological Science series 1: 68–71.
- SMITH, J. M. B., AND M. C. LANCASTER. 1965. Adiaspiromycosis in the brush possum (*Trichosurus vulpecula*) in New Zealand. *Sabouraudia* 4: 146–147.
- SWEDISH HUNTERS ASSOCIATION, 1991. Svenska Jägareförbundets årsredogörelse 1989/1990, Swedish Hunters Association, Stockholm, Sweden, 117 pp. (In Swedish).

Received for publication 24 February 1998.