

Naturally Occurring and Experimentally Transmitted *Hepatozoon americanum* in Coyotes from Oklahoma

Authors: Kocan, A. Alan, Cummings, Connie A., Panciera, Roger J., Mathew, J. S., Ewing, S. A., et al.

Source: Journal of Wildlife Diseases, 36(1) : 149-153

Published By: Wildlife Disease Association

URL: <https://doi.org/10.7589/0090-3558-36.1.149>

BioOne Complete (complete.BioOne.org) is a full-text database of 200 subscribed and open-access titles in the biological, ecological, and environmental sciences published by nonprofit societies, associations, museums, institutions, and presses.

Your use of this PDF, the BioOne Complete website, and all posted and associated content indicates your acceptance of BioOne's Terms of Use, available at www.bioone.org/terms-of-use.

Usage of BioOne Complete content is strictly limited to personal, educational, and non - commercial use. Commercial inquiries or rights and permissions requests should be directed to the individual publisher as copyright holder.

BioOne sees sustainable scholarly publishing as an inherently collaborative enterprise connecting authors, nonprofit publishers, academic institutions, research libraries, and research funders in the common goal of maximizing access to critical research.

Naturally Occurring and Experimentally Transmitted *Hepatozoon americanum* in Coyotes from Oklahoma

A. Alan Kocan,^{1,4} Connie A. Cummings,² Roger J. Panciera,² J. S. Mathew,¹ S. A. Ewing,¹ and Robert W. Barker³ ¹Department of Infectious Diseases and Physiology, College of Veterinary Medicine, Oklahoma State University, Stillwater, Oklahoma 74078-2006, USA; ²Department of Anatomy, Pathology and Pharmacology, College of Veterinary Medicine, Oklahoma State University, Stillwater, Oklahoma 74078-2006, USA; ³Department of Entomology and Plant Pathology, Oklahoma State University, Stillwater, Oklahoma 74078-2006, USA; and ⁴Corresponding author (e-mail: aak4453@vms.okstate.edu).

ABSTRACT: Twenty free-ranging coyotes (*Canis latrans*) in Oklahoma (USA) were examined for the presence of naturally occurring infections with *Hepatozoon americanum* and to determine if bone lesions attributable to *H. americanum* were present. Although eight of the 20 free-ranging coyotes were found to be naturally infected with *H. americanum*, no bone lesions were detected. In addition, two coyote pups were exposed to *H. americanum* oocysts collected from experimentally infected ticks and the course of the resulting infection was followed. Both experimentally infected coyotes developed hepatozoonosis detectable by specific muscle lesions beginning 4 wk after exposure. Bone lesions were detected grossly and histologically at necropsy. Histologic evidence of periosteal bone proliferation ranged from segmental areas of plump hypercellularity and thickening of the periosteum, with minor degrees of osteogenesis, to extensive proliferation of woven bone and periosteal hypercellularity and thickening. Nymphal *Amblyomma maculatum* that fed on one of the experimentally infected coyote pups became infected and mature *H. americanum* oocysts were recovered when the ticks molted to adults. These results demonstrate that coyotes in some parts of Oklahoma are naturally infected with *H. americanum*, that experimentally infected coyotes can develop clinical disease, including characteristic bone lesions, and that *A. maculatum* nymphs can acquire infections by feeding on them.

Key words: *Amblyomma maculatum*, *Canis latrans*, Coyote, experimental transmission, Gulf Coast tick, *Hepatozoon americanum*, natural infection.

Hepatozoon americanum (Apicomplexa: Adeleina) is a recently described species and the causative agent of canine hepatozoonosis in the United States (Vincent-Johnson et al., 1997). The presently known distribution of this parasite in domestic dogs in the United States is Alabama, Georgia, Louisiana, Mississippi, Texas and

Oklahoma (Craig et al., 1978; Gaunt et al., 1983; Barton et al., 1985; Gosset et al., 1985; McIntire et al., 1997; Vincent-Johnson et al., 1997; Panciera et al., 1997). The recent finding that *H. americanum* is endemic in free-ranging coyotes (*Canis latrans*) in Oklahoma (USA) (Kocan et al., 1999) extends the known geographic distribution of this organism in wild carnivores (Davis et al., 1978; Mercer et al., 1988). The extent of overt disease in naturally infected free-ranging animals is unknown.

Mathew et al. (1998) have shown that the Gulf Coast tick, *Amblyomma maculatum*, is an excellent vector for *H. americanum*. Nymphs that engorged on a naturally infected dog had *H. americanum* oocysts in their hemocoel as adults. Dogs that were experimentally infected by ingestion of these oocysts developed clinical disease that included elevated body temperature, leukocytosis, myasthenia and bone pain starting 4 to 5 wk after exposure. Altered host cells that sometimes contained demonstrable parasites were observed in skeletal muscle as early as 3 wk after exposure and gamonts were found in peripheral blood leukocytes as early as 5 wk after the dogs consumed oocysts.

The course of infection and the potential for clinically detectable disease to develop in coyotes was assessed by examining 20 free-ranging coyotes and by exposing each of two laboratory-reared coyote pups orally to 100 *H. americanum* oocysts. All coyotes were obtained from the Predator Damage Management Unit (United States Department of Agriculture, Animal Damage Control, Washington D.C., USA).

The free-ranging coyotes were obtained from three locations in central and north-central Oklahoma (35°50'N to 36°50'N, 97°00'W to 98°00'W) during January, 1999. Adult animals were shot as a part of predator damage management and the two pups were captured alive. Those that were shot were, immediately upon death, transported to the Oklahoma Animal Disease Diagnostic Laboratory (Stillwater, Oklahoma, USA) for gross necropsy and histologic evaluation. The left femur of each animal was removed. The bones were cooked in an autoclave for 30 min and the soft-tissue and periosteum manually separated from the bone in order to evaluate the presence of proliferative bone changes.

Eight of 20 free-ranging coyotes were confirmed by histologic examination of muscle to be infected with *H. americanum*. Bone lesions referable to hepatozoonosis were not found in the prepared femurs of any of the 20 coyotes. The femoral condyles of one coyote showed evidence of severe degenerative joint disease, a lesion not associated with canine hepatozoonosis.

The two coyote pups were intact males that were estimated to be 6-wk-old when captured. They were housed in tick-free isolation facilities and cared for in accord with conventional laboratory practices until they were 10-wk-old. Each coyote pup was evaluated for general health and for specific pathogens by routine hematologic determinations (CBC), and serologic examination for *Ehrlichia* spp. In addition, skeletal muscle samples ($0.5 \times 0.5 \times 1.5 \text{ cm}^3$) were obtained under sterile surgical conditions from either the biceps femoris or the triceps brachii. Prior to surgery, coyotes were pre-anesthetized with 50 mg of Xylazine (Bayer Corp., Shawnee Mission, Kansas, USA) and placed under Halothane gas anesthesia. Muscle specimens were fixed in neutral buffered formalin and processed for routine histologic examination.

Prior to exposure, serologic findings and muscle biopsy examination confirmed that

both coyote pups were free of parasitic infection. Hematologic parameters were determined to be within normal limits.

In order to initiate experimental *H. americanum* infections, specific pathogen-free *A. maculatum* nymphs were purchased from the tick rearing facility of the Oklahoma Agricultural Experiment Station and were allowed to feed on a naturally infected domestic dog that was demonstrated to have gamonts in circulating leukocytes. Procedures for acquisition feeding of ticks followed those of Mathew et al. (1998).

Following habituation, each pup was fed 100 oocysts of *H. americanum*. Procedures for recovering oocysts and exposing pups followed those of Mathew et al. (1998). Pups were monitored daily by visual observation and periodically by muscle biopsy and hematologic determinations.

Biopsy and CBC determinations were scheduled so that samples were obtained on a given coyote only once per month. Coyote #2 was maintained for 98 days after exposure and coyote #1 for 123 days.

Both coyote pups developed hepatozoonosis following ingestion of *H. americanum* oocysts. Neutrophilic leukocytosis developed at about 4 wk after exposure and continued throughout the course of infection (Fig. 1). Beginning at about the same time, myasthenia and bone and/or muscle pain (determined by reluctance to move), ocular discharge, and inappetence were observed. These signs also continued throughout the study. Histologic evidence of *H. americanum* infection was detected in muscle biopsies from both animals. Muscle lesions were found in Coyote #1 at 42 days post exposure but were not detected at 22 days. Coyote #2 had lesions in the first post-exposure biopsy, at 56 days.

Coyote #2 was euthanatized 98 days after exposure to oocysts. Gross lesions at necropsy consisted largely of an attendant paleness of many organs and tissues. Additionally, a deep, bleeding ulcer in the pyloric mucosa of the stomach with extensive blood loss into the GI tract was observed

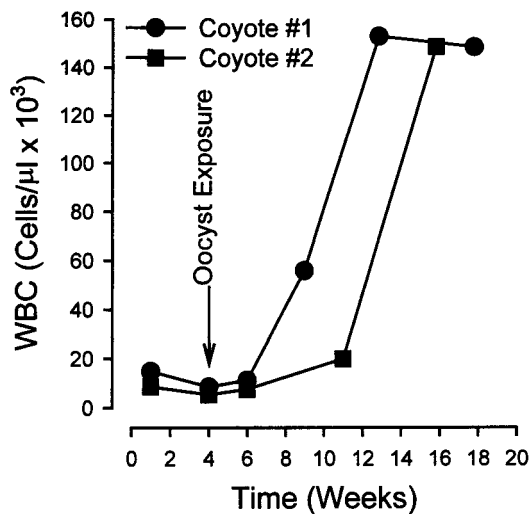


FIGURE 1. White blood cell count (no./microliter) of two coyote pups experimentally infected by ingestion of 100 *Hepatozoon americanum* oocysts. Coyotes #1 & #2 were euthanatized 123 days and 98 days, respectively, after exposure.

but thought to not be associated with canine hepatozoonosis. Examination of prepared bones revealed shallow plaques of periosteal bone proliferation on various bones including humerus, scapula, ilium, femur and tibia. Bone lesions were not observed on the skulls.

Coyote #1 was euthanatized on day 123 post exposure and subjected to necropsy. Major gross findings consisted of varying degrees of periosteal bone deposit on many bones (long bones, flat bones, short bones). There was massive proliferation of periosteal bone that included concentric lamellae of relatively compact bone (pseudocortices) alternating with spicules of cancellous bone, particularly involving humerus and femur (Fig. 2).

Many tissues from the two experimentally infected coyotes were examined histologically. Lesions associated with various asexual stages of *H. americanum*, indistinguishable from those previously reported (Kocan et al., 1999), were present in skeletal and cardiac muscle and in the subcutaneous adipose tissue of each animal.

Histologic evidence of periosteal proliferation ranged from segmental areas of

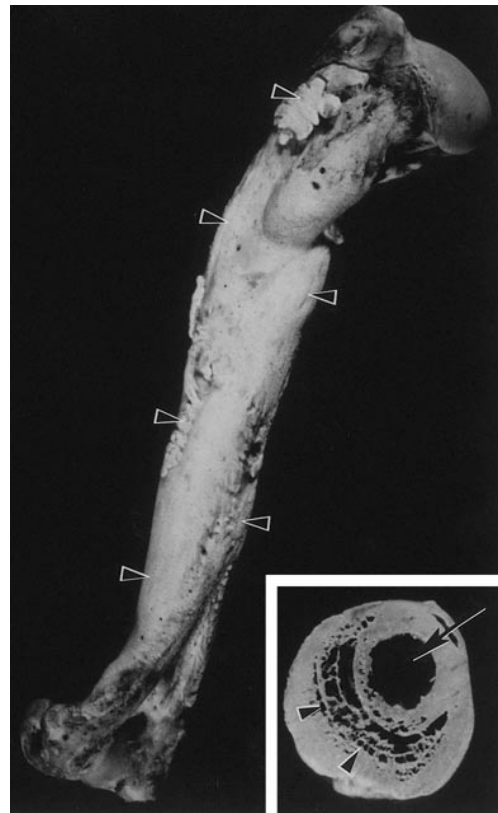


FIGURE 2. Humerus of coyote pup #1: Humeral shaft (diaphysis) greatly expanded by irregular deposition of periosteal new bone (arrow heads). Inset. Transverse section of shaft of humerus. Note original cortex (arrow) and periosteal new bone (arrow heads).

plump hypercellularity and thickening of the periosteum and minor degrees of osteogenesis in coyote #2 to extensive proliferation of woven bone and periosteal hypercellularity and thickening in coyote #1. Marrow elements filled the space between spicules and new bone at the inner zones of new bones.

Gamonts were detected in circulating leukocytes of both pups beginning 6 wk after exposure and continuing throughout the remainder of the study (Fig. 3).

Nymphal *A. maculatum* were acquisition fed on coyote #1 following the procedures described by Mathew et al. (1998). After molting, 40 adult ticks were dissected and the number of oocysts enumerated. Of the ticks dissected (20 male,

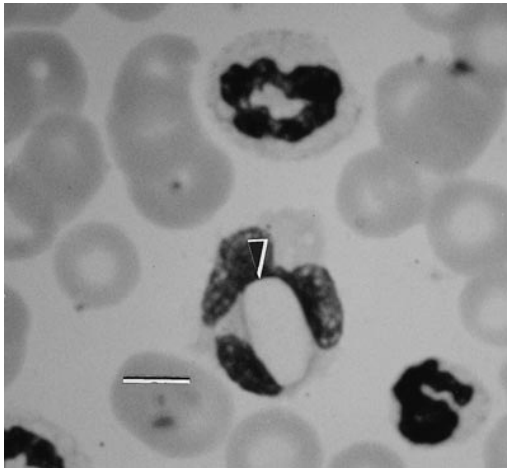


FIGURE 3. *Hepatozoon americanum* gamont (arrow) in circulating leukocyte of experimentally infected coyote pup at 6 wk after exposure. Giemsa. Bar = 5 μ m.

20 female), 80% were infected. The number of oocysts recovered from infected tick ranged from 0 to 8, a number considerably fewer than reported by Mathew et al. (1998) for ticks infected by feeding on domestic dogs.

Observations of the 20 free-ranging coyotes evaluated here and earlier observations of naturally infected coyotes (Davis et al., 1978; Kocan et al., 1999) did not reveal the occurrence of bone lesions nor evidence of *Hepatozoon*-related clinical illness. By comparison, the present study clearly demonstrates that young coyotes are readily susceptible to experimental infection with *H. americanum* and suffer severe disease that is comparable to that produced in experimentally and naturally infected dogs (Panciera et al., 1997; Mathew et al., 1998). Our findings also confirm that the infection in coyotes is potentially fatal. We speculate that the age of the coyote pups used in this study or the number of oocysts used to produce infection may have contributed to the severity of disease that developed. It appears that individual variation undoubtedly exists in the response to infection and as a result, severely affected coyotes may not survive long enough, under natural conditions, for bone

lesions to develop. Whatever the case, the findings of this study show that coyotes are readily susceptible to infection by *H. americanum*, that they may develop severe clinical disease, and that they can serve as a source of infection for *A. maculatum*.

We thank J. Lilley and D. Alley for their assistance in obtaining coyotes and R. Coleman for her assistance in providing biopsy specimens. This research was supported in part by Animal Health Grant no. 1433 and project 3714 of the Agricultural Experiment Station, Oklahoma State University.

LITERATURE CITED

- BARTON, C. L., E. A. RUSSO, T. M. CRAIG, AND R. W. GREEN. 1985. Canine hepatozoonosis: A retrospective study of 15 naturally occurring cases. *Journal of the American Animal Hospital Association* 21: 125–134.
- CRAIG, T. M., J. E. SMALLWOOD, AND K. W. MCGRATH. 1978. *Hepatozoon canis* infection in dogs: Clinical, radiographic, and hematologic findings. *Journal of the American Veterinary Medical Association* 173: 967–972.
- DAVIS, D. S., R. M. ROBINSON, AND T. M. CRAIG. 1978. Naturally occurring hepatozoonosis in a coyote. *Journal of Wildlife Diseases* 14: 244–246.
- GAUNT, P. S., S. D. GAUNT, AND T. M. CRAIG. 1983. Extreme neutrophilic leukocytosis in a dog with hepatozoonosis. *Journal of the American Veterinary Medical Association* 182: 409–410.
- GOSSET, K. A., S. D. GAUNT, AND D. S. AJA. 1985. Hepatozoonosis and ehrlichiosis in a dog. *Journal of the American Animal Hospital Association* 21: 265–267.
- KOCAN, A. A., M. BRESHEARS, C. CUMMINGS, R. J. PANCIERA, S. A. EWING, AND R. W. BARKER. 1999. Naturally occurring hepatozoonosis in coyotes from Oklahoma. *Journal of Wildlife Diseases* 35: 86–89.
- MACINTIRE, D. K., N. VINCENT-JOHNSON, A. R. DILLON, B. BLAGBURN, D. LINDSAY, E. M. WHITLEY, AND C. BANFIELD. 1997. Hepatozoonosis in dogs: 22 cases (1989–1994). *Journal of the American Veterinary Medical Association* 210: 916–922.
- MATHEW, J. S., S. A. EWING, R. J. PANCIERA, AND P. WOODS. 1998. Experimental transmission of *Hepatozoon americanum* Vincent-Johnson et al., 1997 to dogs by the Gulf Coast tick, *Amblyomma maculatum* Koch. *Veterinary Parasitology* 80: 1–14.
- MERCER, S. H., L. P. JONES, J. H. PAPPOLE, D. TWEDT, L. L. LAACK, AND T. M. CRAIG. 1988.

- Hepatozoonosis in wild carnivores in Texas. *Journal of Wildlife Diseases* 24: 574–576.
- PANCIERA, R. J., N. T. GATTO, M. CRYSTAL, R. G. HELMAN, AND R. W. ELY. 1997. Canine hepatozoonosis in Oklahoma. *Journal of the American Animal Hospital Association* 33: 221–225.
- VINCENT-JOHNSON, N. A., D. K. MACINTIRE, D. S. LINDSAY, S. D. LENZ, G. BANETH, V. SHKAP, AND B. L. BLAGBURN. 1997. A new *Hepatozoon* species from dogs: Description of the causative agent of canine hepatozoonosis in North America. *The Journal of Parasitology* 83: 1165–1172.

Received for publication 26 April 1999.