

SCURVY IN CAPYBARAS BRED IN CAPTIVITY IN ARGENTINE

Authors: Cueto, Gerardo Ruben, Allekotte, Roman, and Kravetz, Fernando Osvaldo

Source: Journal of Wildlife Diseases, 36(1) : 97-101

Published By: Wildlife Disease Association

URL: <https://doi.org/10.7589/0090-3558-36.1.97>

BioOne Complete (complete.BioOne.org) is a full-text database of 200 subscribed and open-access titles in the biological, ecological, and environmental sciences published by nonprofit societies, associations, museums, institutions, and presses.

Your use of this PDF, the BioOne Complete website, and all posted and associated content indicates your acceptance of BioOne's Terms of Use, available at www.bioone.org/terms-of-use.

Usage of BioOne Complete content is strictly limited to personal, educational, and non - commercial use. Commercial inquiries or rights and permissions requests should be directed to the individual publisher as copyright holder.

BioOne sees sustainable scholarly publishing as an inherently collaborative enterprise connecting authors, nonprofit publishers, academic institutions, research libraries, and research funders in the common goal of maximizing access to critical research.

SCURVY IN CAPYBARAS BRED IN CAPTIVITY IN ARGENTINE

Gerardo Ruben Cueto,^{1,2} Roman Allekotte,¹ and Fernando Osvaldo Kravetz¹

¹ Departamento de Biología, Facultad de Ciencias Exactas y Naturales, Universidad de Buenos Aires, Ciudad Universitaria, Pab. II, 4º p., (1428), Buenos Aires, Argentina

² Corresponding author (e-mail: gcueto@bg.fcen.uba.ar)

ABSTRACT: In order to determine if the absence of vitamin C in the diet of capybaras (*Hydrochoerus hydrochaeris*) causes scurvy, a group of seven young individuals were fed food pellets without ascorbic acid, while another group of eight individuals received the same food with 1 g of ascorbic acid per animal per day. Animals in the first group developed signs of scurvy-like gingivitis, breaking of the incisors and death of one animal. Clinical signs appeared between 25 and 104 days from the beginning of the trial in all individuals. Growth rates of individuals deprived of vitamin C was considerably less than those observed in the control group. Deficiency of ascorbic acid had a severe effect on reproduction of another population of captive capybaras. We found that the decrease in ascorbic acid content in the diet affected pregnancy, especially during the first stages. The results obtained suggest that it is necessary to supply a suitable quantity of vitamin C in the diet of this species in captivity.

Key words: Ascorbic acid, capybara, experimental study, *Hydrochoerus hydrochaeris*, nutrition, scurvy, reproduction.

INTRODUCTION

In most mammals, glucose is converted to ascorbic acid (vitamin C) by the hepatic enzyme L-gulonolactone oxidase. However, higher primates and cavid, like the guinea pig (*Cavia porcella*) lack this enzyme and thus must receive their vitamin C from an exogenous source. In these species, signs of scurvy (sluggishness, physical discomfort, bleeding gums and noses, loss of teeth, joint weakness, fragile bones, and death) appear when vitamin C is left out of their diet (Barnes et al., 1973; Jones et al., 1973; Odumosu and Wilson, 1973; Kipp et al., 1996). Lack of ascorbic acid also has a negative effect on reproduction, both in males (Chinoy et al., 1986) and females (Clow et al., 1975; Norkus, and Rosso, 1975; Fazleabas et al., 1997).

The capybara is the largest living rodent, weighing as much as 75 kg in Argentina. It is exclusively herbivorous, and feeds in flooded grasslands (Ojasti, 1973; Herrera and Macdonald, 1989); an adult ingests 3 to 4 kg of fresh grass daily (Ojasti, 1973). The gestation period lasts 150 days and the average litter comprises four pups.

We initially observed that in captivity when fresh vegetables in the diet are reduced, capybaras show signs of scurvy similar to those observed in humans and guinea

pigs. There are no reports in the literature of susceptibility of capybaras to scurvy, in spite of its phylogenetic relation to cavid. The present work was aimed at determining if a reduction in the amount of vitamin C supplied in the diet leads to scurvy in captive capybaras, and to assess its effects on their reproductive success. We also included a retrospective study of the clinical signs of vitamin C deficiency recorded in captivity.

MATERIALS AND METHODS

The study was executed between August 1996 and August 1997, at the Módulo Experimental de Cría de Carpinchos located in the Agricultural Experimental Station Delta del Paraná of the National Institute for Agricultural Technology (INTA; Campana, province of Buenos Aires, Argentina; 34°08'S; 58°12'W).

We selected 15 young capybaras born in captivity. These individuals, between 42- to 60-days-old (initial weights varied from 3.35 to 6.75 kg), were selected because they had just begun their maximum growth rate period.

The experiment was divided into three stages. During the first, all capybaras remained together in a closure of 18 × 9 m, divided in two sectors by a wire net. The animals could freely move between both sectors through a door that was permanently opened. They were fed fresh grass and commercial food pellets (Table 1) ad libitum. A vitamin C supplement (L-ascorbic acid, ROVIMIX®, Roche) was added at a rate of 1 g per animal per day, mixed with the com-

TABLE 1. Nutritional analysis of commercial food which capybaras were fed during experimental studies on scurvy in Argentina.

Contents	Quantity
Minimum crude protein	15.0%
Crude fiber	14.0%
Calcium (Ca)	0.8%
Phosphorous (P)	0.7
Total minerals (Co, Cu, Mn, Zn, Fe, I)	7.0%
Moisture	13.0%
Ascorbic acid	<10 ppm

mercial food pellets. This feeding pattern was maintained for 61 days.

On day 62, the deprivation stage began (second stage); the door was permanently closed and the animals were divided randomly into a group of seven and a group of eight. The group of seven individuals (experimental group) was fed the pellets without additional ascorbic acid, while the other group (control group) was fed with the same pellet diet with ascorbic acid supplement. Neither group was fed fresh grass.

The vitamin C deprivation stage lasted 104 days. At the end of this period, an ascorbic acid supplement (1 g per individual per day) was added again to the diet of the experimental group (third stage).

We checked the clinical condition of the animals, and their food consumption daily, and weighed all the individuals in both groups once a week.

In order to evaluate the effect of dietary vitamin C on reproduction of capybaras, we selected 52 reproductive individuals, which were divided into 12 groups, each made up of one male and one to eight females. They were maintained for over 5 mo fed a diet with approximately 10% of ascorbic acid commonly offered to reproductive individuals. Pregnancy was determined by ultrasound (Berger LC 2010), which could detect fetuses beginning at the end of the first one-third of gestation (45–50 days). At the end of the vitamin C deprivation period, we added 300 mg of ascorbic acid per individual per day to the diet, and 3 mo later, the females were again assessed by ultrasound for pregnancy. The beginning of gestation was calculated according to parturition dates.

During 3 yr prior to these experiments the population size in the breeding center increased from 40 to 120 individuals. During this period, the vitamin C content of the diet offered to the capybaras was not controlled, and it varied according to the availability of green

forage, which never exceeded 20% of the diet. We recorded all the clinical signs of scurvy observed in the individuals over this period.

RESULTS

During the vitamin C deprivation stage, all the animals in the experimental group showed signs of scurvy, while animals in the control group remained healthy. Signs of scurvy started between 25 to 104 days after ascorbic acid deprivation. Signs recorded included broken incisor, gingivitis, loss of all upper and lower incisors, and one death. During the vitamin C deprivation stage, the individuals in the control group showed a greater growth rate than the experimental group ($\bar{X} \pm SD = 88.7 \pm 17.9$ g/day and 76.9 ± 18.6 g/day, respectively). The mean feed consumption was 647 ± 151 g/day per animal in the experimental group until the apparition of scurvy signs, while it was 653 ± 138 g/day per animal in the control group. The signs resolved after vitamin C supplement was restored to the diet. In some cases the incisors did not grow parallel at first (V form), but over time incisor growth became normal. The growth rate of individuals in the experimental group increased to 93.3 ± 16.7 g/day whereas the growth rate of control group remained constant.

While adult capybaras were maintained on a diet poor in vitamin C, only one of 40 females completed gestation successfully. Other females did not show signs of pregnancy by ultrasound scans, although mating had been observed. Thirty-one of 40 females (78%) became pregnant and completed gestation when ascorbic acid supplement was restored. In 1998 these females became again pregnant, inclusive during the period absent of reproduction in 1997, as was observed in Figure 1. The number of matings registered decreased with respect to the previous stage of the experiment (from 22 matings/mo to 10.5 matings/mo).

When green forage was scarce and most of the diet was made up of pelleted rations, we observed signs in capybaras that

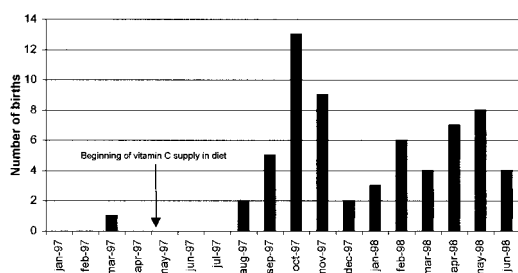


FIGURE 1. Monthly distribution of births of capybaras registered between January 1997 and June 1998. The arrow shows the date of beginning of vitamin C supply in adult capybara diet.

appear to be associated with lack of ascorbic acid in the diet. Clinical signs observed included broken incisors, gingivitis, incisor loss, weakness in all four limbs involving difficulty flexing joint, and a tendency to remain in the water. Joint affections worsened as the animals were forced to move. One individual with affected joints recovered when treated with high doses of vitamin C, but remains unable to stand normally. During five post-mortem examinations we observed lesions in the oral cavity as previously described. Cartilage in some joints in the forelimbs and hind limbs was avulsed with associated bleeding and inflammation. In some cases, joint cartilage was completely detached from the bone. Abortion and fetal mummification were common at different gestational stages. In one female, three different fetal development stages were found in the uterus.

DISCUSSION

Signs of scurvy in individuals deprived of vitamin C and reduction or disappearance of signs when vitamin C was added to the diet shows that capybaras fail to convert glucose into ascorbic acid efficiently. Ascorbic acid is a cofactor of prolinhydroxidase, an essential enzyme in the synthesis of collagen. Vitamin C deficiency prevents synthesis of collagen. This leads to generalized decreased integrity of connective tissue, especially where collagen regeneration is accelerated. The ligaments holding teeth in place have high collagen

turnover, and for that reason they are quickly affected by scurvy as recorded in the capybaras deprived of vitamin C.

The design of the experiment in young capybaras made it possible to rule out infectious disease as the unique cause of the clinical signs observed because the two groups had been kept apart only by means of wire netting, which would have allowed pathogen transmission between them. However, the lack of exogenous vitamin C could facilitate the appearance of certain infections in the individuals of the experimental group.

Guinea pigs deprived of vitamin C show voluntary decreased food consumption which led to weight loss and even death (Barnes et al., 1973; Odumosu and Wilson, 1973; Kipp et al., 1996). Herein, we observed that the growth rate of capybaras, although lower in experimental compared with the control group, was always positive.

We observed a marked effect of vitamin C level on reproduction of captive capybaras. Decreased ascorbic acid in the diet did not affect mating but it severely affected pregnancy rates. The absence of embryos detected by ultrasound scans in females on the deficient diet suggests that either the deprived females did not become pregnant or gestation was interrupted at very early stages, before the embryos were large enough to be detected. Two mechanisms could be influencing decreased reproduction efficiency. Deficient vitamin C levels could affect male fertility. In humans, moderate vitamin C deficiency, even in the absence of clinical signs of scurvy, increases damage caused by oxidation of the genetic material in the sperm cells (Jacob et al., 1991). Chinoy et al. (1986) demonstrated that ascorbic acid is essential for maintaining the physiological integrity of the androgen target reproductive organs in guinea pigs. Dabrowski and Ciereszko (1996) reported that dietary ascorbate levels affected sperm quality and influenced male fertility in a scurvy-prone fish. Alternatively, the level of ascorbic

acid in blood may affect the reproductive capacity of females. Tarín and Trounson (1993) reported that ascorbic acid significantly increases embryo implantation in rodents. The fundamental role of the different collagen types in the implantation, migration, growth, and cell differentiation of embryos has been discussed in rodents (Sherman et al., 1980; Uehara and Yajima, 1987; Carson et al., 1988; Clark et al., 1992, 1993) and primates (Fazleabas et al., 1997).

Under natural conditions, the inability to synthesize ascorbic acid would not affect the survival of capybaras because their diet is exclusively herbivorous. However, their requirement for exogenous vitamin C might affect their reproductive success under certain environmental conditions in which green forage availability is reduced.

We concluded that capybaras require an external supply of ascorbic acid in order to survive and that the level of vitamin C in the diet strongly affects their reproductive success in captivity. These results are important for design of diets for this species in captivity. Capybara could be used as a model for the study of scurvy and collagen synthesis.

ACKNOWLEDGMENTS

We thank to M. Alvarez, J. and J. Taborda, R. Aranda and A. Lozano for field assistance. We thank to K. Hodara, O. Suárez and D. Bilenca for helpful comments and critical review of the manuscript. This study was supported by the Consejo Nacional de Investigaciones Científicas y Tecnológicas (CONICET Argentina).

LITERATURE CITED

- BARNES, M. J., B. J. CONSTABLE, S. G. IMPEY, AND E. KODICEK. 1973. Mortality rate in male and female guinea-pigs on a scorbutogenic diet. *Nature* 242: 522–523.
- CARSON, D. D., J. P. TANG, AND S. GAY. 1988. Collagens support embryo attachment and outgrowth in vitro: Effects of the Arg-Gly-Asp sequence. *Developmental Biology* 127: 368–375.
- CHINYOY, N. J., R. R. MEHTA, L. SEETHALAKSHMI, J. D. SHARMA, AND M. R. CHINYOY. 1986. Effects of vitamin C deficiency on physiology of male reproductive organs of guinea pigs. *International Journal of Fertility* 31: 232–239.
- CLARK, D. E., P. R. HURST, D. B. MYERS, AND G. F. SPEARS. 1992. Collagen concentrations in dissected tissue compartments of rat uterus on days 6, 7 and 8 of pregnancy. *Journal of Reproduction and Fertility* 94: 169–175.
- , ———, I. S. MCLENNAN, AND D. B. MYERS. 1993. Immunolocalization of collagen type I and laminin in the uterus on days 5 to 8 of embryo implantation in the rat. *Anatomical Records* 237: 8–20.
- CLOW, C. L., C. LABERGE, AND C. R. SCRIVER. 1975. Neonatal hypertyrosinemia and evidence for deficiency of ascorbic acid in arctic and subarctic peoples. *Canadian Medical Association Journal* 113: 624–626.
- DABROWSKI, K., AND A. CIERESZKO. 1996. Ascorbic acid protects against male infertility in a teleost fish. *Experientia* 52: 97–100.
- FAZLEABAS, A. T., S. C. BELL, S. FLEMING, J. SUN, AND B. A. LESSEY. 1997. Distribution of integrins and the extracellular matrix proteins in the baboon endometrium during the menstrual cycle and early pregnancy. *Biology of Reproduction* 56: 348–356.
- HERRERA, E. A., AND D. W. MACDONALD. 1989. Resource utilization and territoriality in group-living capybaras (*Hydrochoerus hydrochaeris*). *Journal of Animal Ecology* 58: 667–679.
- JACOB, R. A., D. S. KELLEY, F. S. PIANALTO, M. E. SWENDSEID, S. M. HENNING, J. Z. ZHANG, B. N. AMES, C. G. FRAGA, AND J. H. PETERS. 1991. Immunocompetence and oxidant defense during ascorbate depletion of healthy men. *American Journal of Clinical Nutrition* 54: 1302–1309.
- JONES, P. R., R. J. HURLEY, AND R. E. HUGHES. 1973. Dietary cholesterol, sex and scurvy in guinea-pigs. *Nature* 242: 521–522.
- KIPP, D. E., M. MCELVAIN, D. B. KIMMEL, M. P. AKHTER, R. G. ROBINSON, AND B. P. LUKERT. 1996. Scurvy results in decreased collagen synthesis and bone density in the guinea pig animal model. *Bone* 18: 281–288.
- NORKUS, E. P., AND P. ROSSO. 1975. Changes in ascorbic acid metabolism of the offspring following high maternal intake of this vitamin in the pregnant guinea pig. *Annals of the New York Academy of Sciences* 30: 401–409.
- ODUMOSU, A., AND C. W. WILSON. 1973. Metabolic availability of vitamin C in the guinea pig. *Nature* 242: 519–521.
- OJASTI, J. 1973. Estudio biológico del chiquire o capibara. Editorial Sucre. Caracas, Venezuela, 275 pp.
- SHERMAN, M. I., R. GAY, S. GAY, AND E. J. MILLER. 1980. Association of collagen with preimplantation and peri-implantation mouse embryos. *Developmental Biology* 74: 470–478.

- TARÍN, J. J., AND A. O. TROUNSON. 1993. Effects of stimulation or inhibition of lipid peroxidation on freezing-thawing of mouse embryos. *Biology of Reproduction* 49: 1362–1368.
- UEHARA, S., AND A. YAJIMA. 1987. Morphology of mouse embryo cultured in a newly established culture system using collagen gel layer. *Tohoku Journal of Experimental Medicine* 153: 245–248.
- WINER, B. J. 1971. *Statistical principals in experimental design*. McGraw-Hill Press, New York, New York, 897 pp.

Received for publication 22 July 1998.