

EPIZOOTIC VESICULAR DISEASE IN CAPTIVE CALIFORNIA SEA LIONS

Authors: Van Bonn, William, Jensen, Eric D., House, Carol, House, James A., Burrage, Thomas, et al.

Source: Journal of Wildlife Diseases, 36(3) : 500-507

Published By: Wildlife Disease Association

URL: <https://doi.org/10.7589/0090-3558-36.3.500>

BioOne Complete (complete.BioOne.org) is a full-text database of 200 subscribed and open-access titles in the biological, ecological, and environmental sciences published by nonprofit societies, associations, museums, institutions, and presses.

Your use of this PDF, the BioOne Complete website, and all posted and associated content indicates your acceptance of BioOne's Terms of Use, available at www.bioone.org/terms-of-use.

Usage of BioOne Complete content is strictly limited to personal, educational, and non - commercial use. Commercial inquiries or rights and permissions requests should be directed to the individual publisher as copyright holder.

BioOne sees sustainable scholarly publishing as an inherently collaborative enterprise connecting authors, nonprofit publishers, academic institutions, research libraries, and research funders in the common goal of maximizing access to critical research.

EPIZOOTIC VESICULAR DISEASE IN CAPTIVE CALIFORNIA SEA LIONS

William Van Bonn,^{1,3} Eric D. Jensen,¹ Carol House,² James A. House,² Thomas Burrage,² and Douglas A. Gregg²

¹ Upstream Associates, P.O. Box 60680, San Diego, California 92166, USA

² United States Department of Agriculture, Animal and Plant Health Inspection Service, Foreign Animal Disease Diagnostic Laboratory, Plum Island, New York 11957, USA

³ Corresponding Author (e-mail: vanbonn@spawar.navy.mil)

ABSTRACT: An epizootic of vesicular disease occurred in a group of semi-domesticated California sea lions (*Zalophus californianus*) during the months of April and May 1997. Ten castrated mature male sea lions, ages 12 to 19 yr, were housed in three adjacent open-ocean net enclosures in San Diego Bay (California, USA). Four animals (40%) developed oral and extremity vesicles, anorexia, and were reluctant to perform learned behaviors. One animal developed vesicles but maintained a normal appetite and behavior. The remaining animals showed no clinical signs of infection. Virus (designated FADDL 7005) was isolated from four of the five animals that developed vesicles. Serum antibody titers to FADDL 7005, a previously untyped calicivirus, were demonstrated in animals that showed any combination of clinical signs and in two animals that did not show any clinical signs. No virus was isolated from five fecal samples collected from four of the group animals. Clinical signs lasted 4 to 20 days in affected animals. All affected animals recovered from infection. An experimental swine was inoculated with FADDL 7005 and developed vesicular disease, which was transmitted to another experimental swine upon contact. It is proposed that FADDL 7005 is a new San Miguel sea lion virus.

Key words: Calicivirus, epizootic, sea lion, San Miguel sea lion virus, vesicular disease, *Zalophus californianus*.

INTRODUCTION

Calicivirus infection was first reported in California sea lions (*Zalophus californianus*) in 1972. The virus, designated San Miguel Sea Lion Virus (SMSV), was the first isolated from a pinniped species and has been shown to be indistinguishable from the causative agent of vesicular exanthema of swine (VES) (Smith et al., 1973; Sawyer, 1976). Vesicular exanthema of swine has not been reported in the United States since 1956 and was declared eradicated in that species in 1959 (Smith and Akers, 1976). At least 34 serotypes of calicivirus have been determined to be of ocean origin (Smith and Boyt, 1990). The potential relationship of caliciviruses of marine origin to VES virus, and the potential interspecies transmission of caliciviruses, have been the subject of much investigation and speculation (Prato et al., 1974; Smith et al., 1978, 1983, 1998; Smith and Boyt, 1990).

There are few reports of the natural course of calicivirus infection in pinnipeds.

Gage et al. (1990) described the case history of a California sea lion that developed vesicular lesions, from which a calicivirus was isolated. They also described 31 other sea lions presenting to The Marine Mammal Center (Sausalito, California, USA) with vesicular lesions during an epizootic of leptospirosis in 1984. They reported 32/239 (13%) of California sea lions presenting that year with vesicular lesions suggestive of calicivirus infection. More recent estimates of the prevalence of these lesions in pinnipeds at that facility are three to four times higher (F. M. Gulland, pers. comm.). In contrast, vesicular lesions of pinnipeds presenting as stranded animals to Sea World® of California (San Diego, California, USA) are rare (T. Reidarson, pers. comm.).

This report describes the clinical signs of infection with and the isolation of a serotype of calicivirus, designated FADDL 7005, in a group of semi-domesticated California sea lions housed in San Diego bay. The experimental transmission of the isolate to swine and resulting disease, in-



FIGURE 1. Clinical appearance of California sea lion with unerupted oral vesicle on tongue (arrow).

distinguishable from vesicular exanthema of swine, is also described.

MATERIALS AND METHODS

Clinical procedures

Ten castrated mature male California sea lions (*Zalophus californianus*), ages 12 to 19 yr, were housed in three adjacent open-ocean net enclosures in San Diego Bay (32°42.3'N, 117°14.2'W). All animals were employed in the U.S. Navy Marine Mammal Program (San Diego, California, USA) as open-ocean deep-sea recovery animals and routinely worked at various locations along the southern California coast outward to San Clemente Island (32°58.8'N, 118°32.3'W). The animals were fed daily rations of various fish species from worldwide sources including sardines (*Sardinops sagax caerulea*), mackerel (*Scomber japonicus* or *Pneumatophorus diego*), and squid (*Illex* sp.) from southern California fisheries.

On 8 April 1997 one of the group animals, NIC, was brought to the attention of the veterinary staff with the complaint of poor appetite and reluctance to perform learned behaviors. The following day an erupted vesicle was noted on the sea lion's tongue and calicivirus infection was suspected. Whole blood and serum samples were collected with the animal restrained in a squeeze cage. Amoxicillin (SmithKline Beecham Pharmaceuticals, Philadelphia, Pennsylvania, USA) at 15 mg/kg and clindamycin (The Upjohn Company, Kalamazoo, Michigan, USA) at 12 mg/kg orally, twice daily, were prescribed. On 12 April this animal subsequently developed multiple vesicles of the hard palate and dorsal surface of the tongue, which were causing obvious discomfort (Figs. 1, 2). The animal stayed out of the water with mouth open and refused all fish offered. Topi-



FIGURE 2. Clinical appearance of California sea lion with erupted oral vesicles on hard palate (arrow).

cal application of local anesthetic spray (Cetylite Industries, Inc. Pennsauken, New Jersey, USA) did not improve its condition.

The sea lion was restrained in a squeeze cage, masked down with Isoflurane (Ohmeda Caribe, Inc. Liberty Corner, New Jersey, USA), and the largest oral vesicle (~3.5 cm²) aspirated with a 22 gauge needle. The vesicular fluid and a biopsy of the overlying epithelial tissue collected with iris scissors were transferred immediately to viral transport medium (Multi-Microbe Medium [M4] Micro Test Inc, Liburn, Georgia USA) and stored at approximately 5°C. The samples were shipped the following day on cold packs to the Foreign Animal Disease Diagnostic Laboratory (FADDL, Plum Island, New York, USA) for virus isolation attempts. Whole blood, serum, and fecal samples were also collected. The animal recovered uneventfully, was returned to the group enclosure, and was eating well the following day. On 17, 18, 22, and 24 April, additional vesicles developed on the superior hairless surfaces of this animal's flippers and each was aspirated with a 21 gauge butterfly catheter (Becton Dickinson Vascular Access, Sandy, Utah, USA). The vesicular fluid was transferred immediately to viral transport

media and submitted to FADDL. Several erupted vesicles were also swabbed with sterile dacron swabs, the swab immediately transferred to viral transport media and submitted to FADDL. The animal's appetite remained normal after 12 April and it was returned to work. Antibiotics were discontinued on 21 April. All vesicular lesions were completely healed by 29 April.

Four additional group animals developed vesicular lesions and three of these were also anorexic. On 14 and 16 April, respectively, ZAC, LIB, and DUK had poor appetites. In each case, vesicles developed one to fourteen days following onset of poor appetite and vesicular fluid was collected opportunistically. In two of these cases, LIB and DUK, confirmed oral lesions preceded flipper lesions. Oral lesions were also suspected in ZAC on 21 April but could not be confirmed, as the animal would not open its mouth on command. A single animal, NOR, developed vesicles, first noted on 21 April, but did not show other clinical signs of disease. The remaining five animals in the group showed no clinical evidence of infection.

Between 12 April and 25 June 1997, a total of 44 serum samples, five fecal samples, nine vesicular aspirates, five vesicular swabs, and four tissue samples were collected from the group, using techniques described above.

Virus isolation (VI)

Vesicular fluid samples were placed directly onto Vero cell (ATCC CRL 1587) culture monolayers in 25 cm² flasks (Costar, Cambridge, Massachusetts, USA) and IBRS-2 cell (DeCastro, 1964) culture monolayers in 16 × 125 mm size roller tubes (Corning Glass Works, Corning, New York, USA) and incubated for 1 hr at 37°C. Eagles minimum essential media with nonessential amino acids (EMEM-NEAA) (Bio Whittaker, Walkersville, Maryland, USA) containing 23 mcg/ml gentamicin (Sigma-Adrich, Irvine, Kansas, USA) and ten percent fetal bovine serum (FBS) (NVSL, Ames, Iowa, USA) was added to each vessel and the vessels were incubated at 37°C for seven days. The monolayers were examined daily for cytopathogenic effects (CPE). Cultures that did not exhibit CPE were frozen, thawed, and 1 ml of the cell-media slurry was inoculated into a second cell culture flask or tube, which was incubated and observed for an additional seven days. A third passage was made in an identical manner. Cultures exhibiting CPE were examined by the methods described below. Tissue samples were finely minced as a ten percent suspension in EMEM-NEAA supplemented to contain 30 mcg gentamicin/ml (EMEM-AB),

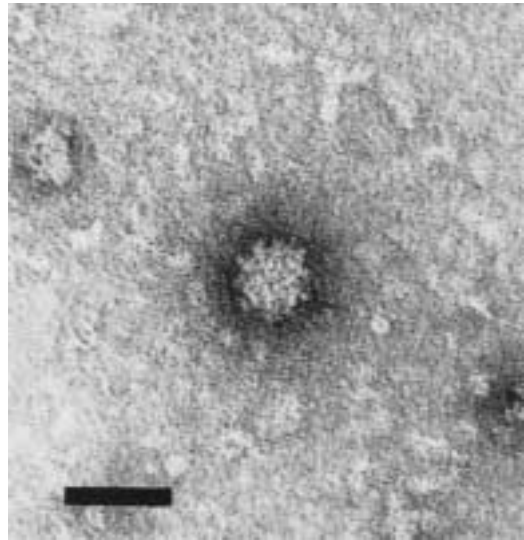


FIGURE 3. Transmission electron micrograph of calcivirus particle in vesicular fluid. Bar = 50 nm.

and centrifuged at 200 × *g* for 5 min. One ml supernatant was inoculated onto Vero and IBRS-2 monolayers, and the cultures were treated as described for vesicular fluid samples. The transportation medium from each fecal swab was centrifuged at 200 × *g* for 5 min, and one ml supernatant placed onto Vero and IBRS-2 monolayers. After 1 hr at 37°C, the inoculum was decanted, and the monolayer rinsed with 3 ml EMEM-AB, to decrease contamination with fecal bacteria. The EMEM-AB supplemented with ten percent FBS was added to each culture, and the cultures were incubated and treated as described for vesicular fluid samples.

Electron microscopy

Vesicular fluid samples and the supernatants of cell cultures exhibiting CPE were prepared for negative stain electron microscopy by floating formvar grids on a drop of the fluid for 30 minutes. The grids were blotted and transferred to a drop of 4% phosphotungstic acid, pH 7.2, for 10 min. After blotting and drying for 30 min, the grids were examined for the presence of viral-like particles in a Zeiss EM 10 electron microscope. Tentative identification of the genus of the virus was made by measurements of morphological features (Fig. 3).

Virus identification

Electron micrographs were used to tentatively identify the virus genus in samples and cell culture isolates. Virus neutralization by spe-

cific reference antisera (Reagents and Vaccine Section, FADDL, Greenport New York, USA) diluted to contain 20 antibody units_{50%} was used to identify the serotype of all cell culture isolates.

Serological tests

Antibodies to the caliciviruses SMSV1, 2, 4–13, vesicular exanthema of swine viruses 1934B, A48, B4, C52, D53, E54, F55, G55, H54, I55, J56, K54, bovine calicivirus Tillamook, and the new isolate FADDL 7005, were assayed in a virus neutralization test (VN) (O'Hara et al., 1998), using 100 to 400 tissue culture infective doses_{50%} (TCID₅₀) of each calicivirus in 25 μ l EMEM-NEAA and 3 days incubation. Antibodies to bovine respiratory syncytial virus (BRSV) were assayed in a similar test using 100 to 400 TCID₅₀ BRSV in 25 μ l EMEM-NEAA, embryonic bovine lung cells (NVSL, Ames, Iowa, USA) and 3 days incubation. Antibodies to influenza viruses were assayed by the agar gel immunodiffusion test (NVSL, Ames, Iowa, USA).

Production of rabbit antiserum

Vero cell culture isolate, passage two, was treated with chloroform to remove potential contamination (Gwaltney et al., 1989). Virus was propagated on Vero cells using serum-free medium. Virus in the third and fourth Vero cell passage, in serum-free medium, was used as antigen for rabbit immunization. Ten 150 cm² culture flasks (Corning Costar Corp., Cambridge, Massachusetts, USA) were inoculated with each virus passage and harvested 20 hr after inoculation, when CPE was complete. Cultures were frozen and thawed, clarified for 20 min at 2,000 \times *g* using a Beckman J6B centrifuge (Beckman Instruments, Palo Alto, California, USA). The suspension was filtered through a 0.45 μ nitrocellulose filter (Nalge Co., Rochester, New York, USA). In each of four tubes, 30 ml of viral suspension was pelleted through 5 ml of a 45% sucrose solution in 0.01 M trihydroxymethylaminomethane (TRIS) and 0.15 M sodium chloride cushion for 1 hr at 300,000 \times *g* using a fixed angle 60 TI rotor with a Beckman L8-70M ultracentrifuge (Beckman Instruments, Palo Alto, California, USA). The viral pellets were dissolved in 10 ml of Eagles minimum essential medium (Biowhittaker Inc. Walkersville, Maryland, USA) overnight at 4C on a rocker (Caframa Ltd. Warton, Ontario, Canada). The viral suspensions were pooled for rabbit inoculation. For the initial inoculation viral suspension was mixed with an equal volume of Freund's complete adjuvant (Difco Laboratories, Detroit,

Michigan, USA) and 0.5 ml was administered in three sites IM, 0.2 ml in three sites SC and 1.2 ml was administered IP. Rabbits were prebled and then test-bled 5 wk after the first inoculation (2 ml) by the marginal ear vein. The rabbits were hyperimmunized 6 wk after the original inoculation by inoculating 0.5 ml of the viral suspension IV. The rabbits were bled by cannulating the middle ear artery 2 wk after hyperimmunization. Three wk after hyperimmunization, they were exsanguinated by cardiac puncture under general anesthesia induced by the IM injection of 1.5 ml Ketaset (Fort Dodge Laboratories, Inc, Fort Dodge, Iowa, USA) and 0.25 ml Xylazine (Fermenta Animal Health Co., Kansas City, Missouri, USA). Rabbits were euthanized by the IM injection of 6 ml of FATAL Plus (Vortech Pharmaceuticals Ltd., Dearborn, Michigan, USA). The antiserum was titrated for neutralizing antibody to FADDL 7005 as described above, and used in the VN test at a dilution containing 20 antibody units_{50%} to identify the serotype of the virus isolates. The antisera was also used in the VN test with known caliciviruses and found to be unreactive.

Indirect fluorescent antibody staining

A mouse monoclonal antibody designated as 14F7E6 that is specific for a group reactive epitope in all of the known vesicular exanthema of swine (VES) and San Miguel sea lion viruses (SMSVs) was obtained from the FADDL repository. The antibody was used at a working dilution of 1:80 in a standard indirect fluorescent antibody test system. Briefly, VES A48 and FADDL 7005 were used in tenfold dilutions to infect Vero cells in 8-chambered cell culture slides to obtain about 30 infected cells/field under 100 \times magnification. The VES A48 served as the positive control and uninfected wells served as the negative control. A polyvalent anti-mouse IgG, IgA and IgM fluorescent antibody (Sigma, St. Louis, Missouri, USA) was used to detect mouse immunoglobulin.

Swine inoculation studies

Adult healthy swine were housed in biocontainment level 3+ animal facilities at FADDL and were observed daily. Animals were anesthetized for inoculation, examination, photographing for lesions and collection of tissues by IM injection of 3 mg/kg Telazol (Fort Dodge Lab, Inc, Fort Dodge, Iowa, USA), 8 mg/kg Ketamine (ASCO, Fort Dodge, Iowa USA) and 4 mg/kg Xylazine (Fermenta Animal Healthco, Kansas City, Missouri, USA). Animal #21 was bled and then inoculated intradermally in the snout and right front foot with 0.5 ml Vero cell

TABLE 1. Calicivirus isolation, calicivirus serology, and clinical signs in California sea lions during an epizootic of vesicular disease in California.

1997 Date	Sea lion				
	NIC	ZAC	LIB	DUK	NOR ^a
April 8	S ^b				
9	S				
10	S				
11	S				
12	S Ci+ ^c Cs- ^d				
13	S				
14	S	S	S		
15	S	S	S		
16	S	S	S Ci+	S	
17	S		S	S	
18	S Ci- ^e Cs+ ^f	Cs-	S Ci+ Cs-	Cs-	
19	S	S	S	S	
20	S		S		
21	S		S		S Ci+
22	S Ci- Cs+		S Ci+	S Ci-	S Ci-
23	S		S		
24	S	Cs+	S Ci+ Cs+	Cs+	S Ci+
25	S		S	S Ci+	
26	S		S		
27	S				
28	S	S		S	
May 5				Cs+	
9		Cs+			
21	Cs+	Cs+	Cs+	Cs+	
June 4		Cs+			
25	Cs+		Cs+	Cs+	

^a Blood samples were not available from NOR during epizootic.

^b S = presence of vesicles, poor appetite or reluctance to perform learned behaviors.

^c Ci+ = Isolation of calicivirus in tissue culture.

^d Cs- = Negative calicivirus neutralization titer.

^e Ci- = No virus isolated in tissue culture.

^f Cs+ = Positive calicivirus neutralization titer.

culture passage two of FADDL 7005. A second animal (#22) was bled for serology and introduced into the room on two days post inoculation (dpi). A third pig (#25) was bled for serology and introduced into the room on 6 dpi. Additional blood was drawn for serology from animal #25 on 7 dpi, 14 dpi, 21 dpi, and 27 dpi.

RESULTS

Sea lion clinical cases

The results of calicivirus serology, virus isolations, and observed clinical signs in the affected sea lions are presented as Table 1. All animals were negative for antibodies to BRSV, influenza viruses, and all caliciviruses except FADDL 7005. Clinical signs lasted 4 to 20 days in affected animals. Four of them, NIC, ZAC, LIB,

DUK, developed oral and extremity vesicles, anorexia, and were reluctant to perform learned behaviors. One animal, NOR, developed vesicles but maintained a normal appetite and behavior. Serum samples from sea lions exhibiting any combination of clinical signs had serum neutralizing antibody titers to FADDL 7005 (Table 2). The maximum recorded titer was $\geq 1:3,600$ seen in the index case. Blood samples were not available from NOR during the outbreak. Titers decreased after clinical recovery. Two sea lions that did not develop clinical signs, GRE and NEW, had measurable titers to FADDL 7005 of 1:290 and 1:110 respectively. All remaining animals had no measurable titer against

TABLE 2. Calicivirus FADDL 7005 serum neutralizing antibody titers in California sea lions during an epizootic of vesicular disease in California.

1997 Date	Sea lion				
	NIC ^a	ZAC	LIB	DUK	RAM ^b
April 18	1:2,900	Neg ^c	Neg	Neg	ND ^d
22	108>1:3,600	ND	ND	ND	ND
24	ND	1:2,300	1:2,300	1:450	1:1,150
May 5	ND	ND	ND	1:1,150	ND
9	ND	1:140	ND	ND	ND
21	1:720	1:71	1:720	1:720	1:1,000
June 4	ND	1:57	ND	ND	ND
25	1:230	ND	1:910	1:570	1:230

^a Index case.

^b Did not develop clinical signs.

^c Neg = Not measurable.

^d ND = No data.

FADDL 7005. Virus FADDL 7005 was isolated from four of the five animals that developed vesicles. Virus was not isolated from any of five fecal samples collected from animals showing clinical signs.

Swine inoculation and transmission studies

A summary of virus isolations and the presence or absence of lesions or fever (rectal temperature of $\geq 40^{\circ}\text{C}$ or greater) in

TABLE 3. Calicivirus isolation, vesicles, and fever of two swine exposed to swine #21 inoculated with FADDL 7005.

Dpi	#21	#22	#25 ^a
0			
1			
2	F ^b V ^c	IE ^d	
3	F V Ci ⁺ e	F V Ci+	
4	F V	F V	
5	F V Ci+	F V	
6	V	F V	IE
7	V	F V	
8		F V Ci+	
9		F V	
10		F V	
11		F V	
12		F V	
13		F V	
14		F V	

^a Swine #25 did not develop fever or vesicles.

^b F = Rectal temperature $\geq 40^{\circ}\text{C}$.

^c V = Vesicles present.

^d IE = Day of initial exposure.

^e Ci+ = Calicivirus isolated in tissue culture.

experimental swine is presented in Table 3. The inoculated animal, #21, developed vesicular disease by the afternoon of 2 dpi (Figs. 4, 5). Animal #22 was exposed to animal #21 at that time and developed vesicular disease on 1 days post exposure (dpe). The third animal, #25, was introduced on 6 dpi and remained clinically normal. All animals (#21, #22, and #25) were negative for neutralizing antibody to FADDL 7005 on 0 dpi or 0 dpe. Animal #21 quickly developed a high titer of 1:5,750 at 7 dpi, which remained fairly stable throughout the study, with titers of 1:4,550, 1:7,250, and 1:9,100 on 14, 21, and

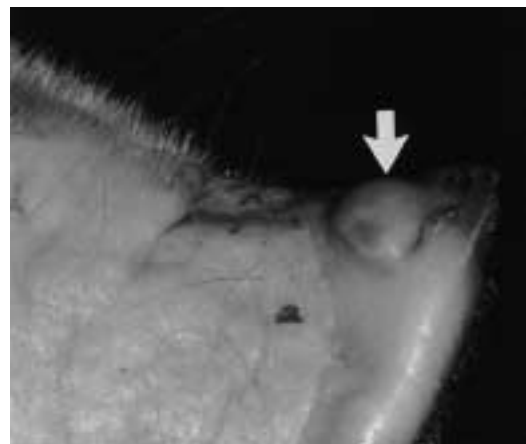

FIGURE 4. Typical lesions of snout in experimental swine infected with calicivirus FADDL 7005 (arrow).

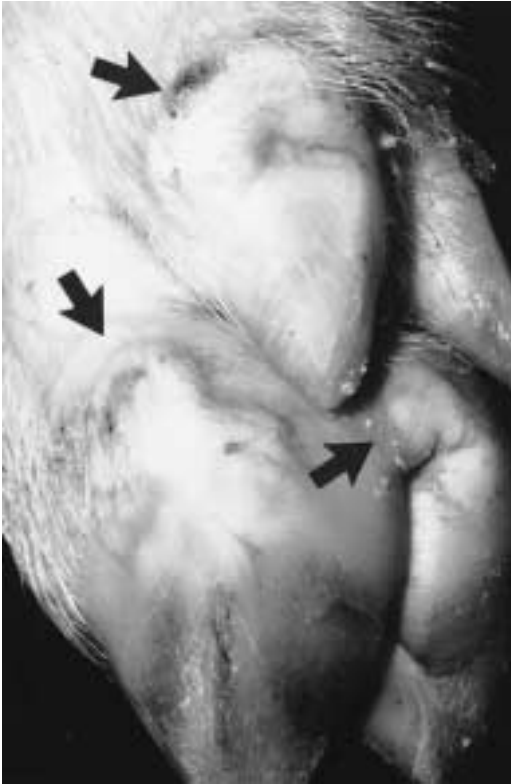


FIGURE 5. Typical lesions of foot in experimental swine infected with calicivirus FADDL 7005 (arrows).

27 dpi respectively. Animal #22 responded more slowly, with titers of 1:570, 1:5,750 and 1:910 on 6, 14, and 25 dpe respectively. Animal #25 developed a low titer over the course of the study, with titers of 1:71, 1:360, and 1:230 on 7, 14, and 20 dpe.

Indirect fluorescent antibody study

Specific staining, typical of the group reactive epitope of calicivirus seen with the monoclonal antibody 14F7E6, was observed with VES A48 and FADDL 7005. Uninfected cell cultures showed no staining.

DISCUSSION

The California sea lions in this group were infected with a previously uncharacterized calicivirus, FADDL 7005. The source of the calicivirus infection in this

group of animals was not determined. It is possible that local wild sea lions exposed the group to the calicivirus. Wild sea lions are occasionally observed near the enclosures or approach the animals while working at sea. We observed vesicular lesions on a wild yearling male California sea lion that stranded at our facility in March 1997. A swab of vesicular fluid from this animal was submitted to FADDL and was negative on virus isolation attempts. However, the swab had been stored for a prolonged time at room temperature prior to submission. It also is interesting that vesicular lesions are rare in sea lions presenting as stranded animals to the nearby San Diego Sea World® facility (T. Reidarson, pers. comm.). A marine calicivirus has been isolated from the teleost fish (*Girella nigricans*) (Smith et al., 1998), but antiserum to the fish virus was not able to be obtained for purposes of comparing it to FADDL 7005. The opaleye and other fish species have been postulated as a source for pinniped infection (Smith and Akers, 1976, and Smith et al., 1998). *Girella nigricans* is not included in the diets of our working animals, but other southern California species are eaten by our animals. To date we have not attempted virus isolation from any species of our food fishes.

We note the development of oral vesicles as the primary lesion in this epizootic. This is in contrast to the clinical description provided by Gage et al. (1990) where lesions primarily involved the flippers. It is possible, however, that oral lesions had resolved in stranded animals by the time of presentation to a treatment facility.

The results of our swine inoculation and transmission studies clearly demonstrate that FADDL 7005, isolated from California sea lions in southern California, is infectious for swine and causes a vesicular syndrome indistinguishable from vesicular exanthema of swine.

ACKNOWLEDGMENTS

We gratefully acknowledge S. H. Ridgway and T. A. Romano for manuscript review. A.

Smith kindly donated the SMSVs and the bovine calicivirus Tillamook for serological testing. We wish to thank M. Todd and M. Xitco for assistance in preparation of the figures and C. E. Lomax for data collection.

LITERATURE CITED

- DECASTRO, M. P. 1964. Behavior of foot and mouth disease virus in cell culture: susceptibility of the IB-RS-2 swine cell line. *Arquivos Instituto Biologica* 31: 63–78.
- GAGE, L. J., L. AMAYA-SHERMAN, J. ROLETTO, AND S. BENTLY. 1990. Clinical signs of San Miguel sea lion virus in debilitated California sea lions. *Journal of Zoo and Wildlife Medicine*. 21: 79–83.
- GWALTNEY, J. M., R. J. COLONNO, V. V. HAMPARIAN, AND R. B. TURNER. 1989. Rhinoviruses. *In* Diagnostic procedures for viral, rickettsial and chlamydial infections, 6th Edition, N. J. Schmidt and R. Emmons (eds.). American Public Health Association, Inc., Washington, D.C., pp. 579–614.
- O'HARA, T. M., C. HOUSE, J. A. HOUSE, R. S. SUYDAM, AND J. C. GEORGE. 1998. Viral serologic survey of bowhead whale in Alaska. *Journal of Wildlife Diseases* 34: 39–46.
- PRATO, C. M., T. G. AKERS, AND A. W. SMITH. 1974. Serological evidence of calicivirus transmission between marine and terrestrial mammals. *Nature* 249: 255–256.
- SAWER, J. G. 1976. Vesicular exanthema of swine and San Miguel sea lion virus. *Journal of the American Veterinary Medical Association* 169: 707–709.
- SMITH, A. W., T. G. AKERS, S. H. MADIN, AND N. A. VEDROS. 1973. San Miguel sea lion virus isolation, preliminary characterization and relationship to vesicular exanthema of swine virus. *Nature* 244: 108–110.
- , AND T. G. AKERS. 1976. Vesicular exanthema of swine. *Journal of the American Veterinary Medical Association* 169: 700–703.
- , T. G. AKERS, C. M. PRATO, AND H. BRAY. 1976. Prevalence and distribution of four serotypes of SMSV serum neutralizing antibodies in wild animal populations. *Journal of Wildlife Diseases* 12: 326–334.
- , C. PRATO, AND D. E. SKILLING. 1978. Caliciviruses infecting monkeys and possibly man. *The American Journal of Veterinary Research* 39: 287–289.
- , D. E. SKILLING, AND S. RIDGWAY. 1983. Calicivirus induced vesicular disease in cetaceans and probable interspecies transmission. *Journal of The American Veterinary Medical Association* 183: 1223–1225.
- , AND P. M. BOYT. 1990. Caliciviruses of ocean origin: A review. *Journal of Zoo and Wildlife Medicine* 21: 3–23.
- , D. E. SKILLING, N. CHERRY, J. H. MEAD, AND D. O. MATSON. 1998. Calicivirus emergence from ocean reservoirs: Zoonotic and interspecies movements. *Emerging Infectious Diseases* 4: 13–20.

Received for publication 26 October 1998.