



Sarcoma of Possible Nerve Sheath Origin in a Captive Muskrat

Authors: Borucinska, J. D., Trettel, J., and Knibbs, D.

Source: Journal of Wildlife Diseases, 36(3) : 570-575

Published By: Wildlife Disease Association

URL: <https://doi.org/10.7589/0090-3558-36.3.570>

BioOne Complete (complete.BioOne.org) is a full-text database of 200 subscribed and open-access titles in the biological, ecological, and environmental sciences published by nonprofit societies, associations, museums, institutions, and presses.

Your use of this PDF, the BioOne Complete website, and all posted and associated content indicates your acceptance of BioOne's Terms of Use, available at www.bioone.org/terms-of-use.

Usage of BioOne Complete content is strictly limited to personal, educational, and non - commercial use. Commercial inquiries or rights and permissions requests should be directed to the individual publisher as copyright holder.

BioOne sees sustainable scholarly publishing as an inherently collaborative enterprise connecting authors, nonprofit publishers, academic institutions, research libraries, and research funders in the common goal of maximizing access to critical research.

Sarcoma of Possible Nerve Sheath Origin in a Captive Muskrat

J. D. Borucinska,^{1,3} J. Trettel,¹ and D. Knibbs^{2,1} Department of Biology, University of Hartford, West Hartford, Connecticut, USA; ² Hartford Hospital, Hartford, Connecticut, USA; ³ Corresponding author (email: borucinsk@mail.hartford.edu).

ABSTRACT: A captive adult female muskrat (*Ondatra zibethicus*) was found dead without previous signs of disease. At necropsy, abdominal organs were infiltrated with a poorly demarcated, soft, tan tissue. Microscopically this tissue was composed of neoplastic cells assuming two distinct growth characteristics consistent with Antoni A and B patterns. Ultrastructurally, the neoplastic cells were pleomorphic, lacked junctional devices, had abundant mitochondria and ergastoplasm, and frequently were closely associated with extracellular collagen. Immunocytochemical examination of tumor cells demonstrated sporadic expression of neuron specific enolase. Microscopic tumor metastases to the myocardium, ascending aorta, lungs and visceral pleura were present. This is the first report of a sarcoma compatible with a malignant peripheral nerve sheath tumor in a muskrat.

Key words: Case report, malignant peripheral nerve sheath tumor, muskrat, neurogenic sarcoma, *Ondatra zibethicus*.

In April 1996 an adult wild-captured, female muskrat from a breeding colony at the University of Connecticut (Storrs, Connecticut, USA; 41°48'N, 72°15'W) was found dead. The animal did not show previous signs of illness. At necropsy the peritoneal cavity contained soft, tan, lobulated, poorly demarcated tissue that diffusely involved the broad ligament of the uterus, the ovarian ligaments and the ovaries, most of the mesentery and omenta, serosa of the large and small intestines, pancreas, spleen, liver, and abdominal surface of the diaphragm. Hemorrhage and necrosis were common within this tissue.

Samples from the involved organs and the brain, lungs, heart, kidneys and adrenals were fixed in 10% neutral buffered formalin, embedded in paraffin, sectioned at 5 μ m, and stained with hematoxylin and eosin (H&E). Selected sections were in addition stained with trichrome and PAS (all staining procedures were as in Sheehan and Hrapchak, 1980). For immuno-

cytochemical examination formalin fixed, paraffin embedded sections were deparaffinized, treated with a target unmasking fluid (TUF, Signet Laboratories Inc., Dedham, Massachusetts, USA) and processed using commercially available primary and secondary antibodies (OmniTags Plus, Immunon, Pittsburgh, Pennsylvania, USA) according to the manufacturer's directions. The following primary antibodies (Immunon) were used: monoclonal antibodies raised against muscle specific actin (mouse IgG, a and c isotypes); vimentin (mouse IgG); pancytokeratin monoclonal pool (mouse IgG); and polyclonal antibodies against S-100 protein (rabbit IgG, α and β subunits), desmin (rabbit IgG 1), factor VIII (rabbit IgG), and neuron specific enolase, NSE (rabbit IgG). Secondary antibodies (Immunon) were either antirabbit or antimouse conjugated to a streptavidin-peroxidase complex and developed with 3-amino-9-ethylcarbazole (AEC) as chromogen. For negative controls the primary antibodies were replaced with the appropriate normal serum. Tissue sections supplied by Immunon known to express the relevant antigens served as positive controls. In addition tissue sections from the muskrat with the tumor served as positive internal controls that allowed to assess the cross-reactivity of muskrat antigens with the antigens used by Immunon to obtain the primary antibodies. For ultrastructural examination previously formalin fixed tissues were post-fixed in 2% osmium tetroxide, dehydrated through graded ethanol and embedded in epoxy resin. Ultrathin sections were stained with Sato's lead and uranyl acetate (Hayat, 1970), and examined on a Zeiss EM 10C electron microscope (LEO Electron Microscopy, Thornwood, New York, USA).

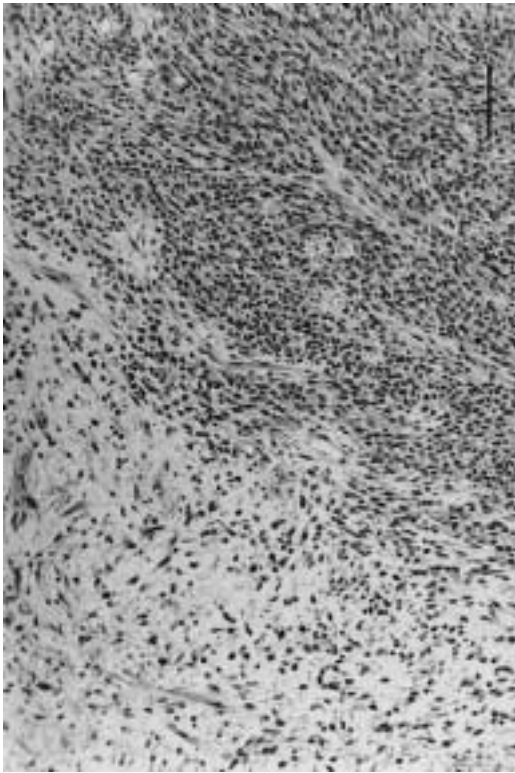


FIGURE 1. Ovary of a muskrat with a malignant peripheral nerve sheath-compatible tumor composed of well defined Antoni A and Antoni B areas. H&E. Bar = 100 μ m.

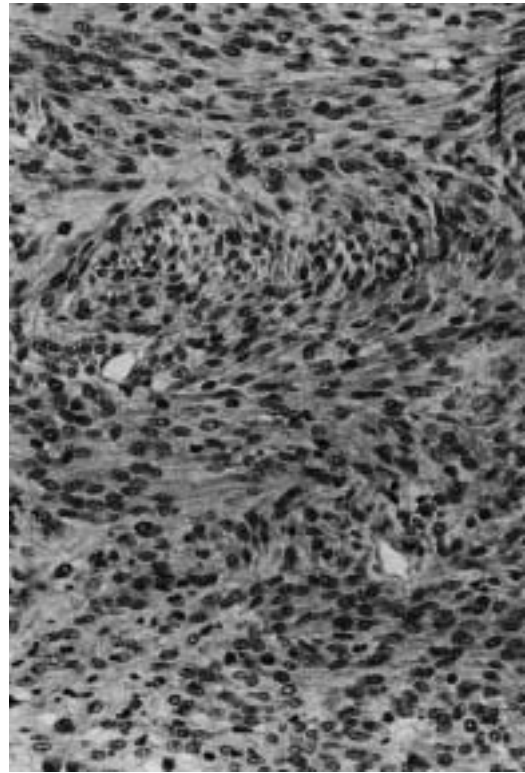


FIGURE 2. Pancreas with parenchyma replaced by tumor cells growing in Antoni A pattern with densely packed spindle cells in interwoven fascicles. H&E. Bar = 50 μ m.

Histologically, the lobulated masses infiltrating the abdominal organs were formed by neoplastic tissue with two distinct morphological patterns (Fig. 1). The first had storiform or fascicular arrangements of tightly packed, spindle-shaped cells (Fig. 2), or areas formed by polygonal epithelioid cells arranged either into a pseudoglandular fashion around blood-filled spaces or in densely packed alveolar nests (Fig. 3). The spindle cells had pale eosinophilic cytoplasm that merged imperceptibly with sparse adjacent collagen fibers, and elongated, infrequently wavy nuclei with tapered ends; the epithelioid cells had a centrally located round to oval nucleus and abundant basophilic to amphophilic cytoplasm. Necrosis and hemorrhage were frequent as were mitotic figures which ranged from 0 to 8 per high

power field. The second pattern within the tumor had sparse stellate, fusiform, or epithelioid cells growing irregularly in abundant to moderate fibromyxoid stroma (Figs. 1, 4). Close association of the tumor with a peripheral nerve was found within the diaphragm (Fig. 5).

Trichrome staining revealed scant to moderate collagen among tumor cells. The densely cellular areas contained fragmented and irregular PAS positive basement membranes (BM)-like material whereas minimal to no PAS positivity was detected in the less cellular regions. The ultrastructural features of the tumor cells were not well preserved due to the fact of formalin fixation and paraffin embedding prior to processing for transmission electron microscopy (TEM). Poorly differentiated cells had ultrastructural features of fibro-

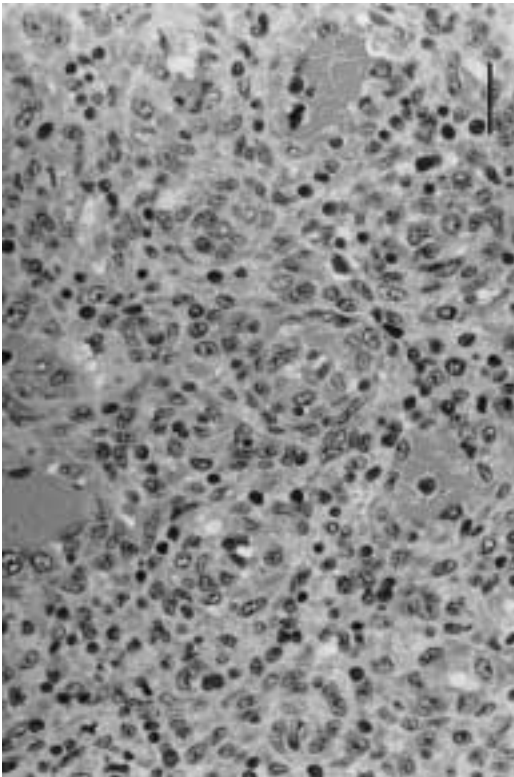


FIGURE 3. Diaphragm infiltrated by tumor composed of polygonal epithelioid cells arranged in alveolar nests and perivascular rosettes. H&E. Bar = 75 μ m.

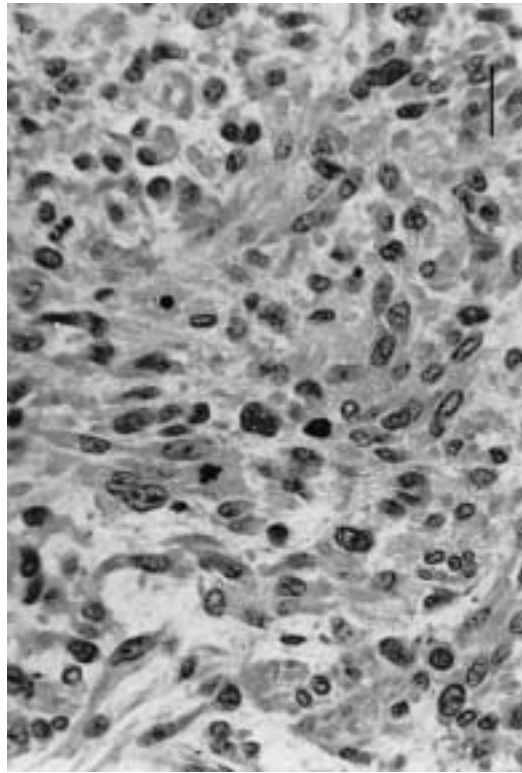


FIGURE 4. Ovary with tumor cells arranged in a Antoni B pattern. The pleomorphic cells have numerous mitotic figures and grow within a moderate fibromyxoid stroma. H&E. Bar = 25 μ m.

blasts with prominent ergastoplasm and mitochondria, and numerous cell processes. The cells were frequently associated with abundant stromal collagen (Fig. 6). The cell membranes were fragmented which precluded the identification of interdigitating cellular processes, basement membranes and cell junctions which are features of schwann and perineurial cells, respectively. Accordingly, the TEM images were supportive of a poorly differentiated tumor composed of fibroblast compatible cells, but were not useful in detection of schwann and perineurial cells.

Immunocytochemical examination demonstrated that sporadic spindle cells and some epithelioid cells had fine granular cytoplasmic staining for NSE. The same reactivity was present in single ganglion-like cells found in the fibromyxoid stroma. No

detectable staining for muscle specific actin, vimentin, desmin, S-100 protein, factor VIII, and pankeratin was detected in the tumor. On the internal positive control slides with normal muskrat tissues positive reactivity to muscle specific actin and desmin was found in the intestinal muscularis and vascular media, and positive reactivity to factor VIII was present within endothelia. Fibroblasts within organ capsules stained positively with vimentin, positive reactivity to S-100 and NSE was present within myenteric ganglion cells and peripheral nerves, and renal and intestinal epithelia reacted with the pankeratin antibody. Thus the lack of reactivity of the tumor cells with the above antibodies was not due to the lack of crossreactivity.

Microscopic tumor metastases were found in the myocardium, ascending aorta,

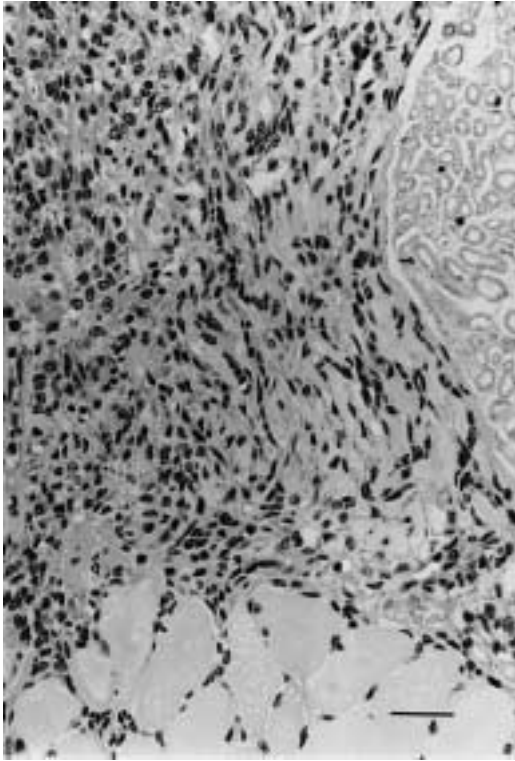


FIGURE 5. Diaphragm infiltrated by tumor cells closely associated with epineurium. Note the numerous mitoses within the tumor. H&E. Bar = 50 μ m.

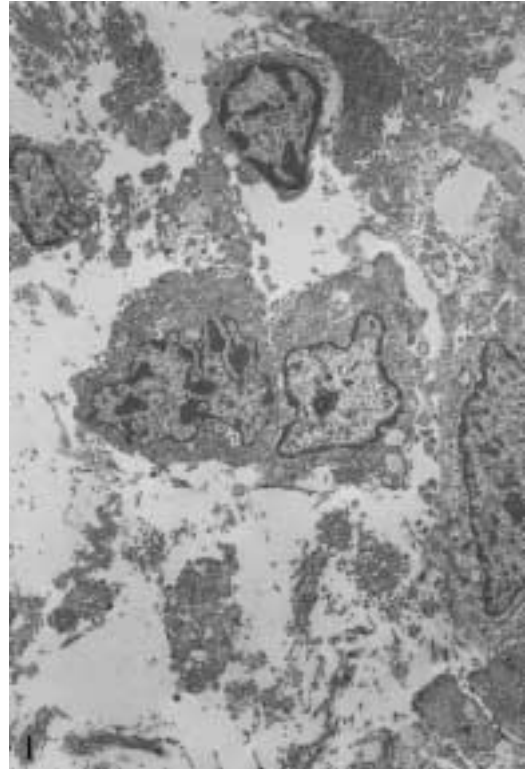


FIGURE 6. Poorly differentiated tumor cells with ultrastructural features of fibroblasts. There are numerous cell processes and abundant collagen. Sato's lead and uranyl acetate. Bar = 1 μ m.

lungs and visceral pleura. The microscopic features of the tumor and the close association with a peripheral nerve suggest a malignant mesenchymal tumor possibly of nerve sheath origin, but other anaplastic mesenchymal tumors including fibrosarcoma can not be excluded. Paraffin embedded tissues of this tumor have been deposited in the Registry of Veterinary Pathology (Armed Forces Institute of Pathology, Washington, D.C., USA).

Malignant peripheral nerve sheath tumors (MPNST) are poorly defined sarcomas that demonstrate a mixture of florid histologic patterns which leads to difficulty in their diagnosis (Matsunou et al., 1985). Since almost all the histologic patterns expressed in MPNST also are seen in other soft tissue tumors, ultrastructural or immunocytochemical studies are needed for accurate diagnosis of MPNST (Swanson et al., 1996). Using the above methods it has

been established, that all cellular elements of the peripheral nerve sheath, i.e., schwann cells, perineurial cells and fibroblasts, can be found within these tumors (Hirose et al., 1992). This explains their heterologous differentiation including glandular and epithelioid MPNST, rhabdomyoblastic (triton) tumors, malignant granular cells tumors, and neurotropic/desmoplastic melanomas (Sanguenza and Requena, 1998; Woodruff and Christensen, 1993).

Immunohistochemical analyses of human and animal MPNST have shown variable expression of vimentin, S-100 protein, NSE, neurofilament, myelin basic protein, glial fibrillary acidic protein (GFAP), epithelial membrane antigen (EMA), and cytokeratins (Matsunou et al., 1985; Gough et al., 1986; Cardesa et al.,

1990; Hirose et al., 1992) confirming the complex histogenesis of MPNST. Accordingly, although S-100 protein is considered one of the most useful markers for neuroectodermal tumors including schwannian cell derived neoplasms, its expression within the latter seems to depend on tumor location and the degree of differentiation (Matsunou et al., 1985; Cardesa et al., 1990). A large proportion of MPNST lacks the S-100 expression, which seems to correlate with a high degree of anaplasia (Matsunou et al., 1985) or perineurial or fibroblastic differentiation (Swanson et al., 1996). The lack of S-100 reactivity in the tumor of this report was most likely caused by predominantly fibroblastic differentiation. Neuron specific enolase is a constituent of proliferating schwann cells (Swanson et al., 1996) and its expression has been found in fusiform, epithelioid, and large ganglion-like cells in MPNST (Matsunou et al., 1985), acoustic schwannomas in humans (Swanson et al., 1996), and in cells from Antoni B pattern in a mediastinal tumor from a laboratory rat (Cardesa et al., 1990). It is noteworthy that all the above immunocytochemical markers are not tissue specific and can be found in tumors derived from mesenchymal, epithelial and muscle tissues. Thus, we find the scattered immunoreactivity with NSE in our tumor to be only supportive of a diagnosis of a nerve sheath derived tumor.

Peripheral nerve sheath (PNS) tumors include schwannomas, neurofibromas and their malignant counterpart the MPNST. In humans, neurofibromas and MPNST are most often associated with von Recklinghausen's disease (neurofibromatosis type I) while schwannomas can be associated with neurofibromatosis type II, where bilateral acoustic nerve involvement is pathognomonic (Hajdu, 1993; Swanson et al., 1996). In animals, the preferred term for PNS tumors is benign or malignant schwannoma (Kirchhof et al., 1996). The benign are most commonly associated with solitary cranial or spinal nerve roots in cattle and dogs, or with bovine neurofibro-

matosis. Malignant PNS tumors have been reported in domestic animals, but with the exception of a recent report of a MPNST in a water moccasin (*Agkistrodon piscivorus*), (Ramis et al., 1998) we are not aware of its description from wild animals including muskrats. In other microtine rodents including laboratory rats spontaneous neoplasms of the peripheral nervous system are very rare (Bernischke et al., 1978; Abbott, 1982; Gough et al., 1986) although they constitute common tumors induced experimentally with polycyclic aromatic hydrocarbons (PAHs), ethyl and methyl nitrosurea, DNA-adenovirus SA7, and radiation. (Gough et al., 1986; Cardesa et al., 1990). It is an interesting speculation if the muskrat developed the tumor described herein due to environmental exposure to PAHs, which are ubiquitous anthropogenic contaminants.

We acknowledge R. Cartun, W. Ernst, S. Gemme, and I. Jackman for their technical assistance. Funding for this project was provided in part by a grant from the Connecticut Space Grant College Consortium (no. 204490).

LITERATURE CITED

- ABBOTT, D. P. 1982. Malignant schwannoma of the dorsal spinal nerve root in a laboratory rat. *Laboratory Animals* 16: 265-266.
- BERNISCHKE, K., F. M. GARNER, AND T. C. JONES. 1978. *Pathology of laboratory animals*, Vol. 2. Springer Verlag, New York, New York, 1242 pp.
- CARDESA, A., T. RIBALTA, K. T. VOGLEY, G. REIFENBERGER, W. WECHSLER, AND V. S. TURUSOV. 1990. Tumors of the peripheral nervous system. *In Pathology of tumors in laboratory animals*, Vol. 99, V. S. Turusov (ed.). International Agency for Research on Cancer Scientific Publications, Lyon, France, pp. 699-724.
- GOUGH, A. W., W. HANNA, N. J. BARSOUM, J. MOORE, AND J. M. STURGESS. 1986. Morphologic and immunohistochemical features of two spontaneous peripheral nerve tumors in Wistar rats. *Veterinary Pathology* 23: 68-73.
- HAJDU, S. I. 1993. Peripheral nerve sheath tumors: Histogenesis, classification, and prognosis. *Cancer* 72: 3549-3552.
- HAYAT, M. A. 1970. *Techniques and principles of electron microscopy, biological applications*, Vol. 1. Van Nostrand Reinhold Co., New York, New York, 412 pp.

- HIROSE, T., T. HASEGAWA, E. KUDO, K. SEKI, T. SANO, AND K. HIZAWA. 1992. Malignant peripheral nerve sheath tumors: An immunohistochemical study in relation to ultrastructural features. *Human Pathology* 23: 865–870.
- KIRCHOF, N., W. SCHEDEMANN, AND W. BAUMGÄRTNER. 1996. Multiple peripheral nerve sheath tumors in the small intestine of a horse. *Veterinary Pathology* 33: 727–730.
- MATSUNOU, H., T. SHIMODA, S. KAKIMOTO, H. YAMASHITA, E. ISHIKAWA, AND M. MUKAI. 1985. Histopathologic and immunohistochemical study of malignant tumors of peripheral nerve sheath (malignant schwannoma). *Cancer* 56: 2269–2279.
- RAMIS, A., M. PUMAROLA, J. FERNANDEZ-MORAN, S. ANOR, N. MAJO, AND A. ZIDAN. 1998. Malignant peripheral nerve sheath tumor in a water moccasin (*Agkistrodon piscivorus*). *Journal of Veterinary Diagnostic Investigation* 10: 205–208.
- SANGUEZA, O. P., AND L. REQUENA. 1998. Neoplasms with neural differentiation: A review. Part II: Malignant neoplasms. *American Journal of Dermatopathology* 20: 89–102.
- SHEEHAN, D. Z., AND B. B. HRAPCHAK. 1980. Theory and practice of histotechnology. Bettelle Press, Columbus, Ohio, 157 pp.
- SWANSON, P. E., B. W. SCHEITHAUER, AND M. R. WICK. 1996. Peripheral nerve sheath neoplasms: Clinicopathologic and immunochemical observations. *Pathology Annual* 30: 1–82.
- WOODRUFF, J. M., AND W. N. CHRISTENSEN. 1993. Glandular peripheral nerve sheath tumors. A study of eleven cases and a review of the literature. *Cancer* 72: 3618–3628.

Received for publication 29 January 1999.