

SALT TOXICOSIS IN RUDDY DUCKS THAT WINTER ON AN AGRICULTURAL EVAPORATION BASIN IN CALIFORNIA

Authors: Gordus, Andrew G., Shivaprasad, H. L., and Swift, Pamela K.

Source: Journal of Wildlife Diseases, 38(1) : 124-131

Published By: Wildlife Disease Association

URL: <https://doi.org/10.7589/0090-3558-38.1.124>

BioOne Complete (complete.BioOne.org) is a full-text database of 200 subscribed and open-access titles in the biological, ecological, and environmental sciences published by nonprofit societies, associations, museums, institutions, and presses.

Your use of this PDF, the BioOne Complete website, and all posted and associated content indicates your acceptance of BioOne's Terms of Use, available at www.bioone.org/terms-of-use.

Usage of BioOne Complete content is strictly limited to personal, educational, and non - commercial use. Commercial inquiries or rights and permissions requests should be directed to the individual publisher as copyright holder.

BioOne sees sustainable scholarly publishing as an inherently collaborative enterprise connecting authors, nonprofit publishers, academic institutions, research libraries, and research funders in the common goal of maximizing access to critical research.

SALT TOXICOSIS IN RUDDY DUCKS THAT WINTER ON AN AGRICULTURAL EVAPORATION BASIN IN CALIFORNIA

Andrew G. Gordus,^{1,2,5} H. L. Shivaprasad,³ and Pamela K. Swift⁴

¹ H. T. Harvey & Associates, 423 W. Fallbrook Street, Suite 206, Fresno, California 93711, USA

² Current address: California Department of Fish and Game, 1234 East Shaw Avenue, Fresno, California 93710, USA

³ California Veterinary Diagnostic Laboratory System, University of California, 2789 S. Orange Avenue, Fresno, California 93725, USA

⁴ California Department of Fish and Game, 1701 Nimbus Road, Suite D, Rancho Cordova, California 95670, USA

⁵ Corresponding author (email: agordus@dfg.ca.gov)

ABSTRACT: Agricultural evaporation basins are used as a means to dispose of highly saline underground-tile-drainage water in the San Joaquin Valley (California, USA). The hypersaline water conditions encourage high aquatic invertebrate production, primarily brine shrimp (*Artemia franciscana*), which attract birds to these sites. Cool winter temperatures (<4 C) and hypersaline water conditions (>70,000 $\mu\text{mhos/cm}$) resulted in feather salt encrustation and salt toxicosis in ruddy ducks (*Oxyura jamaicensis*). During December 1998 and January 1999, approximately 200 dead and sick ruddy ducks were collected from an evaporation basin and five healthy control ruddy ducks were collected from a freshwater wetland. Brains contained $\geq 1,890$ ppm sodium (wet tissue mass) in seven dead birds and contained $\leq 1,150$ ppm sodium in the control birds. Liver arsenic, lead, and mercury concentrations were <1 ppm in all birds examined. Manganese, molybdenum, and copper liver concentrations did not differ significantly ($P > 0.05$) between the two groups of ducks. The dead ducks had significantly higher liver selenium, cadmium, iron, and zinc than the controls, but the concentrations were not sufficient to cause toxicity. Significant gross and microscopic lesions in most of the dead birds included conjunctivitis, lens opacity and cataract formation, vascular congestion in various organs most notably in the meninges of the brain, and myocardial and skeletal muscle degeneration.

Key words: Brain sodium, evaporation ponds, hypersaline water, *Oxyura jamaicensis*, ruddy duck, salt encrustation, salt toxicosis.

INTRODUCTION

To increase crop production in the San Joaquin Valley (California, USA), farmers installed sub-surface drainage tiles to remove highly-saline perched water from the plant root zone (Tanji and Valoppi, 1989). This high-saline drainage water is delivered to large evaporation basins for disposal (Tanji et al., 1985, 1992). The primary cations are sodium, calcium, and potassium, and the main anions are sulfates, chlorides, and carbonates in agricultural drainage water (Tanji et al., 1985, 1992). As water evaporates, salinity increases, resulting in mass production of brine shrimp (*Artemia franciscana*), which is a major food source that attracts birds to these ponds (Tribbey, 1988). This saline water also contains elevated selenium concentrations which impacts breeding recurvirostrids that nest at these basins (Ohlendorf and Skorupa, 1989).

Ruddy ducks (*Oxyura jamaicensis*),

eared grebes (*Podiceps nigricollis*), and American coots (*Fulica americana*) are the main species that winter on large, open, deep agricultural evaporation basins in the San Joaquin Valley. Salt encrustation on ruddy duck feathers has been documented at one evaporation basin (Euliss et al., 1989). The encrusted salts on ruddy ducks were mostly carbonates. Salt toxicosis and feather encrustation have occurred in waterfowl that inhabited hypersaline playa lakes or ponds (Wobeser, 1981; Wobeser and Howard, 1987; Windingstad et al., 1987; Meteyer et al., 1997). Salt toxicosis usually occurred because of drought conditions in an area or when the birds were unable to move to a freshwater source. Lesions associated with salt toxicosis in waterfowl have been described and include conjunctivitis, lens opacities, and vascular congestion in various organs such as oropharynx, lungs, kidney, and spleen, but is most prominent in meninges of the brain

TABLE 1. Concentrations (mg/l) of selected chemicals and electroconductivity in hypersaline water collected 14 October 1998 from an agricultural evaporation basin where ruddy ducks died from salt toxicosis in December 1998 and January 1999 (data from Provost and Pritchard Engineering Group, Inc., 1998).

Chemicals	Pond 1	Pond 2
Arsenic	<0.1	0.210
Boron	100	190
Chlorine	12,000	33,000
Molybdenum	2.10	3.50
Selenium	0.379	0.676
Sodium	16,000	39,000
Sulfate	21,000	51,000
Total dissolved solids (mg/l)	51,000	120,000
Electroconductivity (μ mhos/cm)	51,000	100,000

(Wobeser and Howard, 1987; Windingstad et al., 1987; Meteyer et al., 1997). The purpose of this study was to document salt encrustation and salt toxicosis in ruddy ducks that winter on a hypersaline agricultural evaporation basin.

MATERIALS AND METHODS

In December 1998 and January 1999, approximately 200 dead and sick ruddy ducks and six eared grebes were collected from an agricultural evaporation basin near Lost Hills (Kern County, California, USA) in the San Joaquin Valley (35°65'N, 119°60'W). The evaporation basin is 138 ha and comprised of two ponds: pond 1 and pond 2 which are 80 ha and 58 ha, respectively. All sick and dead birds were collected from pond 2. The electroconductivity of the water, measured with a temperature-

compensated meter, was 51,000 μ mhos/cm in pond 1 and 112,000 μ mhos/cm in pond 2 on 31 December 1998. The water was highly saline, with sodium and sulfates as the dominant ions (Table 1). Additionally, as part of an ongoing monitoring program, bird censuses were conducted twice per month including the months before, during, and after the epornitic. All birds were identified with 10 \times binoculars or a 15 to 40 \times spotting scope and total counts recorded from the perimeter dikes of each pond. Waterfowl were hazed daily on a 24-hr basis, with propane cannons and discharging of cracker shells during daylight hours to discourage bird use at the site. Minimum and maximum air temperatures for December 1994–98 were obtained from the Naval Air Station, Lemoore, California (National Climatic Data Center, 1999) that is approximately 48 km north of the evaporation basin (Table 2).

On 11 January 1999, five control ruddy ducks were shot using steel shot at Mendota Wildlife Management Area (WMA) (36°41'N, 120°18'W) located approximately 104 km north of the evaporation basin. Mendota WMA is a freshwater marsh that receives irrigation quality water for wetland habitat management.

Five freshly dead and two frozen ruddy ducks collected at the evaporation basin were submitted to the California Veterinary Diagnostic Laboratory System (Fresno, California) for necropsy. Birds were individually weighed, necropsied, and gross lesions were recorded. For histopathologic analysis, eyelids, eyes, liver, spleen, kidney, heart, brain, spinal cord, sinus, trachea, lung, oral mucosa, esophagus, proventriculus, gizzard, intestine, pancreas, bone, bone marrow, skeletal muscle, adrenal, thyroid, gonads, ears, and skin were fixed in 10% neutral buffered formalin, trimmed, processed, paraffin embedded, sectioned at 4 μ m, and stained with hematoxylin and eosin (HE) stain. Liver was stained for iron using Perl's stain.

TABLE 2. Minimum and maximum air temperatures (C) for December^a at Naval Air Station, Lemoore, California.

Year	Minimum			Maximum			Number of days <0 C
	Mean ^b	SE	Range	Mean ^b	SE	Range	
1994	3.33A	0.56	-3.3-7.7	13.08DE	0.42	7.7-17.7	5
1995	5.17AB	0.59	0.5-10.5	16.89	0.70	11.1-24.4	0
1996	6.23B	0.67	0.0-12.0	14.94D	0.59	7.0-21.0	0
1997	0.86C	0.69	-6.0-9.0	12.24E	0.52	7.0-18.0	13
1998	-0.89C	0.93	-7.2-10.0	13.8DE	1.11	3.0-23.2	16 ^c

^a Data from National Climatic Data Center, 4 February 1999.

^b Means denoted by same capital letter are similar between years ($P > 0.05$, ANOVA; Duncan's multiple range test).

^c Minimum number of days because 8 observation days were missing.

Liver and lung from a few birds were cultured for aerobic bacteria on 5% sheep blood agar and MacConkey agar (Remel, Lenexa, Kansas, USA) and incubated at 37 C in 7.5% CO₂ for 24 to 48 hr. Intestinal contents were cultured for *Salmonella* by inoculating intestinal contents into selenite broth (Remel), incubated aerobically at 36 C for 18 to 20 hr, then plated onto brilliant green agar. For *Mycoplasma* culture, tracheal swabs were cultured on modified Frey's agar and inoculated into Frey's broth and incubated at 37 C in 7.5% CO₂ and 98% humidity. Plates were examined after 1 to 3 days for aerobic bacteria and *Salmonella* and 1 to 14 days for *Mycoplasma*.

Brains were removed from ducks by cutting the skull with stainless steel scissors and the brain was dislodged from the calvarium by use of a stainless steel spatula. Brain sodium analysis was determined by nitric acid digestion and inductively coupled plasma (ICP) emission spectrophotometry (Accuris, ALL/Fisons, Detroit, Michigan, USA) (Meteyer et al., 1997). Liver samples were digested with nitric acid and analyzed for heavy metals (arsenic, cadmium, copper, iron, lead, manganese, mercury, molybdenum, and zinc) and selenium (Anderson, 1996). The metal screen was conducted by ICP and hydride generation was used for selenium analysis (Tracy and Moller, 1990). All results are presented based on parts per million (ppm) wet tissue mass.

Carcasses were weighed before feathers with salt crystals were plucked by hand from the carcass. The carcasses were then reweighed to determine the percentage of total body weight represented by salt.

Five grams of wet salt crystals collected from the feathers were dissolved in 500 ml distilled, deionized water and the solution was filtered through a 0.45 µm filter. The solution was analyzed for carbonates, chlorides, sulfates, sodium, calcium, and magnesium using high pressure liquid chromatography (Tabatabai and Frankenburger, 1996).

Toxicologic results were analyzed using one-way analysis of variance (ANOVA). The null hypothesis was that brain and liver elemental concentrations were the same between the dead and control ruddy ducks. Minimum and maximum air temperatures were also compared between years via ANOVA. Duncan's multiple range tests were used to separate means when ANOVA showed a significant difference ($P < 0.05$). The results were analyzed using BMDP statistical program 7D (Dixon, 1990).

RESULTS

In December 1997, less than 50 ruddy ducks and over 500 eared grebes were ob-

served on the ponds during a period of freezing temperatures. On 10 December 1998, 562 ruddy ducks and 916 eared grebes were present on pond 2. Numbers decreased in late December (13 and 755, respectively) and by 13 January 1999, 12 ruddy ducks and 137 eared grebes were observed using the evaporation basin.

Minimum December temperatures were significantly lower ($F_{4,142} = 17.6$, $P < 0.001$) in 1997 and 1998 compared to 1994–96 (Table 2). Both years also had >10 days below freezing. However, maximum temperatures in 1998 were not significantly different compared to 1994, 1996, and 1997, and in 1995 maximum temperatures were significantly higher than the other 4 yr.

Six of seven dead ruddy ducks from the evaporation basin had moderate to heavy salt encrustation on the head, neck, breast, wing, and tail feathers (Fig. 1). The salt crystals primarily consisted of sodium sulfate with some chlorides and calcium present. These constituents are similar to the relative amounts of minerals present in the hypersaline water in pond 2. Thirty-one percent of the total body weight of one ruddy duck was from salt encrustation on the head, neck, breast, and tail feathers (Fig. 1). Ten to 20% of the total body weight for four other birds was salt encrustation. None of the five control birds had any salt encrusted feathers.

Brain sodium concentrations in the control ruddy ducks ($\leq 1,150$ ppm) were significantly lower ($F_{1,10} = 75.2$, $P < 0.0001$) than the dead ruddy ducks ($\geq 1,890$ ppm) (Table 3). Arsenic, lead, and mercury liver concentrations in all birds were <1 ppm. Selenium, cadmium, iron, and zinc liver concentrations were significantly higher ($F_{1,8} = 8.8, 17.1, 7.3, 27.8$, respectively, $P < 0.03$) in dead ruddy ducks than the control birds (Table 3). Although copper concentration was lower in the dead ruddy ducks than in the controls, the difference was not significant ($F_{1,8} = 4.7$, $P = 0.06$). There was no significant difference between the two groups for manganese ($F_{1,8}$

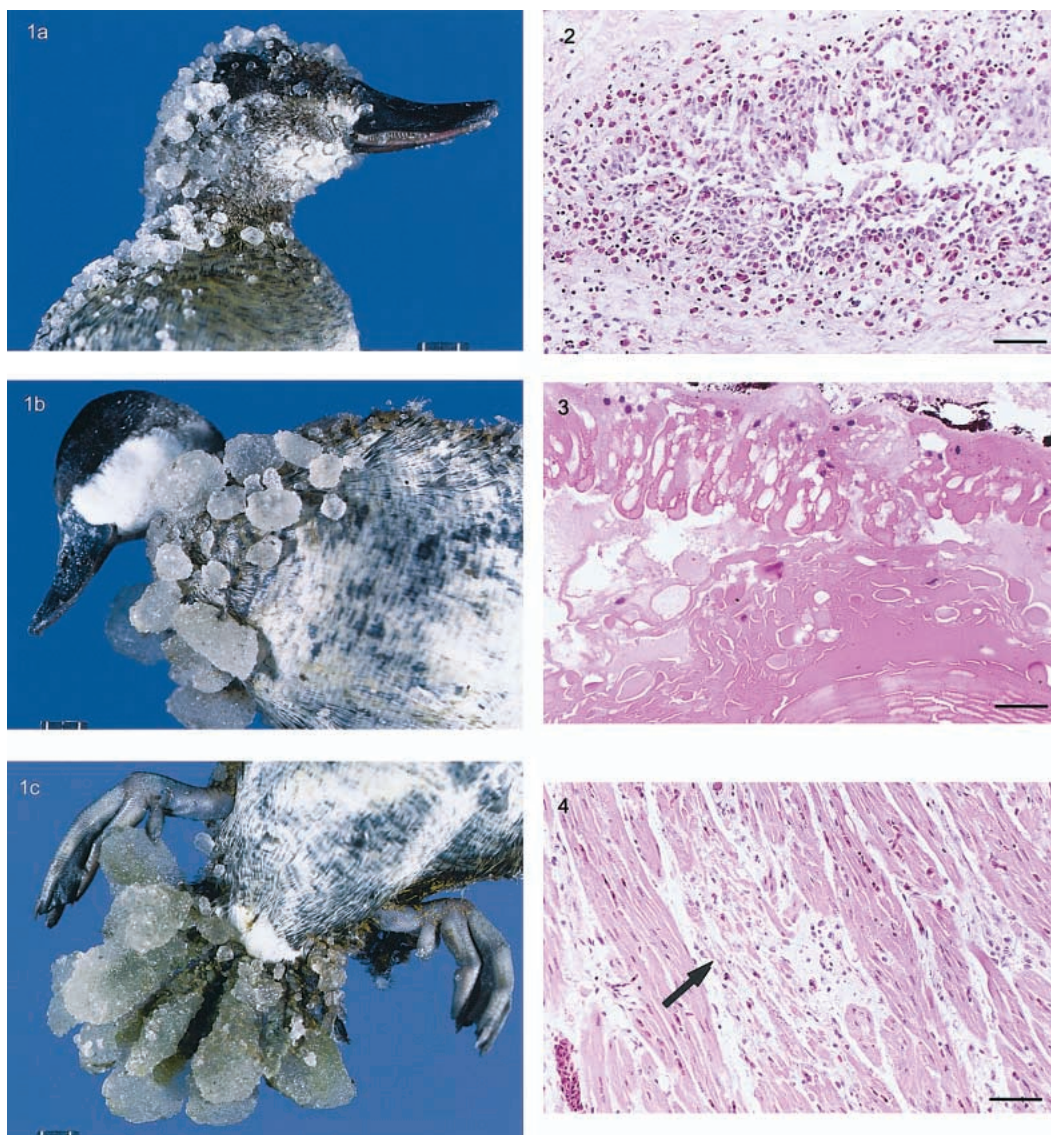


FIGURE 1. Salt encrustation on the a) head, b) breast, and c) tail feathers of two ruddy ducks collected at a hypersaline agricultural evaporation basin in December 1998. The salt crystals were primarily sodium sulfate. Bar = 1 cm.

FIGURE 2. Photomicrograph of duck conjunctiva with mild proliferation of epithelial cells and granulocytic infiltration. HE. Bar = 140 μ m.

FIGURE 3. Photomicrograph of a duck lens with cataractic changes, severe swelling, and necrosis of lens fibers. HE. Bar = 80 μ m.

FIGURE 4. Photomicrograph of a duck heart with degeneration of myofibers (arrow) and infiltration of a few mononuclear cells. HE. Bar = 200 μ m.

TABLE 3. Concentration of elements from tissues of ruddy ducks collected in December 1998 and January 1999 at a highly saline agricultural evaporation basin and a freshwater wetland (control site), California.

	Concentrations (ppm wet tissue mass)							
	Dead birds				Control birds			
	<i>n</i>	Mean	SE	Range	<i>n</i>	Mean	SE	Range
Brain								
Sodium	7	2,580A ^a	1.08	1,890–3,670	5	1,090B	1.03	988–1,150
Liver								
Cadmium	5	4.5A	1.18	2.6–6.0	5	0.38B ^b	1.77	<0.30–1.7
Copper	5	19.8A	1.50	5.8–50.6	5	50.6A	1.17	33.1–81.3
Iron	5	1,799A	1.16	1,230–2,420	5	838B	1.27	338–1,340
Manganese	5	4.8A	1.05	4.14–5.42	5	5.2A	1.09	4.28–6.77
Molybdenum	5	1.43A	1.19	0.9–2.6	5	0.99A	1.13	0.7–1.3
Selenium	5	5.41A	1.12	4.06–6.94	5	2.98B	1.18	1.96–4.38
Zinc	5	70.2A	1.10	51.8–90.3	5	40.5B	1.03	35.9–42.3

^a Geometric means denoted by same capital letter are similar ($P > 0.05$, ANOVA) between the dead and control ruddy ducks for each element.

^b One-half the detection limit was used to calculate the geometric mean when the chemical concentration was below the limit of detection.

= 0.80, $P = 0.40$) and molybdenum ($F_{1,8} = 3.0$, $P = 0.12$) (Table 3).

Gross lesions in all the dead ducks with salt encrustation were dehydration, congestion of conjunctiva, mild to moderate opacity of lens in five freshly dead birds, and increased mucus in the proventriculus. Congestion occurred in various organs and was most prominent in the meninges of the brain. Two dead birds had enlarged gall bladders and one bird had pale kidneys.

All the dead ducks had microscopic lesions consisting of mild hypertrophy and proliferation of conjunctival epithelial cells with infiltration of granulocytes in the mucosa (Fig. 2) and cataracts. These changes were characterized by swelling, degeneration, and necrosis of the lens fibers with accumulation of granular debris (Morgagnian globules) in the cytoplasm (Fig. 3). Most of these cataractic changes were in the cortex involving primarily the lens pad but the lens capsule was intact. Five birds had mild multifocal myocardial degeneration with mineralization and infiltration of a few mononuclear cells randomly scattered throughout the heart (Fig. 4). Three birds had severe degeneration and mineralization of skeletal muscle fibers. Six of

seven birds had large amounts of bile in bile ducts within the liver and three birds had accumulation of iron-positive, golden-brown pigments in the cytoplasm of hepatocytes and Kupffer cells. All dead birds had mild to moderate inflammation of the mucosal and glandular portions of the proventriculus associated with a few nematode larvae. Other changes seen in five ducks were disseminated vascular congestion in liver, kidney, and spleen, but change was most prominent in the meninges of brain. These birds also had mild nephrosis in the kidney. No significant lesions were observed in the esophagus, intestine, pancreas, gonads, skin, trachea, bone, bone marrow, ear, and spinal cord from the dead ruddy ducks. Control birds were free of significant lesions except for the presence of hemosiderin pigment in the liver. Bacteria were not cultured from the lungs or livers, and tracheas were negative for *Mycoplasma* sp. The intestines were negative for *Salmonella* sp.

DISCUSSION

In late December 1998 and January 1999, numbers of birds declined at the evaporation basin. In mid-December 1998, a brine shrimp harvester indicated

no brine shrimp were captured, most likely due to relatively cool temperatures which resulted in a brine shrimp population crash. The most likely reason the birds left the evaporation basin in late December was the lack of food, thus decreasing the risk of salt encrustation and toxicosis to this group of birds.

Meteyer et al. (1997) considered $\geq 2,000$ ppm sodium (wet mass) in bird brain as diagnostic of salt toxicosis. Brains from six birds from the evaporation basin were over this sodium threshold, but all seven were within the sodium range (1,900 to 2,100 ppm) that caused salt toxicosis in Canada geese (*Branta canadensis*) that died on a highly saline lake in North Dakota (Windingstad et al., 1987). Sodium brain concentrations in ruddy ducks and other waterfowl collected at hypersaline playa lakes in southeast New Mexico (Meteyer et al., 1997) were similar to our results. Our control-bird brain-sodium concentrations were lower than concentrations for control waterfowl stated in Windingstad et al. (1987) (1,600 to 1,710 ppm) and Meteyer et al. (1997) (1,305 to 1,413 ppm).

Although liver concentrations of four elements were significantly higher in the birds from the evaporation basin than the control birds, these elements do not appear to have caused direct mortality. More than 20 ppm selenium (wet liver mass) can cause avian mortality and 10 to 20 ppm (wet mass) can result in sublethal biochemical effects and microscopic lesions in the liver and spleen (Albers et al., 1996). Liver concentrations in all seven dead ruddy ducks were below the 10 ppm selenium (wet mass) threshold.

Cadmium induces the synthesis of metallothionein, a protein that binds divalent metals which can lead to zinc and other heavy metal accumulation in the liver (Furness, 1996). All liver concentrations in ruddy ducks were below 10 ppm cadmium (wet mass) which is the threshold indicative of cadmium contamination (Eisler, 1985) and were well below the 40 ppm liver cadmium threshold suggested by

Furness (1996). Additionally, ducks appear to be resistant to cadmium toxicosis, compared to other avian species, because duck liver contains high levels of metallothionein that bind cadmium (Eisler, 1985).

The metabolic relationship between cadmium and other metals in birds is complex and not very well known. Cadmium, through induction of metallothionein, could increase zinc and iron liver concentrations (Furness, 1996). It is highly unlikely elevated zinc levels had sublethal effects on birds that inhabited the evaporation basin. Zinc concentrations in avian food-organisms at the evaporation basin were below the dietary thresholds for birds (Moore et al., 1990; Eisler, 1993). For example, mallards (*Anas platyrhynchos*) fed 3,000 mg Zn/kg (dry wt) had 401 mg/kg (wet mass) in the liver compared to 54 mg/kg in controls (Eisler, 1993). Elevated zinc in liver can reduce liver turnover of iron and reduce copper content of the liver and pancreas in chicks (Eisler, 1993). Therefore, elevated cadmium in conjunction with elevated zinc may have caused elevated iron and decreased copper in the livers of the dead ruddy ducks. Additionally, we speculate elevated plasma sodium may have altered osmolarity resulting in hemolysis. Hemolysis and liver congestion could explain elevated iron concentrations in the dead duck livers.

Conjunctivitis, cataracts, myocardial and skeletal muscle degeneration, nephrosis, dehydration, bile stasis in the liver, and congestion in various organs have been described with salt toxicosis in waterfowl (Wobeser and Howard, 1987; Windingstad et al., 1987; Meteyer et al., 1997). Dehydration, nephrosis, and bile stasis in the liver is probably secondary to lack of fresh water. Myocardial and skeletal muscle degeneration have been inconsistently reported. These changes were described in one study (Wobeser and Howard, 1987), but were not described in two other studies (Windingstad et al., 1987; Meteyer et al., 1997). Myocardial degeneration and right ventricular failure due to salt toxicity

have been described in broiler chickens (Julian and Brown, 1997).

Five of seven ducks had cataracts. Though cataracts have been associated with salt toxicosis in ducks (Meteyer et al., 1997), they have not been associated with salt toxicosis in other birds (Julian and Brown, 1997). It has been suggested that cataractic changes associated with salt toxicity in ducks is not an antemortem change and that the ducks develop these lesions postmortem due to the terminal immersion of the eye in hypersaline water (Miller et al., 1998). It has been suggested that this terminal event leads to a shift of fluid/electrolyte within the eye resulting in cataract formation (Miller et al., 1998).

Decreased salt solubility, particularly sulfates, in the hypersaline waters at the evaporation basin was a result of cool December temperatures. Wobeser and Howard (1987) observed large crystal agglomerates formed rapidly in a hypersaline solution (100,000 $\mu\text{mhos/cm}$ at 25 C) cooled to 3 C. After the crystals formed, the solution conductance was 77,000 $\mu\text{mhos/cm}$ at 3 C. The ability of the ruddy ducks to forage and to fly to a fresh water source was decreased as a result of salt precipitation on the feathers. Therefore, it is likely that a combination of factors contributed to salt encrustation and toxicosis in the ruddy ducks at the basin including: (1) cool ambient temperatures (<4 C); (2) hypersalinity (using >70,000 $\mu\text{mhos/cm}$ as a conservative value based on Wobeser and Howard, 1987), and (3) relatively high numbers of ruddy ducks utilizing the pond. To minimize the risk of ruddy duck salt toxicosis and encrustation, the following program for evaporation basin management is suggested for individual ponds that have (1) >70,000 $\mu\text{mhos/cm}$ electrical conductance, (2) ambient temperatures ≤ 4 C, and (3) more than 50 ruddy ducks using the hypersaline pond. Modified management includes increased hazing efforts through the use of boats (i.e., airboats, hovercraft, brine shrimp harvester) and adding low saline water (i.e., inlet wa-

ter or freshwater) to the pond directly or through circulation from a lower saline pond to decrease the salinity of the pond. Although additional research is needed to identify and manage negative impacts to wintering birds that use agricultural evaporation basins, decreasing bird use through an aggressive hazing program and decreasing salinity by dilution should decrease the risk of ruddy ducks to salt encrustation and toxicosis. Also providing a clean, freshwater wetland near the evaporation basin would provide a low saline environment for the ruddy ducks.

ACKNOWLEDGMENTS

The authors thank M. Crew, E. Smith, and B. Huddleson for collecting and submitting dead and control ruddy ducks to the pathology laboratory. Toxicologic results were provided by F. Galey. K. Tanji provided the salt crystal constituent results. R. Botzler provided helpful comments and suggestions on previous drafts of this report. Funding for this study was provided by P. Nixon of the Lost Hills Water District.

LITERATURE CITED

- ALBERS, P. H., D. E. GREEN, AND C. J. SANDERSON. 1996. Diagnostic criteria for selenium toxicosis in aquatic birds: Dietary exposure, tissue concentrations, and macroscopic effects. *Journal of Wildlife Diseases* 32: 468–485.
- ANDERSON, K. A. 1996. A micro digestion and analysis method for determining macro and micro elements in plant tissues by inductively coupled plasma atomic emission. *Journal of Atomic Spectroscopy* 1: 30–33.
- DIXON, W. J. 1990. *BMDP statistical software manual*. University of California Press, Berkeley, California, 1,385 pp.
- EISLER, R. 1985. Cadmium hazards to fish, wildlife, and invertebrates: A synoptic review. *Biological Report* 85(1.2), U.S. Fish and Wildlife Service, Laurel, Maryland, 46 pp.
- . 1993. Zinc hazards to fish, wildlife, and invertebrates: a synoptic review. *Biological Report* 10, U.S. Fish and Wildlife Service, Laurel, Maryland, 106 pp.
- EULISS, N. H., JR., R. L. JARVIS, AND D. S. GILMER. 1989. Carbonate deposition on tail feathers of ruddy ducks using evaporation ponds. *The Condor* 91: 803–806.
- FURNESS, R. W. 1996. Cadmium in birds. *In* Environmental contaminants in wildlife. Interpreting tissue concentrations, W. N. Beyer, G. H. Heinz,

- and A. W. Redmond-Norwood (eds.). Society of Environmental Toxicology and Chemistry special publication. CRC Press, Inc., Boca Raton, Florida, pp. 389–404.
- JULIAN, R. J., AND T. P. BROWN. 1997. Other toxins and poisons. *In* Diseases of poultry, B. C. Calnek, H. J. Barnes, C. W. Beard, L. R. McDougald, and Y. M. Saif (eds.). Iowa State University Press, Ames, Iowa, pp. 985–986.
- METEYER, C. U., R. R. DUBIELZIG, F. J. DEIN, L. A. BAETEN, M. K. MOORE, J. R. JEHL, JR., AND K. WESENBERG. 1997. Sodium toxicity and pathology associated with exposure of waterfowl to hypersaline playa lakes of southeast New Mexico. *Journal of Veterinary Diagnostic Investigations* 9: 269–280.
- MILLER, P. E., L. A. BAETEN, S. SISSLER, F. J. DEIN, R. R. DUBIELZIG, AND C. J. MURPHY. 1998. Ocular abnormalities in ducks exposed to hypersaline water from the playa lakes of southeastern New Mexico. *Investigative Ophthalmology and Visual Science* 39: S713.
- MOORE, S., J. WINCKEL, S. DETWILER, S. KLASING, P. GAUL, N. KANIM, B. KESSER, A. DEBEVEC, K. BEARDSLEY, AND L. PUCKETT. 1989. Fish and wildlife resources and agricultural drainage in the San Joaquin Valley, California. San Joaquin Drainage Program, Sacramento, California. Vol. I and II. 812 pp.
- NATIONAL CLIMATIC DATA CENTER. 1999. www.ncdc.noaa.gov. Accessed 4 February 1999.
- OHLENDORF, H. M., AND J. P. SKORUPA. 1989. Selenium in relationship to wildlife and agricultural drainage water. *Proceedings of the International Symposium on Uses of Selenium and Tellurium* 4: 314–338.
- PROVOST AND PRITCHARD ENGINEERING GROUP, INC. 1998. Annual report to the California Regional Water Quality Control Board Central Valley Region, monitoring and reporting program, 93-152, Lost Hills Water District agricultural subsurface drainage evaporation disposal basin, Kern County, 31 pp.
- TABATABAI, M. A., AND W. T. FRANKENBURGER. 1996. Liquid chromatography. *In* D. L. Sparks (ed.). *Methods of soil analysis*. SSSA Book Series 5, Soil Science Society of America, Inc., Madison, Wisconsin, pp. 225–245.
- TANJI, K. K., AND L. VALOPPI. 1989. Groundwater contamination by trace elements. *Agriculture, Ecosystems and Environment* 26: 229–274.
- , M. E. GRISMER, AND B. R. HANSON. 1985. Subsurface drainage evaporation ponds. *California Agriculture* 39: 10–12.
- , C. G. H. ONG, R. A. DAHLGREN, AND M. J. HERBEL. 1992. Salt deposits in evaporation ponds: An environmental hazard? *California Agriculture* 46: 18–21.
- TRACY, M. L., AND G. MOLLER. 1990. Continuous flow vapor generation for inductively coupled argon plasma spectrometric analysis. Part I: Selenium. *Journal of Associated Official Analytical Chemists* 73: 404–410.
- TRIBBEY, B. 1988. Biological assessment of evaporation ponds. U.S. Soil Conservation Service, Kings River Conservation District. California State University, Fresno, California, 102 pp.
- WINDINGSTAD, R. M., F. X. KARTCH, AND R. K. STROUD. 1987. Salt toxicosis in waterfowl in North Dakota. *Journal of Wildlife Diseases* 23: 443–446.
- WOBESER, G. 1981. *Diseases of wild waterfowl*. Plenum Press, New York, New York. 300 pp.
- , AND J. HOWARD. 1987. Mortality of waterfowl on a hypersaline wetland as a result of salt encrustation. *Journal of Wildlife Diseases* 23: 127–134.

Received for publication 30 September 1999.