



Fatal Cytauxzoonosis in a Free-ranging Bobcat (*Lynx rufus*)

Authors: Nietfeld, Jerome C., and Pollock, Christal

Source: Journal of Wildlife Diseases, 38(3) : 607-610

Published By: Wildlife Disease Association

URL: <https://doi.org/10.7589/0090-3558-38.3.607>

BioOne Complete (complete.BioOne.org) is a full-text database of 200 subscribed and open-access titles in the biological, ecological, and environmental sciences published by nonprofit societies, associations, museums, institutions, and presses.

Your use of this PDF, the BioOne Complete website, and all posted and associated content indicates your acceptance of BioOne's Terms of Use, available at www.bioone.org/terms-of-use.

Usage of BioOne Complete content is strictly limited to personal, educational, and non - commercial use. Commercial inquiries or rights and permissions requests should be directed to the individual publisher as copyright holder.

BioOne sees sustainable scholarly publishing as an inherently collaborative enterprise connecting authors, nonprofit publishers, academic institutions, research libraries, and research funders in the common goal of maximizing access to critical research.

Fatal Cytauxzoonosis in a Free-ranging Bobcat (*Lynx rufus*)

Jerome C. Nietfeld^{1,3} and Christal Pollock² ¹Department of Diagnostic Medicine/Pathobiology and ²Department of Clinical Sciences, College of Veterinary Medicine, Mosier Hall, Kansas State University, Manhattan, Kansas 66506-5705, USA; ³Corresponding author (email: nietfeld@vet.ksu.edu)

ABSTRACT: In September 2000, a free-ranging bobcat (*Lynx rufus*) cub was presented to the Kansas State University Veterinary Teaching Hospital (Manhattan, Kansas, USA) in a moribund state with signs of severe anemia and respiratory difficulty. The cub was euthanized. Gross necropsy findings included multifocal atelectasis, splenomegaly, and pericardial effusion. Microscopic examination revealed subacute pulmonary thrombosis, mild vasculitis in the brain, and large schizont-filled macrophages within blood vessels of all tissues examined. The organisms were typical of the developmental stages of *Cytauxzoon felis*. Cytauxzoonosis is considered to be a persistent, subclinical infection in the bobcat; however, this cub had lesions consistent with those seen in fatal infections in domestic cats. This case of fatal *C. felis* infection indicates that some free-ranging bobcats may die of cytauxzoonosis.

Key words: Anemia, bobcat, *Cytauxzoon felis*, cytauxzoonosis, *Lynx rufus*.

Cytauxzoon felis is a tick-borne protozoa that causes an acute, highly fatal, febrile disease of domestic cats with clinical signs of an acute hemolytic crisis (Kier and Greene, 1998). Survival of infected domestic cats is unusual. A recent report described 18 domestic cats that survived natural infection by *C. felis* (Meinkoth et al., 2000). Prior to that only two naturally infected domestic cats were known to have survived (Walker and Cowell, 1995; Kier and Greene, 1998).

In contrast, *C. felis* infection of healthy, free-ranging bobcats (*Lynx rufus*) has been found by several investigators (Glenn et al., 1982, 1983; Kocan and Blouin, 1985; Blouin et al., 1987). In some areas, infection is quite common. Researchers have reported that 13 of 26 (50%) and five of 16 (32%) wild-trapped bobcats from Oklahoma were infected (Glenn et al., 1982; Kocan and Blouin, 1985). In the first study, all infected bobcats were from two counties and 13 of 21 (62%) bobcats were

infected. Even though most infected bobcats remain healthy, it is possible for them to develop fatal infection. One of two bobcats died after parental inoculation of tissue homogenates from a domestic cat that died of cytauxzoonosis (Kier et al., 1982), and one of two bobcats developed fatal cytauxzoonosis after researchers allowed *C. felis* infected ticks (*Dermacentor variabilis*) to feed on the bobcats (Blouin et al., 1987). However, we found no reports of fatal infection in naturally infected free-ranging bobcats. The purpose of this report is to describe a case of fatal cytauxzoonosis in a naturally infected, free-ranging bobcat.

In September 2000, a free-ranging, female bobcat cub was found in an open field near Wamego, Kansas (USA, 39°25'N, 96°32'W). The bobcat was caught and taken to the Kansas State University Veterinary Teaching Hospital (Manhattan, Kansas, USA). Upon presentation, the 0.7 kg cub, estimated to be 2–3 mo old was moribund, emaciated, and hypothermic (34.9 C). It had white mucous membranes, fixed and dilated pupils, irregular respiration, and a small amount of brown feces pasted around its rectum. Blood was drawn after initiating treatment with 100% oxygen via a face mask. The bobcat was severely anemic with a packed cell volume of 7% (normal=41.1±6.7%; Teare, 1998). Serum blood glucose was 180 mg/dl (normal=159±91 mg/dl). Because of the poor prognosis, the cub was euthanized.

Postmortem examination revealed that the kitten was thin but otherwise externally normal. There were 5–10 ml of clear, straw-colored fluid in the pericardial sac. The lungs contained patchy areas of atelectasis and the spleen was enlarged and

dark red. No other significant macroscopic changes were found. Samples of major organs were collected and fixed in 10% neutral buffered formalin. Sections of lung, brain, liver, spleen, kidneys, and bone marrow were further processed and examined histologically.

Microscopic examination demonstrated large macrophages filled with small basophilic organisms typical of developing stages of *C. felis* within vascular spaces, especially veins, of all tissues examined. The intravascular macrophages were enlarged several fold (up to 150 μm in diameter) and tended to line the endothelial surfaces. Occasional small and medium sized vessels appeared to be occluded by macrophages, but a definite lumen was present in large vessels. The majority of the macrophages were filled with 2–3 μm structures that were round to oblong and occasionally indented or partially folded. These structures were compatible with mature schizonts or macroschizonts (Kier et al., 1987). A few macrophages were filled with smaller, uniform, basophilic structures approximately 1 μm in diameter that were compatible with micros schizonts or extraerythrocytic micromerozoites (Kier et al., 1987). Both the macroschizonts and micros schizonts were surrounded by clear spaces, giving the macrophages a foamy appearance.

In the lungs, parasite-filled macrophages were especially prominent, and several medium and large veins contained fibrin thrombi that partially to totally occluded the lumen. *Cytauxzoon*-filled macrophages were attached to thrombi and the endothelial surface adjacent to thrombi (Fig. 1). Many thrombi were being organized by fibroblasts, which indicated that the thrombi had been present for at least a few days. The connective tissue surrounding many of the larger pulmonary veins was markedly edematous and contained *Cytauxzoon*-filled macrophages. Scattered throughout the brain, usually closely associated with blood vessels, were small groups of mononuclear cells. Infiltrating

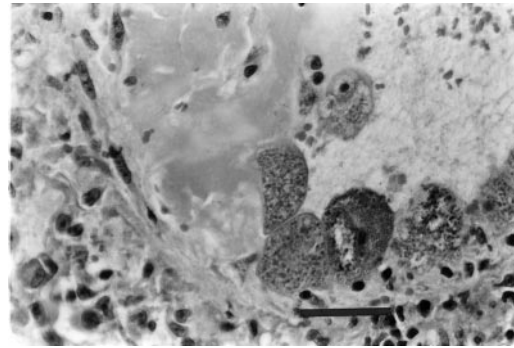


FIGURE 1. A pulmonary vein with several *Cytauxzoon felis* schizont-filled macrophages attached to the endothelial surface. Immediately adjacent to the parasitized macrophages is a fibrin thrombus that is partially organized by fibroblasts. HE stain. Bar=95 μm .

lymphocytes and plasma cells thickened the walls of scattered vessels. Macrophages filled with *Cytauxzoon* organisms were often present in these foci of inflammation (Fig. 2). The bone marrow, which also contained parasitized macrophages, was hypercellular with an increase in erythrocytic blast cells indicating an ongoing regenerative response to the anemia. *Cytauxzoon*-filled macrophages were present in vessels in other organs, but there were no associated lesions.

The genus *Cytauxzoon*, along with the genera *Theileria* and *Gonderia*, is a member of the family Theileriidae (Cowell et al., 1988). All members of the family have a nonreplicating erythrocytic phase where piroplasms are present within erythrocytes and a replicating tissue phase where schizonts are present in leukocytes. *Cytauxzoon* species differ from other members of the family in that the schizogonous phase occurs within macrophages that line blood vessels throughout the body, while the schizogonous stage of *Theileria* and *Gonderia* occurs in lymphocytes (Cowell et al., 1988; Kier and Greene, 1998). The erythrocytic form of *Cytauxzoon* can appear very similar to *Babesia* and *Haemobartonella*; however, neither *Babesia* nor *Haemobartonella* have a leukocytic or tissue phase.

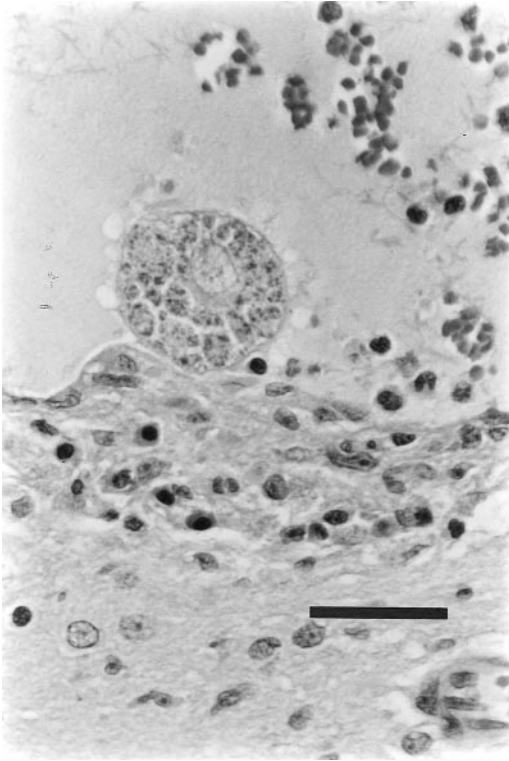


FIGURE 2. An enlarged macrophage filled with schizonts of *C. felis* attached to the endothelium of a vein in the brain stem. Note the infiltrate of mononuclear leukocytes immediately adjacent to the macrophage. HE stain. Bar=90 μ m.

Development of the schizogonous form is necessary for the disease to be fatal. Domestic cats experimentally infected only with the intraerythrocytic form of *C. felis* became parasitemic, but did not develop the tissue phase and infection was not fatal (Glenn et al., 1983). When infected with the schizogonous tissue phase of *C. felis*, domestic cats developed both the intraerythrocytic and tissue phases, and infection was fatal. Only the intraerythrocytic form has been found in naturally infected free-ranging bobcats (Glenn et al., 1983; Blouin et al., 1987). However, bobcats can develop the tissue phase. Each of two adult bobcats infected by parenteral inoculation of ground tissue suspensions from *C. felis* infected domestic cats became parasitemic, and one died 2 wk after infection (Kier et al., 1982). Schizonts of *C. felis*

were present in macrophages in tissues from the dead bobcat. The surviving bobcat was parasitemic for at least 4 yr, but whether it developed the tissue phase was not determined. However, based on work in domestic cats, it probably did develop and recover from the tissue phase. In a second experiment, two bobcats were experimentally infected by allowing *C. felis* infected *D. variabilis* to feed on them (Blouin et al., 1987). Schizogonous forms of *C. felis* were found in both bobcats 11 days after tick-attachment. One bobcat developed typical signs of cytauxzoonosis and died 19 days after tick-attachment. The second bobcat remained healthy and no evidence of the tissue phase was found 30 days after tick-attachment. Thus, both the schizogonous and intraerythrocytic forms can develop in bobcats after infection with the schizogonous form. Some bobcats die as a result of infection, while others survive and eliminate the schizogonous stages, but remain persistently infected with the intraerythrocytic stage. Because so few bobcats have been experimentally infected, the prevalence of fatal infections is unknown. The roles of other factors such as age, health, and strain of *C. felis* are also unknown.

Finding free-ranging bobcats that die of cytauxzoonosis would be difficult and studies to determine prevalence of cytauxzoonosis in healthy bobcats can only identify those animals that are persistently infected with the intraerythrocytic phase. The presence of large schizont-filled macrophages lining vessels throughout the body of the bobcat in the current report is diagnostic of the schizogonous phase of *C. felis*. Anemia caused by destruction of parasitized erythrocytes, thrombosis, perivascular edema, and mild vasculitis, which were present in this bobcat, occur in the later stages of fatal cytauxzoonosis in domestic cats (Kier et al., 1987; Kier and Greene, 1998). The clinical and pathologic findings in this bobcat are consistent with and support the results of experimental infection, which

suggest that some free-ranging bobcats die each year of cytauxzoonosis.

ACKNOWLEDGMENTS

Contribution no. 01-434-J from the Kansas Agricultural Experiment Station.

LITERATURE CITED

- BLOUIN, E. F., A. A. KOCAN, K. M. KOCAN, AND J. HAIR. 1987. Evidence of a limited schizogonous cycle for *Cytauxzoon felis* in bobcats following exposure to infected ticks. *Journal of Wildlife Diseases* 23: 499–501.
- COWELL, R. L., R. J. PANCIERA, J. C. FOX, AND R. D. TYLER. 1988. Feline cytauxzoonosis. Compendium on Continuing Education for the Practicing Veterinarian 10: 731–736.
- GLENN, B. L., R. E. ROLLEY, AND A. A. KOCAN. 1982. *Cytauxzoon*-like piroplasms in erythrocytes of wild-trapped bobcats in Oklahoma. *Journal of the American Veterinary Medical Association* 181: 1251–1253.
- , A. A. KOCAN, AND E. F. BLOUIN. 1983. Cytauxzoonosis in bobcats. *Journal of the American Veterinary Medical Association* 183: 1155–1158.
- KIER, A. B., AND C. E. GREENE. 1998. Cytauxzoonosis. In *Infectious diseases of the dog and cat*, 2nd Edition, C. E. Greene (ed.). W. B. Saunders Company, Philadelphia, Pennsylvania, pp. 470–473.
- , S. R. WIGHTMAN, AND J. E. WAGNER. 1982. Interspecies transmission of *Cytauxzoon felis*. *American Journal of Veterinary Research* 43: 102–105.
- , J. E. WAGNER, AND D. A. KINDEN. 1987. The pathology of experimental cytauxzoonosis. *Journal of Comparative Pathology* 97: 415–432.
- KOCAN, A. A., AND E. F. BLOUIN. 1985. Hematologic and serum chemical values for free-ranging bobcats, *Felis rufus* (Schreber), with reference to animals with natural infections of *Cytauxzoon felis* Kier, 1979. *Journal of Wildlife Diseases* 21: 190–192.
- MEINKOTH, J., A. A. KOCAN, L. WHITWORTH, G. MURPHY, J. C. FOX, AND J. P. WOODS. 2000. Cats surviving natural infection with *Cytauxzoon felis*: 18 cases (1997–1998). *Journal of Veterinary Internal Medicine* 14: 521–525.
- TEARE, J. A. (Editor). 1998. Physiologic data reference values CD-ROM. International Species Information System, Apple Valley, Minnesota.
- WALKER, D. B., AND R. L. COWELL. 1995. Survival of a domestic cat with naturally acquired cytauxzoonosis. *Journal of the American Medical Association* 206: 1363–1365.

Received for publication 15 June 2001.