

## **AN ADENOVIRUS ASSOCIATED WITH INTESTINAL IMPACTION AND MORTALITY OF MALE COMMON EIDERS (SOMATERIA MOLLISSIMA) IN THE BALTIC SEA**

Authors: Hollmén, Tuula E., Franson, J. Christian, Kilpi, Mikael, Docherty, Douglas E., and Myllys, Vesa

Source: Journal of Wildlife Diseases, 39(1) : 114-120

Published By: Wildlife Disease Association

URL: <https://doi.org/10.7589/0090-3558-39.1.114>

---

BioOne Complete ([complete.BioOne.org](https://complete.BioOne.org)) is a full-text database of 200 subscribed and open-access titles in the biological, ecological, and environmental sciences published by nonprofit societies, associations, museums, institutions, and presses.

Your use of this PDF, the BioOne Complete website, and all posted and associated content indicates your acceptance of BioOne's Terms of Use, available at [www.bioone.org/terms-of-use](https://www.bioone.org/terms-of-use).

Usage of BioOne Complete content is strictly limited to personal, educational, and non - commercial use. Commercial inquiries or rights and permissions requests should be directed to the individual publisher as copyright holder.

---

BioOne sees sustainable scholarly publishing as an inherently collaborative enterprise connecting authors, nonprofit publishers, academic institutions, research libraries, and research funders in the common goal of maximizing access to critical research.

# AN ADENOVIRUS ASSOCIATED WITH INTESTINAL IMPACTION AND MORTALITY OF MALE COMMON EIDERS (*SOMATERIA MOLLISSIMA*) IN THE BALTIC SEA

Tuula E. Hollmén,<sup>1,2,3,7</sup> J. Christian Franson,<sup>2</sup> Mikael Kilpi,<sup>4,6</sup> Douglas E. Docherty,<sup>2</sup> and Vesa Myllys<sup>5</sup>

<sup>1</sup> Department of Basic Veterinary Sciences, P.O. Box 57, 00014 University of Helsinki, Finland

<sup>2</sup> US Geological Survey, National Wildlife Health Center, 6006 Schroeder Road, Madison, Wisconsin 53711, USA

<sup>3</sup> Alaska Sea Life Center, P.O. Box 1329, Seward, Alaska 99664, USA

<sup>4</sup> Department of Ecology and Systematics, P.O. Box 7, 00014 University of Helsinki, Finland

<sup>5</sup> National Veterinary and Food Research Institute, P.O. Box 358, 00231 Helsinki, Finland

<sup>6</sup> Current address: Aronia Research Centre, Åbo Akademi University and Sydväst Polytechnic, Raseborgsvägen 6-8, Tammissaari, Finland

<sup>7</sup> Corresponding author (email: tuula.hollmen@alaskasealife.org)

**ABSTRACT:** We examined 10 common eider (*Somateria mollissima*) males found dead in 1998 during a die-off in the northern Baltic Sea off the southwestern coast of Finland. We diagnosed impaction of the posterior small intestine with mucosal necrosis as the cause of death in all 10 and isolated adenoviruses from cloacal samples of six birds. The adenovirus isolates were not neutralized by reference antisera to group I, II, or III avian adenoviruses. Cloacal swabs from 22 apparently healthy eider females nesting at the mortality area were negative for viruses. An adenovirus isolated from one of the eiders caused clinical signs of illness and gastrointestinal pathology in experimentally infected mallard (*Anas platyrhynchos*) ducklings. These findings suggest that the adenovirus contributed to the mortality of common eider males in the Finnish archipelago.

**Key words:** Adenovirus, *Anas platyrhynchos*, common eider, enteritis, mallard, *Somateria mollissima*.

## INTRODUCTION

The common eider (*Somateria mollissima*) is the most numerous species of waterfowl in the Baltic Sea, with an estimated 150,000–200,000 pairs currently breeding in the Finnish archipelago (Hario, 2000). Baltic eiders overwinter in Denmark, migrate to their breeding grounds in the northern Baltic in early spring, and initiate nesting after the near shore ice cover surrounding the breeding islands breaks up (Hario and Selin, 1986). At the breeding grounds, males continuously court their females until nest initiation. During this period, which lasts several weeks, males spend less time feeding than females and may lose a substantial amount of body weight (Christensen, 2000). When females begin incubation, males concentrate in flocks and feed intensively to regain body condition prior to moving to molting grounds in the open sea.

In spring of 1998, many eider males died during the mating period in the southwest-

ern Finnish archipelago in the Baltic Sea (Kilpi et al., 1999). In the Utö-Jurmo area of the Archipelago Sea National Park, dead drakes were first observed in late April, a few weeks after the arrival of breeding pairs and at the time when the first hens were laying clutches and beginning incubation. Mortality continued for several weeks and the estimated number of carcasses in the Archipelago Sea reached thousands (Kilpi et al., 1999). Mostly males were affected. Sick birds were observed feeding in shallow lagoons before they moved to the shores and died. At the same time, females appeared to begin and continue incubation normally. Dead males were simultaneously reported from nearby waters in the Archipelago Sea National Park, but not from farther east in the Gulf of Finland or farther north in the Gulf of Bothnia.

Grenqvist et al. (1971) described a similar die-off of common eider males in the same geographic area in the spring of 1970 and diagnosed intestinal occlusion as the cause of death. Intestinal helminths were impli-

cated in only 14% of the carcasses, and contaminants analyses did not reveal toxic concentrations of trace elements in eider tissues (Grenqvist et al., 1971). Grenqvist et al. (1971) suggested that severe weather in the preceding winter led to poor body condition of males and predisposed them to the development of intestinal disturbances during the breeding period.

In 1998, weather conditions were not exceptionally severe, and yet a large die-off of male eiders occurred at the breeding grounds. As in 1970, toxic concentrations of trace elements were not detected in tissues collected from dead males (Franson et al., 2000). We conducted necropsies on ten male carcasses collected in 1998 and analyzed tissue samples for viruses and bacteria to evaluate the potential role of infectious diseases in the mortality. We collected serum samples and cloacal swabs from incubating eider females at the mortality site and analyzed tissue samples from males shot during the previous breeding season to evaluate the prevalence of viruses in apparently healthy eiders. We also infected mallard (*Anas platyrhynchos*) ducklings with an adenovirus isolated from one of the eider males to evaluate its potential gastrointestinal pathogenicity.

#### MATERIALS AND METHODS

Utö Archipelago (59°50'N, 21°25'E) is located in the Archipelago Sea National Park in the Baltic Sea approximately 50 km off the southwestern coast of Finland (Fig. 1). The area lies in the outer zone of the Finnish Archipelago and consists mainly of barren rocky islands with low, shrubby vegetation. In 1998, 3,259 common eider pairs were found to breed in the area (Hario, 2000). Dead eider males were first observed on the islands in mid-April and, by the end of the courtship period in May, approximately 1,000 dead males were counted in the archipelago, representing about 25% of the local male population. A few females ( $n=33$ ), some on their nests, were also found dead.

On May 11 and 12, carcasses of 10 male eiders were collected from the Utö area for post-mortem examination. Nine males were found dead, but one was captured moribund and blood was collected from this individual prior to necropsy. Blood was transferred to a plastic

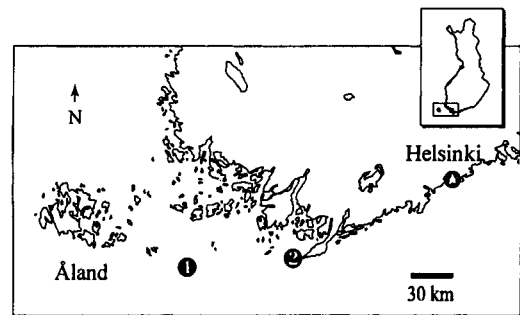


FIGURE 1. Location of the common eider male mortality site (1) and the reference site (2) where samples were collected in the Baltic Sea off the southwestern coast of Finland.

tube without anticoagulant and allowed to clot at 4 C for 2 hr. Serum was separated by centrifugation at 1,500×G for 10 min and stored at -80 C until laboratory analyses. Cloacal swabs collected from five carcasses with Dacron-tipped swabs (Fisher Scientific, Pittsburgh, Pennsylvania, USA) were transferred into virus transport media (Docherty and Slota, 1988). Female eiders ( $n=22$ ) nesting at Utö were captured with long-handled dipnets on May 11 and 12, and weighed. The incubation stage of each nest was determined by floating eggs in water (Kilpi and Lindström, 1997), and the number of eggs was recorded. Cloacal swabs and blood samples were collected from females as described for males.

Carcasses of the 10 males found dead were weighed and the amount of subcutaneous and visceral fat was evaluated. The type and amount of intestinal contents, and macroscopic tissue lesions were recorded. Samples of lung, liver, spleen, kidney, heart, duodenum, jejunum, ileum, and cecum from all of the 10 birds were fixed in 10% neutral buffered formalin, embedded in paraffin, sectioned at 5  $\mu$ m, and stained with hematoxylin and eosin for evaluation by light microscopy. Samples of lung, liver, spleen, kidney, small intestine, and cloaca were collected from all carcasses for virus isolation and samples of lung, liver, spleen, and small intestine were collected from five carcasses for bacterial cultures. The same suite of tissue samples for histopathology, virology, and bacteriology also had been collected from 14 apparently healthy hunter-killed common eider males from an area in coastal Finland (59°50'N, 22°50'E) (Fig. 1) in early June 1997. Tissue samples were stored at -80 C until laboratory analyses.

Samples for bacteriology were cultured aerobically on trypticase soy agar (LabM, Cockeysville, Maryland, USA) plates, containing 50

ml/l bovine blood, and anaerobically on fastidious anaerobe agar (LabM, Bury, UK) plates. Aerobic cultures were incubated at 37 C for 72 hrs and inspected at 24 hr intervals, and anaerobic cultures were incubated at 37 C for 96 hrs and inspected at 48 hr intervals. *Salmonella* enrichment was performed by inoculating samples in 10 ml Rappaport Vassiliadis (LabM, Bury, UK) broth and incubating at 42 C for 24 hrs. Ten  $\mu$ l of enrichment broth was transferred to Brolac (Merck, Darmstadt, Germany) and Önöz (Merck) agars, incubated at 37 C for 24 hrs, and inspected for growth of *Salmonella* sp.

Approximately 1 g of each lung, liver, spleen, kidney, small intestine, and cloaca was homogenized in 10 ml of virus transport media, and tissue suspensions were centrifuged at 800 $\times$ G for 30 min. The transport media vials containing cloacal swabs were mixed by vortexing, and a 0.5 ml aliquot of each was centrifuged at 800 $\times$ G for 15 min. All samples were tested individually. Muscovy duck (*Cairina moschata*) embryo fibroblast (MDEF) monolayers (Docherty and Slota, 1988) were inoculated with supernatants of each sample, incubated at 37 C for 7 days, and monitored daily for viral cytopathic effects (CPE). When no CPE was observed, samples were freeze-thawed, passaged to fresh cell monolayers, and monitored for an additional 7 days. The nucleic acid type of the isolated viruses was tested by determining their infectivity to MDEF cells after 5-iodo-2'-deoxyuridine treatment, and the presence or absence of lipoprotein envelope was evaluated with the chloroform lability test (Feldman and Wang, 1961). Positive tissue cultures were prepared for electron microscopy by one freeze-thaw, slow centrifugation at 800 $\times$ G for 30 min, and ultracentrifugation of the supernatant at 35,000 $\times$ G for 150 min. The viral pellets were resuspended in distilled water, placed on grids, negatively stained with 0.5% phosphotungstic acid, and examined with a Hitachi H-500 transmission electron microscope (Hitachi High Technologies, Tokyo, Japan). Viral hemagglutination activity was evaluated using chicken and turkey red blood cells (Rovozzo and Burke, 1973). One of the isolates was tested against avian adenovirus I (serotypes 1, 3, and 5) (Spafas Inc., Preston, Connecticut, USA), avian adenovirus II (hemorrhagic enteritis virus) (Spafas Inc.), and avian adenovirus III (egg drop syndrome virus, duck adenovirus serotype 1) (National Veterinary Services Laboratory, Ames, Iowa, USA) antiserum using a standard virus neutralization assay (Thayer and Beard, 1998).

Serial two-fold dilutions were prepared from heat inactivated (56 C for 30 min) serum samples collected from female eiders and tested with a standard virus neutralization assay

(Thayer and Beard, 1998) for antibodies against a virus isolated from a male eider carcass.

Twelve mallard hatchlings (Whistling Wings, Hanover, Illinois, USA) were randomly divided into two groups of six birds each and housed in 1 $\times$ 1 m brooder cages in separate isolation units with a 12/12 hr light/dark cycle. The temperature in the rooms was maintained at 16–26 C, and the relative humidity was within 40–70%. The birds were fed a commercial formula for ducklings (Purina<sup>®</sup> Duck Starter, St. Louis, Missouri, USA) *ad libitum*. At 3 days of age, the ducklings were weighed to the nearest 1 g, and blood samples were collected from the jugular vein with plastic syringes and 23 gauge needles. Serum was harvested as previously described and tested for neutralizing antibodies against the eider adenovirus isolate used in the infectivity trial (Thayer and Beard, 1998). The birds in the experimental group were inoculated subcutaneously with 5,000 infectious units (determined by mean tissue culture infective dose values) of the same isolate that was used in the neutralization assays and diluted in 0.25 mls of Hanks' balanced salt solution (BSS) with 0.5% glycerin. Control birds were inoculated subcutaneously with 0.25 mls of BSS with glycerin. The ducklings were monitored twice daily for clinical signs of illness. Two weeks post-infection, blood samples were collected from each duckling and tested for neutralizing antibodies against the virus. The ducklings were euthanized by cervical dislocation, weighed, and necropsied. Macroscopic tissue lesions were evaluated, and samples of thymus, lung, heart muscle, liver, spleen, kidney, duodenum, jejunum, ileum, cecum, and bursa of Fabricius were fixed in 10% neutral buffered formalin, processed, and stained with hematoxylin-eosin for histopathology. Tissue samples of lung, liver, spleen, kidney, intestine, cecum, and bursa of Fabricius were collected in virus transport media and processed for virus isolation in MDEF cell cultures.

## RESULTS

The mean ( $\pm$ SD) weight of the male carcasses found at Utö was 1,615 ( $\pm$ 198) g. Pectoral muscles were markedly reduced in all birds, and subcutaneous fat reserves were depleted in nine carcasses. Traces of orange-colored coronary and visceral fat were present in seven carcasses, but none was found in three carcasses. The liver was atrophied in all birds and slightly greenish in two birds. A pale, necrotic area approximately 0.5 cm in diameter was observed in the esophageal mucosa of two birds. The most remarkable lesion was in the proximal

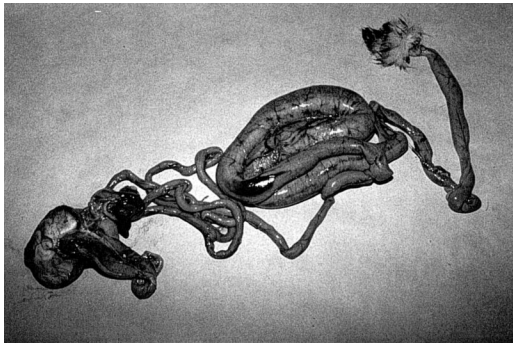


FIGURE 2. Intestinal impaction in the posterior small intestine in a common eider male in the Baltic Sea.

small intestine in all birds that were necropsied and consisted of a 45–60 cm long area of impaction that was 2.5–3.5 cm in diameter (Fig. 2). The content consisted of tightly packed mussel shell fragments and vegetation, in approximately equal volumes. The intestinal mucosa throughout the impacted area was necrotic and sloughing. In several birds, trematodes were embedded in the thin layer of the remaining lamina propria. Histologically, hepatocytes were atrophied and contained moderate amounts of greenish bile pigment. Necrosis of single hepatocytes in diffuse pattern was evident in two livers, and foci of coagulative necrosis were seen in one liver. No inclusion bodies were seen in the liver or other tissues. Epithelium of the proximal renal tubules was degenerate, and tubular lumens contained eosinophilic material. Lungs were congested. Pathologic lesions were not observed in the 14 apparently healthy males collected from the reference area in 1997.

Viruses were isolated from all five cloacal swabs collected from dead males at Utö and from the cloacal tissue collected at necropsy from one additional male found dead at Utö. Viral CPE developed in 5–6 days in the original inoculation and was first characterized by rounded-up cells. In approximately 1 wk, all cells had become necrotic and the entire monolayer of muscovy duck cells was destroyed. The isolates were characterized as nonenvelo-

ped DNA viruses and did not agglutinate chicken or turkey red blood cells. The mean ( $\pm$ SD) diameter of virus particles ( $n=8$ , representing three different isolates) was 67 ( $\pm$ 2.1) nm and the viral capsomeres were arranged in equilateral triangles characteristic of *Adenoviridae* (Horne et al., 1959). The virus was not neutralized by reference antiserum against avian adenovirus group I, II, or III viruses. Viruses were not isolated from other tissue samples from males found dead at Utö, from any of the tissue samples from male eiders collected in 1997, or from cloacal swabs collected from nesting females at Utö. No known pathogens were identified in bacterial cultures of any of the tissues.

The mean ( $\pm$ SD) incubation stage of females captured on nests was 5.6 ( $\pm$ 2.8) days and the mean ( $\pm$ SD) clutch size was 4.3 ( $\pm$ 1.0) eggs. The mean ( $\pm$ SD) weight of the females was 1,997 ( $\pm$ 246) g. Adenovirus antibody titer of  $\geq 1:128$  was found in one (4.5%) of the females. The serum sample collected from a sick male at Utö was negative ( $<1:8$ ) for adenovirus antibody.

On days 6–8 postinoculation, three of the six experimentally infected mallard ducklings were shivering and gasping, and watery feces were observed in their cage. After the 8th day, the ducklings appeared normal again. Four of the infected ducklings had antibody titers of 1:64 to 1:128 against the adenovirus at 14 days postinoculation. The remaining two infected ducklings had titers of 1:4 and  $<1:4$ , and all of the control ducklings were negative for antibodies (titers  $<1:4$ ). The mean ( $\pm$ SD) weight gain did not differ significantly between the infected ( $378 \pm 29.4$  g) and control ( $358 \pm 26.1$  g) group (Mann Whitney *U*-test). Intestinal lumens of five of the six infected ducklings were distended and had granular, grayish-yellow, and fluid contents. A mild, chronic inflammatory reaction was observed in the mucosa of the lower intestine and caeca of the infected ducklings. No viruses were isolated from mallard duckling tissues collected at 14 days postinoculation.

## DISCUSSION

We diagnosed intestinal impaction with mucosal necrosis as the cause of death in a sample of male eiders collected from a large mortality event in the southwestern Finnish archipelago of the Baltic Sea in 1998. Field observations and postmortem findings were similar to those reported from an eider die-off in the same geographic area in 1970 (Grenqvist et al., 1971), suggesting a similar etiology for the mortality events. In 1970, it was suggested that poor body condition and inability of male eiders to process large, rapidly ingested quantities of food after the courtship period led to intestinal disturbances and mortality. However, it seems unlikely that poor body condition alone would have predisposed large numbers of male eiders to intestinal impactions. Female eiders that interrupt incubation and abandon their nests due to poor body condition have been observed to feed intensively and recover their body condition rapidly, without developing impactions that lead to mortality (Öst and Kilpi, 1999). Grenqvist et al. (1971) also suggested the possibility of other contributing factors, such as parasites, in the intestinal impactions, but concluded that the low prevalence (14%) of intestinal helminths probably did not increase mortality significantly. We isolated an adenovirus from cloacal samples collected from six of 10 dead males at Utö in 1998, but from none of 14 apparently healthy hunter-killed males collected in 1997. Furthermore, the eider adenovirus was associated with clinical signs of gastrointestinal disease in mallard ducklings under experimental conditions. The virus from one bird tested was not neutralized with antisera against fowl adenoviruses, hemorrhagic enteritis virus of turkeys, or egg drop syndrome virus and may represent a new duck serotype. Based on these results, we hypothesize that an adenovirus was involved in the eider mortality event in 1998, although the exact role of the virus remains speculative.

Adenoviruses have been associated with gastrointestinal lesions and disease in several avian species and have also been suggested as part of a multiple etiology rather than primary disease agents (McFerran and Adair, 1977; Lenz et al., 1998). The fact that the eider adenovirus did not cause mortality in experimentally infected mallards could be due to the lack of environmental stressors or other co-factors required by the virus, although differences in host species' susceptibility or the relatively low, parenteral dosage that was used in the experiment may also have affected viral pathogenicity. In the wild, the stress and close contacts among individuals associated with the courtship period provides ideal conditions for virus transmission and replication within the flocks. Based on carcass weight, the dead males were in poorer body condition than apparently healthy hunter-killed males from a reference area (mean  $\pm$  SD = 2,270  $\pm$  143 g,  $n=12$ ; Franson et al., 2000). The reason for the poor body condition of males remains unknown, but may be related to their feeding behavior during the courtship period or to the virus infections. It is also possible that latent infections were reactivated in male eiders undergoing weight loss and physiologic stress. Antibody was not detected in the serum of one affected male, which may reflect recent exposure or inability of males in poor body condition to raise antibodies and control virus infections.

The low level of mortality or apparent absence of disease in eider females breeding in the area is of interest and suggests that local food items did not contain toxins or other substances that paralyzed intestinal function in eiders. Otherwise, a higher prevalence of illness would be expected in females that feed intensively in the same area prior to nest initiation. One of 22 females captured on the nests during early incubation had antibody to the adenovirus but virus isolation attempts from cloacal swabs were negative, indicating that none of the captured females were shedding vi-

ruses or were shedding at a very low level. If females maintain their body condition during the courtship period they also may be able to raise and maintain an immune response to control viral infections better than the males in poor body condition. The mean ( $\pm$ SD) weight and clutch size of eider females at Utö were similar to females incubating at a reference area ( $1,964 \pm 221$  g and  $4.7 \pm 1.0$  eggs,  $n=19$ ; M. Kilpi, unpubl. data), suggesting that their body condition prior to nest initiation was maintained at a normal level. Another possible explanation for the difference in mortality rates between male and female eiders may be associated with the incubation fast. At the peak of the mortality, most females were already on their nests, and the changes in intestinal motility that accompany the incubation fast may have altered the pathogenicity of the virus. Also, while males concentrate in flocks prior to moving to the molting areas, the females infrequently contact other birds after nest initiation allowing fewer opportunities for virus transmission.

The large proportion of vegetation in the intestinal contents led us to speculate that interactions between infectious diseases and changes in the environment could also play a role in the mortality events. Blue mussels (*Mytilus edulis*) are the preferred food of Baltic eiders and, when mussels are abundant, the eiders feed primarily on them (Öst and Kilpi, 1998). In some areas of the Baltic Sea, algae of *Cladophora* sp. have markedly increased in density during the recent decades as a result of eutrophication (Vahteri et al., 2000). In the affected areas, such as those surrounding the Utö archipelago, the vegetation covers musselbeds in the bottom of the waterbed and eiders feeding on mussels inevitably also ingest large quantities of algae. Skirnisson et al. (2000) estimated that vegetable matter constituted approximately 3.7% of common eider diet in Iceland, and found vegetation in only 7% of eider intestines. Our estimate of male eider intestines containing 50% of

vegetation is much higher. The digestibility of algae in eiders is not known, but diet changes have been shown to decrease absorption rates of nutrients in sea birds (Hilton et al., 2000) and could potentially contribute to intestinal disturbances.

Problems in differentiating proximate from ultimate causes of death are widely acknowledged in wildlife disease investigations (see Wobeser, 1994). A disease syndrome may be caused by a combination of several pathogens, environmental factors, and physiologic status of the host, and a multifactorial etiology seems likely also in the common eider male mortality in the Baltic Sea. Although it is possible that the adenoviruses isolated from eider males were associated with a latent infection reactivated by other environmental stressors, the adenoviruses appear the most prevalent potential etiologic agent found in the carcasses. Viruses were not isolated from cloacal samples collected from apparently healthy eider females nesting at the mortality site or from apparently healthy male eiders shot by hunters on coastal Finland near the eastern border of the Archipelago Sea National Park. Known pathogens were not isolated from bacterial cultures from either the males found dead or in the reference material. Although trematodes, cestodes, and acanthocephalans were also identified in the intestinal tracts of the dead male eiders, they were found in relatively low intensities (T. Hollmén, unpubl. data; for methods, see Sloss et al. 1994) and it appears unlikely that they contributed to the mortality in a significant manner. Grenqvist et al. (1971) also concluded in their investigation of a similar event in the same area in 1970 that the prevalence and intensity of intestinal parasites was low, and that parasites could not be considered the cause of the intestinal disturbance. Concentrations of trace elements found in die-offs in 1970 (Grenqvist et al., 1971) and in 1998 were relatively low and not considered directly responsible for the mortality of male eiders. Therefore, it is possible that viral epidemics con-

tribute to the described intestinal dysfunction and increase mortality of breeding male eiders in some years in the Baltic Sea, and that the low-level mortality observed in other years is primarily related to the poor body condition of birds. Experimental infectivity trials in eiders, and further comparisons of body condition and the prevalence of viruses between years of low and high mortality rates are needed to test the hypothesis that adenoviruses are a significant etiological factor in the mortality events of male common eiders breeding in the Baltic Sea.

#### ACKNOWLEDGMENTS

We thank J. Högmänder, M. Nordström, V. Ranki, and W. Velmala for assistance with sample collection, and K. Jaquish, R. Long, and T. Pankasalo for assistance with the laboratory analyses. Funding support was provided by the Academy of Finland and the American-Scandinavian Foundation.

#### LITERATURE CITED

- CHRISTENSEN, T. K. 2000. Female pre-nesting foraging and male vigilance in common eider *Somateria mollissima*. *Bird Study* 47: 311–319.
- DOCHERTY, D. E., AND P. G. SLOTA. 1988. Use of muscovy duck embryo fibroblasts for the isolation of viruses from wild birds. *Journal of Tissue Culture Methods* 11: 165–170.
- FELDMAN, H., AND S. WANG. 1961. Sensitivity of various viruses to chloroform. *Proceedings of the Society of Experimental Biology and Medicine* 106: 736–738.
- FRANSON, J. C., T. HOLLMÉN, R. H. POPPENG, M. HARIO, AND M. KILPI. 2000. Metals and trace elements in tissues of common eiders (*Somateria mollissima*) from the Finnish archipelago. *Ornis Fennica* 77: 57–63.
- GRENQVIST, P., K. HENRIKSSON, AND T. RAITIS. 1971. Haahkakoiraideen suolitukkeumasta. On intestinal occlusion in male eider ducks. *Suomen Riista* 16: 91–96. [In Finnish with English summary].
- HARIO, M. 2000. Haahkan, ruokkilintujen, kalatiiran ja lapintiiran runsaus Suomen rannikolla 1999. The archipelago birds census in 1999: Recent trends of common eiders, alcids, and sea terns in Finland. *In* The yearbook of the Linnut magazine. T. Solonen and E. Lammi (eds.). *Birdlife Finland, Kuopio, Finland*, pp. 40–50. [In Finnish with English summary].
- , AND K. SELIN. 1986. Mitä pesinnän ajoittuminen kertoo haahkan menestymisestä Suomenlahdella A 30 year change in the breeding time of the common eider in the Gulf of Finland. *Suomen Riista* 33: 19–25. [In Finnish with English summary].
- HILTON, G. M., R. W. FURNESS, AND D. C. HOUSTON. 2000. The effects of diet switching and mixing on digestion in sea birds. *Functional Ecology* 14: 145–154.
- HORNE, R. W., S. BRENNER, A. P. WATERSON, AND P. WILDY. 1959. The icosahedral form of an adenovirus. *Journal of Molecular Biology* 1: 84–86.
- KILPI, M., AND K. LINDSTRÖM. 1997. Habitat-specific clutch size and cost of incubation in common eiders, *Somateria mollissima*. *Oecologia* 111: 297–301.
- , T. HOLLMÉN, AND J. C. FRANSON. 1999. Varför dör ejdraman? Skärgård 2: 21–22.
- LENZ, S. D., F. J. HOERT, A. C. ELLIS, M. A. TOIVIO-KINNUNAN, AND M. YU. 1998. Gastrointestinal pathogenicity of adenoviruses and reoviruses isolated from broiler chickens in Alabama. *Journal of Veterinary Diagnostic Investigations* 10: 145–151.
- MCFERRAN, J. B., AND B. MCC. ADAIR. 1977. Avian adenoviruses—A review. *Avian Pathology* 6: 189–217.
- ÖST, M., AND M. KILPI. 1998. Blue mussels *Mytilus edulis* in the Baltic: Good news for foraging eiders *Somateria mollissima*. *Wildlife Biology* 4: 81–89.
- , AND ———. 1999. Parental care influences the feeding behavior of female eiders *Somateria mollissima*. *Annales Zoologici Fennici* 36: 195–204.
- ROVOZZO, G. C., AND C. N. BURKE. 1973. Serologic techniques. *In* A manual of basic virological techniques. Prentice-Hall, Inc., Englewood Cliffs, New Jersey, pp. 94–125.
- SKIRNISON, K., A. Á. JÓNSSON, A. SIGFÚSSON, AND S. SIGURÐARSON. 2000. Árstíðabreytingar í fæðuvali æðarfugla á Skerjafirði. Food composition of the common eider in Skerjafjörður. *Bliki* 21: 1–14. [In Icelandic with English summary].
- SLOSS, M. W., R. L. KEMP, AND A. M. ZAJAC. 1994. *Veterinary clinical parasitology*, 6th Edition, Iowa State Press, Ames, Iowa, 208 pp.
- THAYER, S. G., AND C. W. BEARD. 1998. Serologic procedures. *In* A laboratory manual for the isolation and identification of avian pathogens, 4th Edition, D. E. Swayne, J. R. Glisson, M. W. Jackwood, J. E. Pearson and W. M. Reed (eds.). American Association of Avian Pathologists, Kennett Square, Pennsylvania, pp. 255–266.
- VAHTERI, P., A. MÄKINEN, S. SALOVIUS, AND I. VUORINEN. 2000. Are drifting algal mats conquering the bottom of the Archipelago Sea, SW Finland? *Ambio* 29: 338–343.
- WOBESER, G. A. 1994. *Investigation and management of disease in wild animals*. Plenum Press, New York, USA, 265 pp.

Received for publication 4 September 2001.