



## **CELLULAR RESPONSE IN THE DERMIS OF COMMON WOMBATS (*VOMBATUS URSINUS*) INFECTED WITH *SARCOPTES SCABIEI* VAR. *WOMBATI***

Author: Skerratt, Lee F.

Source: Journal of Wildlife Diseases, 39(1) : 193-202

Published By: Wildlife Disease Association

URL: <https://doi.org/10.7589/0090-3558-39.1.193>

---

BioOne Complete ([complete.BioOne.org](https://complete.BioOne.org)) is a full-text database of 200 subscribed and open-access titles in the biological, ecological, and environmental sciences published by nonprofit societies, associations, museums, institutions, and presses.

Your use of this PDF, the BioOne Complete website, and all posted and associated content indicates your acceptance of BioOne's Terms of Use, available at [www.bioone.org/terms-of-use](https://www.bioone.org/terms-of-use).

Usage of BioOne Complete content is strictly limited to personal, educational, and non - commercial use. Commercial inquiries or rights and permissions requests should be directed to the individual publisher as copyright holder.

---

BioOne sees sustainable scholarly publishing as an inherently collaborative enterprise connecting authors, nonprofit publishers, academic institutions, research libraries, and research funders in the common goal of maximizing access to critical research.

## CELLULAR RESPONSE IN THE DERMIS OF COMMON WOMBATS (*VOMBATUS URSINUS*) INFECTED WITH *SARCOPTES SCABIEI* VAR. *WOMBATI*

Lee F. Skerratt<sup>1,2,3</sup>

<sup>1</sup> University of Melbourne, School of Veterinary Science, Veterinary Clinical Centre, 250 Princes Highway, Werribee, Victoria 3030, Australia

<sup>2</sup> Current address: US Department of the Interior, US Geological Survey, National Wildlife Health Center, 6006 Schroeder Rd, Madison, Wisconsin 53711, USA

<sup>3</sup> Corresponding author (email: lskerratt@usgs.gov)

**ABSTRACT:** The cellular response in the dermis of common wombats (*Vombatus ursinus*) with sarcoptic mange exhibited some typical aspects of an immune response to *Sarcoptes scabiei*. There was an induction phase for wombats experimentally infected with *S. scabiei* represented by absence of a dermal inflammatory infiltrate for at least 12 days after infection. T lymphocytes, plasma cells, mast cells, and neutrophils then entered the dermis, consistent with a type IV (delayed) hypersensitivity response. In free-living wombats with severe parakeratotic sarcoptic mange eosinophils were also present in the dermis suggesting that a type I (immediate) hypersensitivity response may develop after a type IV hypersensitivity response. Absence of plasma cells and B lymphocytes in free-living wombats with severe parakeratotic sarcoptic mange compared with their presence in wombats experimentally infected with *S. scabiei* suggested that some immune tolerance may develop with severe infections. A large proportion of cells in the dermal response were not identified but were possibly cells of connective tissue. The thickness of the epidermis increased within 4 days in response to *S. scabiei* infection. Some antibodies raised against human leucocyte antigens CD3, CD5, HLA-DP, DQ, DR, and CD79b cross-reacted with leucocyte antigens of common wombats and were used to identify cell types in inflammatory infiltrates using immunohistochemistry.

**Key words:** Common wombat, cross-reactive antibodies, immunohistochemistry, inflammatory response, *Sarcoptes scabiei*, sarcoptic mange, *Vombatus ursinus*.

### INTRODUCTION

Histopathology of the skin of wombats with sarcoptic mange has been described (Skerratt, 1998). However, the cellular immune response in the dermis has not been quantified even though it appears to regulate the intensity of *S. scabiei* in other animals (Davis and Moon, 1990a; Arlian et al., 1994, 1996a, 1997; Arlian, 1996). The dermal cellular immune response to *S. scabiei* infection has been examined in humans and animals including rabbits, dogs, foxes, chamois, and pigs (Sheahan, 1975; Ackerman, 1985; Van Neste, 1986; Morsy and Gaafar, 1989; Arlian et al., 1994, 1996a, 1997; Arlian, 1996; Little et al., 1998; Rode et al., 1998). Whilst marsupials have an immune system similar to that of eutherian mammals (Croix et al., 1989) differences have been identified such as slower antibody responses in some metatherians including wombats (Johnson et

al., 1989; Wilkinson et al., 1992; Skerratt et al., 1997), suggesting that differences may exist in the immune response of wombats to *S. scabiei* that affect its ability to regulate the abundance of mites. In this study, conventional staining methods as well as immunohistochemistry using antibodies raised against conserved antigens were used to identify cell types in the dermis of common wombats infected with *S. scabiei*. The immunohistochemical staining of T and B lymphocytes of Australian marsupials such as the koala (*Phascogaleus cinereus*), brushtail possum (*Trichosurus vulpecula*), tammar wallaby (*Macropus eugenii*), and ringtail possum (*Pseudocheirus peregrinus*) has been achieved using antibodies raised against intracytoplasmic regions of receptors such as CD3 and CD79b of human T and B lymphocytes (Hemsley et al., 1995; Wilkinson et al., 1995), suggesting that these antibodies may also identify T and B lymphocytes of

wombats. However, anti-human cell antibodies, such as anti-human leucocyte common antigen did not stain wombat leucocytes (Byard et al., 1998). Immunohistochemistry using the avidin-biotin-peroxidase method has been employed successfully in studies of tissues of the southern hairy-nosed wombat (*Lasiorhinus latifrons*) with anti-human protein antibodies, such as antibodies raised against desmin, myoglobin, vimentin, glial fibrillary acidic protein, S100 protein, and keratin (Byard et al., 1998).

## MATERIALS AND METHODS

### Animals and tissues

**Free-living wombats with severe sarcoptic mange:** Ten free-living wombats with severe parakeratotic sarcoptic mange were collected and euthanized (see Skerratt et al., 1999). Three free-living wombats without sarcoptic mange that had been hit on a road by a vehicle or shot by landowners were also collected for comparison. The entire skin of each wombat was removed and a 7 mm diameter skin biopsy punch attached to a drill was used to remove cores of skin from six sites that had significantly different intensities of infection, (Numbers 7–12, Fig. 1) (see Skerratt et al., 1999 for numbers of mites at each site). Biopsies were fixed in Bouin's fixative and then transferred to 70% alcohol prior to histologic sectioning and staining. Two samples of each of the following tissues were also collected; spleen, peripheral lymph node (PLN), and mesenteric lymph node (MLN). One sample of each tissue was fixed in Bouin's fixative. The other was frozen in OCT medium (Tissue-Tek, Indianapolis, Indiana, USA) in cryomolds (Tissue-Tek) in liquid nitrogen in case fixation of tissues in Bouin's fixative adversely affected immunohistochemical staining. Frozen tissues were stored at  $-70^{\circ}\text{C}$  prior to histologic sectioning on a cryostat and staining.

**Captive wombats experimentally infected with *S. scabiei*:** Seven captive common wombats were experimentally infected with 1,000–5,000 mites, *S. scabiei* var. *wombati* on their shoulders. The mean intensities of infection at 0 and 77 days after infection (DAI) on the shoulder were  $9 \pm 1$  and  $1,244 \pm 458$  mites/cm<sup>2</sup> ( $\pm$  standard error,  $n=7$ ), respectively. Four captive wombats were not infected and acted as controls (see Skerratt et al., 2003 for methods on counting mites). Biopsies of skin, 7mm diameter, were taken during the course of the

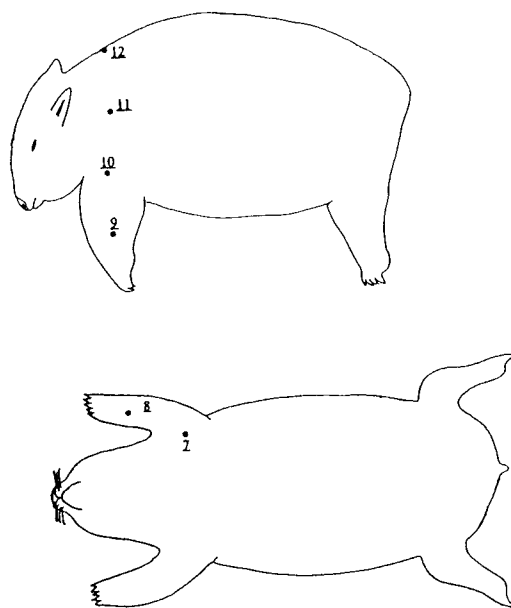


FIGURE 1. Sites on lateral surfaces, along the dorsal midline and on the ventral surface of common wombats from which 7 mm diameter biopsies were taken. The number of a site is underlined (Numbers 7–12).

experiment (0, 1, 4, 12, 19, 34, and 77 DAI) from the shoulders of wombats infected with mites and from control wombats (corresponding to site 10 in Fig. 1) and fixed in Bouin's fixative prior to histologic sectioning and staining. Biopsy wounds were sutured with nylon suture material (Vetafil, Bengen, Germany).

### Cellular characterization

**Histologic staining:** Histologic sections were cut at 4  $\mu\text{m}$  from fixed tissues embedded in paraffin or from frozen tissues embedded in OCT medium. Sections of fixed skin biopsies were stained with hematoxylin and eosin to examine the total number of cells and percentage of polymorphonuclear cells in the dermal infiltrate. To enable ready differentiation of inflammatory cell types, histologic sections of fixed skin biopsies were stained with alcian blue, Trakris, or toluidine blue to examine the number of mast cells in the dermal infiltrate (differentially stained cytoplasm of mast cells blue or purple, respectively; Lillee and Fulmer, 1976; Henwood, 1994). Chromotrope 2R stain was used to evaluate numbers of eosinophils (stained eosinophil granules bright red). Briefly, 1 g phenol crystals was dissolved in 5–10 ml Sorenson's phosphate buffer, 0.5 g chromotrope was added and dissolved, and then the

remaining buffer was added and mixed. Histologic sections were stained in chromotrope solution for 20–30 min, rinsed in clean water for 2 min, and counterstained with methylene blue for 10–15 sec. Methyl green-pyronin stain was used to determine the number of plasma cells (stained RNA in plasma cells pink) (Sheehan and Hrapchak, 1980). Positive tissue controls for these stains were, respectively, a mast cell tumor in a dog, eosinophilic dermatitis in a horse, an eosinophilic granuloma in a cat, and plasmacytic enteritis and chronic dermatitis in a dog. The negative tissue control was blood from captive common wombats in which no cells were stained apart from the occasional eosinophil. To further differentiate inflammatory cell types, immunohistochemistry was used.

**Immunohistochemistry:** Tissue sections on glass slides were labelled and circumscribed with a diamond edged marker to demarcate the area to be used for immunohistochemistry and to localize reagents to the defined area. Histologic sections of paraffin embedded tissues on glass slides were then loaded into racks and paraffin removed by immersion in xylene. Sections were rehydrated gradually using graded alcohols and “quenched” for endogenous peroxidase activity with 0.3% hydrogen peroxide in phosphate buffered saline (PBS) for 10 min. Histologic sections of frozen tissues were fixed in acetone at 4 C and “quenched” for endogenous peroxidase activity with 0.3% hydrogen peroxide for 10 min. Fixed and frozen histologic sections were then incubated with normal sheep serum at a 1:20 dilution with PBS to block non-specific binding sites of primary antibodies. Excess sheep serum was drained from the slide prior to application of the primary antibody. A number of primary polyclonal or monoclonal antibodies, some of which have been shown to have interspecies reactivity, were tested initially to determine the most sensitive and specific for identification of cell types such as T and B cells (Table 1). Serial dilutions of these antibodies were used in order to determine the dilution that minimized background staining but differentially stained target cells (Table 1). Both the blocking agent and the primary antibody were applied with a 100  $\mu$ l pipette until the entire tissue section was covered. The Dako Envision System (Dako, Carpinteria, California, USA) was then used to visualize cells to which primary antibodies had adhered (the cytoplasmic margins of immunopositive cells were brown). In the first step, sections were incubated with the secondary antibody conjugated to a peroxidase labelled polymer, in the second step conjugate binding was determined by application of 3,3'-diaminobenzidine (DAB) chromogen. Incubation times for

the blocking agent and the primary and secondary antibodies were either 30 or 60 min at 24 C and this was carried out at high humidity to prevent tissue sections from drying out. Tissue sections were washed twice in PBS for 5 min after primary and secondary antibody incubations. Rabbit immunoglobulin (Dako, Glostrup, Denmark) was used as a negative control. Sections were counterstained with hematoxylin in order to highlight the nuclei of cells.

### Cell counts

Cells in the dermis immediately below the epidermal-dermal junction were counted with an ocular 10 $\times$ 10 square grid, 0.023 mm<sup>2</sup>, at 400 $\times$  magnification using a compound microscope (Olympus, Tokyo, Japan). For each histologic section the number of stained cells and the total number of cells in a grid were counted. To increase the accuracy of the estimate of cellular density, if few stained cells were present, additional grids were counted until at least 10 stained cells had been counted in total. The thickness of the epidermis was also measured with the grid. Cells in areas of dermis directly below ulcerated epidermis were not counted.

## RESULTS

### Dermal inflammatory response to *S. scabiei*

Free-living wombats with severe sarcoptic mange exhibited a significant inflammatory cellular response in the upper dermis when compared with normal wombats (Table 2). Histopathologic changes in the skin were similar to those described by Skerratt (1998) for wombats with severe sarcoptic mange. There were significantly more neutrophils, eosinophils, T lymphocytes, mast cells, and total cells in the dermis of free-living wombats with severe sarcoptic mange compared with normal wombats (Table 2). A moderate percent ( $29.7 \pm 1.8\%$ ) of the cells in the dermis were mast cells, T lymphocytes, eosinophils, and neutrophils with mast cells and T lymphocytes comprising  $14.2 \pm 1.2\%$  and  $9.5 \pm 0.9\%$ , respectively. Eosinophils and neutrophils were present at much lower percentages,  $3.2 \pm 0.8\%$  and  $2.8 \pm 0.6\%$ , respectively. Occasionally a plasma cell or B cell was present. The vast majority of cells in the response were not identified using

TABLE 1. Type, source, specificity, dilution, and results of primary antibodies used in immunohistochemical staining of common wombat tissues.

Antibody	Specificity	Dilutions <sup>a</sup>	Immunopositive cells
<i>Polyclonal</i>			
Rabbit anti-human T cell, CD3 <sup>b</sup>	T lymphocytes. Reacts with intracytoplasmic domain of CD3 epsilon chain (Mason et al., 1989).	1:10, 1:50, 1:100, 1:500, 1:1,000	+
Rabbit anti-koala IgG <sup>c</sup>	Plasma cells (Wilkinson et al., 1991).	1:1,000, 1:2,000, 1:5,000, 1:10,000, 1:20,000	—
<i>Monoclonal</i>			
Mouse anti-human B cell, CD79a <sup>b</sup>	B lymphocytes and plasma cells. Reacts with intracytoplasmic C-terminal part of mb-1 protein (Mason et al., 1992).	1:10, 1:50, 1:100	—
Mouse anti-human B cell, CD79b <sup>d</sup>	B lymphocytes. Reacts with intracytoplasmic part of B29 protein (Mason et al., 1992).	1:10, 1:50, 1:100	+
Mouse anti-human HLA-DR, DQ, DR <sup>d</sup>	Principally B lymphocytes, activated T lymphocytes and a variety of other cells. Reacts with beta chain of products of gene subregions DP, DQ and DR (Ghosh et al., 1984).	1:10, 1:50, 1:100	+
Mouse anti-human T cell, CD3 <sup>d</sup>	T lymphocytes. Reacts with intracytoplasmic domain of CD3 epsilon chain (Mason et al., 1989).	1:10, 1:50, 1:100, 1:500	+
Mouse anti-human T cell CD5 <sup>d</sup>	Principally T lymphocytes and small proportion of tissue B lymphocytes (Kroese et al., 1992).	1:10, 1:50, 1:100, 1:500	+
Mouse anti-human T cell, CD8 <sup>d</sup>	T lymphocytes.	1:10, 1:50, 1:100	—
Mouse anti-human CD68 <sup>d</sup>	Macrophages.	1:10, 1:50, 1:100	—
Mouse anti-human BCL-2 <sup>d</sup>	Lymphocytes. Reacts with protein produced by BCL-2 gene.	1:10, 1:50, 1:100	—

<sup>a</sup> Serial dilutions were used in order to determine the dilution that minimised background staining but differentially stained cells (optimal dilution underlined).

<sup>b</sup> Produced by Dako, Glostrup, Denmark.

<sup>c</sup> Produced by Central Veterinary Laboratories, Department of Agriculture, Adelaide, South Australia, Australia.

<sup>d</sup> Produced by LRF Immunodiagnostics Unit, Department of Clinical Biochemistry and Cellular Science, University of Oxford, Oxford, UK.

TABLE 2. Mean numbers  $\pm$  standard errors of mites and types of cells in the upper dermis of naturally infected free-living common wombats with sarcoptic mange at sites Numbers 7–12 in Figure 1 compared with normal common wombats.

	Wombats	
	Mangy ( <i>n</i> =10)	Normal ( <i>n</i> =3)
Mites (/cm <sup>2</sup> )	1,540 <sup>a</sup> $\pm$ 270	0
Cells (/mm <sup>2</sup> )	5,230 <sup>a</sup> $\pm$ 270	2,450 $\pm$ 160
Neutrophils (/mm <sup>2</sup> )	170 <sup>a</sup> $\pm$ 43	5 $\pm$ 5
Eosinophils (/mm <sup>2</sup> )	239 <sup>a</sup> $\pm$ 65	0
T cells (/mm <sup>2</sup> )	604 <sup>a</sup> $\pm$ 75	291 $\pm$ 69
Mast cells (/mm <sup>2</sup> )	640 <sup>a</sup> $\pm$ 63	338 $\pm$ 28

<sup>a</sup> Indicates significant difference ( $P<0.05$ , Student's *t*-test).

differential stains but appeared to be cells of connective tissue such as fibroblasts. There were significant correlations ( $P<0.05$ ) between the number of mites in the epidermis and the total number of cells in the dermis ( $r=0.70$ ,  $n=58$ ), the number of T lymphocytes ( $r=0.69$ ,  $n=58$ ), and the number of eosinophils ( $r=0.55$ ,  $n=58$ ).

Captive wombats experimentally infected with *S. scabiei* also developed a significant inflammatory cellular response in the dermis compared with control wombats 77 DAI (Table 3). There were significant increases in the number of T lymphocytes, plasma cells, and the total number of cells in the dermis of infected wombats compared with control wombats (Table 3). There was a significant increase in the number of mast cells in infected wombats but this change was not significant when compared with control wombats (Table 3). There was an increase in the number of neutrophils in infected wombats but this was not significant nor was the change significant when compared with the change in control wombats (Table 3). There was a slight increase in the number of eosinophils in infected wombats but it was not significant (Table 3). T lymphocytes, plasma cells, mast cells, and neutrophils did not start to increase within the dermis until 12 DAI whereas the epidermis began to increase in thickness immediately (Fig. 2).

TABLE 3. Numbers of various cell types per mm<sup>2</sup> in the upper dermis and thickness of the epidermis ( $\mu$ m) in common wombats experimentally infected with *Sarcoptes scabiei* var. *wombati* and in control wombats on days 0 and 77 after infection.

Cell type	Infected ( <i>n</i> =7)			Controls ( <i>n</i> =4)		
	Day 0	Day 77	Change	Day 0	Day 77	Change
Neutrophils (/mm <sup>2</sup> )	0	742 $\pm$ 439	742 $\pm$ 439	0	44 $\pm$ 26	44 $\pm$ 26
Eosinophils (/mm <sup>2</sup> )	0	6 $\pm$ 6	6 $\pm$ 6	0	0	0
T Lymphocytes (/mm <sup>2</sup> )	120 <sup>a</sup> $\pm$ 30	1,080 <sup>a</sup> $\pm$ 251	960 <sup>b</sup> $\pm$ 272	67 $\pm$ 22	56 $\pm$ 33	-11 <sup>b</sup> $\pm$ 28
Mast cells (/mm <sup>2</sup> )	216 <sup>a</sup> $\pm$ 23	502 <sup>a</sup> $\pm$ 95	286 $\pm$ 109	322 $\pm$ 80	356 $\pm$ 101	34 $\pm$ 84
Plasma cells (/mm <sup>2</sup> )	0 <sup>a</sup>	400 <sup>a</sup> $\pm$ 50	400 <sup>b</sup> $\pm$ 50	0	0	0 <sup>b</sup>
Total cells (/mm <sup>2</sup> )	1,619 <sup>a</sup> $\pm$ 127	7,149 <sup>a</sup> $\pm$ 1,660	5,530 <sup>b</sup> $\pm$ 1,660	2,122 $\pm$ 109	2,333 $\pm$ 645	211 <sup>b</sup> $\pm$ 631
Thickness of epidermis ( $\mu$ m)	34 <sup>a</sup> $\pm$ 3	321 <sup>a</sup> $\pm$ 53	287 <sup>b</sup> $\pm$ 53	26 $\pm$ 4	25 $\pm$ 4	2 <sup>b</sup> $\pm$ 2

<sup>a,b</sup> Numbers sharing a superscript letter in the same row were significantly different ( $P<0.05$ ).



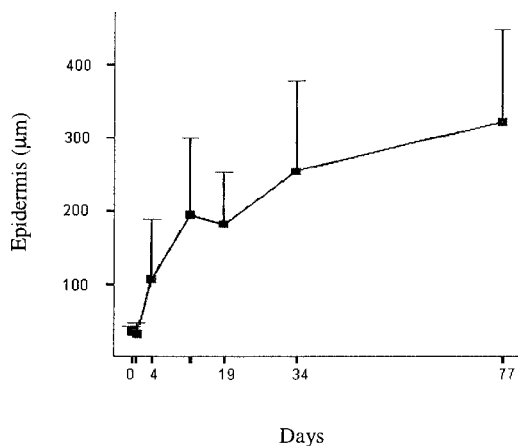


FIGURE 2. Change in epidermal thickness ( $\mu\text{m}$ ) with time in common wombats ( $n=7$ ) experimentally infected with 1,000 to 5,000 *Sarcoptes scabiei* var. *wombati*. Epidermal thickness did not change in control wombats (Table 3). Error bars show 95% confidence interval of means.

Almost half ( $44.5 \pm 2.0\%$ ) of the dermal cellular response in captive wombats 77 DAI were T lymphocytes ( $18.9 \pm 2.2\%$ ), mast cells ( $9.9 \pm 1.9\%$ ), plasma cells ( $8.9 \pm 1.3\%$ ), and neutrophils ( $6.8 \pm 2.7\%$ ). Eosinophils were absent. The majority of cells were not identified using differential stains but they were probably connective tissue cells.

#### Immunohistochemistry

Assuming that the anatomical distribution of lymphocytes in lymphoid tissue in wombats is typical of other marsupials, then excellent consistent differential staining of T lymphocytes occurred in histologic sections of fixed spleen, PLN, MLN, and skin with polyclonal antibodies anti-CD3 up to 1:1,000 dilution and monoclonal antibodies anti-CD5 up to 1:500 dilution (Table 1). Monoclonal anti-CD3 also differentially stained T lymphocytes but less strongly and consistently at a 1:100 dilution. Consistent differential staining of B lymphocytes occurred with the monoclonal antibody anti-CD79b at a 1:10 dilution whereas poor differential staining of B lymphocytes occurred with the monoclonal antibody anti-HLA at a 1:10 dilution.

Monoclonal anti-CD79b at a 1:25 dilution faintly stained cells in skin that had the appearance of macrophages or mast cells rather than B cells. Monoclonal antibodies anti-CD79a, anti-CD8, anti-CD68, and anti-BCL-2 and polyclonal anti-koala IgG did not differentially stain any cells in histologic sections of fixed spleen, PLN, MLN, and skin. The antibodies were also tested on histologic sections of frozen tissues. Polyclonal anti-CD3 stained T lymphocytes but less strongly than in fixed tissues; monoclonal anti-HLA differentially stained B lymphocytes at a 1:100 dilution but the remainder of the monoclonal antibodies anti-CD5, anti-CD79a, anti-CD79b, anti-CD8, anti-CD68, and anti-BCL-2 and polyclonal antibodies anti-koala IgG did not differentially stain cells. Rabbit immunoglobulin did not stain cells in fixed or frozen histologic sections of spleen, PLN, MLN, and skin. There was some background staining of connective tissues noted in most tissue sections but this did not affect the interpretation of staining of cells.

Based on sensitivity and specificity of the polyclonal antibodies, anti-CD3 was used to stain T lymphocytes in the dermis of wombats with sarcoptic mange with rabbit immunoglobulin as a negative control. Monoclonal anti-CD79b was used to stain B lymphocytes in the dermis of wombats with sarcoptic mange with monoclonal anti-CD79a as a negative control.

#### DISCUSSION

The cellular immune response in the dermis of wombats exhibited typical aspects of an immune response to *S. scabiei* (Davis and Moon, 1990a). There was an induction phase for wombats experimentally infected with *S. scabiei* represented by the absence of a dermal inflammatory infiltrate for at least 12 DAI. In contrast, as in rabbits (Arlian et al., 1994), the epidermis started to thicken the day after mites burrowed into it suggesting that the burrowing of mites is responsible for epidermal stimulation and increased produc-

tion of keratinocytes. T lymphocytes were present as a relatively large proportion of the dermal inflammatory response in both free-living wombats with severe sarcoptic mange and wombats experimentally infected with *S. scabiei*. They are a consistent feature of the dermal inflammatory response to *S. scabiei* and generally reflect the development of a type IV hypersensitivity reaction (Arlian, 1996). The numbers of T lymphocytes in the dermis of wombats were correlated with the intensity of mites, suggesting that T lymphocytes responded to the numbers of mites or products of mites. Similarly, densities of lymphocytes were greater in older versus younger lesions in humans with scabies (Falk and Matre, 1982).

Mast cells were also present in relatively large numbers in wombats and have been reported to migrate to the dermis in pigs with crusted sarcoptic mange (Sheahan, 1975). In experimentally infected wombats, this may represent the beginning of a type I hypersensitivity response, although eosinophils, another feature of type I hypersensitivity (Tizard, 2000), were not present. However, in free-living wombats with chronic sarcoptic mange, eosinophils and mast cells were present in the dermal inflammatory response. Development of type I hypersensitivity generally followed that of type IV hypersensitivity in other animals infected with *S. scabiei* (Davis and Moon, 1990a). In free-living wombats, numbers of eosinophils in the dermis were correlated with densities of mites suggesting that lesional recruitment of eosinophils is influenced by mites or their products.

Neutrophils were present in the dermal inflammatory response of free-living wombats with sarcoptic mange and wombats experimentally infected with *S. scabiei*. However, increase in numbers of neutrophils in experimentally infected wombats was not significant compared with control wombats due to a relatively slight neutrophilic response to earlier skin biopsies in control wombats. There was also extensive

variation in the number of neutrophils present in the dermis among wombats infected with *S. scabiei*. This may be because there are other factors besides the presence of mites that determine the magnitude of the neutrophilic response such as the exposure of the dermis to bacteria due to excoriation (Skerratt, 1998) or tissue injury from self trauma. In support of this is the fact that in free-living wombats numbers of neutrophils were not correlated with the intensity of mite infection. Neutrophils constitute a greater proportion of the inflammatory response in secondary infections of *S. scabiei*, also suggesting that there are factors other than the number of mites that control the neutrophilic response (Arlian, 1996). Arlian (1996) suggested that the oxidative burst of neutrophils is important in eliminating mites.

Plasma cells were present in experimentally infected wombats. However, neither plasma cells nor B lymphocytes were detected in free-living wombats with severe sarcoptic mange. This may represent the development of some tolerance to infection with *S. scabiei* in free-living wombats and a reduction in the humoral immune response (Davis and Moon, 1990a; Tizard, 2000). Desensitisation is the last in the sequence of phases that develop during the immune response to arthropod antigens of which exhaustion or suppression of antibody-producing cells is a feature (Davis and Moon, 1990a).

Comparison between intensities of the cellular infiltrates in different host species can not be made unless the extent of exposure of the hosts to mites is known. Therefore, studies should quantify the density of mites and duration of infection in the host to determine the extent of exposure (Davis and Moon, 1990b). Differences between varieties of *S. scabiei* in the type of immune response that they elicit must also be considered (Arlian et al., 1996b).

In summary, the immune response of wombats experimentally infected with *S. scabiei* is dominated by T lymphocytes,



plasma cells, mast cells, and neutrophils and appears to be similar to that reported for dogs (Arlian et al., 1996a, 1997). This is a significant finding since resistance to secondary infections of *S. scabiei* has been identified in dogs and suggests that vaccination with an appropriate antigen from *S. scabiei* may provide some protection against infection with *S. scabiei* (Arlian et al., 1996a). The immune response of wombats is different to the immediate hypersensitivity response that occurs initially in foxes (Little et al., 1998). Pigs and rabbits also differ in their inflammatory infiltrate in the dermis in that eosinophils are initially present in pigs whereas T lymphocytes are absent in rabbits (Davis and Moon, 1990a; Arlian et al., 1994). The immune response of free-living wombats with severe sarcoptic mange is typical of an immune system that has become desensitised to infection with *S. scabiei* (Davis and Moon, 1990a). However, desensitisation may also occur, even though aspects of a hypersensitivity response are present (Davis and Moon, 1990a). It appears that once parakeratotic scale has built up sufficiently to prevent mites being removed by scratching the immune response is less effective at limiting the number of mites. The number of mites then increases dramatically and provides the immune system with a vast amount of antigen that probably results in desensitisation.

Immunohistochemical staining of tissues of the common wombat is similar to that of the koala, its closest relative, and other marsupials, the ringtail possum and the tammar wallaby, with monoclonal antibodies anti-CD5, anti-CD3, and anti-CD79b differentially staining cells (Hemsley et al., 1995). Similarly, the monoclonal antibody anti-CD79a did not stain cells and the polyclonal antibody anti-CD3 stained cells more strongly than monoclonal anti-CD3 (Hemsley et al., 1995). However, anti-koala IgG antibodies did not differentially stain wombat plasma cells although they stained plasma cells from ko-

ala, brushtail and ringtail possums, and tammar wallabies. Although it is possible that there was some false negative and positive staining, these results support the conclusion that intracytoplasmic regions of some receptors are highly conserved among species (Jones et al., 1993; Wilkinson et al., 1995). Antibodies raised against external receptors such as anti-koala IgG and anti-human HLA were less cross-reactive. Similarly, anti-human leucocyte common antigen did not stain lymphocytes of the southern hairy-nosed wombat (Byard et al., 1998). Fixation compared with freezing of tissues resulted in better staining of intracytoplasmic but not extracellular regions of leucocyte receptors.

#### ACKNOWLEDGMENTS

J. Wilson is especially thanked for histologic sectioning and staining of tissues. D. Middleton is thanked for supervision of this study and, along with I. Beveridge, comments on the manuscript. Two anonymous referees and an assistant editor are thanked for their comments on the manuscript. The Holsworth Wildlife Research Fund funded this research and Dr. Holsworth is thanked for his support. L. Skerratt was supported by an Australian postgraduate scholarship. This research was conducted with approval from the Veterinary Science Animal Experimentation Ethics Sub-Committee, register number 97082 and permits from the Department of Natural Resources and Environment, permit numbers 10000433, 10000434, 10000936 and RP-97-138. Antibodies for immunohistochemistry were generously donated by R. Wilkinson from the Central Veterinary Laboratories, Department of Agriculture, Adelaide, Australia and the LRF Immunodiagnosics Unit, Department of Clinical Biochemistry and Cellular Science, University of Oxford, United Kingdom and were imported with the permission of the Australian Quarantine and Inspection Service, permit number 199905742.

#### LITERATURE CITED

- ACKERMAN, A. B. 1985. Histopathology of human scabies. In Cutaneous infestations and insect bites, M. Orkin and H. I. Maibach (eds.), Marcel Dekker, New York, New York, pp. 85-93.
- ARLIAN, L. G. 1996. Immunology of scabies. In The immunology of host ectoparasitic arthropod relationships, S. K. Wikel (ed.), CAB International, Wallingford, UK, pp. 232-258.

- , C. M. RAPP, D. L. VYSZENSKI-MOHER, AND M. S. MORGAN. 1994. *Sarcoptes scabiei*: Histopathological changes associated with acquisition and expression of host immunity to scabies. *Experimental Parasitology* 78: 51–63.
- , M. S. MORGAN, C. M. RAPP, AND D. L. VYSZENSKI MOHER. 1996a. The development of protective immunity in canine scabies. *Veterinary Parasitology* 62: 133–142.
- , ———, AND J. J. ARENDS. 1996b. Immunologic cross-reactivity among various strains of *Sarcoptes scabiei*. *Journal of Parasitology* 82: 66–72.
- , C. M. RAPP, B. L. STEMMER, M. S. MORGAN, AND P. F. MOORE. 1997. Characterization of lymphocyte subsets in scabietic skin lesions of naive and sensitized dogs. *Veterinary Parasitology* 68: 347–358.
- BYARD, R. W., M. CARLI, AND A. MOORE. 1998. An immunohistochemical study of the southern hairy-nosed wombat *Lasiorhinus latifrons*. In *Wombats*, R. T. Wells and P. A. Pridmore (eds.). Surrey Beatty & Sons, Chipping Norton, New South Wales, Australia, pp. 42–47.
- CROIX, D. A., N. K. SAMPLES, J. L. VANDEBERG, AND W. H. STONE. 1989. Immune response of a marsupial (*Monodelphis domestica*) to sheep red blood cells. *Developmental and Comparative Immunology* 13: 73–78.
- DAVIS, D. P., AND R. D. MOON. 1990a. Dynamics of swine mange: A critical review of the literature. *Journal of Medical Entomology* 27: 727–737.
- , AND ———. 1990b. Density of itch mite, *Sarcoptes scabiei* (Acari: Sarcoptidae) and temporal development of cutaneous hypersensitivity in swine mange. *Veterinary Parasitology* 85: 285–293.
- FALK, E. S., AND R. MATRE. 1982. *In situ* characterization of cell infiltrates in the dermis of human scabies. *American Journal of Dermatopathology* 4: 9–15.
- GHOSH, A. K., K. C. GATTER, AND D. Y. MASON. 1984. Immunocytochemical characterization of monoclonal anti-HLA-DR antibodies. In *Disease markers*, C. M. Steel (ed.). John Wiley & Sons, Sussex, UK, pp. 223–233.
- HEMSLEY, S. W., P. J. CANFIELD, AND A. J. HUSBAND. 1995. Immunological staining of lymphoid tissue in four Australian marsupial species using cross-reactive antibodies. *Immunology and Cell Biology* 73: 321–325.
- HENWOOD, A. 1994. An improved alcian blue for the demonstration of mast cells. *Technical Bulletin for Histotechnology* (Bayer) May: 2.
- JOHNSON, A. M., H. ROBERTS, P. STATHAM, AND B. L. MUNDAY. 1989. Serodiagnosis of acute toxoplasmosis in macropods. *Veterinary Parasitology* 34: 25–33.
- JONES, M., J. L. CORDELL, A. D. BEYERS, A. G. D. TSE, AND D. Y. MASON. 1993. Detection of T and B cells in many animal species using cross-reactive anti-peptide antibodies. *The Journal of Immunology* 150: 5429–5435.
- KROESE, F. G. M., W. A. M. AMMERLAAN, AND G. J. DEENEN. 1992. CD5 B cells in development and disease. *Annals of the New York Academy of Science* 651: 44–58.
- LILLEE, R. D., AND H. M. FULMER. 1976. *Histopathologic technique and practical histochemistry*, 4th Edition. McGraw Hill, New York, New York, 672 pp.
- LITTLE, S. E., W. R. DAVIDSON, P. M. RAKICH, T. L. NIXON, D. I. BOUNOUS, AND V. F. NETTLES. 1998. Responses of red foxes to first and second infection with *Sarcoptes scabiei*. *Journal of Wildlife Diseases* 34: 600–611.
- MASON, D. Y., J. CORDELL, M. BROWN, G. PALLESEN, E. RALFFIKIVER, J. ROTHBAND, M. CRUMPTON, AND K. C. GATTER. 1989. Detection of T cells in paraffin wax embedded tissue using antibodies against a peptide sequence from the CD3 antigen. *Journal of Clinical Pathology* 42: 1194–1200.
- , C. J. M. VAN NOESSEL, J. L. CORDELL, W. M. COMANS-BITTER, K. J. MICKLEM, A. G. D. TSE, R. A. W. VAN LIER, J. J. M. VAN DONGEN, AND J. BORST. 1992. The B29 and mb-1 polypeptides are differentially expressed during human B cell differentiation. *European Journal of Immunology* 22: 2753–2756.
- MORSY, G. H., AND S. M. GAAFAR. 1989. Responses of immunoglobulin-secreting cells in the skin of pigs during *Sarcoptes scabiei* infestation. *Veterinary Parasitology* 33: 165–175.
- RODE, B., S. V. BAVDEK, G. LACKOVIC, G. FAZARINC, AND A. BIDOVEC. 1998. Immunohistochemical study of normal and mange (*S. scabiei* var. *rupicaprae*) infested chamois (*Rupicapra rupicapra*) skin. *Anatomia Histologia Embryologia* 27: 187–192.
- SHEAHAN, B. J. 1975. Pathology of *Sarcoptes scabiei* infection in pigs. I. Naturally occurring and experimentally induced lesions. *Journal of Comparative Pathology* 85: 87–95.
- SHEEHAN, D. C., AND HRAPCHAK, B. B. 1980. *Theory and practice of histotechnology*. 2nd Edition. C. V. Mosby, St. Louis, Missouri, pp. 150–151.
- SKERRATT, L. F. 1998. Diseases and parasites of the common wombat *Vombatus ursinus* in the Healesville area of Victoria. In *Wombats*, R. T. Wells and P. A. Pridmore (eds.). Surrey Beatty & Sons, Chipping Norton, New South Wales, Australia, pp. 317–328.
- , J. PHELAN, R. MCFARLANE, AND R. SPEARE. 1997. Serodiagnosis of toxoplasmosis in a common wombat. *Journal of Wildlife Diseases* 33: 346–351.
- , D. MIDDLETON, AND I. BEVERIDGE. 1999. Distribution of life cycle stages of *Sarcoptes scabiei* var. *wombati* and effects of severe mange on common wombats in Victoria. *Journal of Wildlife Diseases* 35: 633–646.

- . 2003. Clinical response of captive common wombats (*Vombatus ursinus*) infected with *Sarcoptes scabiei* var. *wombati*. *Journal of Wildlife Diseases* 39: 179–192.
- TIZARD, I. R. 2000. *Veterinary Immunology: An introduction*, 6th Edition. W. B. Saunders, Sydney, New South Wales, Australia, 401 pp.
- VAN NESTE, D. J. J. 1986. Immunology of scabies. *Parasitology Today* 2: 194–195.
- WILKINSON, R., M. ALLANSON, V. KOLEGA, D. LAWRENCE, AND S. NEVILLE. 1991. Purification and initial characterisation of koala immunoglobulins. *Veterinary Immunology and Immunopathology* 29: 189–195.
- , I. KOTLARSKI, AND M. BARTON. 1992. Koala lymphoid cells: Analysis of antigen-specific responses. *Veterinary Immunology and Immunopathology* 33: 237–247.
- , M. BARTON, AND I. KOTLARSKI. 1995. Identification of koala T-lymphocytes using an anti-human CD3 antibody. *Developmental and Comparative Immunology* 19: 537–545.

*Received for publication 28 August 2001.*