

Chorioptic Mange in a Wild Japanese Serow

Authors: Shibata, Akiko, Yachimori, Shyuji, Morita, Tatsushi, Kanda, Eiji, Ike, Kazunori, et al.

Source: Journal of Wildlife Diseases, 39(2) : 437-440

Published By: Wildlife Disease Association

URL: <https://doi.org/10.7589/0090-3558-39.2.437>

BioOne Complete (complete.BioOne.org) is a full-text database of 200 subscribed and open-access titles in the biological, ecological, and environmental sciences published by nonprofit societies, associations, museums, institutions, and presses.

Your use of this PDF, the BioOne Complete website, and all posted and associated content indicates your acceptance of BioOne's Terms of Use, available at www.bioone.org/terms-of-use.

Usage of BioOne Complete content is strictly limited to personal, educational, and non - commercial use. Commercial inquiries or rights and permissions requests should be directed to the individual publisher as copyright holder.

BioOne sees sustainable scholarly publishing as an inherently collaborative enterprise connecting authors, nonprofit publishers, academic institutions, research libraries, and research funders in the common goal of maximizing access to critical research.

Chorioptic Mange in a Wild Japanese Serow

Akiko Shibata,^{1,4} Shyuji Yachimori,² Tatsushi Morita,¹ Eiji Kanda,³ Kazunori Ike,¹ and Soichi Imai¹ ¹ Department of Veterinary Parasitology, Nippon Veterinary and Animal Science University, Kyonan-cho 1-7-1, Musashino-shi, Tokyo 180-8602, Japan; ² Ecosystem Conservation Society-Kochi, 558-2 Ryu, Usa-cho, Tosa, Kochi 781-1165, Japan; ³ Tokyo Wildlife Research Center, Oguno 2452, Hinode-machi, Tokyo 190-0181, Japan; ⁴ Corresponding author (email: d0003@nvau.ac.jp)

ABSTRACT: Parasitologic and histopathologic examinations were performed on a wild Japanese serow (*Capricornis crispus*) with severe dermatitis from Tochigi, Japan in February 1999. The serow was infested with a large number *Chorioptes bovis*. Marked parakeratotic hyperkeratosis was characteristic of the lesions induced by these mites. Japanese serow is a new host of *C. bovis*.

Key words: *Capricornis crispus*, *Chorioptes bovis*, chorioptic mange, Japanese serow, mites.

Chorioptic mange is a skin disease caused by *Chorioptes* spp. (Acarina: Psoroptidae). Mites of this genus affect many domestic and some wild ruminants worldwide (Sweatman, 1957, 1958; Baker et al., 1967), and cause irritation, localized dermatitis, and self-trauma due to pruritis (Yeruham et al., 1999). Sweatman (1957, 1958) made detailed biologic and morphologic studies of the genus *Chorioptes* collected from many ungulates and concluded that two species, *Chorioptes bovis* and *C. texanus*, are present in this genus. These two species are distinguished by differences in the shape and length of the opisthosomal setae of the adult males. Esig et al. (1999) confirmed that these phenotypic differences agree with their bipartite division of genotypes of the second internal transcribed spacer of the rRNA gene. In Japan, both *C. bovis* and *C. texanus* produce subclinical infestations in dairy and beef cattle (Nagata et al., 1995); however no report of infestations in wild ruminants has been published.

In February 1999, the carcass of a male Japanese serow (*Capricornis crispus*), a solitary ruminant inhabiting forested mountainous areas of Japan, with severe dermatitis was found in Shiobara town, Tochigi prefecture, Japan (36°56'N, 139°53'W).

The body surface of the serow was characterized by alopecia, marked lichenification, accumulation of crust, and fissuring. Skin lesions were distributed over the legs, thorax, ventral abdomen, and perineum. Axilla and inguinal regions were most seriously affected; skin was up to 5 cm thick with cauliflower-like and/or papillary growth (Fig. 1). For histopathologic examination, skin samples were collected from severe lesions and fixed in 10% formalin, embedded in paraffin, sectioned at 5 μ m thickness, and stained with hematoxylin and eosin. For parasitologic examination, skin samples were taken from the same lesions and fixed in 70% ethanol. Mites were extracted from these samples under a stereoscopic microscope and mounted in Gater's gum chloral solution. Twenty mites of each life stage, i.e., adult male, adult female, nymph male, nymph female, and larva, were measured using an ocular micrometer within 10 min after mounting to avoid flattening and enlarging of the specimen with time.

Histologically, the epidermis of lichenized skin was characterized by marked




FIGURE 1. Medial aspect of the left hind leg of the affected serow. Note thick, fissured and crusted skin. Bar=20 cm.

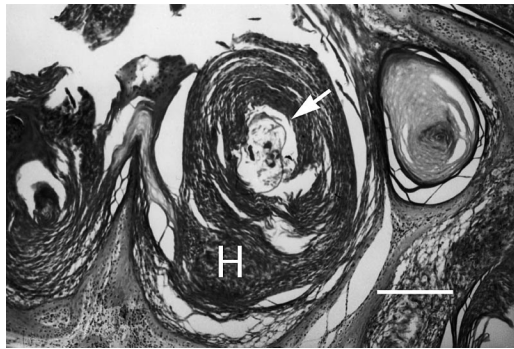


FIGURE 2. Histologic section of skin. Note parakeratotic hyperkeratosis (H) associated with *Chorioptes bovis* (arrow). Bar=200 μm .

parakeratotic hyperkeratosis with prominent rete-ridge formation (Fig. 2). There were some mites and bacteria in the horny layer of the thickened epidermis. The epidermis and dermis were infiltrated by a mixture of inflammatory cells. These le-

sions were similar in appearance to those of chorioptic mange of sheep and goats (Yeruham et al., 1999). The cauliflower-like lesion consisted of hyperplastic epidermis, accumulations of dried serous exudates, and cuticles. This type of lesion has not been reported in chorioptic mange.

A large number of mites were recovered from skin lesions. Morphologic examination demonstrated that pedicels of the mites were short and unjointed. The adult male was bilobed posteriorly, with five setae arising from each lobe. Two of these setae arose from the posteromedial corner of the lobe, and were wider basally and toward the distal end changed to a ensiform or lanceolate shape (Fig. 3). These morphologic characteristics agreed with those of *C. bovis*. Measurements of mites in each life stage are shown in Table 1. Length and width of the idiosoma of mites

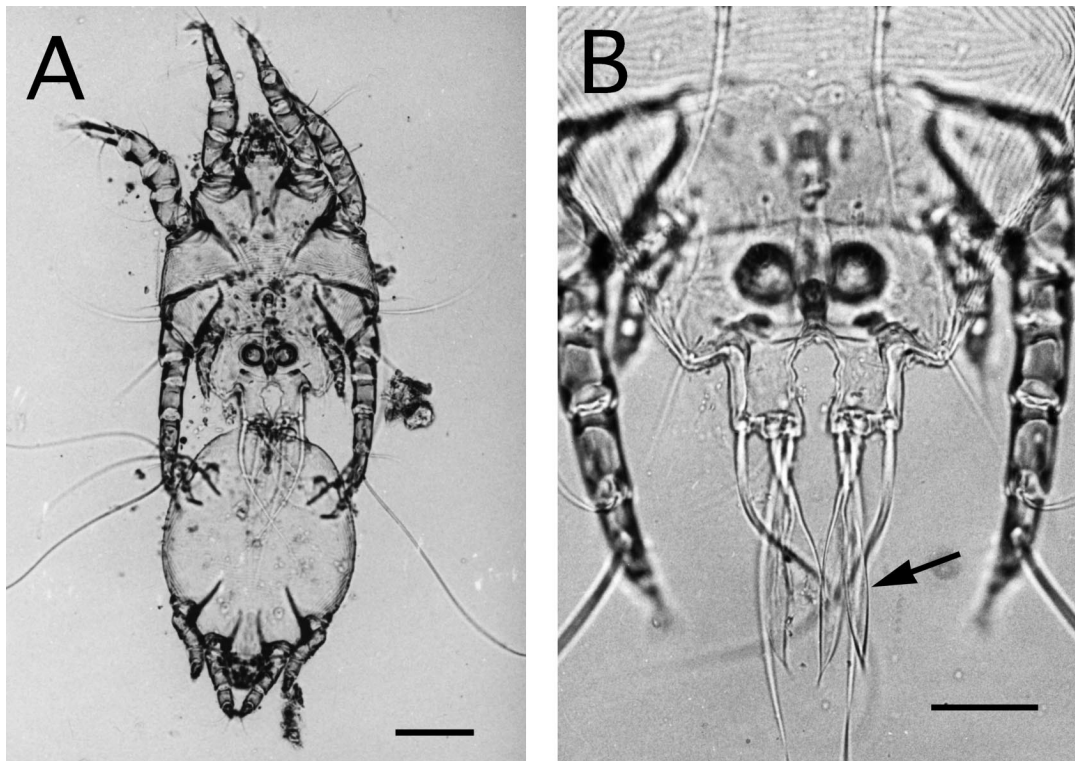


FIGURE 3. A: Adult male and nymph female stages of *Chorioptes bovis* from a Japanese serow. Bar=100 μm . B: The adult male was bilobed posteriorly, with two spatulate setae arising from each lobe (arrow). Bar=50 μm .

TABLE 1. Measurement of each life stage of *Chorioptes bovis* from the Japanese serow with mange.^a

	Adult		Nymph		
	Male (n=20)	Female (n=20)	Male (n=20)	Female (n=20)	Larva (n=20)
Length	277±27.5 (229-302)	427±31.0 (365-485)	230±26.4 (193-289)	225±22.2 (187-272)	201±12.9 (178-233)
Width	248±31.3 (213-315)	389±22.6 (326-426)	209±27.1 (166-264)	202±21.8 (167-250)	181±12.3 (156-208)
Dorsum length	230±9.8 (218-250)	260±15.2 (232-299)	161±17.9 (137-202)	155±19.3 (123-200)	125±12.1 (100-147)
Propodosomal plate length	87±2.3 (83-91)	131±5.1 (119-142)	69±4.8 (60-78)	69±3.4 (63-76)	61±3.6 (53-68)
Propodosomal plate width	40±2.6 (35-43)	67±3.8 (59-73)	36±2.7 (32-40)	36±2.9 (33-42)	30±1.8 (26-33)
Gnathosoma width	53±2.2 (51-57)	72±2.3 (69-78)	42±2.3 (38-47)	42±2.5 (34-46)	33±1.1 (32-36)

^a All data are shown in micrometers as means followed by the standard deviation and ranges in parentheses.

agreed with Sweatman (1957). Given these observations, the mite was identified as *C. bovis*. Specimens were deposited in the collection of the Department of Zoology (National Science Museum in Tokyo, Japan; accession numbers, NSMT-Ac. 11537, 11538, 11539). Presence of all life stages on the Japanese serow suggests that this is a suitable host for *C. bovis*. Since other mites that cause mange in ruminants, or other causes of similar histologic lesions, such as parapoxvirus infection, were not detected in the skin lesions, these lesions were attributed to *C. bovis* infestation alone.

This is the first report of severe choriopic mange in a Japanese serow caused by *C. bovis*. Because *C. bovis* has little host specificity and rarely causes serious damage to the skin (Sweatman, 1957; Creemers, 1985), it may subclinically infest Japanese serows. Generally, serious mange tends to occur in patients with malnutrition and/or immunosuppression (Egawa et al., 1992), and severe scrotal choriopic mange equivalent to this case has been associated with impaired reproduction in rams (Rhodes, 1976).

A complete evaluation of the health of the animal was not possible, and thus the consequences of severe infestation to the overall health of the serow could not be determined. Because the Japanese serow is an indigenous wild ruminant belonging to the natural monuments of Japan, preservation of the species is essential and should include further studies of *C. bovis*, the cause of potentially serious mange in this host.

We wish to acknowledge T. Nunoya (Nippon Institute for Biological Science: NIBS) for review of histologic slides and the manuscript. We also thank H. Tomioka (NIBS) and Dr. T. Hirai (NIBS) for invaluable assistance in technique.

LITERATURE CITED

- BAKER, E. W., T. M. EVANS, D. J. GOULD, W. B. HULL, AND H. L. KEEGAN. 1967. A manual of parasitic mites of medical or economic impor-

- tance. National Pest Control Association, Woodhaven, New York, pp. 139–144.
- CREMERS, H. J. 1985. The incidence of *Chorioptes bovis* (Acarina: Psoroptidae) on the feet of horses, sheep, and goats in the Netherlands. *Veterinary Quarterly* 7: 283–289.
- EGAWA, K., M. JOHNNO, T. HAYASHIBARA, AND T. ONO. 1992. Familial occurrence of crusted (Norwegian) scabies with adult T-cell leukaemia. *British Journal of Dermatology* 127: 57–59.
- ESSIG, A., H. RINDER, R. GOTHE, AND M. ZÄHLER. 1999. Genetic differentiation of mites of the genus *Chorioptes* (Acari: Psoroptidae). *Experimental and Applied Acarology* 23: 309–318.
- NAGATA, T., A. R. RONCALLI, T. MISHIBA, K. MATUOKA, K. YAMADA, AND S. URA. 1995. Efficacy of ivermectin pour-on formulation against naturally infected mange mites (*Chorioptes* spp.) in cattle, Japan. *Bulletin Animal Hygienics* 41: 27–33.
- RHODES, A. P. 1976. The effect of extensive chorioptic mange of the scrotum on reproductive function of the ram. *Australian Veterinary Journal* 52: 250–257.
- SWEATMAN, G. K. 1957. Life history, non-specificity, and revision of the genus *Chorioptes*, a parasitic mite of herbivores. *Canadian Journal of Zoology* 35: 641–689.
- . 1958. Redescription of *Chorioptes texanus*, a parasitic mite from the ears of reindeer in the Canadian Arctic. *Canadian Journal of Zoology* 36: 525–528.
- YERUHAM, S., S. ROSEN, AND A. HADANI. 1999. Chorioptic mange (Acarina: Psoroptidae) in domestic and wild ruminants in Israel. *Experimental and Applied Acarology* 23: 861–869.

Received for publication 26 February 2002.