



## ORAL PAPILLOMATOSIS IN THE COYOTE

Authors: TRAINER, D. O., KNOWLTON, F. F., and KARSTAD, L.

Source: Bulletin of the Wildlife Disease Association, 4(2) : 52-54

Published By: Wildlife Disease Association

URL: <https://doi.org/10.7589/0090-3558-4.2.52>

---

BioOne Complete ([complete.BioOne.org](https://complete.BioOne.org)) is a full-text database of 200 subscribed and open-access titles in the biological, ecological, and environmental sciences published by nonprofit societies, associations, museums, institutions, and presses.

Your use of this PDF, the BioOne Complete website, and all posted and associated content indicates your acceptance of BioOne's Terms of Use, available at [www.bioone.org/terms-of-use](https://www.bioone.org/terms-of-use).

Usage of BioOne Complete content is strictly limited to personal, educational, and non - commercial use. Commercial inquiries or rights and permissions requests should be directed to the individual publisher as copyright holder.

---

BioOne sees sustainable scholarly publishing as an inherently collaborative enterprise connecting authors, nonprofit publishers, academic institutions, research libraries, and research funders in the common goal of maximizing access to critical research.

**ORAL PAPILLOMATOSIS IN THE COYOTE**

Information on neoplasms of the coyote (*Canis latrans*) is meager and confined to captive animals (Halloran, Amer. J. Vet. Res. 16, (61): 155-157, 1955). There are no reports of oral papillomatosis in either wild or captive coyotes.

**Case Report**

As part of a coyote population investigation, in Andrews County, Texas, animals were trapped and examined. In March, 1966, a severe "wart-like" infection was noted in an adult male coyote. The entire surface of the lips, tongue and buccal cavity were covered with large "wart-like" growths, some of which obscured many of the teeth. Growths were even detected in the area of the epiglottis and glottis. The coyote was anesthetized, photographed (Fig. 1 and 2), and specimens were taken and submitted to the laboratory.

All of the warts were sharply delimited from surrounding normal tissue; many were single, while others were multiple or in cauliflower-like masses. The growths ranged in diameter from 15-300 mm. A strong, foul odor was associated with the specimen. The extensive growth of warts probably interfered with normal feeding; although the animal was of usual stature, it weighed only 16.5 pounds, some 7 to 10 pounds below average.

Histopathologically, this tumor was epithelial and resembled the canine oral papilloma (Smith and Jones, Veterinary Pathology, Lea and Febiger. 422, 1966). The bulk of the papilloma was made up of thick papilliform growths of stratified squamous epithelium covering and supported by thin, delicate filiform branches of connective tissue from the dermis, containing blood vessels and leukocytes (Fig. 3). The epithelial overgrowth was covered by a heavy layer of cornified epithelium (Fig. 3), a classical feature of canine papillomatosis. Many of the squamous cells below the cornified layer



FIGURE 1. Gross lesions of coyote oral papillomatosis illustrating involvement of the tongue and oral mucosa.

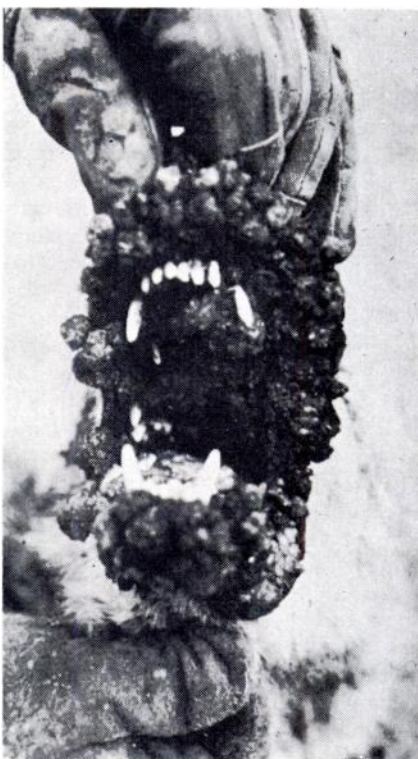


FIGURE 2. Gross lesions of coyote oral papillomatosis. Involvement of the lips and oral mucosa.

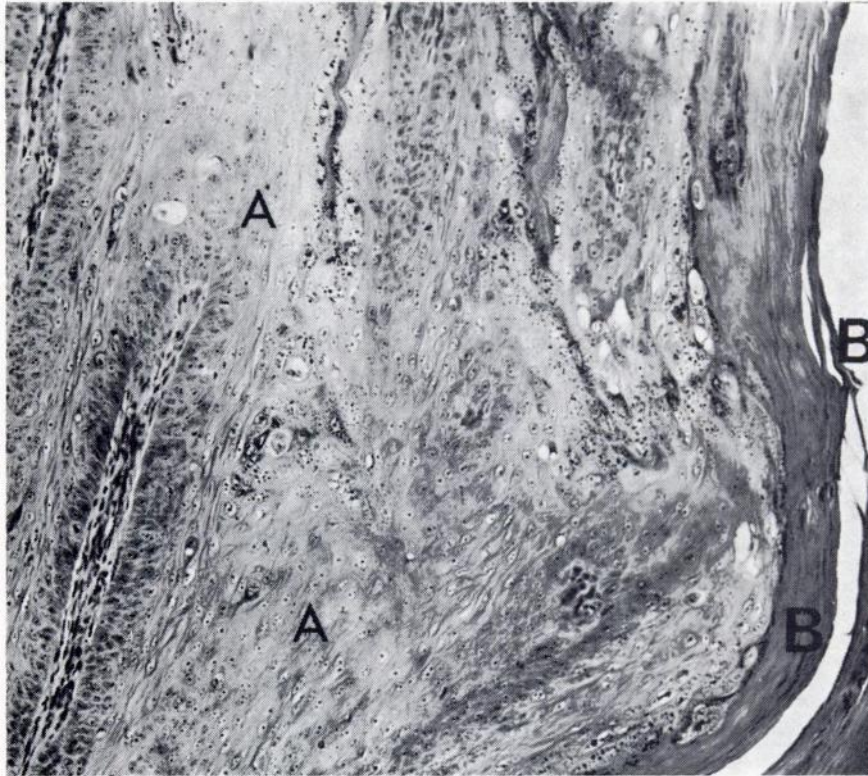


FIGURE 3. *Histological section of coyote oral papilloma. (A) Stratified squamous epithelium supported by filiform branches of connective tissue; (B) surface layer of cornified cells.*

were enlarged and vacuolated. Basophilic intranuclear inclusions were not found; however, acidophilic "inclusions" which resembled kerato-hyalin bodies were present in the cytoplasm of some of the cells of the stratum spinosum (DeMonbreun and Goodpasture, *Amer. J. Path.* 8: 43-56, 1932). Scattered plasma cells and lymphocytes were seen in the connective tissues underlying the tumors. Purulent inflammation had occurred in some areas, apparently the result of secondary bacterial infection through breaks in the abnormal epithelium. Masses of pus cells were present in the dermis in these areas. Otherwise, the dermis and underlying muscle was relatively normal.

From these features of gross and micro-

scopic pathology, a diagnosis of oral papillomatosis was made.

#### Discussion

It has been reported that only the dog is susceptible to natural or experimental infectious canine oral papillomatosis, although kittens, guinea pigs, rabbits, rats, mice, monkeys and red foxes have been unsuccessfully exposed (DeMonbreun and Goodpasture, *Amer. J. Path.* 8: 43-56, 1932). This is the first observation, to our knowledge, of an apparent naturally-occurring canine oral papillomatosis in a species other than the dog. We acknowledge the need to confirm this diagnosis with additional study, including attempted transmission

and characterization of the causative agent.

Two mild cases of oral papillomatosis in coyotes were encountered by the field biologist in Webb County, Texas in November, 1967. These cases were not spectacular and probably would have gone undetected without the interest generated by the first case. Discussions with trappers and other biologists revealed three additional suspected cases of the disease, including one for which photographs were available for scrutiny. If spontaneous recovery occurs among coyotes and is followed by strong immunity, as in dogs, papillomatosis may not be a rare or isolated disease, but rather one that is frequently overlooked.

This case illustrates the thesis that

wildlife is susceptible to a wide variety of infectious diseases and that when these disease processes are described and looked for, they are often found. The continuous need to scrutinize wild populations for the existence of disease, and the importance of integrating disease studies with ecological research, are evident.

\*D. O. TRAINER

\*\*F. F. KNOWLTON

\*\*\*L. KARSTAD

\*Department of Veterinary Science,  
University of Madison, Wisconsin 53706

\*\*U.S. Department of Interior,  
Fish and Wildlife Service,  
P.O. Box 9037, Guilbeau Station,  
San Antonio, Texas

\*\*\*Ontario Veterinary College,  
University of Guelph,  
Guelph, Ontario

January 8, 1968

#### SYNHIMANTUS (NEMATODA) ASSOCIATED WITH GASTRIC SQUAMOUS TUMORS IN MUSKRATS\*

Nematodes of the genus *Synhimantus* have been reported in raccoons (Chandler, 1942. *J. Parasitol.* 28:255-268) and birds, with larval stages in fish and ostracods (Yamaguti, 1961. *Systema Helminthum*, Vol. III, *The Nematodes of Vertebrates*, Interscience). This and other genera in the spirurid family *Acuariidae* are principally parasites of birds. The first occurrence reported here in muskrats (*Ondatra zibethicus ripens*) is most unusual in view of previous extensive negative findings in surveys of parasitism in this mammal (Grundmann and Tsai, 1967. *Trans. Am. Microscop. Soc.* 86: 139-144) and because of the tissue reaction associated with the *Synhimantus* nematode in the muskrats' stomachs.

Two muskrats were trapped in irrigation ditches along the Rio Grande River near Las Cruces, Dona Ana County, New Mexico, in early summer of 1967. At necropsy, the limiting ridges of their forestomachs were distorted by papillary tumors which involved 5 cm. in one muskrat (Figure 1) and 2 cm. in the other. Histologically, the gastric tumors were composed of hyperplastic squamous epithelial papillomata that projected into the lumen (Figure 2). Anastomosing cords of squamous epithelium occurred in the submucosa (Figure 3). Several pathologists examined the histologic slides. Opinion was divided, but the majority felt that the tumors were benign

\*Research jointly sponsored by the Oak Ridge Associated Universities, and by the U.S. Atomic Energy Commission under contract with Union Carbide Corporation.