

EUROPEAN BROWN HARE SYNDROME IN FREE-LIVING MOUNTAIN HARES (LEPUS TIMIDUS) AND EUROPEAN BROWN HARES (LEPUS EUROPAEUS) IN FINLAND 1990–2002

Authors: Syrjälä, Paula, Nylund, Minna, and Heinikainen, Sirpa

Source: Journal of Wildlife Diseases, 41(1) : 42-47

Published By: Wildlife Disease Association

URL: <https://doi.org/10.7589/0090-3558-41.1.42>

BioOne Complete (complete.BioOne.org) is a full-text database of 200 subscribed and open-access titles in the biological, ecological, and environmental sciences published by nonprofit societies, associations, museums, institutions, and presses.

Your use of this PDF, the BioOne Complete website, and all posted and associated content indicates your acceptance of BioOne's Terms of Use, available at www.bioone.org/terms-of-use.

Usage of BioOne Complete content is strictly limited to personal, educational, and non - commercial use. Commercial inquiries or rights and permissions requests should be directed to the individual publisher as copyright holder.

BioOne sees sustainable scholarly publishing as an inherently collaborative enterprise connecting authors, nonprofit publishers, academic institutions, research libraries, and research funders in the common goal of maximizing access to critical research.

EUROPEAN BROWN HARE SYNDROME IN FREE-LIVING MOUNTAIN HARES (*LEPUS TIMIDUS*) AND EUROPEAN BROWN HARES (*LEPUS EUROPAEUS*) IN FINLAND 1990–2002

Paula Syrjälä,^{1,3} Minna Nylund,² and Sirpa Heinikainen¹

¹ National Veterinary and Food Research Institute, Kuopio Department, Neulaniementie 4, PO Box 92, FIN 70701 Kuopio, Finland

² National Veterinary and Food Research Institute, Oulu Regional Unit, Satamatie 15, PO Box 517, FIN 90101 Oulu, Finland

³ Corresponding author (email: paula.syrjala@eela.fi)

ABSTRACT: We investigated the epidemiology of the European brown hare syndrome (EBHS) in Finland among free-living mountain hares (*Lepus timidus*) and European brown hares (*Lepus europaeus*). Carcasses of 297 European brown hares and 843 mountain hares submitted for postmortem examination were analyzed between 1990 and 2002. One hundred thirty-six cases of EBHS were detected during the examination, 20 cases in European brown hares and 116 in mountain hares. Liver samples from 56 histopathologically positive and 135 negative cases were analyzed by reverse transcription polymerase chain reaction (RT-PCR). The results of RT-PCR correlated well with histopathology. Cases of EBHS appeared only sporadically in a restricted area in eastern Finland during 1990–97. In 1998, the number of cases increased, and the disease spread to the north. In 1998–99, EBHS was the most common disease of mountain hares in necropsy material from northern and eastern Finland. Special features were the occurrence of the disease in areas in which European brown hares are rare and the seasonal distribution of cases, most of which appeared in spring or summer. This is the first report of an outbreak of EBHS occurring mainly among free-living mountain hares from Finland.

Key words: Calicivirus, epidemiology, European brown hare syndrome, histology, lagomorphs, *Lepus europaeus*, *Lepus timidus*, RT-PCR.

INTRODUCTION

European brown hare syndrome (EBHS) is an acute and severe, contagious, necrotizing viral hepatitis occurring in European brown hares (*Lepus europaeus*) and mountain hares (*Lepus timidus*). It is caused by a calicivirus (genus *Lagovirus*) closely related to rabbit hemorrhagic disease (RHD) virus. Rabbit hemorrhagic disease has caused high mortality among feral and farmed rabbits (*Oryctolagus cuniculus*) on several continents. European brown hare syndrome occurs commonly in European brown hares in southern, central, and eastern Europe and in Denmark and Sweden. It seems to be endemic among European brown hares in many areas in Europe (Henriksen et al., 1989; Gavier-Widen and Mörner, 1991; Kwapil, 1993; Steineck and Nowotny, 1993; Duff et al., 1994; Scicluna et al., 1994; Frölich et al., 1996; Lamarque et al., 1996). There are only few reports of the disease in mountain hares (Gavier-Widen

and Mörner, 1991, 1993; Frölich et al., 2001). In Finland, the first cases of EBHS were diagnosed in 1990 in two mountain hares and one European brown hare (Salmela et al., 1993). Recently, antibodies against EBHS virus have been detected in European brown hares in Argentina (Frölich et al., 2003). European brown hare syndrome has caused marked local mortality in free-living populations and severe losses in European brown hares on farms. Both RHD and EBHS can exist in the same areas, but cross-infection does not occur (Lavazza et al., 1996). European brown hare syndrome virus was first isolated in Italy in 1989 (Lavazza and Vecchi, 1989), but according to retrospective studies, the disease occurred in several countries as early as the 1970s (Lavazza and Vecchi, 1989; Chasey, 1994; Gavier-Widen, 1994; Bascunana et al., 1997).

The mountain hare is an indigenous species to Finland. It is common in all parts of the country, primarily in forests.

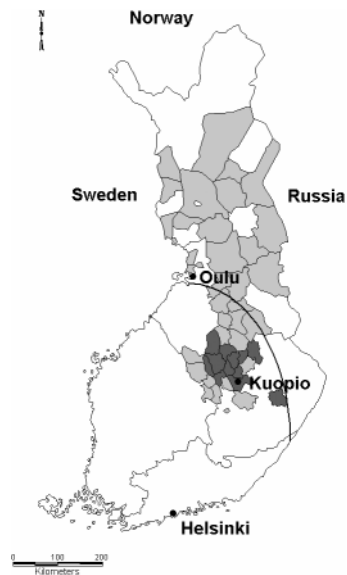


FIGURE 1. Regional distribution of European brown hare syndrome cases in Finland. Dark grey area=cases detected in 1990–97; light grey=new disease area 1998–2002; black line=northern limit of the permanent occurrence of European brown hares.

The population is most abundant in eastern Finland. It is well adapted to deep snow with specialized feet and can exist with poor-quality food during winter. The European brown hare spread to Finland in the late 1880s from Russia (Linden et al., 1996). This latter species favors pastures and open fields, and the population density is highest in the southern and western parts of the country. The approximate northern limit of its permanent occurrence is shown in Figure 1. Small local populations of European brown hares occur also in northern Finland, especially in river valleys. The most important limiting factor to their occurrence in the north is deep snow. Both species are important and popular game animals in Finland. Annually, about half a million hares, of which one fifth are European brown hares, are hunted (Anonymous, 2003).

The objective of this study was to describe the occurrence, geographic distribution, and pathologic features of the EBHS especially among mountain hares, in which this disease seems to be more

common than in European brown hares in Finland.

MATERIALS AND METHODS

Between 1990 and 2002, 1,140 carcasses of free-living hares, 843 mountain hares and 297 European brown hares, were examined post-mortem in the National Veterinary and Food Research Institute units in Kuopio and Oulu, Finland. Samples originated from areas around these laboratories in eastern and northern Finland and were submitted by hunters or local people. Most of the animals were found dead, some were euthanized because of severe illness. A routine necropsy was performed. The age of the animals was scored as young (having milk in their stomachs), subadult (gonads not fully developed), or adult (Gavier-Widen and Mörner, 1993). The nutritional body condition of the hares was determined as good, normal, moderate, or poor depending on fat stores and muscle condition. Postmortem changes were classified as mild, moderate, or severe. Tissue samples, including liver, were collected and fixed in 10% neutral buffered formalin from all carcasses when the cause of death was not acute fatal trauma. Samples were routinely processed, embedded in paraffin, cut into 5- μ m sections, and stained with hematoxylin and eosin. Von Kossa and Masson's trichrome stains (Luna, 1968) were used to detect mineralization and fibrosis. Histopathologic diagnosis of EBHS was based on liver lesions, which are considered characteristic for the disease (Fuchs and Weissenböck, 1992; Gavier-Widen, 1994). They included periportal to diffuse coagulation and lytic necrosis of hepatocytes with severe hemorrhages, minimal inflammatory reaction, and a variable amount of fatty change and mineralization. All other lesions were recorded (data not shown).

In addition, 191 liver samples from the necropsy material were selected for reverse transcription polymerase chain reaction (RT-PCR) assay. These samples were chosen to confirm the diagnosis and distribution of the disease into new areas in 1997–99. All hares from northern Finland ($n=117$) between 1997 and 1999 were tested (1997: 37, 1998: 35, 1999: 45), and all hares ($n=74$) from eastern Finland from 1999 were tested. This material consisted of 56 histopathologically positive and 135 negative samples. Four samples were rejected because of autolysis.

The nested RT-PCR assay described by Basunana et al. (1997) was used with minor modifications to test paraffin-embedded samples. Briefly, a 20- μ m section of the sample was deparaffinized with xylene and digested with 200

μg of proteinase K. Samples were extracted once with a 1:1 phenol (pH 4.3)–chloroform mixture and once with chloroform. RNA was precipitated with ethanol and sodium acetate and dissolved in 50 μl of DEPC-treated water. Synthesis of cDNA was done with HEB primer from 5 μl of RNA. The first amplification of the DNA was done with HEF and HEB primers and the nested PCR with HIF and HIB primers using DyNAzyme[®] DNA polymerase kit (Finnzymes, Espoo, Finland). Negative and positive liver sections were included as controls in every analysis. Amplification products were electrophoresed in 2% agarose with ethidium bromide and photographed under ultraviolet light.

RESULTS

One hundred thirty-six cases of EBHS were diagnosed by histopathology, 20 cases (six males, nine females, five of unknown sex) in European brown hares and 116 (37 males, 64 females, 15 of unknown sex) in mountain hares. Most of the hares (109/136) were found dead. Twenty-seven hares were seen alive a few minutes before death or were euthanized by hunters. They seemed to have lost their shyness toward humans. Some had convulsions or abnormal gait. The carcasses were mostly in normal or moderate body condition, only two hares were in poor condition. The mean body weight of mountain hares was 3.1 kg (range 1.3–5 kg, $n=102$) and of European brown hares was 3.5 kg (range 1.6–4.8 kg, $n=17$). All hares were classified as subadults or adults.

Typical gross lesions in both species included a moderately enlarged dark spleen, congested or pale liver with or without pinpoint hemorrhages, and severe pulmonary edema associated with hemorrhage and congestion under the tracheal mucosa. Massive enlargement of the spleen was rarely seen (8/136). Some hares (16/136) also had icterus, subcutaneous hemorrhages (12/136), intestinal subserosal hemorrhages (9/136), or moderate amounts of serous liquid in peritoneal or pleural cavities (4/136). Many females (26/75) were pregnant or had recently delivered (16/75).

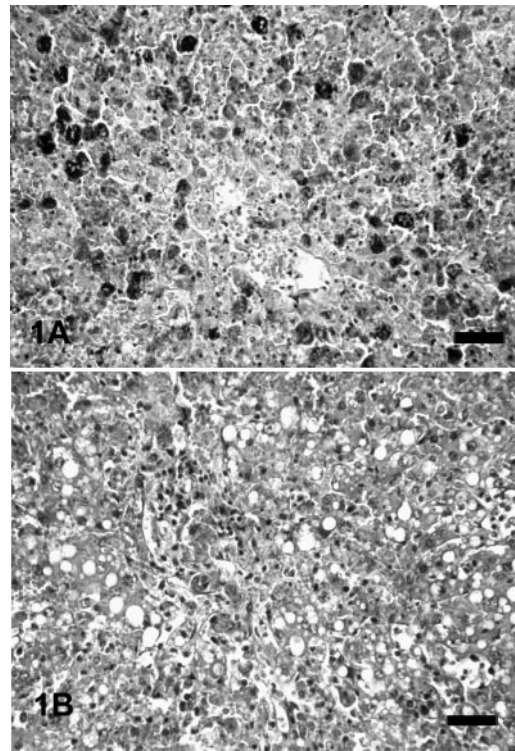


FIGURE 2. (A) Acute necrotizing hepatitis with marked mineralization of hepatocytes. Liver, mountain hare, H&E stain. Bar=50 μm . (B) Subacute hepatitis with fatty change and mild nonsuppurative inflammation. Liver, mountain hare, H&E stain. Bar=50 μm .

Typical, acute, histopathologic lesions varied from clearly demarcated periportal coagulation necrosis (19/136) to massive acute coagulation and lytic liver necrosis with hemorrhage (110/136) and no or scant inflammation (Fig. 2A). Vacuolation of hepatocytes, indicating fatty change, was detected in 31 of 136 cases. A minority of cases (7/136) were classified as subacute and showed mild to moderate fatty degeneration of hepatocytes, biliary tract proliferation, and mild mononuclear cell infiltrate in the portal areas (Fig. 2B). Granular mineralization (calcification) of hepatocytes was prominent in most acute cases (74/136; Fig. 2A). Mineralization and coagulation necrosis of hepatocytes were also detectable in many cases classified as severely autolyzed (15/136).

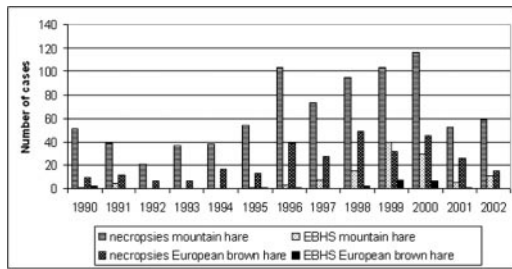


FIGURE 3. Annual number of necropsies and European brown hare syndrome cases in mountain hares and European brown hares.

Of the 56 histologically positive samples tested by RT-PCR, 54 were classified as acute and two as subacute. All were positive by RT-PCR. All samples negative in histologic examination (135/191), and tested by RT-PCR, were negative also by this test. All liver samples collected from northern Finland before the outbreak in 1997 ($n=39$) were negative by histopathology and RT-PCR.

The first sporadic EBHS cases were diagnosed in a small area in eastern Finland in 1990–95. In 1996–97, the number of cases increased slightly, but the disease was still restricted to a limited geographic area (Fig. 1). During the next 3 yr, the disease spread to northern Finland. In 1999, EBHS was the most common infectious disease diagnosed in hares. It was detected in 35% of the necropsy cases from this part of the country (Fig. 3). In the next 3 yr, the proportion of EBHS cases decreased again. Most cases were detected in samples submitted in spring and summer (Fig. 4).

DISCUSSION

Clinical signs and pathologic features of EBHS were similar to previous descriptions (Fuchs and Weissenböck, 1992; Gavier-Widen, 1994). In acute cases, macroscopic lesions in mountain hares were often minimal and could be easily overlooked, but histopathologic changes were typical and diagnostic. Reverse transcription PCR was found to be useful in confirmation of the positive histopathologic

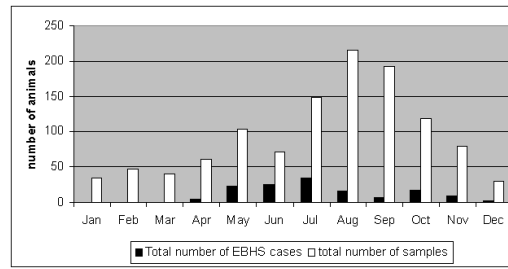


FIGURE 4. Seasonal distribution of 1,140 samples and 136 European brown hare syndrome cases between 1990 and 2002.

diagnosis in acute cases, even if the tissue was autolyzed. Our intention in using RT-PCR was to determine whether any hares carried the virus in northern Finland before the first histologic diagnoses, but no carrier animals without histologically detectable liver lesions were found. In addition, there were two hares with hepatitis and more chronic lesions, including biliary tract proliferation, moderate mononuclear inflammatory infiltrates, and slight fibrosis, possibly suggestive of chronic EBHS, but viral material was not detected in these cases and they were classified as negative.

Distribution of EBHS was concentrated in areas in which the mountain hare population is most abundant. Small numbers of European brown hares occur in northern Finland, and we cannot exclude the possibility that they spread the disease, but it is doubtful that such a small population could sustain the infection. European brown hare syndrome was not diagnosed in southern Finland until 2004, when it was confirmed in one European brown hare in our laboratory.

In Sweden, where EBHS has been reported in mountain hares, the disease occurs in the southern and central parts of the country, where brown hares are most common (Gavier-Widen and Mörner, 1993). Most diseased animals in Sweden have been European brown hares, although the number of diseased mountain hares has increased (Gavier-Widen and Mörner, 1993). It seems that mountain hares are very susceptible, but their ability

to carry the disease has not been shown. The origin and reservoirs of EBHS are not known, but it is suggested that European brown hares can spread and maintain the disease (Frölich et al., 1996; Seck-Lanzendorf, 1997). The occurrence of the disease on separate islands in Sweden and Denmark has also raised the question of the role of birds in spreading the disease (Clausen et al., 1997). Chrobocinska (2000) has shown that EBHS virus strains from Poland from different years had different restriction profiles and they differed from Italian and French strains. If antigenic changes are common in this virus, epidemics could appear repeatedly and adaptation to a new species would be easier.

European brown hare syndrome cases occurred almost all year round. The majority of cases occurred in spring and summer, with a minor peak of the occurrence in October and November. In previous reports, most cases have been detected in late autumn and winter (Gavier-Widen and Mörner, 1993; Steineck and Novotny, 1993; Duff et al., 1994). The cause of this has been suspected to be greater numbers of young, susceptible animals at the end of the breeding season, making spread of the disease easier by direct contact (Duff et al., 1994). There may be other predisposing factors. The hare population in Finland is smallest in late winter. Impaired nutritional status and parasitism during winter could be predisposing factors; however, the body condition of the animals we examined was generally normal. Moreover, EBHS was not identified in late winter (January–March). The beginning of the breeding season with increasing contacts between animals could possibly aid in spreading the infection.

It is difficult to estimate the real significance of the disease to the hare populations in the area of investigation. According to hunting and population monitoring records (Anonymous, 2003), the total number of hunted mountain hares decreased in 2000 and 2001 and local populations declined markedly. However,

there is a high natural variation in hare populations and marked local fluctuations are common. Environmental factors such as predators, weather conditions, and other diseases, especially parasitism and tularemia, can affect hare population numbers. Tularemia was detected in our study area, but the number of diagnosed cases (<25 annually between 1990 and 2002) was lower than the number of EBHS cases (Anonymous, 1990–2002). High local mortality from EBHS is possible (Duff et al., 1994). However, hares are very effective breeders, and it has been estimated that populations can recover in a few years after an epidemic (Clausen et al., 1997).

We conclude that EBHS can spread and cause mortality among wild mountain hares in areas in which the European brown hare population is not permanent and has a low density. Further studies are warranted to determine whether this disease can become endemic among mountain hares and could emerge in areas in which European brown hares do not exist.

LITERATURE CITED

- ANONYMOUS. 1990–2002. Annual reports of the National Veterinary and Food Research Institute, Helsinki, Finland. 366 pp.
- . 2003. Finnish Game and Fisheries Research Institute, *Game animal monitoring, annual reports*. www.rktl.fi. Last access 1-12-2003.
- BASCUNANA, C. R., N. NOWOTNY, AND S. BELAK. 1997. Detection and differentiation of rabbit hemorrhagic disease and European brown hare syndrome viruses by amplification of VP60 genomic sequences from fresh and fixed tissue specimens. *Journal of Clinical Microbiology* 35: 2492–2495.
- CHASEY, D. 1994. Possible origin of rabbit hemorrhagic disease in the United Kingdom. *The Veterinary Record* 135: 496–499.
- CHROBOCINSKA, M. 2000. Restriction analysis of capsid protein gene fragment of two Polish strains of European brown hare syndrome virus. *Bulletin of the Veterinary Institute Pulaway* 44: 25–33.
- CLAUSEN, B., E. RATTENBORG, AND H. H. DIETZ. 1997. New diseases in established populations of wild animals. *Dansk Veterinaertidsskrift* 80: 99–101.
- DUFF, J. P., R. CHASEY, R. MUNRO, AND M. WOOLDRIDGE. 1994. European brown hare syndrome

- in England. *The Veterinary Record* 134: 669–673.
- FRÖLICH, K., G. HAERER, L. BACCIARINI, M. JANOVSKY, M. RUDOLPH, AND M. GIACOMETTI. 2001. European brown hare syndrome in free-ranging European brown hares and mountain hares from Switzerland. *Journal of Wildlife Diseases* 37: 803–807.
- , H. H. MEYER, Z. PIELOWSKI, L. RONSHOLT, S. VON SECK-LANZENDORF, AND M. STOLTE. 1996. European brown hare syndrome in free-ranging hares in Poland. *Journal of Wildlife Diseases* 32: 280–285.
- , O. E. KUJAWSKI, M. RUDOLPH, L. RONSHOLT, AND S. SPECK. 2003. European brown hare syndrome virus in free-ranging European brown hares from Argentina. *Journal of Wildlife Diseases* 39: 121–124.
- FUCHS, A., AND H. WEISSENBOCK. 1992. Comparative histopathological study of rabbit hemorrhagic disease (RHD) and European brown hare syndrome (EBHS). *Journal of Comparative Pathology* 107: 103–113.
- GAVIER-WIDEN, D. 1994. Morphologic and immunohistochemical characterization of the hepatic lesions associated with European brown hare syndrome. *Veterinary Pathology* 31: 327–334.
- , AND T. MÖRNER. 1991. Epidemiology and diagnosis of the European brown hare syndrome in Scandinavian countries: A review. *Revue Scientifique et Technique* 10: 453–458.
- , AND ———. 1993. Descriptive epizootiological study of European brown hare syndrome in Sweden. *Journal of Wildlife Diseases* 29: 15–20.
- HENRIKSEN, P., D. GAVIER-WIDEN, AND F. ELLING. 1989. Acute necrotizing hepatitis in Danish farmed hares. *The Veterinary Record* 125: 486–487.
- KWAPIL, S. 1993. Bakteriologische, virologische und parasitologische Untersuchungen an Feldhasen (*Lepus europaeus* Pallas). Thesis, Tierärztliche Hochschule, Hannover, Germany, 142 pp.
- LAMARQUE, F., J. BARRAT, AND F. MOUTOU. 1996. Principal diagnoses for determining causes of mortality in the European brown hare (*Lepus europaeus*) found dead in France between 1986 and 1994. *Gibier Faune Sauvage* 13: 53–72.
- LAVAZZA, A., AND G. VECCHI. 1989. Osservazioni su alcuni episodi di mortalità nelle lepri. Evidenziazione al microscopio elettronico di una particella virale. Nota preliminare. *Selezione Veterinaria* 30: 461–467.
- , M. T. SCICLUNA, AND L. CAPUCCI. 1996. Susceptibility of hares and rabbits to the European brown hare syndrome virus and rabbit haemorrhagic disease virus under experimental conditions. *Journal of Veterinary Medicine, Series B* 43: 401–410.
- LINDEN, H., M. HARIO, AND M. WIKMAN (EDS). 1996. Riistan jäljille. Finnish Game and Fisheries Research Institute, Edita, Helsinki, Finland, 208 pp.
- LUNA, L. G. (ED.). 1968. Manual of the histologic staining methods for the Armed Forces Institute of Pathology, 3rd Edition. McGraw Hill Company, New York, New York, 258 pp.
- SALMELA, P., K. BELAK, AND D. GAVIER-WIDEN. 1993. The occurrence of European brown hare syndrome in Finland. *Acta Veterinaria Scandinavica* 34: 215–217.
- SCICLUNA, M. T., A. LAVAZZA, AND L. CAPUCCI. 1994. European brown hare syndrome in northern Italy: Results of a virological and serological survey. *Revue Scientifique et Technique* 13: 893–904.
- SECK-LANZENDORF, S. 1997. The influence of the ecofactor diseases on the population of the European brown hare (*Lepus europaeus*) in the research station Czempin in Poland. Dissertation, www.diss.fu-berlin.de/1998/85/index.html. 239 pp.
- STEINECK, T., AND N. NOWOTNY. 1993. European brown hare syndrome (EBHS) in Austria: Epidemiological investigations. *Tierärztliche Umschau* 48: 225–229.

Received for publication 3 December 2003.