

PATHOLOGICAL FEATURES IN MARINE BIRDS AFFECTED BY THE PRESTIGE'S OIL SPILL IN THE NORTH OF SPAIN

Authors: Balseiro, A., Espí, A., Márquez, I., Pérez, V., Ferreras, M. C.,
et al.

Source: Journal of Wildlife Diseases, 41(2) : 371-378

Published By: Wildlife Disease Association

URL: <https://doi.org/10.7589/0090-3558-41.2.371>

BioOne Complete (complete.BioOne.org) is a full-text database of 200 subscribed and open-access titles in the biological, ecological, and environmental sciences published by nonprofit societies, associations, museums, institutions, and presses.

Your use of this PDF, the BioOne Complete website, and all posted and associated content indicates your acceptance of BioOne's Terms of Use, available at www.bioone.org/terms-of-use.

Usage of BioOne Complete content is strictly limited to personal, educational, and non - commercial use. Commercial inquiries or rights and permissions requests should be directed to the individual publisher as copyright holder.

BioOne sees sustainable scholarly publishing as an inherently collaborative enterprise connecting authors, nonprofit publishers, academic institutions, research libraries, and research funders in the common goal of maximizing access to critical research.

PATHOLOGICAL FEATURES IN MARINE BIRDS AFFECTED BY THE PRESTIGE'S OIL SPILL IN THE NORTH OF SPAIN

A. Balseiro,^{1,3} A. Espí,¹ I. Márquez,¹ V. Pérez,² M. C. Ferreras,² J. F. García Marín,² and J. M. Prieto¹

¹ Servicio Regional de Investigación y Desarrollo Agroalimentario (SERIDA), Laboratorio de Sanidad Animal, 33299 Jove, Gijón, Asturias, Spain

² Departamento de Patología Animal: Medicina Animal (Anatomía Patológica), Facultad de Veterinaria, Universidad de León. Campus de Vegazana, s/n, 24071 León, Spain

³ Corresponding author (email: abalseiro@serida.org)

ABSTRACT: A total of 2,465 seabirds, mainly common murrelets (*Uria aalge*), razorbills (*Alca torda*), and puffins (*Fratercula arctica*) that beached in the northwestern part of Spain after the “Prestige” oil spill on 19 November 2002 were examined by pathological methods. Birds were divided into three groups: dead birds with the body covered (group 1) or uncovered (group 2) by oil and birds recovered alive but which died after being treated at a rescue center (group 3). The main gross lesions were severe dehydration and emaciation. Microscopically, hemosiderin deposits, related to cachexia and/or hemolytic anemia, were observed in those birds harboring oil in the intestine. Severe aspergillosis and ulcers in the ventriculus were found only in group 3 birds, probably because of stress associated with attempted rehabilitation at the rescue center. The mild character of the pathological changes suggests that petroleum oil toxicosis causes multiple sub-lethal changes that have an effect on the ability of the birds to survive at sea, especially weak and young, inexperienced animals. Dehydration and exhaustion seem to be the most likely cause of death.

Key words: Lesions, oil, pathology, Prestige, seabirds, spill.

INTRODUCTION

One of the effects of petroleum pollution of the world oceans and seas is mortality of seabirds (Jessup and Leighton, 1996; Camphuysen and Heubeck, 2001). On 19 November 2002, the tanker “Prestige” broke in two in front of the Galician coast, along the northwestern corner of Spain, discharging 70,000 tons of petroleum oil. Fuel analyzed by the Spanish authorities had a high viscosity and density and high levels of several polycyclic aromatic hydrocarbons (PAH) and heavy metals, mainly zinc, lead, copper, and cadmium (CSIC, 2003). Polycyclic aromatic hydrocarbons contribute significantly to the toxicity of crude petroleum products (Jessup and Leighton, 1996; Rocke, 2001). The number of birds affected was significant because the spill occurred during one of the main migratory periods for seabirds, so a large number of birds were in the area.

Birds exposed to spills can be affected both external and internally. Oil sticks to feathers, causing them to mat and sepa-

rate, impairing waterproofing and exposing the bird's sensitive skin to extreme temperatures. Instinctively, the bird tries to remove oil from the feathers by preening, which results in the animal ingesting the oil. Hemolytic anemia induced by ingestion of oil has been described in seaducks and Atlantic puffins (Leighton et al., 1983; Jessup and Leighton, 1996; Yamato et al., 1996). Reported effects of petroleum toxicosis also include gastrointestinal irritation and hemorrhage, as well as liver and kidney disorders (Rocke, 2001).

The importance of detailed studies to monitor causes of death in beached, oiled birds has been previously stated (Camphuysen and Heubeck, 2001). However, few studies have characterized the effects of oil in birds under natural conditions. Therefore, the main objective of this study was to contribute information on pathology and pathogenesis of petroleum toxicosis in seabirds through evaluation of lesions encountered in animals affected to different degrees by the pollution caused by the “Prestige” spill.

TABLE 1. Distribution of examined animals according to the species, sex and age.

Species	Total No. (%) ^a	No. of males (%)	No. of females (%)	No. of adults (%)	No. of immatures (%)
Common murres (<i>Uria aalge</i>)	1,584 (64)	1,188 (75)	396 (25)	412 (26)	1,172 (74)
Razorbills (<i>Alca torda</i>)	379 (15)	193 (51)	186 (49)	80 (21)	299 (79)
Atlantic puffins (<i>Fratercula arctica</i>)	343 (14)	182 (53)	161 (47)	281 (82)	62 (18)
Gulls (<i>Larus</i> spp.)	53 (2.2)	24 (45)	29 (55)	15 (29)	38 (71)
Northern gannets (<i>Sula bassana</i>)	40 (1.7)	16 (39)	24 (61)	15 (37)	25 (63)
Cormorants (<i>Phalacrocorax</i> spp.)	21 (0.9)	11 (52)	10 (48)	16 (75)	5 (25)
Dovekies (<i>Alle alle</i>)	7 (0.3)	4 (57)	3 (43)	7 (100)	0 (0)
Common loons (<i>Gavia immer</i>)	5 (0.2)	2 (40)	3 (60)	5 (100)	0 (0)
Northern fulmars (<i>Fulmarus glacialis</i>)	5 (0.2)	4 (80)	1 (20)	5 (100)	0 (0)
Other species	28 (1.5)	17 (61)	11 (39)	26 (93)	2 (7)
Total	2,465 (100)	1,641 (67)	824 (33)	862 (35)	1,603 (65)

^a First (Total No.) column (%) is based on total number of all birds. Remaining columns (%) is based on total number of birds for individual species.

MATERIALS AND METHODS

Animals

A total of 2,465 birds, belonging to multiple species, were recovered from the coast of Asturias (North of Spain) between 43°25'36–4°44'79 and 43°33'39–7°02'31 (Table 1). Animals were classified into groups according to their status when recovered and the gross appearance of the carcass: Birds from Group 1 ($n=715$, 29%) were found dead on beaches, and the body was covered by oil to varying degrees; Group 2 ($n=172$, 7%) included dead birds recovered from the beaches that were not covered by oil; and Group 3 ($n=1578$, 64%) was composed of birds recovered alive from beaches, but impregnated by oil to varying degrees. These birds were brought to the Bird Rescue Center of Avilés (Asturias), where they were cleaned, hydrated, fed, treated with activated charcoal, and eventually died.

Pathological studies

Complete necropsy was performed and gross lesions recorded in all the birds. Only those in which the tissues had no or minimal autolytic changes were selected for histopathologic examination (Table 2). Samples of the lung, liver, kidney, spleen, ventriculus, proventriculus, intestine, and uropygial gland were collected, fixed in 10% neutral-buffered formalin, and dehydrated through graded alcohols before being embedded in paraffin wax. Several serial sections, 4- μ m thick, were cut from each sample and stained with hematoxylin and eosin (H&E), Perl's Prussian blue method for hemosiderin, and periodic acid-Schiff (PAS). In selected sections from birds belonging to group 3, an avidin-biotin-peroxidase (Vector Lab., Burlingame, California, USA) immunohistochemical

technique was performed, using two monoclonal antibodies that react with the fungal elements that cause aspergillosis and zygomycosis, respectively, both diluted at 1:5 (Dako, Glotstrup, Denmark). Sections positive and negative for both fungal infections were used as controls.

RESULTS

Epidemiological findings

The majority of birds recovered were common murres (*Uria aalge*, 64%), razorbills (*Alca torda*, 15%), and puffins (*Fratercula arctica*, 14%), although other species were also recovered (Table 1). There were no apparent differences between sexes in the different species recovered, but in the majority of the birds, the number of immature specimens was greater than adults (Table 1).

Pathological findings

Among each of the groups, no differences in lesions were found, regardless of species, age, or sex.

Group 1: At necropsy, dehydration, characterized by loss of elasticity of the skin and difficulty in reflecting the skin from the underlying musculature, and diarrhea, evaluated by the presence of a liquid fecal content surrounding the cloaca, were observed. Petroleum covered the surface of the bodies in varying degrees, from less than 10% to 100%. Emaciation

TABLE 2. Number of species in which the tissues were selected for histophologic examination.

Species	Group 1 ^a		Group 2 ^b		Group 3 ^c	
	Total	Examined histologically (%)	Total	Examined histologically (%)	Total	Examined histologically (%)
Common murres (<i>Uria aalge</i>)	479	151 (31.5)	93	39 (41.9)	1,012	22 (2.1)
Razorbills (<i>Alca torda</i>)	92	32 (34.7)	27	8 (29.6)	260	6 (2.3)
Atlantic puffins (<i>Fratercula arctica</i>)	56	15 (26.7)	16	7 (43.7)	271	10 (3.6)
Gulls (<i>Larus</i> spp.)	35	4 (11.4)	18	4 (22.2)	0	0 (0)
Northern gannets (<i>Sula bassama</i>)	14	3 (21.4)	6	2 (33.3)	20	1 (5)
Cormorants (<i>Phalacrocorax</i> spp.)	4	3 (75)	2	2 (100)	15	1 (6.6)
Dovekies (<i>Alle alle</i>)	5	0 (0)	2	0 (0)	0	0 (0)
Common loons (<i>Gavia immer</i>)	5	1 (20)	0	0 (0)	0	0 (0)
Northern fulmers (<i>Fulmarus glacialis</i>)	5	1 (20)	0	0 (0)	0	0 (0)
Other species	20	0 (0)	8	0 (0)	0	0 (0)
Total	715	210 (29.3)	172	62 (36)	1,578	40 (2.5)

^a Birds found dead that were covered by petroleum oil.^b Birds found dead that were not covered by petroleum oil.^c Birds from the Bird Rescue Center of Avilés. (%) based on total in preceding column.

characterized by severe atrophy of the pectoral muscles and complete absence of subcutaneous and/or abdominal fat deposits, as well as serous atrophy of the pericardial fat was noted in all the birds (Fig. 1). Dark material similar to the material on the skin and consistent with oil was pre-

sent in the ventriculus, proventriculus, and intestinal lumen, along with petechiae in the mucosa.

Microscopically, hepatocytes and Kupfer cells contained brown pigment consistent with hemosiderin, as demonstrated by Perl's Prussian blue stain (Fig. 2). Deposits

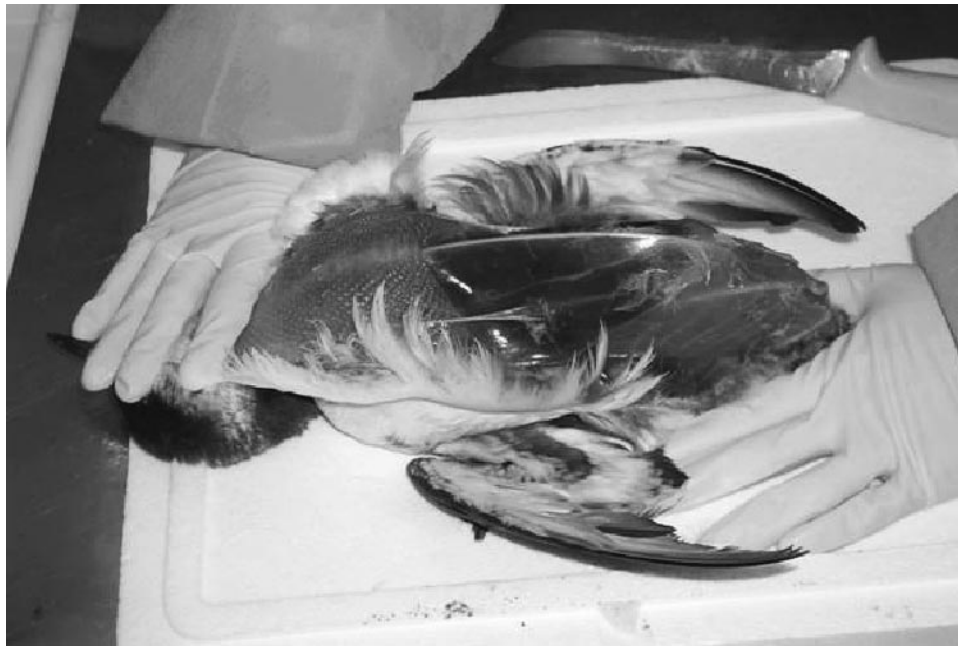

FIGURE 1. Cachectic common murre with severe atrophy of the pectoral muscles and absence of subcutaneous fat.

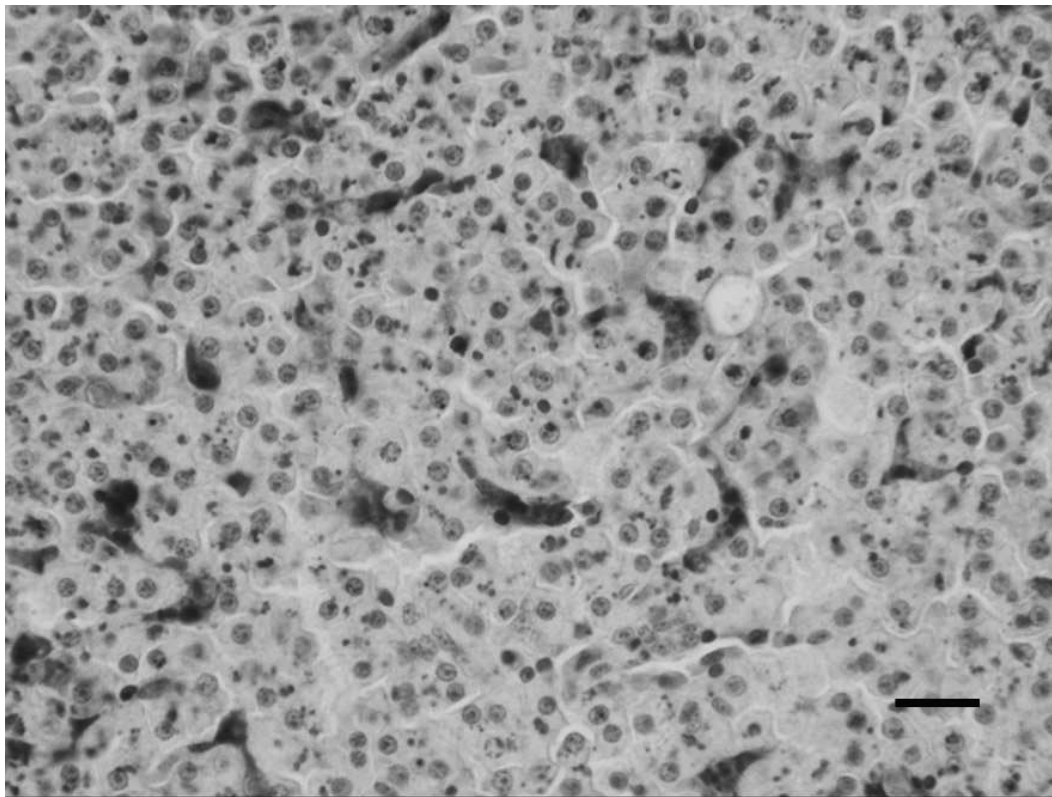


FIGURE 2. Liver; cormorant. Deposits of haemosiderin in the hepatocytes and Kupffer cells. Perl's Prussian blue. Bar = 40 μ m.

of this pigment were also seen in macrophages in the spleen and in the kidney. In kidney, small, spheroid, basophilic intratubular accumulations consistent with urates were common (Fig. 3). Urates were also present in the liver or the spleen but always in lower levels than in the kidney.

Group 2: At necropsy, birds were dehydrated and had evidence of diarrhea similar to group 1 birds, but these birds were not covered by oil. All birds were cachectic and had hemorrhages in the lungs, liver, kidney, spleen, and intestine. Sixty percent of birds from this group had varying amounts of oil in the intestinal lumen that was similar in appearance to group 1.

Microscopically, birds with oil in the intestine had lesions similar to group 1 birds. However, in the birds without oil in the intestine, hemosiderin deposits were not observed in tissues.

Group 3: All birds from group 3 had signs of severe dehydration and diarrhea at necropsy. Broken feathers and skin erosions were also common. No oil was detected on the surface of the birds, but these birds had been cleaned at the center. Besides some degree of emaciation, the main finding was severe, disseminated aspergillosis characterized by multiple small, whitish fungal plaques located on the lungs, air sacs, kidney, and liver in 28% of the birds (Fig. 4). A few birds from this group had ulcers in the ventricular mucosa. No oil was detected in the intestinal lumen.

Microscopically, the whitish plaques contained PAS-positive fungal hyphae. These fungal structures were identified as *Aspergillus fumigatus* on the basis of their morphology and strong and uniform immunoreactivity with the monoclonal anti-

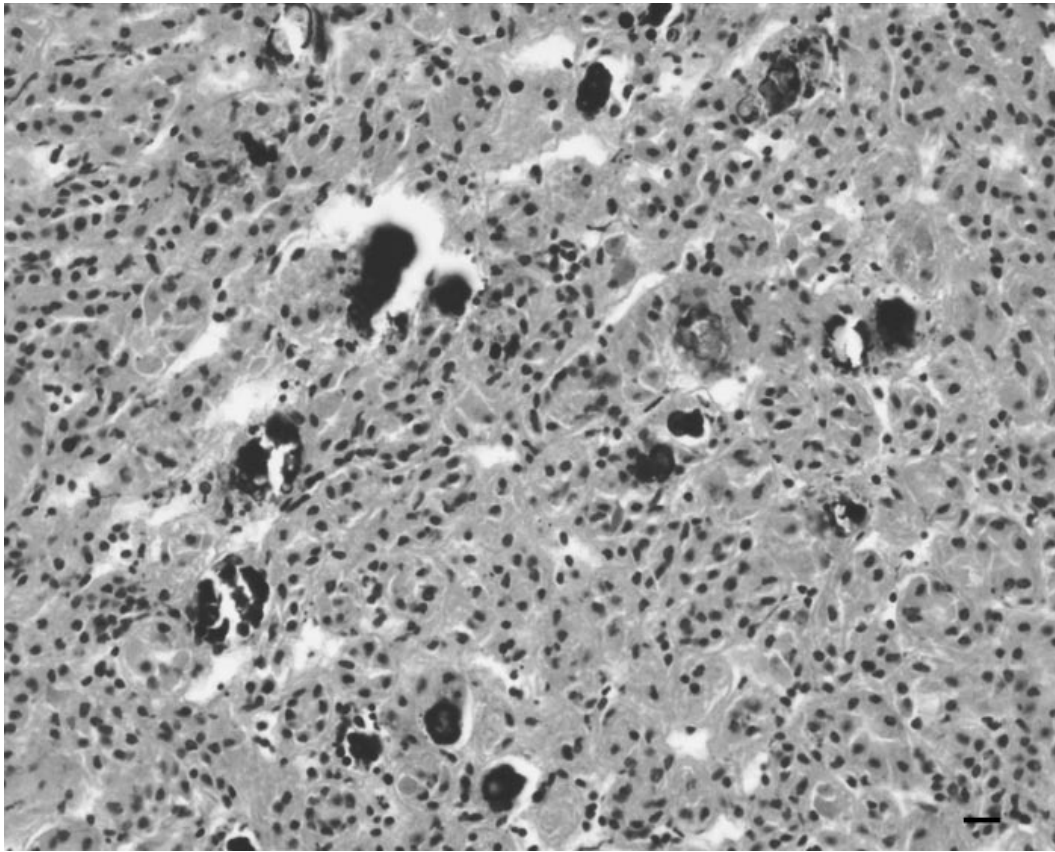


FIGURE 3. Kidney; common murre. Intratubular accumulations of basophilic material (small spheroids) consistent with urate deposits. H&E. Bar = 40 μ m.

body to *A. fumigatus* used for immunohistochemical staining. Additional microscopic lesions included hemosiderin deposits, as in the other groups, and the presence of large numbers of protozoal parasites, identified as *Eimeria* spp., within intestinal epithelial cells of some birds.

DISCUSSION

Based on the number of dead birds with indications of having been in contact with oil, the Prestige oil spill appears to have caused significant mortality in marine birds in the area, similar to other oil spills (Wood et al., 1993; Jessup and Leighton, 1996; Camphuysen and Heubeck, 2001). However, normal mortality rates and causes in marine birds from these areas are not available for comparison.

Severe dehydration and emaciation

were the most outstanding findings at necropsy. This suggests birds suffering from previous weakness were those in which petroleum had more severe consequences. Stress, fright, hypothermia, dehydration, and exhaustion may be associated with oiling (Briggs et al., 1996; Rocke, 2001), and oiling can induce a significant decrease in body and organ weight (Bouqueneau et al., 1997). These factors could have contributed to reduce the ability of previously weak animals to overcome the effects of petroleum. The high percentage of immature birds affected was also a remarkable feature; thus, severe consequences could have been related to inexperience and/or age-associated differences in susceptibility. However, as no detailed surveys on age or type of birds present in the area at this time of the year are available, po-

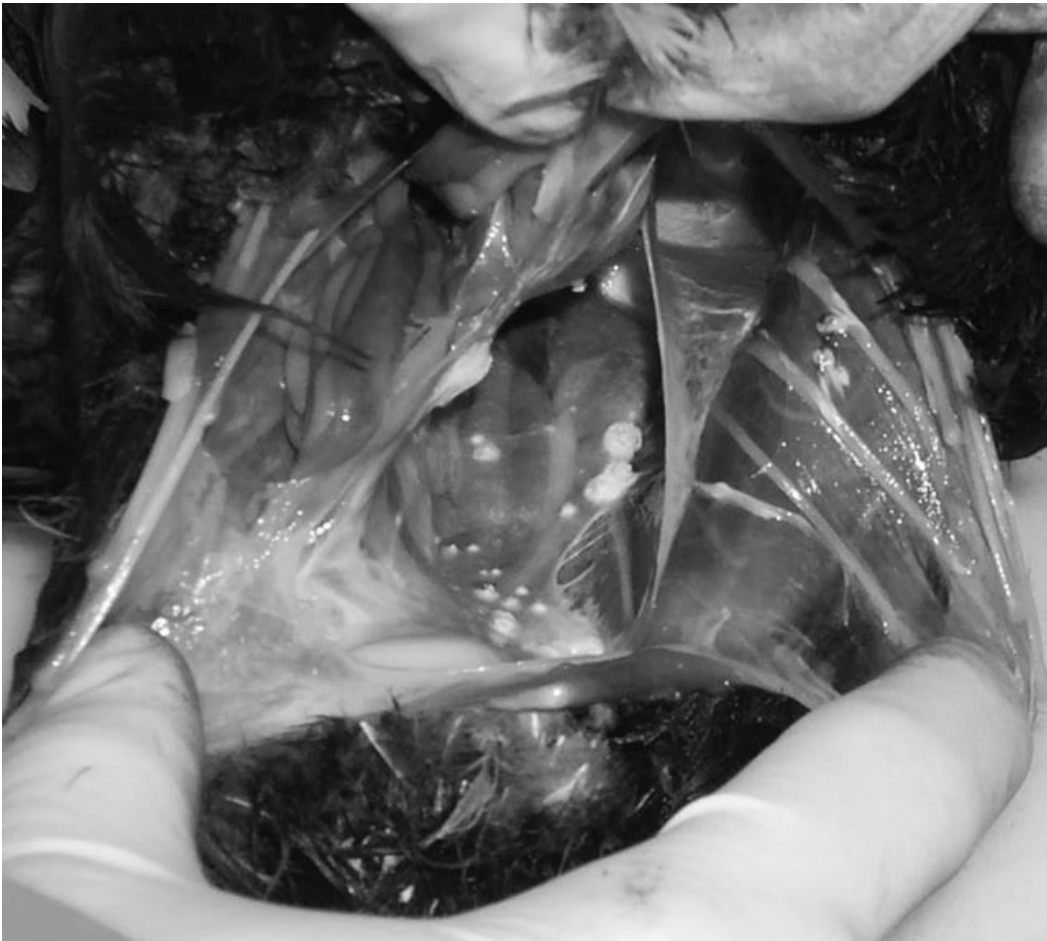

FIGURE 4. Guillemot. Disseminated aspergillosis characterized by multiple small and whitish fungal plaques.

tential age-related susceptibility must be interpreted with caution.

Ingestion of oil while preening could have resulted in mucosal irritation resulting from the presence of a variety of irritants in the oil (Ringler, 1997), including naphthalenes (Jones et al., 1997), a type of PAH encountered in high amounts in the petroleum spilled by the Prestige (CSIC, 2003; IFREMER, 2003). As previously reported (Rocke, 2001; Fudge, 2002), the irritant effect of PAH could have reduced the absorption of nutrients and contributed to cachexia and diarrhea seen in most of the birds.

Urate deposition in the kidney, spleen, and liver in these birds could be related to

the cachexia and severe dehydration. Urate deposition can occur if there is an excess of electrolytes, particularly sodium and potassium ions, associated with a reduced water content of the urine (Radin et al., 1996). In previous cases of oil spillage, this lesion has been also reported in dehydrated shags *Phalacrocorax* spp. (Wood et al., 1993).

Severe hemosiderosis in liver, spleen, and kidney suggests increased hemolysis relative to the rate of iron reuse, as seen in hemolytic anemia or cachexia (Kelly, 1993; Jessup and Leighton, 1996). The fact that the majority of the birds suffered from cachexia could indicate this status as the cause of hemosiderosis; however, al-

though its role should be taken into account, the fact that hemosiderin deposits were not constantly found in emaciated birds from other groups, implicates other causes. Red blood cells appear to be a primary target of oil toxicity, and in marine birds, severe hemolytic anemia, mediated by oxidative chemical compounds, accompanied by an increase in hemosiderin deposition may occur (Leighton et al., 1983; Leighton, 1986; Yamato et al., 1996). In this study, hemosiderosis was only found in birds with oil in the digestive tract, supporting this hypothesis.

Although no renal damage was observed, potentially nephrotoxic compounds, such as halogenated hydrocarbons, arsenic, or lead, were present in the Prestige's petroleum (Szaro et al., 1978; Gopinath et al., 1987; Coppock et al., 1996; CSIC, 2003).

Despite a high success rate (Bird Rescue Center of Avilés, pers. comm.), a large proportion of birds submitted to the Rescue Center died (Group 3). Most had disseminated aspergillosis, one of the most frequent infectious diseases affecting stressed and immunosuppressed animals (Briggs et al., 1996; Carrasco et al., 2001; Friend, 2001). In these birds, stress associated with captivity, dehydration, and emaciation would have been the main predisposing factors for developing severe aspergillosis. Intestinal coccidiosis and ventricular ulcers were only encountered in this group and could be related to stress, as reported in other species (Lipscomb et al., 1993; Grabarevic et al., 1993).

Findings in this study support previous indications that oil spills are responsible for massive seabird deaths (Briggs et al., 1996). The type and severity of lesions suggest that ingestion of crude oil causes multiple effects that might impair a bird's ability to survive at sea, as previously proposed by Miller et al. (1978), affecting cachectic birds and young, inexperienced birds more severely. Dehydration and exhaustion, in previously weak animals, is probably the most likely cause of death.

Further investigations are needed to understand the toxic effects of petroleum in marine birds more fully.

LITERATURE CITED

- BOUQUEGNEAU, J. M., F. COIGNOUL, K. DAS, V. DEBACKER, J. HAELTERS, L. HOLSBECK, T. JAUNIAUX, C. JOIRIS, E. STIENEN, J. TAVERNIER, AND J. VAN WAEYENBERGE. 1997. North Sea seabirds and marine mammals: Pathology and ecotoxicology. In First scientific support plan for sustainable development policy (SPSD 1). Flanders Marine Institute, <http://www.vliz.be/cgi-bin/vmdc2web.exe?action=ProID&ProID=75>. Accessed.
- BRIGGS, K. T., S. H. YOSHIDA, AND M. E. GERSHWIN. 1996. The influence of petrochemicals and stress on the immune system of seabirds. *Regulatory Toxicology and Pharmacology* 23: 145–155.
- CAMPHUYSEN, C. J., AND M. HEUBECK. 2001. Marine oil pollution and beached bird surveys: The development of a sensitive monitoring instrument. *Environmental Pollution* 112: 443–461.
- CARRASCO, L., J. S. LIMA, JR., D. C. HALFEN, F. J. SALGUERO, P. SANCHEZ-CORDON, AND G. BECKER. 2001. Systemic aspergillosis in an oiled magallanic penguin (*Spheniscus magellanicus*). *Journal of Veterinary Medicine, Series B* 48: 551–554.
- COPPOCK, R. W., M. S. MOSTROM, E. L. STAIR, AND S. S. SEMALULU. 1996. Toxicopathology of oil-field poisoning in cattle: A review. *Veterinary and Human Toxicology* 38: 36–42.
- [CSIC] CONSEJO SUPERIOR DE INVESTIGACIONES CIENTÍFICAS. 2003. Informes técnicos CSIC-Prestige. Ministerio de Ciencia y Tecnología: 01. Caracterización del vertido y evolución preliminar en el medio. 02. Presencia de metales pesados en la zona de hundimiento del petrolero Prestige y composición de metales y complejantes del fuel emulsionado de la costa, <http://csicprestige.iim.csic.es>. Accessed.
- FRIEND, M. 2001. Aspergillosis. *Field Manual of wildlife diseases: General field procedures and diseases of birds*, National Wildlife Health Center, Madison, Wisconsin, Section 3, 13: 129–133.
- FUDGE, N. 2002. Assessing the value of the rehabilitation of oiled birds. An essay for ornithology 4620, www.mun.ca/acwern/oil.html. Accessed.
- GOPINATH, C., D. E. PRENTICE, AND J. LEWIS. 1987. The urinary system. In *Atlas of experimental toxicological pathology*, Volume 13, 1st Edition, G. A. Gresham (ed.). MTP Press Ltd., Lancaster, UK, pp. 77–90.
- GRABAREVIC, Z., M. TISLJAR, P. DZAJA, B. ARTUKOVIC, S. SEIWERTH, AND P. SIKIRIC. 1993. Stress-induced gizzard erosion in chicks, I: Gross and histopathological findings. *Zentralblatt für Veterinärmedizin. Reihe A* 40: 265–270.
- [IFREMER] L'INSTITUT FRANÇAIS DE RECHERCHE

- POUR L'EXPLOITATION DE LA MER. 2003. Les analyses du fioul du Prestige, <http://www.ifremer.fr/envlit/prestige/prestrigefioulana.htm>. Accessed.
- JESSUP, D. A., AND T. E. LEIGHTON. 1996. Oil pollution and petroleum toxicity to wildlife. *In* Non-infectious diseases of wildlife, 2nd Edition, G. L. Hoff, A. Fairbrother, and L. Locke (eds.). Iowa State University Press, Ames, Iowa, pp. 141–157.
- JONES, T. C., R. D. HUNT, AND N. W. KING. 1997. Diseases due to extraneous poisons. *In* Veterinary pathology, 6th Edition, T. C. Jones, R. D. Hunt, and N. W. King (eds.). Williams and Wilkins, Baltimore, Maryland, pp. 695–780.
- KELLY, W. R. 1993. The liver and biliary system. pathology of domestic animals. Volume 2, 4th Edition, K. V. F. Jubb, P. C. Kennedy, and N. Palmer (eds.). Academic Press Ltd., San Diego, California, pp. 319–406.
- LEIGHTON, F. A. 1986. Clinical, gross and histological findings in herring gulls and Atlantic puffins that ingested Prudhoe Bay crude oil. *Veterinary Pathology* 23: 254–263.
- , D. B. PEAKALL, AND R. G. BUTLER. 1983. Heinz-body haemolytic anemia from the ingestion of crude oil: A primary toxic effect in marine birds. *Science* 220: 871–873.
- LIPSCOMB, T. P., R. K. HARRIS, R. B. MOELLER, J. M. PLETCHER, R. J. HAEBLER, AND B. E. BALACHEY. 1993. Histopathologic lesions in sea otters exposed to crude oil. *Veterinary Pathology* 30: 1–11.
- MILLER, D. S., D. B. PEAKALL, AND W. B. KINTER. 1978. Ingestion of crude oil: Sublethal effects in herring gull chicks. *Science* 199: 315–317.
- RADIN, M. J., D. E. SWAYNE, A. GIGLIOTTI, AND T. HOEPF. 1996. Renal function and organic anion and cation transport during dehydration and/or food restriction in chickens. *Journal of Comparative Physiology* 166: 138–143.
- RINGLER, D. J. 1997. Inflammation and repair. *In* Veterinary pathology, 6th Edition, T. C. Jones, R. D. Hunt, and N. W. King (eds.). Williams and Wilkins, Baltimore, Maryland, pp. 113–158.
- ROCKE, T. E. 2001. Oil. Field manual of wildlife diseases: General field procedures and diseases of birds, National Wildlife Health Center, Madison, Wisconsin, Section 7 42: 309–315.
- SZARO, R. C., M. P. DIETER, G. H. HEINZ, AND J. F. FERRELL. 1978. Effects of chronic ingestion of south Louisiana crude oil on mallard ducklings. *Environmental Research* 17: 426–436.
- WOOD, A. M., R. MUNRO, AND I. ROBINSON. 1993. Oiled birds from Shetland, January 1993. *Veterinary Record* 132: 367–368.
- YAMATO, O., I. GOTO, AND Y. MAEDE. 1996. Hemolytic anemia in wild seaducks caused by marine oil pollution. *Journal of Wildlife Disease* 32: 381–384.