



Angiostrongylus vasorum Infection in a Coyote (*Canis latrans*) from Newfoundland and Labrador, Canada

Authors: Bourque, Andrea, Whitney, Hugh, and Conboy, Gary

Source: Journal of Wildlife Diseases, 41(4) : 816-819

Published By: Wildlife Disease Association

URL: <https://doi.org/10.7589/0090-3558-41.4.816>

BioOne Complete (complete.BioOne.org) is a full-text database of 200 subscribed and open-access titles in the biological, ecological, and environmental sciences published by nonprofit societies, associations, museums, institutions, and presses.

Your use of this PDF, the BioOne Complete website, and all posted and associated content indicates your acceptance of BioOne's Terms of Use, available at www.bioone.org/terms-of-use.

Usage of BioOne Complete content is strictly limited to personal, educational, and non - commercial use. Commercial inquiries or rights and permissions requests should be directed to the individual publisher as copyright holder.

BioOne sees sustainable scholarly publishing as an inherently collaborative enterprise connecting authors, nonprofit publishers, academic institutions, research libraries, and research funders in the common goal of maximizing access to critical research.

Angiostrongylus vasorum Infection in a Coyote (*Canis latrans*) from Newfoundland and Labrador, Canada

Andrea Bourque,^{1,3} Hugh Whitney,² and Gary Conboy¹ ¹ Department of Pathology and Microbiology, Atlantic Veterinary College, 550 University Avenue, Charlottetown, Prince Edward Island C1A 4P3, Canada; ² Animal Health Division, Newfoundland and Labrador Department of Natural Resources, PO Box 7400, St. John's, Newfoundland A1E 3Y5, Canada; ³ Corresponding author (email: abourque@upe.ca).

ABSTRACT: Tissue samples and feces were collected from a dead, adult female coyote (*Canis latrans*) found at the side of the road in late March 2003 in the Avalon Peninsula region of Newfoundland, Canada. The coyote apparently died of vehicular-related trauma. Samples of lung, brain, heart, liver, and kidney were fixed in formalin and submitted for histologic examination. The entire remaining lung and heart also were submitted for examination. The coyote was diagnosed with moderate, multifocal, granulomatous interstitial pneumonia with eosinophilic vasculitis and many intralesional nematode eggs, larvae, and occasional intravascular adult worms. Adult nematodes recovered from the pulmonary arteries were identified as *Angiostrongylus vasorum*. Small foci of granulomatous inflammation, often containing nematode eggs and larvae, were scattered in the brain and kidney. To our knowledge, this is the first report of *A. vasorum* infection in a coyote from the only endemic area of infection in North America.

Key words: *Angiostrongylus vasorum*, *Canis latrans*, coyote, histology, pneumonia, vasculitis

Angiostrongylus vasorum, or French heartworm, is a metastrongylid nematode that infects the pulmonary arteries and right ventricle of various species of fox, including red fox (*Vulpes vulpes*), African desert fox (*Fennecus zerda*), crab-eating zorro (*Dusicyon thous*) (Bolt et al., 1994), and Brazilian hoary fox (*Dusicyon vetulus*) (Lima et al., 1994). Infection also has been reported in domestic dogs (*Canis familiaris*) (Bolt et al., 1994), wolves (*Canis lupus*) (Segovia et al., 2001), and Eurasian badgers (*Meles meles*) (Torres et al., 2001). Patent experimental infections have been reported in a jackal (*Canis aureus*) and the Nile rat (*Arvicanthis niloticus*), and non-patent experimental infections have been reported in domestic cats (*Felis catus*) (Bolt et al., 1994). Angiostrongylosis has

been reported in Europe, Africa, South America, and North America (Bolt et al., 1994). The single endemic focus in North America occurs in the Canadian province of Newfoundland and Labrador. Infection was first reported on the island of Newfoundland in red fox (Smith and Threlfall, 1973) and has since been reported in dogs (Bourque et al., 2002; Conboy, 2004). The purpose of the present communication is to report a patent infection of *A. vasorum* in an adult coyote (*Canis latrans*) and to describe the associated lesions.

An adult, female coyote in fair body condition was found dead on the side of a highway in late March 2003 in Witless Bay, south of the city of St. John's, Newfoundland and Labrador, Canada (47°27'00"N, 52°57'30"W). The cause of death of the coyote was attributed to obvious, severe, vehicle-related trauma. The lungs and heart were harvested. Samples of lung, liver, heart, brain, and kidney were fixed in 10% formalin. Feces were collected and examined using the Baermann technique. The feces used in the Baermann technique were weighed, and the total number of first-stage larvae (L₁) collected was counted to calculate the number of first-stage larvae per gram of feces (L₁/g feces). Pulmonary arteries were dissected from the large, main branches near the heart to the apical margins of the lung lobes in an attempt to collect adult worms for definitive nematode identification.

Grossly, the lungs had a mottled, red-and-tan appearance and were slightly heavy; occasionally, poorly defined, scattered, slightly firm nodules could be palpated. Several intact adult worms were recovered from pulmonary arteries. Airways

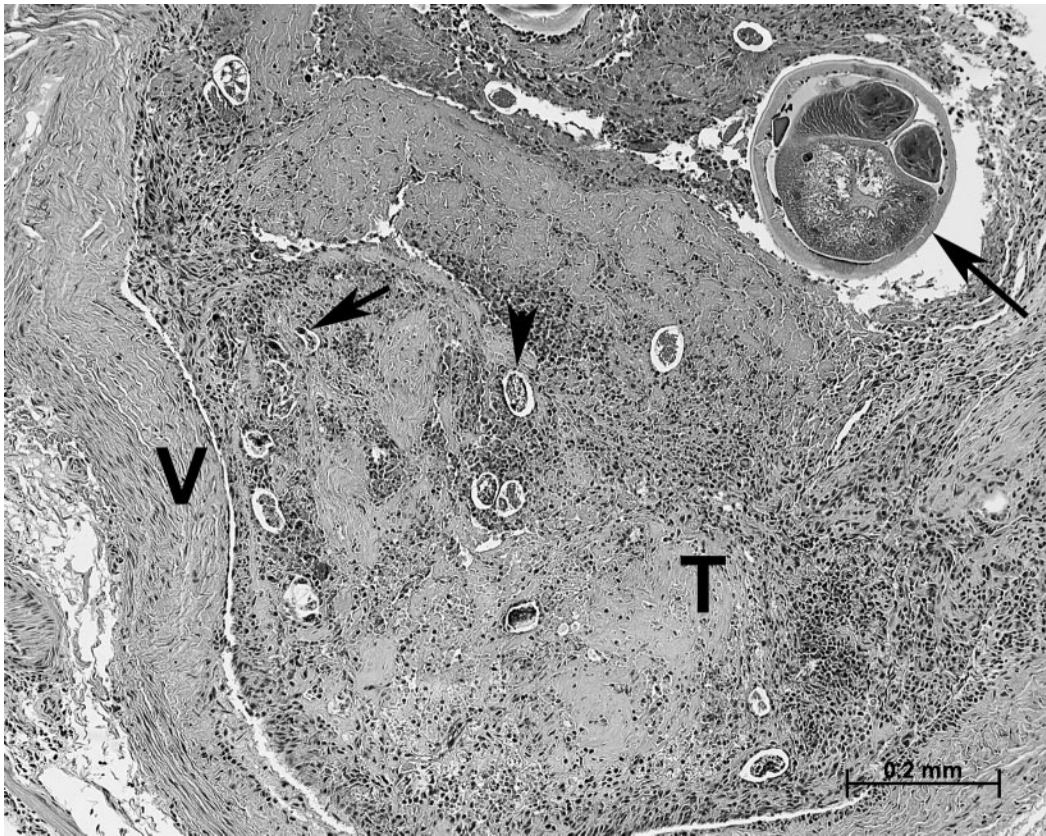


FIGURE 1. A large pulmonary artery (V = vessel wall) containing a partially organized thrombus (T) with embedded cross-sections of adult nematodes (long arrow), eggs (arrowhead illustrates one), and larvae (short arrow illustrates one). Prominent infiltrates of eosinophils and mononuclear cells are seen within the vessel wall and the thrombus. H&E stain. Bar = 0.2 mm.

did not contain nematodes. Microscopically, tissues were moderately autolyzed, but several sections revealed many scattered foci where the interstitium and alveoli contained nematode larvae and eggs associated with mild to moderate interstitial fibrosis and moderate infiltrates of mononuclear cells, consisting predominantly of macrophages and scattered foreign body-type, multinucleated giant cells. Many clusters of macrophages laden with hemosiderin also were present within the alveolar interstitium and pleura. Larvae were approximately 15 μm wide and contained numerous discrete basophilic and eosinophilic granules. Eggs were oval, thin-walled, and approximately 40–50 μm at greatest diameter, and they contained

eosinophilic, finely granular material. Surrounding alveoli were flooded with proteinaceous fluid. Several large arteries had narrowing of the lumina and thickening of the tunica intima because of moderate infiltrates of eosinophils, lymphocytes, and plasma cells as well as mild fibrosis. The tunica media also was thickened because of smooth muscle hypertrophy and hyperplasia. In one section, a large pulmonary artery was partially occluded by proliferation of fibroblastic tissue containing mild infiltrates of eosinophils, cellular debris, and entrapped nematode eggs (Fig. 1). The remaining lumen was filled with fibrin, moderate numbers of eosinophils, nematode eggs, and several cross-sections of adult nematodes. These adult worms

were approximately 300 μm in diameter and had a thin and smooth cuticle, a thin hypodermis with low lateral cords, a coelomyarian musculature, an intestine lined by tall columnar epithelium, and cross-sections of the reproductive tract. The wall of this artery was infiltrated by moderate numbers of eosinophils, plasma cells, and macrophages. In the cerebral cortex, rare, small, discrete perivascular and parenchymal infiltrates of mononuclear cells, consisting of lymphocytes, plasma cells, and macrophages, were found. In the center of one such focus in the gray matter was a cross-section of a larva similar to that described in the lung. Similar granulomatous foci, also centered on nematode larvae, were rare and scattered in the cortex of the kidney. No significant gross or microscopic abnormalities were present in the heart or liver.

First-stage nematode larvae were recovered on Baermann fecal examination. The larvae (349.4 L_1/g feces) were approximately 350 μm in length and had a cephalic button and a kinked tail with a dorsal spine. The larvae appeared to be normal but showed no signs of motility after Baermann recovery. The size and morphology were consistent with those of first-stage larvae of *A. vasorum* (Bolt et al., 1994). Adult worms (three females and one male) collected from the pulmonary arteries were 14–20 mm in length. The nematodes were identified as *A. vasorum* based on the adult male worm bursa morphology and spicule length (left spicule, 455 μm ; right spicule, 442 μm) (Rosen et al., 1971; Kontrimavichus and Delyamure, 1985).

In summary, this coyote had mild to moderate, multifocal to coalescing granulomatous interstitial pneumonia associated with a myriad of nematode eggs and larvae. Adult worms also were associated with thrombosing, eosinophilic vasculitis involving pulmonary arteries. In addition, occasional foci of aberrant parasite migration were found in the brain and kidney associated with granulomatous inflammation.

Microscopic lesions, geographic location, and features of the larval and adult parasites in this case were consistent with infection by *A. vasorum*. Rectal feces contained first-stage larvae, indicating that the infection was patent.

The natural definitive hosts for *A. vasorum* are various species of fox. Adult females in the pulmonary arteries release eggs intravascularly, which then lodge in small vessels and capillaries, where they hatch. First-stage larvae in the interstitium break into alveolar spaces and often are associated with chronic granulomatous pneumonia. Larvae migrate up the tracheobronchial tree, are swallowed, and then are passed in the feces. Gastropod intermediate hosts (terrestrial snails and slugs) become infected by feeding on canid feces. Dogs and foxes become infected by eating gastropods containing the infective, third-stage larvae. In addition, frogs can serve as an intermediate or paratenic host (Bolt et al., 1993). In the canine stomach or intestine, the intermediate or paratenic host is digested, releasing the third-stage larvae, which then migrate through the gastrointestinal wall, continue to mature, and eventually, reach the right ventricle and pulmonary arteries (Bolt et al., 1994). The prepatent period in dogs and foxes is reported to range from 38 to 57 days.

Sporadic cases of angiostrongylosis have been reported in the United States (Michigan) and Canada (Alberta), but these cases have involved dogs that traveled from Europe (Williams et al., 1985; Perry et al., 1991). The only endemic focus of *A. vasorum* infection in North America has been identified in the Avalon Peninsula and the immediately surrounding area on the east coast of the island of Newfoundland. A recent survey involving trapped red fox conducted in 2000–02 (Jeffery et al., 2004) reported that 56% of foxes sampled from the Avalon Peninsula were infected with *A. vasorum*. How the parasite was introduced to the island of Newfoundland remains unknown, but importation of

infected dogs or foxes from Europe has been suggested. Since 1996, increased numbers of domestic dogs from St. John's (the largest urban center in the area), Newfoundland and Labrador, Canada, and the surrounding region have been diagnosed with angiostrongylosis both antemortem (via fecal examination using the Baermann technique) and postmortem (Bourque et al., 2002). A Baermann fecal examination survey (October 2000 to October 2001) found that 24% (16/67) of dogs on the islands of Newfoundland suffering clinical signs of chronic cough were infected with *A. vasorum* (Conboy, 2004), making this parasite and the threat of its spread to the mainland a major veterinary concern in Atlantic Canada.

The effect of *A. vasorum* infection on coyotes in the wild is unknown. In dogs, infection may be subclinical, but in cases of severe and/or chronic infections, reports of exercise intolerance, dyspnea, coagulopathy, and right-heart failure are common. Aberrant foci of parasite migration have been reported frequently in dogs (Perry et al., 1991; Cury and Lima, 1996; Oliveira-Junior et al., 2004), and such foci have been a common finding in dogs we have examined. It has been postulated that the aberrant foci result from hematogenous, systemic dissemination of eggs, larvae, and rarely, adult nematodes that have gained access to the systemic circulation through the lung. The extent of lung damage in this animal may have impaired its health. It is possible that coyotes, in addition to the red fox and domestic dogs, will serve as reservoir host species for *A. vasorum* and as a vector for expanding the current endemic focus of infection within the Avalon Peninsula area of Newfoundland.

We would like to thank Andrew Webber, Conservation Officer with the Government of Newfoundland and Labrador, for the collection of this animal and for bringing it to our attention.

LITERATURE CITED

BOLT, G., J. MONRAD, F. FRANDSEN, P. HENRIKSEN, AND H. H. DIETZ. 1993. The frog (*Rana tem-*

- poraria*) as a potential paratenic and intermediate host for *Angiostrongylus vasorum*. *Parasitology Research* 79: 428–430.
- , ———, J. KOCH, AND A. L. JENSEN. 1994. Canine angiostrongylosis: A review. *Veterinary Record* 135: 447–452.
- BOURQUE A., G. CONBOY, L. M. MILLER, H. WHITNEY, AND S. RALHAN. 2002. *Angiostrongylus vasorum* infection in 2 dogs from Newfoundland. *Canadian Veterinary Journal* 43: 876–879.
- CONBOY G. 2004. Natural infections of *Crenosoma vulpis* and *Angiostrongylus vasorum* in dogs in Atlantic Canada and their treatment with milbemycin oxime. *Veterinary Record* 155: 16–18.
- CURY M. C., AND W. S. LIMA. 1996. Rupture of femoral artery in a dog infected with *Angiostrongylus vasorum*. *Veterinary Parasitology* 65: 313–315.
- JEFFERY R. A., M. W. LANKESTER, J. M. MCGRATH, AND H. WHITNEY. 2004. *Angiostrongylus vasorum* and *Crenosoma vulpis* in red foxes (*Vulpes vulpes*) in Newfoundland, Canada. *Canadian Journal of Zoology* 82: 66–74.
- KONTRIMAVICHUS V. L., AND S. L. DELYAMURE. 1985. *Fundamentals of nematology*, Vol. 29: Filaroids of domestic and wild animals. Oxonian Press Pvt. Ltd., New Delhi, India, 183 pp.
- LIMA W. S., M. P. GUIMARAES, AND I. S. LEMOS. 1994. Occurrence of *Angiostrongylus vasorum* in the lungs of the Brazilian fox *Dusicyon vetulus*. *Journal of Helminthology* 68: 87.
- OLIVEIRA-JUNIOR S. D., J. M. P. BARCANTE, T. A. BARCANTE, V. M. RIBEIRO, AND W. S. LIMA. 2004. Ectopic location of adult worms and first-stage larvae of *Angiostrongylus vasorum* in an infected dog. *Veterinary Parasitology* 121: 293–296.
- PERRY A. W., R. HERTLING, AND M. J. KENNEDY. 1991. Angiostrongylosis with disseminated larval infection associated with signs of ocular and nervous disease in an imported dog. *Canadian Veterinary Journal* 32: 430–431.
- ROSEN L., P. H. LAWRENCE, AND R. ASH. 1970. Life history of the canine lungworm *Angiostrongylus vasorum* (Baillet). *American Journal of Veterinary Research* 31: 131–143.
- SEGOVIA J. M., J. TORRES, J. MIQUEL, L. LLANEZA, AND C. FELIU. 2001. Helminths in the wolf, *Canis lupus*, from northwestern Spain. *Journal of Helminthology* 75: 183–192.
- SMITH F. R., AND W. THRELFALL. 1973. Helminths of some mammals from Newfoundland. *American Midland Naturalist* 90: 215–218.
- TORRES J., J. MIQUEL, AND M. MOTJE. 2001. Helminth parasites of the Eurasian badger (*Meles meles*) in Spain: A biogeographic approach. *Parasitology Research* 87: 259–263.
- WILLIAMS J. F., G. A. PADGETT, AND O. L. SMITH. 1985. Angiostrongylosis in a greyhound. *Journal of the American Veterinary Medical Association* 186: 1101–1103.

Received for publication 1 February 2005.