



## **PATHOLOGY AND PRELIMINARY CHARACTERIZATION OF A PARAPOXVIRUS ISOLATED FROM A CALIFORNIA SEA LION (ZALOPHUS CALIFORNIANUS)**

Authors: Nollens, Hendrik H., Jacobson, Elliott R., Gulland, Frances M. D., Beusse, Diedrich O., Bossart, Gregory D., et al.

Source: Journal of Wildlife Diseases, 42(1) : 23-32

Published By: Wildlife Disease Association

URL: <https://doi.org/10.7589/0090-3558-42.1.23>

---

BioOne Complete ([complete.BioOne.org](https://complete.BioOne.org)) is a full-text database of 200 subscribed and open-access titles in the biological, ecological, and environmental sciences published by nonprofit societies, associations, museums, institutions, and presses.

Your use of this PDF, the BioOne Complete website, and all posted and associated content indicates your acceptance of BioOne's Terms of Use, available at [www.bioone.org/terms-of-use](https://www.bioone.org/terms-of-use).

Usage of BioOne Complete content is strictly limited to personal, educational, and non - commercial use. Commercial inquiries or rights and permissions requests should be directed to the individual publisher as copyright holder.

---

BioOne sees sustainable scholarly publishing as an inherently collaborative enterprise connecting authors, nonprofit publishers, academic institutions, research libraries, and research funders in the common goal of maximizing access to critical research.

# PATHOLOGY AND PRELIMINARY CHARACTERIZATION OF A PARAPOXVIRUS ISOLATED FROM A CALIFORNIA SEA LION (*ZALOPHUS CALIFORNIANUS*)

Hendrik H. Nollens,<sup>1,7</sup> Elliott R. Jacobson,<sup>1</sup> Frances M. D. Gulland,<sup>2</sup> Diedrich O. Beusse,<sup>1</sup> Gregory D. Bossart,<sup>3</sup> Jorge A. Hernandez,<sup>4</sup> Paul A. Klein,<sup>5</sup> and Richard C. Condit<sup>6</sup>

<sup>1</sup> Marine Mammal Health Program and Department of Small Animal Clinical Sciences, College of Veterinary Medicine, University of Florida, PO Box 100126, Gainesville, Florida 32610, USA

<sup>2</sup> The Marine Mammal Center, 1065 Fort Cronkhite, Sausalito, California 94965, USA

<sup>3</sup> Division of Marine Mammal Research and Conservation, Harbor Branch Oceanographical Institution, 5600 US 1 North, Ft. Pierce, Florida 34946, USA

<sup>4</sup> Department of Large Animal Clinical Sciences, College of Veterinary Medicine, University of Florida, PO Box 100126, Gainesville, Florida 32610, USA

<sup>5</sup> Department of Pathology, Immunology and Laboratory Medicine, College of Medicine, University of Florida, PO Box 100275, Gainesville, Florida 32610, USA

<sup>6</sup> Department of Molecular Genetics and Microbiology, College of Medicine, University of Florida, PO Box 100266, Gainesville, Florida 32610, USA

<sup>7</sup> Corresponding author (email: NollensH@mail.vetmed.ufl.edu)

**ABSTRACT:** Cutaneous pox-like lesions are a common complication in the rehabilitation of pinnipeds. However, the exact identity, taxonomy, and host range of pinniped parapoxviruses remain unknown. During a poxvirus outbreak in May 2003 in California sea lions (*Zalophus californianus*) at a marine mammal rehabilitation facility, multiple raised, firm, 1–3-cm skin nodules from the head, neck, and thorax of one sea lion weanling pup that spontaneously died were collected. Histologically, the nodules were characterized by inflammation and necrosis of the dermis and epidermis, acanthosis, and ballooning degeneration of the stratum spinosum. Large, coalescing eosinophilic cytoplasmic inclusions were observed in the ballooned cells. A parapoxvirus (sea lion poxvirus 1, SLPV-1) was isolated on early passage California sea lion kidney cells inoculated with a tissue homogenate of a skin nodule. The morphology of the virions on electron microscopy was consistent with that of parapoxviruses. Partial sequencing of the genomic region encoding the putative major virion envelope antigen p42K confirmed the assignment of the sea lion poxvirus to the genus *Parapoxvirus*. Although SLPV-1 is most closely related to the poxvirus of harbor seals of the European North Sea, it is significantly different from orf virus, bovine papular stomatitis virus, pseudocowpox virus and the parapoxvirus of New Zealand red deer.

**Key words:** California sea lion, isolation, pathology, pinniped, poxvirus, virus, *Zalophus californianus*.

## INTRODUCTION

The viral family *Poxviridae* consists of large, enveloped DNA viruses that are of veterinary and medical importance. In humans, the most pathogenic member, variola virus, causes smallpox (Moss 1996). Members affecting wildlife include Nile crocodile poxvirus, parapoxvirus, buffalopox virus, squirrel parapoxvirus, monkeypox virus, dolphin poxvirus and the poxvirus that causes myxomatosis in rabbits and hares (Moss, 1996). Parapoxviruses cause contagious pustular dermatitis or orf in sheep and goats, papular stomatitis and pseudocowpox in cattle, and

skin lesions in other animals including red deer, squirrels, reindeer, musk ox, and camels (Reid, 1998). Poxvirus infections have also been reported in aquatic mammals, including pinnipeds. The susceptibility of pinnipeds to pox infections was first suspected in 1969 when a 1-yr-old California sea lion (*Zalophus californianus*) was presented with pox-like lesions (Wilson et al., 1969). The presence of poxvirus has since been confirmed in cutaneous and mucosal nodular lesions from harbor seals (*Phoca vitulina*) (Wilson et al., 1972), northern fur seals (*Callorhinus ursinus*) (Hadlow et al., 1980), gray seals (*Halichoerus grypus*) (Hicks and

Worthy, 1987), northern elephant seals (*Mirounga angustirostris*) (Hastings et al., 1989), and South American sea lions (*Otaria flavescens*) (Wilson and Po-glayen-Neuwall, 1971).

Based on electron microscopy of pox nodules in European and North American pinnipeds, several studies have suggested the involvement of both a parapoxvirus (Osterhaus et al., 1994; Simpson et al., 1994; Nettleton et al., 1995) and an orthopoxvirus (Osterhaus et al., 1990). Molecular investigations of the virus are limited to one account of a poxvirus outbreak in European harbor seals, in which the virus was classified as a new member of the parapoxviruses (Becher et al., 2002).

Parapoxviruses and orthopoxviruses have a common evolutionary ancestor and they consequently share features such as size, genome organization, and general virion structure (Fleming et al., 1993; Moss, 1996). However, only some of the surface antigens cross-react (Moss, 1996), and the differing nucleic acid content of the genomes sets them genetically apart (Fleming et al., 1993). The phylogenetic classification of the poxvirus is therefore of importance when developing molecular and serologic diagnostic assays. It has been suggested that some parapoxviruses are capable of causing persistent, recrudescent infections (Iketani et al., 2002). The phylogenetic classification of poxviruses of pinnipeds may therefore be of importance for future epidemiological and ecological studies as well. Molecular phylogenetic studies to resolve identity, taxonomy, and host range have not been performed on poxviruses of seals and sea lions in the United States and elsewhere outside Europe.

We describe the isolation and the electron microscopic appearance of a poxvirus (SLPV-1) from California sea lions and the associated pathologic lesions. The nucleic acid sequence of the gene encoding the p42K envelope protein of SLPV-1 is presented, which supports the classification of the sea lion poxvirus as a member of the genus *Parapoxvirus*.

## MATERIALS AND METHODS

### Case histories

Three California sea lions (CSL 1, CSL 2, CSL 3) were recovered from the central California coastline between July 2002 and May 2003 and were transported to The Marine Mammal Center (TMMC) in Sausalito, California (37°51'N, 122°31'W) for rehabilitation. All animals were group-housed in pens constructed of wire cyclone fencing bolted to an epoxy-coated concrete slab. Each pen contained a rough-textured fiberglass pool. The sea lions entered the pools by climbing a sand-textured fiberglass ramp. All pools were emptied daily and all surfaces cleaned with a dilute bleach solution and rinsed off with fresh water. Sea lion CSL 1, a yearling female, was admitted on 6 July 2002 with an abscess in the left inguinal area. On 14 August 2002, two raised, 1.0–2.0-cm, firm, cutaneous nodules were observed on the nares and upper lip of the animal, and a Dacron swab and a biopsy of the lesion were collected. The abscess was successfully treated and the animal was released on 24 August 2002. Sea lion CSL 2, a subadult female, was admitted on 8 July 2002 with evidence of shark bite wounds to the head. Several raised, firm, ulcerated cutaneous nodules were observed on the right palpebra and skin overlying the cranium on 15 August 2002. A swab was collected from each of two of the lesions. The head wounds and cutaneous nodules gradually resolved and the sea lion was released on 29 September 2002. On 23 May 2003, a female California sea lion pup, CSL 3, was recovered for rehabilitation. Three 2.0–3.0-cm, raised, firm, nodular skin lesions were noted on the head and neck during the physical examination upon admission. Four days later, the animal died and a necropsy was performed.

### Pathologic studies

The biopsy specimen from CSL 1 and all three pox-like lesions of CSL 3 that were collected on necropsy were bisected. Half of each nodule was processed for virologic studies (see below) and the remaining portion was fixed in 10% neutral buffered formalin for light microscopy. Samples from all major organ systems of CSL 3 were similarly fixed in 10% neutral buffered formalin for light microscopy. Subsequently, tissues were embedded in paraffin, sectioned at 6  $\mu$ m, stained with hematoxylin and eosin (H & E), and examined with a light microscope.

### Cell cultures

Frozen early-passage California sea lion skin cell cultures and California sea lion kidney cell cultures were obtained from the Wise Laboratory of Environmental and Genetic Toxicology, University of Southern Maine (Portland, Maine, USA) and were grown to confluency in our laboratory. Additionally, modified African green monkey kidney cell cultures (BSC40) were obtained from the Condit Laboratory, University of Florida (Gainesville, Florida, USA). The culture media consisted of 85% (volume : volume) DMEM-F12 (Cellgro, Herndon, Virginia, USA), 15% (volume : volume) cosmic fetal calf serum (Hyclone, Logan, Utah, USA), 2 mM L-glutamine (Cellgro), 0.1 mM sodium pyruvate (Cellgro), 50 IU penicillin/ml and 50 µg streptomycin (Cellgro). All cultures were kept at 37.0 C, 7.5% CO<sub>2</sub>, and approximately 90% relative humidity.

### Virus isolation

All three swabs (from CSL 1 and CSL 2) and the portion of each of the four nodules (from CSL 1 and CSL 3) for virologic studies were kept frozen at -20 C before overnight shipment to the University of Florida. For virus isolation, swabs were placed in 500 µl of phosphate-buffered saline (PBS) containing 500 IU/ml penicillin and 500 µg/ml streptomycin (Cellgro). The swabs were pulse-vortexed for 30 sec, after which the swab was removed and the swab extract was filtered using a 0.450-µm syringe filter (Fisher Scientific, Pittsburgh, Pennsylvania, USA). Approximately 75 mg of a tissue sample from both CSL 1 and CSL 3 was homogenized using a Dounce homogenizer in 500 µl PBS containing 500 IU/ml penicillin and 500 µg/ml streptomycin (Cellgro). The homogenate was centrifuged at 2,000 rpm for 20 min in a standard benchtop centrifuge, and the supernatant was filtered using a 0.450-µm syringe filter (Fisher Scientific). Next, 50-µl aliquots of each of the filtrates were diluted to a total volume of 500 µl in PBS for inoculation of the cell cultures. The swab filtrates and biopsy homogenate (CSL 1) were each used to inoculate two BSC40 cultures and four early-passage California sea lion skin cell cultures. Two BSC40 cultures, four early-passage California sea lion skin cell cultures, and four early-passage California sea lion kidney cell cultures were inoculated with the pox lesion homogenate of CSL 3. After incubation for 3 hr at 37 C, the cultures were washed and the tissue homogenate replaced by culture medium. All cultures were checked daily for cytopathic

changes. For passaging, the cells were harvested using a scraper, and the cell suspension was centrifuged at 1,800 × G for 5 min. A cell concentrate containing approximately 25% of the cell pellet and 2.5% of the supernatant was freeze-thawed two times at -70 C, sonicated for 2 min (Sonic VibraCell, Danbury, Connecticut, USA), and used to inoculate the next passage. All cultures were blind passaged at least three times. Each second passage was tested for the presence of poxviral DNA using the polymerase chain reaction (PCR) protocol described below.

### Virus morphology

After four passages, two cell cultures displaying a cytopathic effect were processed for transmission electron microscopy 6 days post-inoculation. Monolayers were washed twice using PBS at room temperature and then fixed using a solution of 2.5% glutaraldehyde in 0.1 M cacodylate buffer, pH 7.2 while the cells were adhered to the culture dish. Fixed cells were scraped, washed in 0.1 M cacodylate buffer, and then postfixed for 60 min at 4 C in a solution of 1% osmium tetroxide in 0.1 M cacodylate buffer and submitted to the University of Florida Interdisciplinary Center for Biotechnology Research (UF-ICBR) Electron Microscopy Core laboratory for transmission electron microscopy. Intracellular mature virions (IMV) were purified as described previously for orf virus (Robinson et al., 1982) from lysates of infected cells by high-speed centrifugation through a 40% sucrose cushion followed by banding of the IMV on a 25–50% sodium diatrizoate density gradient. The virus was resuspended in 10 mM Tris. An aliquot of the purified virus was fixed in 2% formaldehyde solution and submitted to the Electron Microscopy Core of the UF-ICBR for negative-staining electron microscopy.

### Molecular characterization of the virus

DNA was extracted from all three pox lesion swabs (CSL 1, CSL 2), from a 25-mg fragment of all four tissue samples (CSL 1, CSL 3) and from each second passage of the virus cultures, using a DNeasy Tissue Kit (Qiagen, Valencia, California, USA), following the manufacturer's guidelines. A universal parapox primer pair (GenBank accession number U06671: sense 5'-3' GTCGTCCACGATGAGCAGCT and antisense 5'-3': TACGTGGGAAGCGCCTC-GCT) was used to amplify part of the genomic region encoding the putative virion envelope antigen (p42K) of parapoxviruses (Sullivan et al., 1994; Inoshima et al., 2000). An aliquot of 15 µl of the extracted DNA was used in 100-µl

amplification reactions containing 10× PCR buffer, 1 mM MgCl<sub>2</sub>, 200 μM of each dNTP, 1 μM of each primer, and two units of *Taq* polymerase (Roche Diagnostics Corporation, Indianapolis, Indiana, USA). DNA from wild-type orf virus was included as positive control for the PCR reaction. Reactions containing no DNA and vaccinia DNA (Vac-WR), respectively, served as negative controls. Amplification conditions were as follows: incubation at 94 C for 2.5 min, 30 cycles of denaturation at 94 C for 30 sec, annealing at 57 C, and extension at 72 C for 40 sec, followed by incubation at 72 C for 10 min. All amplicons (controls and unknown samples) were purified using a High Pure PCR Product Purification Kit (Roche Diagnostics Corporation) following the manufacturers instructions, and submitted to the Sequencing Core of the UF-ICBR for nucleotide sequencing. Each nucleotide position was sequenced at least three times in each direction. Vector NTI software (Informax, Frederick, Maryland, USA) was used to perform the analysis of the sequences. The ClustalX software was used to generate the multiple-sequence alignment of the deduced amino acid sequence and to construct a phylogenetic tree according to the maximum likelihood method. The robustness of the phylogenetic analysis and significance of the branch order were determined by bootstrap analysis carried out on 100 replicates using the PHYLIP software.

## RESULTS

### Pathologic studies

At necropsy, sea lion CSL 3 was 81 cm in length and weighed 12.5 kg. Blubber thickness measured at the level of the sternum was 13 mm. Three raised cutaneous nodules, measuring between 2.0 and 3.0 cm in diameter, were noted on the forehead and left abdomen of the sea lion. On section, the nodules were firm, congested, and focally ulcerated and the epidermis appeared thickened. Internally, severe atrophy of the renal and cardiac fat depots and a diffuse, moderate hemorrhagic gastritis was observed. No evidence of clinically significant viral, bacterial, or parasitic infections was found. Based on the animal's low body weight and the fat atrophy, death was attributed to malnutrition.

On histologic section, diffuse necrosis of

the outer layers of the epidermis was observed throughout the skin nodule (Fig. 1). There was acanthosis and ballooning degeneration of epidermal cells within the stratum spinosum. With H & E staining, many of the ballooned cells were found to contain large, coalescing eosinophilic intracytoplasmic inclusions. In one area, there was ulceration of the epidermis with an accumulation of overlying necrotic cellular debris containing large numbers of bacterial colonies. In the dermis, there were focal areas of necrosis. The dermis contained diffuse infiltrates of mixed inflammatory cells, including small round cells and neutrophils that subtended the epidermal basement membrane and, in some areas, infiltrated epidermal follicular and rete pegs.

### Virus isolation

All attempts to isolate the virus onto BSC40 African green monkey kidney cell cultures or in the early-passage California sea lion skin cell cultures were unsuccessful. Cytopathic changes suggestive of a poxvirus infection developed within 24 hr of inoculation in all four early-passage California sea lion kidney cell cultures. Cytopathic changes consisted of generalized, diffuse rounding of the cells. No cell lysis or plaque formation was observed. Lysates of the infected cell cultures were passaged seven times and portions of each passage were stored at -80 C.

### Virus morphology

Positive staining transmission electron microscopy revealed the presence of poxvirus particles in the sea lion kidney cell cultures (Fig. 2). Mature virions, immature virus particles, crescents, and viroplasm were observed. Mature virions were brick-shaped, although somewhat elongated. The virions had a length and width of approximately 300 nm and 170 nm, respectively. The structure of the mature virions consisted of an electron-dense core surrounded by the viral

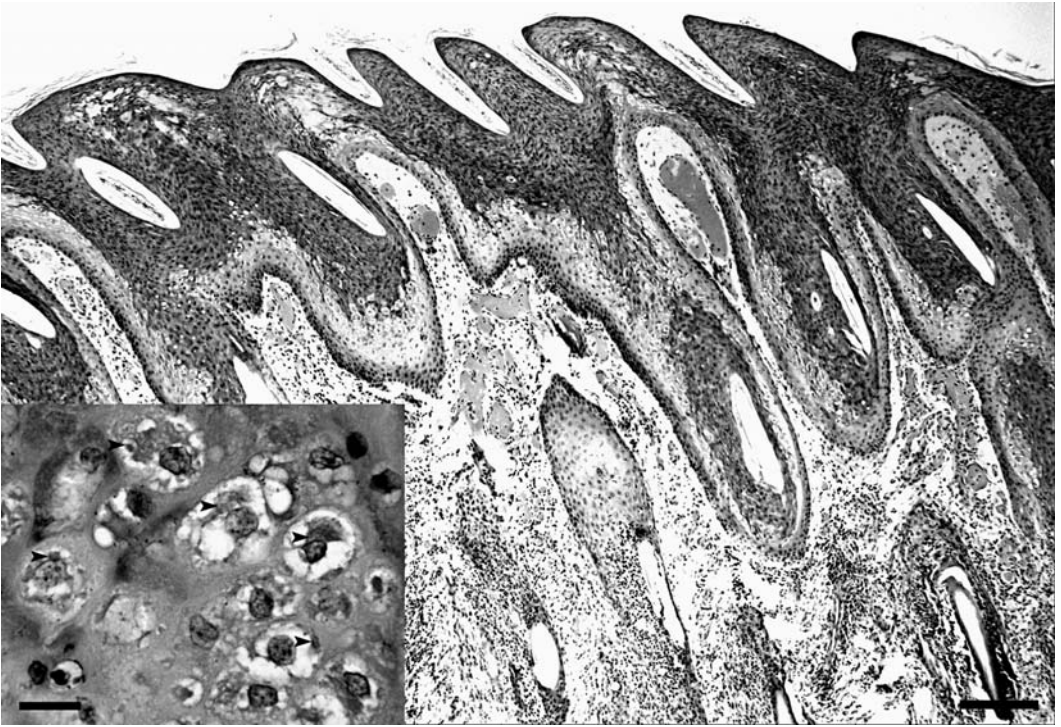


FIGURE 1. Photomicrograph of a pox lesion (H & E stain, 4 $\times$ ). Diffuse necrosis is present in the outer layers of the epidermis. The dermis contains focal areas of necrosis and diffuse infiltrates of mixed inflammatory cells. Inset (H & E stain, 40 $\times$ ): Ballooning degeneration of epidermal cells within the stratum spinosum. Many ballooned cells contained large, coalescing eosinophilic intracytoplasmic inclusions (arrowheads).

envelope. The cores of mature virions were ovoid to lanceolate and only occasionally dumbbell shaped.

On the negative-stained preparation (Fig. 3), the virus particles appeared oval or cylindrical with convex ends. The negative staining also revealed a regularly arranged surface tubule pattern. No smooth, capsular-type virions were observed. Some smaller, rounded virions that did not show the typical parapox surface morphology were also present.

#### Molecular characterization of the virus

The TBLASTX results of the 594-base-pair nucleotide sequence showed the highest score with the harbor seal poxvirus from Northern Europe (SPV, AF414182.1). At the nucleotide level, the sea lion parapoxvirus sequence was 96.6% and 81% identical to the corresponding

sequence of SPV and to orf virus OV-SA200 (ORFV-SA200, AY386264.1), respectively. The nucleotide sequence derived from the sea lion poxvirus corresponds to nucleotide positions 11606–11022 of the orf virus genome (strain OV-SA200). A multiple sequence alignment of the deduced amino acid sequence of the sea lion parapoxvirus with the known sequences of other parapoxviruses is presented in Fig. 4. At the amino acid level, the sea lion poxvirus sequence was 97.3% and 76.1% identical to the harbor seal poxvirus from Northern Europe and to orf virus OV-SA200, respectively. Further, the sea lion poxvirus amino acid sequence was 77% identical to the corresponding amino acid sequences of bovine papular stomatitis virus strain BV-AR02 (BPSV, AY386265.1) and pseudocowpox virus (PCPV, AY424972.1), and 76%

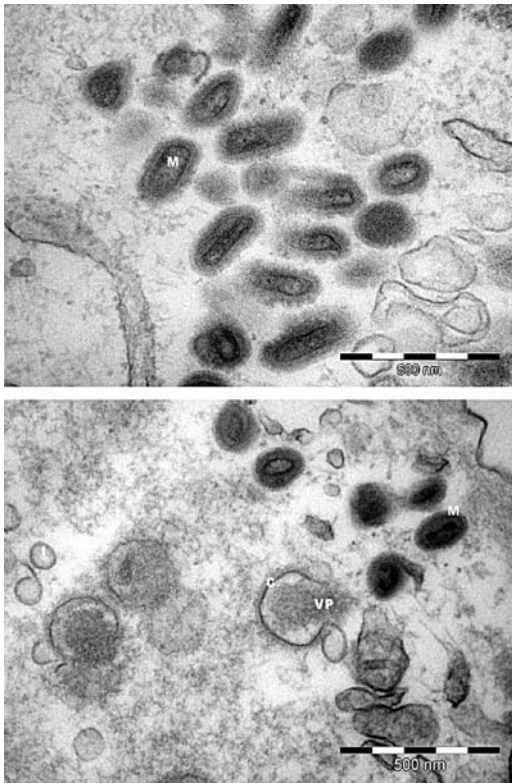


FIGURE 2. Transmission electron micrographs of infected sea lion kidney cell cultures. Mature virions (M), immature virus particles (I), crescents (C), and viroplasm (VP) of the California sea lion poxvirus can be observed. The cores of mature virions are ovoid to lanceolate and only occasionally dumbbell shaped.

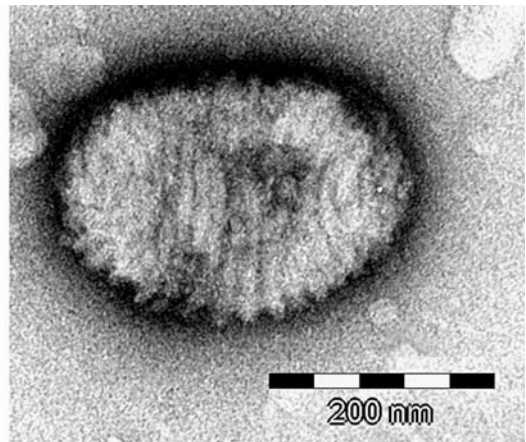
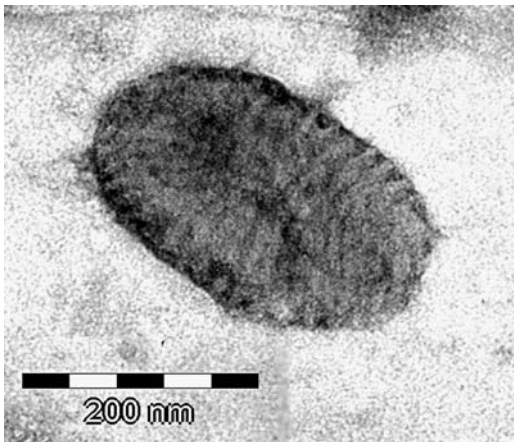


FIGURE 3. Negative-stain transmission electron micrograph. The virus particles are oval or cylindrical with convex ends. Negative staining also reveals the regularly arranged surface tubule spiral that is consistent with parapoxvirus morphology (mulberry type).

identical to the amino acid sequences of the red deer parapoxvirus (PVNZ, AB044794.1) and the orf virus strains IA82 (ORFV-IA82, AY386263.1) and NZ2 (ORFV-NZ2, OVU06671). The evolutionary relationship of the sea lion poxvirus with the other parapoxviruses and with the prototypal member of the other genera of chordopoxviruses is depicted using a phylogenetic tree (Fig. 5). The phylogenetic analysis of the 184 translated amino acids of the putative major envelope antigen of parapoxviruses shows that the sea lion poxvirus is most closely related to the harbor seal poxvirus from Europe. Although the poxvirus of the California sea lions and the European sealpox virus are most closely related to the members of the genus *Parapoxvirus*, they do make up a distinct phylogenetic subgroup within the parapoxviruses (Fig. 5).

#### Nucleotide sequence accession number

The nucleotide sequence of SLPV-1 from this study was deposited in the GenBank data library under accession number DQ163058.

#### DISCUSSION

In this study, we report on California sea lions at a rehabilitation facility; three

BPSV	TGGSISNIKN	LGVYSTNRHL	ATDLMNRYNT	FYSMIVEPKV	PFSRLCCAMI	TPTATDFHLD
PVNZ	TGGSIQTIKN	LGLYSTNKRL	AADLMNRYNT	FFSMIVEPKI	PFTRMCCSMI	TPTATDFHLLN
ORFV-IA82	TGGSVSTIKN	LGLYSTNKHL	AWDLMNRYNT	FYSMIVEPKV	PFTRLCACAVV	TPTATNFHLD
ORFV-SA00	TGGSVSTIKN	LGLYSTNKHL	AWDLMNRYNT	FYSMIVEPKV	PFTRLCACAVV	TPTATNFHLLN
ORFV-NZ2	TGGSVSTIKN	LGLYSTNKHL	AWDLMNRYNT	FYSMIVEPKV	PFTRLCACAVV	TPTATNFHLD
PCPV	TGGSVSTIKN	LGLYSTNKHL	AADLMNRYNT	FYSMIVEPKV	PFTRLCACAVV	TPTATDFHLLN
SPV	TGGSLATIKN	LGVYSTNKHL	AVDLMNRYNT	FSSMVVDSKQ	PFTRFCCAMI	TPTATDFHMN
SLPV-1	TGGSLATIKN	LGVYSTNKHL	AVDLMNRYNT	FSSMVVDPKQ	PFTRFCCAMI	TPTATDFHMN
	***	*	**	*	* * * * *	* * * * *
BPSV	HAGGGVFFSD	APEKFLGFYR	TLDEDLVLHR	IDSAKNSIDL	SLLSLVPVIR	HADRVEYWPR
PVNZ	HAGGGVFFSD	APEKFLGFYR	TLDEDLVLHR	INSAVNSIDL	SLLSIVPVIR	HASSMEYWPA
ORFV-IA82	HSGGGVFFSD	SPERFLGFYR	TLDEDLVLHR	IENAKNSIDL	SLLSMVPVIK	HASAVEYWPR
ORFV-SA00	HSGGGVFFSD	SPERFLGFYR	TLDEDLVLHR	IENAKNSIDL	SLLSMVPVIK	HAGAVEYWPR
ORFV-NZ2	HSGGGVFFSD	SPERFLGFYR	TLDEDLVLHR	IENAKNSIDL	SLLSMVPVIK	HASAVEYWPQ
PCPV	HSGGGVFFSD	SPERFLGFYR	TLDEDLVLHR	IENANNSIDL	SLLSMVPVIK	HASAVEYWPQ
SPV	HSGGGVFFSD	SPERFLGFYR	TLDEDLVLHR	IDAAKNSIDL	SLLSMVPVVR	SGGEVYYWPL
SLPV-1	HSGGGVFFSD	SPERFLGFYR	TLDEDLVLHR	IDAAENSIDL	SLLSMVPVVR	SGSEVYYWPL
	*	*	*	*	** *	* ** * * * *
BPSV	IMDALLRAAI	DRSVRVVIV	TEWKNADPLS	VSAARTLNDF	GVGSIDISTR	LFSIPGRDD
PVNZ	IMDALLRAAV	ERGVRVIV	TEWKNADPLS	VAAARTLNDF	GVGSIDISTR	LFSIPGRDD
ORFV-IA82	IIDALLRAAI	DRGVRVIV	TEWKNADPLS	VSAARSLDDF	GVGSVDMSVR	KFVVPGRDD
ORFV-SA00	IIDALLRAAI	NRGVRVIV	TEWKNADPLS	VSAARSLDDF	GVGSVDMSVR	KFVVPGRDD
ORFV-NZ2	IIDALLRAAI	NRGVRVIV	TEWKNADPLS	VSAARSLDDF	GVGSVDMSVR	KFVVPGRDD
PCPV	IIDALLRAAI	NRGVRVIV	TEWKNADPLS	LSAARSLNDF	GVGSVDMSVR	KFVVPGRDD
SPV	IMDALLRAAI	NRSVRVIV	SQWRNADPLS	VAAVRALDNF	GVGHVDITAR	WFAIPGRDD
SLPV-1	IIDALLRAAI	NRSVRVIV	SQWRNADPLS	VAAVRALDNF	GVGHVDITAR	WFAIPGRDD
	*	* * *	* * *	* * * * *	* * * * *	* * *

FIGURE 4. Multiple sequence alignment of the deduced amino acid sequence of part of the putative virion envelope antigen (p42K). The sequence from the sea lion parapoxvirus (SLPV-1) is compared to the corresponding sequence of the following published parapoxviruses: Orf virus strains SA200 (ORFV-SA00), IA82 (ORFV-IA82), NZ2 (ORFV-NZ2), bovine papular stomatitis virus strain BV-AR02 (BPSV), pseudocowpox virus (PCPV), red deer parapoxvirus (PVNZ) and the European harbor seal poxvirus (SPV). This sequence alignment was generated using the ClustalX software. Sequence differences are indicated with an asterisk.

sea lions studied were found to have cutaneous nodules, from which a parapoxvirus was isolated and shown to have morphologic characteristics of parapoxviruses by electron microscopy. A partial sequence of the gene encoding the viral major envelope protein confirmed the assignment to the subgroup of parapoxviruses and showed that the sea lion parapoxvirus was most closely related to a parapoxvirus of harbor seals of the North Sea.

Although a poxvirus infection in a pinniped was first described in 1969 (Wilson et al., 1969) and several cases have been reported since, reports on the exact nature of the etiologic agents have been conflicting. In most instances the poxvirus was classified as a parapoxvirus (Wilson and Sweeney, 1970; Wilson et al., 1972; Hicks

and Worthy, 1987; Osterhaus et al., 1994; Simpson et al., 1994; Nettleton et al., 1995; Muller et al., 2003). In one case, a mixed infection of a parapoxvirus and an orthopoxvirus was reported (Osterhaus et al., 1990). The classification of the poxviruses in these cases was based on virus surface morphology with negative-staining electron microscopy. However, the viral surface tubules are an artifact that results from nonisotropic drying during sample preparation for electron microscopy (Moss, 1996). Even though an underlying structure must contribute to the acquisition of the characteristic surface appearance of the virions, sequencing of viral genes is the current method of choice for classifying poxviruses. Only in one poxvirus outbreak in harbor seals from the North Sea was the poxvirus classified as



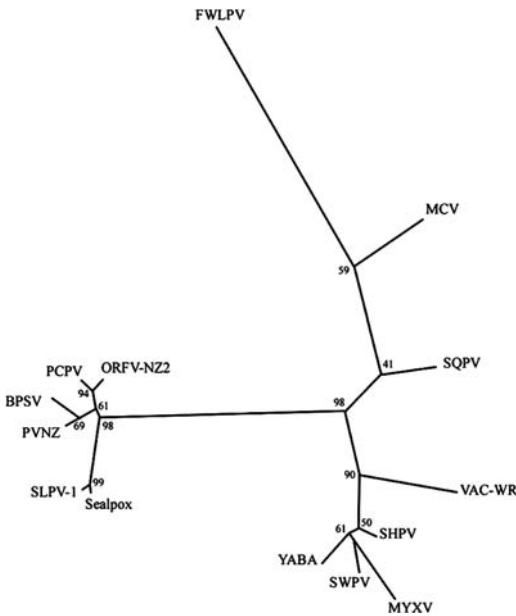


FIGURE 5. Phylogram depicting the relationship of the sea lion poxvirus (SLPV-1) to the published members of the genus *Parapoxvirus*: orf virus strain NZ2 (ORFV-NZ2), bovine papular stomatitis virus strain BV-AR02 (BPSV), pseudocowpox virus (PCPV), red deer parapoxvirus (PVNZ), and the European harbor seal poxvirus (Sealpox). Also included are the protypal viruses of all other *Chordopox* genera: genus *Orthopoxvirus*: vaccinia virus strain WR, (VACV-WR, AY243312.1), squirrel parapoxvirus (SQPV, AY340985.1); genus *Suipoxvirus*: swinepox virus isolate 17077-99 (SWPV, AF410153.1); genus *Capripoxvirus*: sheeppox virus strain A (SHPV, AY077833.1); genus *Molluscipoxvirus*: molluscum contagiosum virus subtype 1 (MCV, U60315.1); genus *Leporipoxvirus*: myxoma virus strain Lausanne (MYXV, AF170726.2); genus *Yatapoxvirus*: Yaba monkey tumor virus (YABA, AY386371.1); and genus *Avipoxvirus*: fowlpox virus (FWLPV, AF198100.1). This phylogenetic tree is based on the 184 translated amino acids of the putative sea lion p42K fragment and homologous regions from the other poxviruses, and was generated according to the maximum likelihood method using ClustalX software. Branch lengths are proportional to genetic distances. Numbers indicate the percentage of 1,000 bootstrap replicates that support each interior branch.

a parapoxvirus based on sequence data that were obtained directly from the pox lesion (Becher et al., 2002).

The difficulty in isolating marine mammal poxviruses has been one of the greatest impediments for the character-

ization of these viruses. These viruses have only been isolated on early-passage kidney cell cultures derived from pinnipeds (Osterhaus et al., 1990; Osterhaus et al., 1994; Nettleton et al., 1995); attempts to isolate poxviruses from pinnipeds using primary rabbit kidney cells, canine kidney cells, and African green monkey kidney cells (Vero) have failed (Osterhaus et al., 1990). Similarly, our attempts to isolate the poxvirus from California sea lions in modified African green monkey kidney cells (BSC40) failed, but virus isolation was successfully carried out using early-passage California sea lion kidney cells.

Our study is the first to provide DNA sequences for a pinniped poxvirus that has been isolated. The sequence analysis data were complemented by positive- and negative-staining electron microscopic findings. On the negative-stained preparation, the regularly arranged surface tubule structure, a hallmark feature of parapox virions (Moss, 1996), was visible. The phylogenetic analysis of the amino acid sequence of the putative major envelope antigen p42K confirmed that the SLPV-1 is most closely related to the parapoxviruses. All observed virions were of the structured mulberry type (Wilson and Sweeney, 1970). Some shorter, more rounded virions were also observed in the negative-stain preparation, in addition to those with the more typical parapox morphology. These atypical viral particles were observed in other studies (Simpson et al., 1994) and are considered either immature or disrupted virions.

Based on part of the open reading frame of the p42K surface protein, SLPV-1 is most closely related to the European harbor seal poxvirus. However, they are only 97.3% identical at the amino acid level and thus are distinct. The phylogenetic analysis of the amino acid sequence of SLPV-1 indicated that the European harbor seal poxvirus and SLPV-1 should be classified within the genus *Parapoxvirus*. The degree of identity between the amino acid chain translated

from the target gene between two orf virus strains and between SLPV-1 and the harbor seal poxvirus from Northern Europe was 97% in both cases. To determine whether SLPV-1 is a novel parapoxvirus species, a more extensive study of the SLPV-1 genome sequence was initiated and is ongoing. In the absence of the complete viral genome sequence, host range is one of the main criteria for provisionally defining virus species within the genus *Parapoxvirus* (Moyer et al., 2000). The natural host range of this poxvirus of California sea lions is at present unknown. Guadalupe fur seals (*Arctocephalus townsendi*), northern fur seals, northern or Steller sea lions (*Eumetopias jubatus*), Pacific harbor seals (*P. vitulina richardsii*), and northern elephant seals frequent the California coast as well and poxvirus infections have been reported in several of these species (Hadlow et al., 1980; Hastings et al., 1989). To date we have been unable to obtain pox lesion samples from these sympatric pinniped species for molecular studies. Pacific harbor seals, northern elephant seals, and California sea lions are often housed in the rehabilitation center at the same time. A previous report of a poxvirus outbreak in this facility did suggest transmission of the same poxvirus from harbor seals to California sea lions and northern elephant seals (Hastings et al., 1989). The transmission of the poxvirus between species during that outbreak was, however, unconfirmed, as no electron microscopy images were obtained from the poxvirus(es) of either the affected California sea lions or the northern elephant seals, and no viral sequence was generated to confirm that the same strain of poxvirus was affecting all three species.

The high degree of amino acid sequence conservation between the European harbor seal poxvirus and the novel California sea lion poxvirus was noteworthy. Not only are the two poxvirus strains apparently geographically isolated, but Atlantic harbor seals (*P. vitulina vitulina*)

and California sea lions, respectively, belong to the families Phocidae and Otariidae, and they are therefore taxonomically very distinct hosts. If the parapoxviruses of pinnipeds are able to infect multiple host species, viruses circulating in the Atlantic basin may be able to enter the Pacific (and vice versa) via infection of the Arctic ice seals (harp seal [*Phoca groenlandica*], hooded seal [*Cystophora cristata*]). As a result, the sea lion and harbor seal parapoxvirus strains may have more recently diverged, which would account for the high degree of genetic identity between the two viruses.

Differences were seen in the nature and distribution of the lesions caused by the poxviruses in Atlantic harbor seals and California sea lions, whereas the histological appearance was very similar. SLPV-1 of California sea lions was associated with nodular skin lesions of head and neck that were occasionally focally ulcerated. The most obvious pathology observed during the poxvirus outbreak in harbor seals were ulcerating to verrucose oral lesions and ulcerated cutaneous lesions of flippers, chest, neck, and perineum (Muller et al., 2003). This divergent clinical presentation may be because of different virus–host interactions or because of the use of different husbandry procedures. Muller et al. (2003) suggested that the parapoxvirus may have been transmitted between the harbor seals via contaminated feeding tubes, leading to oral and mucosal lesions, whereas the source of infection for the California sea lions was unknown.

#### ACKNOWLEDGMENTS

The authors wish to thank the staff at TMMC, especially Denise Greig, for their help in sample collection; John Wise and Carie Goertz at the Wise Laboratory of Environmental and Genetic Toxicology, University of Southern Maine, for supplying the cell cultures; and the Electron Microscopy Core Laboratory of the University of Florida. The authors also thank Andy Mercer of the University of Otago, New Zealand, for his advice on virus isolation and interpretation of electron microscopy images. This work was

supported by a grant from the Florida Fish and Wildlife Conservation Commission and a grant from the John H. Prescott Marine Mammal Rescue Assistance Program (award NA03NMF4390410). Samples were collected under National Marine Fisheries Service Scientific Research Permits 932-1489-00 and 1054-1731-00.

#### LITERATURE CITED

- BECHER, P., M. KONIG, G. MULLER, U. SIEBERT, AND H.-J. THIEL. 2002. Characterization of sealpox virus, a separate member of the parapoxviruses. *Archives of Virology* 147: 1133–1140.
- FLEMING, S. B., J. BLOK, K. M. FRASER, A. A. MERCER, AND A. J. ROBINSON. 1993. Conservation of gene structure and arrangement between vaccinia virus and orf virus. *Virology* 195: 175–184.
- HADLOW, W. J., N. F. CHEVILLE, AND W. I. JELLISON. 1980. Occurrence of pox in a northern fur seal on the Pribilof Islands in 1951. *Journal of Wildlife Diseases* 16: 305–312.
- HASTINGS, B. E., L. J. LOWENSTINE, L. J. GAGE, AND R. J. MUNN. 1989. An epizootic of seal pox in pinnipeds at a rehabilitation center. *Journal of Zoo and Wildlife Medicine* 20: 282–290.
- HICKS, B. D., AND G. A. J. WORTHY. 1987. Sealpox in captive grey seals (*Halichoerus gyrrus*) and their handlers. *Journal of Wildlife Diseases* 23: 1–6.
- IKETANI, Y., Y. INOSHIMA, A. ASANO, K. MURAKAMI, S. SHIMIZU, AND H. SENTSU. 2002. Persistent parapoxvirus infection in cattle. *Microbiology and Immunology* 46: 285–291.
- INOSHIMA, Y., A. MOROOKA, AND H. SENTSU. 2000. Detection and diagnosis of parapoxvirus by the polymerase chain reaction. *Journal of Virological Methods* 84: 201–208.
- MOSS, B. 1996. Poxviridae: The viruses and their replication. In *Fields virology*, 3rd Edition, B. N. Fields, D. M. Knipe, and P. M. Howley (eds.). Lippincott-Raven Publishers, Philadelphia, Pennsylvania, pp. 2637–2671.
- MOYER, R. W., B. M. ARIF, D. N. BLACK, D. B. BOYLE, R. M. BULLER, K. R. DUMBELL, J. J. ESPOSITO, G. MCFADDEN, B. MOSS, A. A. MERCER, S. ROPP, D. N. TRIPATHY, AND C. UPTON. 2000. Family Poxviridae. In *Virus taxonomy. Seventh report of the International Committee on Taxonomy of Viruses*, M. H. V. van Regenmortel, C. M. Fauquet, D. H. L. Bishop, D. B. Carstens, M. K. Estes, S. M. Lemon, J. Maniloff, M. A. Mayo, D. J. McGeoch, C. R. Pringle and R. B. Wickner (eds.). Academic Press, San Diego, California, pp. 137–157.
- MULLER, G., S. GROTERS, U. SIEBERT, T. ROSENBERGER, J. DRIVER, M. KONIG, P. BECHER, U. HETZEL, AND W. BAUMGARTNER. 2003. Parapoxvirus infections in harbor seals (*Phoca vitulina*) from the German North Sea. *Veterinary Pathology* 40: 445–454.
- NETTLETON, P. F., R. MUNRO, I. POW, J. GILRAY, E. GRAY, AND H. W. REID. 1995. Isolation of a parapoxvirus from a grey seal (*Halichoerus gyrrus*). *Veterinary Record* 137: 562–564.
- OSTERHAUS, A. D. M. E., H. W. J. BROEDERS, I. K. G. VISSER, J. S. TEPPEMA, AND E. J. VEDDER. 1990. Isolation of an orthopoxvirus from pox-like lesions of a grey seal (*Halichoerus gyrrus*). *Veterinary Record* 127: 91–92.
- \_\_\_\_\_, \_\_\_\_\_, \_\_\_\_\_, \_\_\_\_\_, AND T. KUIKEN. 1994. Isolation of a parapoxvirus from pox-like lesions in grey seals. *Veterinary Record* 135: 601–602.
- REID, H. W. 1998. Poxviruses. In *Zoonoses, clinical practice and public health control*, S. R. Palmer, Souldsbry, Lord and Simpson D. I. H. (eds.). Oxford University Press, Oxford, UK, pp. 425–421.
- ROBINSON, A. J., G. ELLIS, AND T. BALASSU. 1982. The genome of orf virus: Restriction endonuclease analysis of viral DNA isolated from lesions of orf in sheep. *Archives of Virology* 71: 43–55.
- SIMPSON, V. R., N. C. STUART, M. J. STACK, H. A. ROSS, AND C. H. HEAD. 1994. Parapox infections in grey seals (*Halichoerus gyrrus*) in Cornwall. *Veterinary Record* 134: 292–296.
- SULLIVAN, J. T., A. A. MERCER, S. B. FLEMING, AND A. J. ROBINSON. 1994. Identification and characterization of an orf virus homologue of the vaccinia virus gene encoding the major envelope antigen p37K. *Virology* 202: 968–973.
- WILSON, T. M., AND I. POGLAYEN-NEUWALL. 1971. Pox in South American sea lions (*Otaria byronia*). *Canadian Journal of Comparative Medicine* 35: 174–177.
- \_\_\_\_\_, AND P. R. SWEENEY. 1970. Morphological studies of seal poxvirus. *Journal of Wildlife Diseases* 6: 94–97.
- \_\_\_\_\_, N. F. CHEVILLE, AND L. KARSTAD. 1969. Seal pox. *Bulletin of the Wildlife Disease Association* 5: 412–418.
- \_\_\_\_\_, R. W. DYKES, AND K. S. TSAI. 1972. Pox in young, captive harbor seals. *Journal of the American Veterinary Medical Association* 161: 611–617.

Received for publication 18 March 2005.