



**A NOVEL MYCOPLASMA DETECTED IN ASSOCIATION WITH UPPER RESPIRATORY DISEASE SYNDROME IN FREE-RANGING EASTERN BOX TURTLES (TERRAPENE CAROLINA CAROLINA) IN VIRGINIA**

Authors: Feldman, Sanford H., Wimsatt, Jeffrey, Marchang, Rachel E., Johnson, April J., Brown, William, et al.

Source: Journal of Wildlife Diseases, 42(2) : 279-289

Published By: Wildlife Disease Association

URL: <https://doi.org/10.7589/0090-3558-42.2.279>

---

BioOne Complete (complete.BioOne.org) is a full-text database of 200 subscribed and open-access titles in the biological, ecological, and environmental sciences published by nonprofit societies, associations, museums, institutions, and presses.

Your use of this PDF, the BioOne Complete website, and all posted and associated content indicates your acceptance of BioOne's Terms of Use, available at [www.bioone.org/terms-of-use](http://www.bioone.org/terms-of-use).

Usage of BioOne Complete content is strictly limited to personal, educational, and non - commercial use. Commercial inquiries or rights and permissions requests should be directed to the individual publisher as copyright holder.

---

BioOne sees sustainable scholarly publishing as an inherently collaborative enterprise connecting authors, nonprofit publishers, academic institutions, research libraries, and research funders in the common goal of maximizing access to critical research.

# A NOVEL MYCOPLASMA DETECTED IN ASSOCIATION WITH UPPER RESPIRATORY DISEASE SYNDROME IN FREE-RANGING EASTERN BOX TURTLES (*TERRAPENE CAROLINA CAROLINA*) IN VIRGINIA

Sanford H. Feldman,<sup>1</sup> Jeffrey Wimsatt,<sup>1,2,8</sup> Rachel E. Marchang,<sup>3</sup> April J. Johnson,<sup>4</sup> William Brown,<sup>5</sup> Joseph C. Mitchell,<sup>6</sup> and Jonathan M. Sleeman<sup>7</sup>

<sup>1</sup> Center for Comparative Medicine, University of Virginia, Charlottesville, Virginia 22908, USA

<sup>2</sup> Department of Biology, University of Virginia, Charlottesville, Virginia 22904, USA

<sup>3</sup> Institut für Umwelt- und Tierhygiene, Universität Hohenheim, Garbenstrasse 30, D-70599, Stuttgart, Germany

<sup>4</sup> Department of Small Animal Clinical Sciences, College of Veterinary Medicine, University of Florida, Gainesville, Florida 32608, USA

<sup>5</sup> Blue Ridge Biological, 978 Bull Yearling Road, Stanardsville, Virginia 22973, USA

<sup>6</sup> Department of Biology, University of Richmond, Richmond, Virginia 23173, USA

<sup>7</sup> Wildlife Center of Virginia, Waynesboro, Virginia 22980, USA

<sup>8</sup> Corresponding author (email: jhw5b@virginia.edu)

**ABSTRACT:** Clinical signs of upper respiratory tract disease-like syndrome (URTD-LS) were observed in free-ranging eastern box turtles (*Terrapene carolina carolina*) from Virginia, USA (May 2001–August 2003), some of which also had aural abscesses. After a *Mycoplasma* sp. was detected by polymerase chain reaction (PCR), a study was undertaken to better define the range of clinical signs of disease and to distinguish mycoplasma-associated URTD-LS from other suspected causes of URTD-LS and aural abscessation in box turtles. Nasal and/or ocular swabs (from turtles possessing URTD-LS) or nasal washes (from asymptomatic turtles) were collected from turtles May 2001–August 2003; samples were assayed for *Mycoplasma* spp., chelonian herpesvirus, and iridoviruses by PCR testing. A partial DNA sequence (933 bases) of the small ribosomal subunit (16S rRNA) of the box turtle *Mycoplasma* sp. was analyzed to determine its phylogenetic relatedness to other *Mycoplasma* spp. of veterinary interest. *Mycoplasma* sp. was detected in seven (six with clinical signs of URTD-LS; one asymptomatic) of 23 fortuitously collected animals from six of 11 Virginia counties. Clinical signs in *Mycoplasma* sp.–infected animals included unilateral to bilateral serous to mucopurulent nasal discharge, epiphora, ocular edema, and conjunctival injection. Five *Mycoplasma* sp.–positive animals possessed aural abscesses; two did not. Analysis of the mycoplasma 16S rRNA gene sequence from one asymptomatic and three symptomatic animals representing four counties revealed a consensus *Mycoplasma* sp. sequence closely related to, but distinct from, *M. agassizii*. None of the samples collected contained viral DNA of chelonian herpesviruses or invertebrate and vertebrate (including FV3) iridoviruses. In conclusion, a new *Mycoplasma* sp. was associated with URTD-LS in native box turtles from Virginia that was not codetected with other suspected causes of chelonian upper respiratory disease; there was no proof of a direct relationship between aural abscessation and the *Mycoplasma* sp.

**Key words:** Aural abscess, eastern box turtles, herpesvirus, iridovirus, *Mycoplasma*, PCR, *Terrapene carolina*, upper respiratory disease.

## INTRODUCTION

Upper respiratory tract disease (URTD) in tortoises is primarily caused by *Mycoplasma agassizii*; the pathogenicity of this agent has been confirmed experimentally in two American tortoise species (Brown et al., 1994, 1999b). *Mycoplasma*-infected tortoises have cyclic URTD signs, and recrudescence may occur in response to anthropogenic influences (United States Fish and Service, 1994; Brown et al., 1999a). This disease has caused significant

morbidity and mortality in free-living Mojave Desert tortoises (*Gopherus agassizii*) (Brown et al., 1994; Jacobson, 1994) and Southeastern US gopher tortoises (*Gopherus polyphemus*) (Brown et al., 2001). Cases of URTD in captive tortoises also are caused by *M. agassizii*, as confirmed by polymerase chain reaction (PCR), culture, and serology (Jacobson et al., 1991; Brown et al., 2001).

A URTD-like syndrome (URTD-LS) closely resembling URTD in tortoises was recently identified in free-ranging

eastern box turtles (*Terrapene carolina carolina*) from several counties in Virginia, USA. Coincident with URTD-LS was another distinct syndrome characterized by aural abscesses; these animals sometimes also had signs associated with URTD in tortoises and turtles (ocular and nasal discharge and eyelid swelling). Virginia box turtles affected with aural abscesses typically have histologic lesions consistent with vitamin A deficiency; a link between aural abscesses and organochlorine compounds has been hypothesized (Holladay et al., 2001).

Major objectives of this study involving box turtles with URTD-LS and detectable mycoplasma were to identify the type and prevalence of clinical signs in *Mycoplasma* sp.-positive animals, screen for other potential causes of URTD (herpesvirus, iridovirus), characterize the phylogenetic relationship of this box turtle *Mycoplasma* sp. to other pathogenic *Mycoplasma* spp., and present the partial geographic distribution of this agent in Virginia.

## MATERIALS AND METHODS

### Turtles

The index case was a wild-caught male eastern box turtle identified in May 2001, from Greene County Virginia, USA, within 1 mile of the eastern boundary of Shenandoah National Park (38°20'24''N, 78°29'26''W). The affected individual had serous to mucopurulent nasal discharge, swollen ocular adnexal tissues, epiphora, and a loss of body condition. The index case transmitted URTD-LS to a cohoused previously unaffected female box turtle known to be free of clinical signs for over a year prior to infection. Both cases initially responded to tylosin, and the female was maintained in captivity and subsequently cleared of clinical URTD-LS by application of extended clarithromycin treatment (Wimsatt et al., 1999). A *Mycoplasma* sp. was detected in nasal swabs from this female using a consensus *Mycoplasma* sp. 16S rRNA PCR (validated to detect verified *M. agassizi* in captive desert tortoises by the Colorado State University State Diagnostic Laboratory; Wimsatt, unpubl. data, 2001) followed by development and testing with a box turtle *Mycoplasma* sp. sequence-specific PCR. The

sequence-specific PCR detected the box turtle mycoplasma and *M. agassizi* but not other distantly related *Mycoplasma* spp. The DNA of this new box turtle mycoplasma was used as a positive control for screening subsequently collected turtle samples.

Subsequently, samples obtained from native box turtles submitted to the Wildlife Center of Virginia from May 2002 to August 2003 or animals identified with URTD-LS, aural abscesses, or other unrelated diseases during routine herpetological surveys were assayed by box turtle *Mycoplasma* sp. sequence-specific PCR. Samples were obtained using saline premoistened swabs (Rayon® culturette, Fisher Scientific, Houston, USA) of ocular/nasal secretions from animals with URTD-LS signs. Alternatively, swabs collected from saline nasal flushes of animals without overt URTD-LS signs were submitted for PCR. Samples were placed into saline-containing sealed tubes, refrigerated or quick frozen at -20 C, and transported to the Center for Comparative Medicine, University of Virginia, Charlottesville, Virginia, for testing.

### DNA extraction

The DNA was isolated from culturettes using DNeasy silica spin columns (Qiagen, Valencia, California, USA) as follows. The tip of each culturette was placed into a sterile 1.5-ml microfuge tube containing 180 µl of buffer ATL and 20 µl of proteinase-K solution. The swab and digestion reagents were vortexed 10 sec followed by incubation at 55 C for 2 hr with shaking. Subsequently, each swab was discarded, and 200 µl of absolute ethanol and 200 µl of buffer AL (Qiagen) were added to the eluted sample. The solution was vortexed 10 sec, applied to a spin column, centrifuged (60 sec at 11,400 × G), and washed according to the manufacturer's instructions. Immobilized DNA was eluted from the column by application of 50 µl of 70 C distilled water, incubation for 60 sec, and centrifugation (60 sec, 11,400 × G). A 5-µl aliquot of each eluted sample was subjected to DNA amplification using a validated PCR assay optimized to detect the box turtle *Mycoplasma* sp. Primer specificity was determined based on comparisons of GenBank accessions with sequences obtained from clinical material. In addition, amplicon size and verification of base sequences were further validations.

### PCR amplification of mycoplasma 16S rRNA gene and amplicon cloning

The PCR primer sequences (5' to 3') used for amplification were as follows: sense

(*Escherichia coli* position 449) CTGCTGTTA-TACAGAAAGAAAAG and antisense (*E. coli* position 1466) GACTTTGGGCATTACCGGC. Each 50- $\mu$ l PCR reaction contained 0.5  $\mu$ M of each primer, 200  $\mu$ M of each deoxynucleotide triphosphate, 1.5 mM MgCl<sub>2</sub>, 2.5 units of Taq polymerase (Hotstar<sup>®</sup>, Qiagen), and 1X buffer supplied with the enzyme. Amplification was performed using a Robocycler 9600 gradient thermal cycler (Stratagene, La Jolla, California, USA). Thermal cycler settings were one cycle of 14 min and 15 sec at 95 C (hotstart); 35 cycles of denaturation at 95 C for 45 sec, annealing at 55 C for 1 min, extension at 72 C for 1 min 15 sec; and one cycle of final extension at 72 C for 5 min. The amplified products (993 nucleotides) from four positive samples (three symptomatic, one asymptomatic turtles) representing different Virginia geographical regions were cloned into plasmid pCR4 TOPO (Invitrogen Corporation, Carlsbad, California, USA) and transformed into competent *E. coli* Top 10<sup>®</sup> (Invitrogen). Two bacterial clone replicates produced from each sample were selected and further grown in Luria Bertani (LB) broth; plasmids were biotyped and purified using the Plasmid Mini Kit (Invitrogen). The biotyped plasmids were subjected to DNA sequencing by Davis Sequencing (davissequencing.com, University of California at Davis, Davis, California, USA). Overall, two replicate clones were analyzed to determine the consensus sequence of a given amplification product, and four distinct amplification products from turtles with differing clinical presentations and geographic locations were analyzed to determine the partial 16S rRNA consensus sequence for the *Mycoplasma* sp. DNA from Virginia box turtles.

#### Phylogenetic analyses of partial mycoplasma 16S rRNA gene sequence

A partial sequence comparison was made of 16S rRNA accessions from several *Mycoplasma* spp. in the National Institutes of Health GenBank. The DNA sequences were aligned using the PILEUP software in the Wisconsin<sup>®</sup> software package (Accelrys, Inc., Cambridge, UK), and the resulting alignment made compatible with the PHYLIP analysis software (PHYLIP: Phylogeny Inference Package, version 3.6a2, 1993, J. Felsenstein, Department of Genetics, University of Washington, Seattle, Washington, USA) using the READSEQ routine. The GenBank sequences were all truncated to correspond with the 5'- and 3'- ends of the DNA sequence determined for the box turtle *Mycoplasma* sp. One thousand data

sets were generated from the alignment using SEQBOOT and bootstrap analysis of the data sets, jumbling the input sequence order three times. DNAPARS software was used to find the most parsimonious trees. The consensus at branch points of the 1,000 trees was determined using CONSENSE, and the resulting phylogram was displayed using TREEVIEW (R. D. M. Page, 2001, Division of Environmental and Evolutionary Biology, Institute of Biomedical and Life Sciences, University of Glasgow, Glasgow G12 8QQ, Scotland, UK). The consensus phylogram furnishes the number of candidate phylograms out of the 1,000 generated, agreeing at any particular junction. An agreement of 500 of more phylograms at a branch point was considered significant (i.e., indicating a statistically significant relationship among sequences analyzed around that branch point).

#### Bacterial isolation

Culture for *Mycoplasma* spp. was attempted and consisted of sample filtration (0.8  $\mu$ m pore size) and plating on SP-4 (Remel Inc., Lexana, Kansas, USA) agar. Culture conditions consisted of incubation under anaerobic conditions at 30 C as previously described (Brown et al., 2001).

#### Screening for other causes of URTD

The same samples were also screened by PCR for chelonian herpesviruses (Van Devanter et al., 1996; Une et al., 2000) and invertebrate (Just et al., 2001) and vertebrate (including FV3) (Mao et al., 1997; Marschang et al., 1999) iridoviruses.

## RESULTS

Of 23 animals screened for *Mycoplasma* sp., seven animals representing six counties were PCR positive (Table 1; Fig. 1). The 16 turtles PCR negative for mycoplasma were dispersed over the seven counties examined, and some counties contained both PCR positive and negative turtles. Six counties had animals with aural abscessation (Table 1), but these were not necessarily identical to those counties with turtles PCR positive for *Mycoplasma* sp. (Green County had one PCR positive turtle without aural abscessation; Louisa County had one turtle with aural abscessation without detectable mycoplasma).

TABLE 1. Date of sample collection, location, sex, age, PCR test results, clinical signs, and presence or absence of aural abscesses for eastern box turtles screened for a unique *Mycoplasma* sp. by species-specific PCR.

Date	County	Sex <sup>a</sup>	Age <sup>b</sup>	PCR (+/-)	Clinical signs	Aural abscess signs (+/-)
5/01	Greene	M	A	+ <sup>c</sup>	Eye and bilateral nasal mucous discharge	-
5/02	Orange	F	A	-	Bilateral eye and nasal mucous discharge, cachexia	-
3/03	Orange	U	U	-	Bilateral blepharitis, eyelid edema, nasal discharge	-
5/03	Fluvanna	F	A	+ <sup>c</sup>	Bilateral mucopurulent nasal discharge and swollen closed eyes	+
6/03	Spotsylvania	M	A	+ <sup>c</sup>	Bilateral eye and nasal mucous discharge	+ <sup>d</sup>
6/03	Albemarle	U	A	+	Unilateral eye and nasal mucous, white plaques in pharynx	+
6/03	Albemarle	U	A	+ <sup>c</sup>	Trauma, fractured globe, plastron, and skull	-
6/03	Nelson	U	A	-	Trauma, maxillary fracture, globe rupture	-
6/03	Albemarle	F	A	-	Lacerated hindlimb	-
7/03	Rockbridge	F	A	+	Bilateral swollen eyelids and nasal mucous discharge	+
7/03	Albemarle	U	A	-	No other findings	+
7/03	Augusta	U	A	-	Trauma	-
7/03	Orange	U	A	-	Trauma	-
7/03	Albemarle	M	A	-	Bilateral swollen eyelids	+
7/03	Rappahannock	M	A	-	No other findings	+
7/03	Rappahannock	M	A	+	Bilateral swollen eyelids, mucopurulent nasal discharge	+
7/03	Rockingham	U	A	-	Trauma	-
7/03	Albemarle	U	A	-	Trauma	-
7/03	Louisa	M	A	-	No other findings	+
7/03	Albemarle	M	A	-	Trauma	-
8/03	Albemarle	U	A	-	Trauma	-
8/03	Albemarle	U	A	-	Trauma	-
8/03	Albemarle	U	A	-	Trauma	-

<sup>a</sup> M = Male, F = female, U = unknown.

<sup>b</sup> A = adult, U = unknown age.

<sup>c</sup> *Mycoplasma* sp. isolates sequenced in replicate for phylogenetic comparisons.

<sup>d</sup> Bilateral aural abscesses were present.

Six of the seven *Mycoplasma* sp.-positive turtles had clinical signs of URTD-LS (Table 1). Clinical signs were similar to those observed in tortoises infected with *M. agassizi* and included serous to mucopurulent nasal and ocular discharge, and erythematous swollen conjunctivas. Three animals had typical URTD-LS signs without aural abscessation, and two of these had no detectable *Mycoplasma* sp. from PCR (Table 1). Five

of the seven *Mycoplasma* sp.-positive cases and four of the 16 *Mycoplasma* sp.-negative cases had aural abscesses. *Mycoplasma* sp. PCR-negative animals had a range of afflictions (Table 1).

All samples were negative for chelonian herpesvirus, as well as invertebrate and vertebrate iridoviruses. No mycoplasma was isolated from bacterial culture.

Analysis of eight clones representing four different clinical samples provided

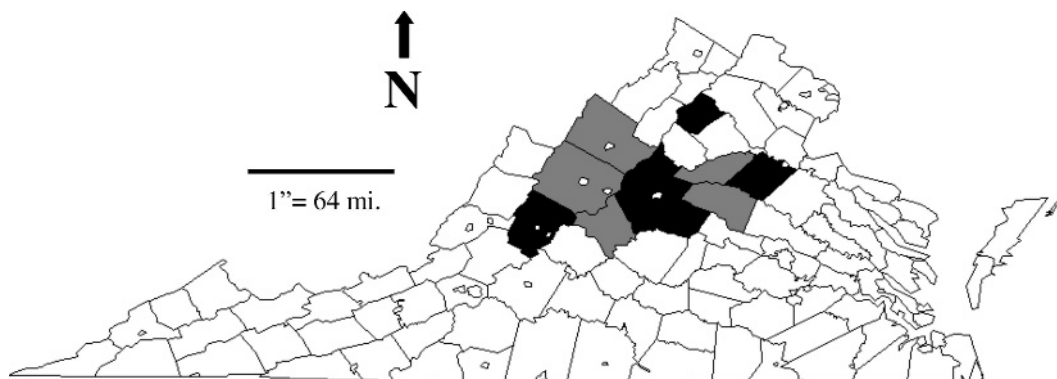


FIGURE 1. Counties where box turtles were collected and screened for iridovirus, herpesvirus, and box turtle-specific *Mycoplasma* by PCR are shaded. Turtles from the light-shaded counties were PCR negative for *Mycoplasma* infection. Dark-shaded counties had animals PCR positive for *Mycoplasma*. No viruses were detected from turtle samples screened for mycoplasma infection.

a consensus sequence with variation only at two nucleotide positions: nucleotide position 585 contained either C or G, and nucleotide position 812 contained either C or A. Alignment of the DNA sequence of Virginia box turtle *Mycoplasma* sp with *M. agassizii* (GenBank accessions AF060821 and MAU09786) demonstrated 98.2–98.4% sequence identity, differing between 16 and 18 nucleotide positions within the portion of the 16S rRNA region analyzed (Fig. 2). In contrast, the two *M. agassizii* sequences have 99.8% sequence identity (differing at only two nucleotides within the 993 bp of sequence analyzed). The phylogram (Fig. 3) depicts the close relationship of the Virginia box turtle *Mycoplasma* sp. sequence to the two *Mycoplasma agassizii* sequences deposited in GenBank but implies that a unique *Mycoplasma* sp. sequence was identified within this chelonian clade (i.e., the branch point of the box turtle *Mycoplasma* sp. sequence represented a consensus among all 1,000 phylograms). The close phylogenetic relationship of *M. agassizii* to *M. hyorhina* (Brown et al., 1995) is preserved in the box turtle *Mycoplasma* sequence (Fig. 3). *Mycoplasma pulmonis*, a respiratory and genitourinary pathogen of rodents, resides within this clade as well.

## DISCUSSION

*Mycoplasma agassizi* is the preponderant causative agent responsible for URTD in desert and gopher tortoises (Brown et al., 1994, 1999b); endemic *M. agassizi* disease has resulted in population declines of wild native tortoises (Jacobson et al., 1991; Brown et al., 1994; United States Fish and Wildlife Service, 1994; Brown et al., 1999b; Holladay et al., 2001), and the same agent affects a wide range of other tortoise species with a cyclical pattern of URTD signs (Brown et al., 1999a, b, 2001; Brown, 2002). *Mycoplasma agassizii* was recently identified from a wild-caught Florida Gulf Coast, USA, box turtle (*T. c. bauri*) with URTD (Brown et al., 2001 after Siefkas et al., 1998) and was hypothesized, but not confirmed, to be the cause of an over-winter die-off of radio-tracked eastern box turtles from North Carolina, USA (Rossell et al., 2002).

Occult mycoplasma infection is punctuated with cyclical appearance of clinical signs during *M. agassizi* infection in tortoises (Brown et al., 1999a); this pattern of disease expression in the tortoises is consistent with observations involving the characterization of mycoplasma associated URTD-LS of eastern box turtles in this series. Our results are consistent with the




FIGURE 2. Listed are 993 bp of the 16S rRNA region from the novel box turtle *Mycoplasma* sp. compared with two closely related sequences of *M. agassizi* (AF060821 and U09786) from GenBank.

observation regarding PCR detection of mycoplasma in tortoises, in that animals serving as carriers may only intermittently shed (Brown et al., 1999b). Thus, in the absence of confirmatory tests, long-term monitoring of suspect turtles for the appearance of clinical signs may be warranted prior to translocation, to avoid spreading the disease.

Positive PCR detection indicates direct agent identification, a potential advantage over serological diagnosis. In our limited series, PCR detection was greater in animals with overt clinical signs (notably oculonasal discharge), similar to *M. agassizi* detection in captive desert tortoises; however, presence of clinical signs per se did not have a 100% correspondence with PCR detection in a captive colony of United States Fish and Wildlife Service-donated *Mycoplasma*-positive tortoises diagnosed by enzyme-linked immunosorbent assay (ELISA) (Wimsatt, unpubl. data). Although a single nasal flush from an asymptomatic turtle tested PCR positive, routine screening for mycoplasma would be expected to have a low yield because of the preponderance of animals without disease and those not shedding the organism.

Serological screening for antimycoplasma antibodies has been widely used to detect mycoplasma carriers in wild tortoise species (Brown et al., 1999a). The seroprevalence of eastern box turtles from Pennsylvania, USA (Belzer, 1996), and New York State, USA (Calle et al., 1998), for *M. agassizi* were 0% and 43%, respectively, using ELISA with reagents validated in tortoises for detection of *M. agassizi*. These surveys suggested no association of seropositive animals with clinical signs, suggesting either false positive serology results or the presence of an avirulent mycoplasma in New York turtles. A more recent survey detected seropositive resident, rehabilitated and repatriated box turtles in a state park in southeastern New York, and a single culture-positive asymptomatic resident wild animal was

identified at this study site (P. Calle, pers. comm., 2003). Even so, caution is warranted in interpreting a tortoise-validated serology test in other species (United States Fish and Wildlife Service, 1994; Lee et al., 2003).

Eastern box turtles may range widely, increasing the likelihood of disease transmission and dissemination. In addition, they engage in considerable conspecific contact during courtship and during aggressive displays between males (Dodd, 2001); stress associated with courtship and the opportunity for close contact could increase the likelihood of mycoplasma transmission between turtles. Desert tortoises frequently share burrows (especially summer burrows and Mojave tortoise aggregates [Lederle et al., 1997]) in small groups (Ernst and Barbour, 1989), and this behavior may contribute to *Mycoplasma agassizi* spread. In contrast, eastern box turtles often burrow singly (Dodd, 2001); even so, whether this behavioral difference is sufficient to reduce the risk of mycoplasma transmission in box turtles is unknown. The potential impact of environmental cofactors on the occurrence and recrudescence of URTD signs has been highlighted for desert tortoises harboring *M. agassizi* (Lederle et al., 1997).

In a recent survey, significant morbidity in Virginia box turtles that often had signs indistinguishable from URTD-LS was attributed to anthropogenic trauma and aural abscessation (Brown and Sleeman, 2002). Aural abscessation was an occasional finding in one survey of free-living Virginia box turtles brought to a rehabilitation center (Brown and Sleeman, 2002). In the present series, some Virginia box turtles with aural abscessation presented similar to those seen in URTD-LS. The present study does not provide support for a relationship between aural abscess development and mycoplasma infection. The relationship between mycoplasma colonization, URTD-LS in box turtles, and the contribution of other etiologic factors such



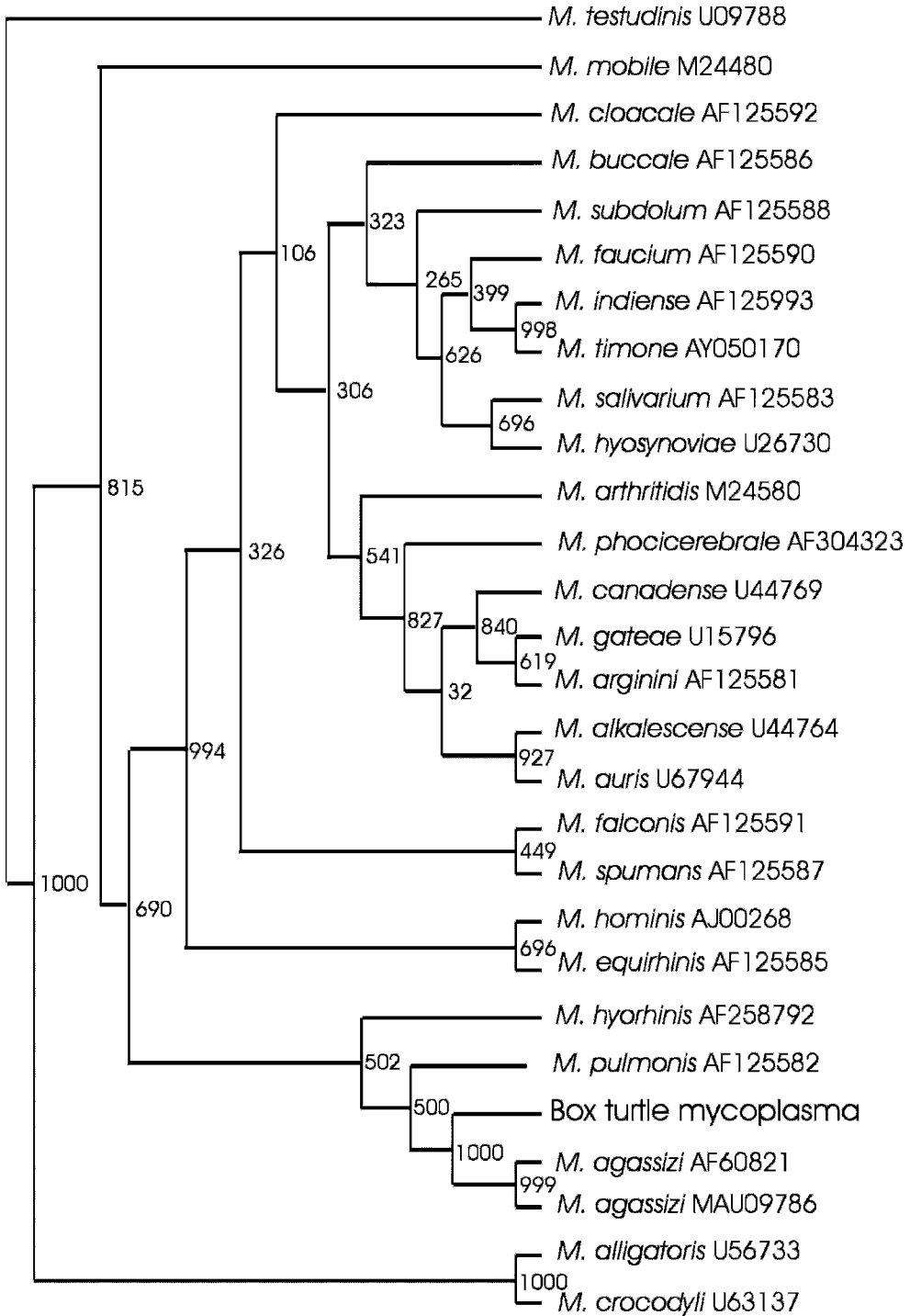


FIGURE 3. Phylogram comparing the 16S rRNA sequence of the novel *Mycoplasma* sp. from Virginia eastern box turtles with other known pathogenic *Mycoplasma* spp. GenBank accessions used in the analyses were *Mycoplasma agassizii* (AF060821), *M. agassizii* (MAU09786), *M. mobile* (M24480), *M. cloacale* (AF125592), *M. buccale* (AF125586), *M. hyorhinis* (AF258792), *M. subdolum* (AF125588), *M. testudineum* (U09788), *M. faucium* (AF125590), *M. indiense* (AF125993), *M. timone* (AY050170), *M. salivarium*

as those associated with aural abscessation warrant further study. Recently it has been proposed that organochlorine-induced vitamin A deficiency may predispose box turtles to aural abscess formation, common in native Virginia box turtles (Holladay et al., 2001) and may explain how vitamin A deficiency could occur in wild turtles on natural diets. Other factors may predispose to aural abscessation (Murray, 1996). For example, aural abscessation has been reported from wild box turtles from New York (P. Calle, pers. comm., 2003), North Carolina (K. Grayson, pers. comm., 2006), and Florida (Dodd and Griffey, 2004), where it was attributed to high rainfall.

Turtles with mycoplasma were fortuitously collected by the public and by biologists performing herpetological surveys. Thus, case distribution may be more a reflection of proximity to the Wildlife Center of Virginia and where surveys were performed rather than a reflection of the true distribution of disease. Mycoplasma cases detected via the Wildlife Center were fortuitously selected from a considerably larger group submitted to the center, and sampling was likely biased in favor of animals with clinical signs of either aural abscessation, URTD-LS, or the timing of available turtles to sample.

Although molecular analysis of the Virginia box turtle *Mycoplasma* sp. was performed to determine its taxonomic relationship to known *Mycoplasma* spp., further characterization based on the organism's biochemical properties, serum cross-neutralization assays, and culture requirements is required. However, repeated attempts to isolate this fastidious organism using SP-4 agar as previously described (Brown et al., 2001) have been

unsuccessful, currently making further characterization impossible. Although there is some evidence of disease transmission from this report, isolation of this new putative *Mycoplasma* sp. is needed for controlled challenge studies to fulfill Koch's postulates and to confirm that it is a primary pathogen, as was previously demonstrated for *M. agassizi* in native tortoise species (Brown et al., 1994, 1999b).

The impact of *M. agassizi*-induced disease on native Mojave Desert and Southeastern US gopher tortoise populations has been dramatic and well documented (Homer et al., 1998; Brown et al., 1999a). Similarly, *M. agassizi* is endemic in Sonoran Desert tortoise populations south of the Colorado River, yet the population does not appear to be declining from URTD (Dickinson et al., 2002), and the distribution of differing genetic assemblages based on mitochondrial DNA typing does appear to directly map to mycoplasma disease expression (Lamb and McLuckie, 2002). Current evidence supports greater food and water availability and life style differences as cofactors in the decline of desert tortoises in the Mojave life zone (Lamb and McLuckie, 2002). Thus, a careful evaluation of the role of *Mycoplasma* sp. strain (virulence) differences and the impact of concurrent environmental stressors on the expression of disease in Eastern box turtles are factors worthy of further investigation.

If the *Mycoplasma* sp. of eastern box turtles proves to have either a primary or secondary pathogenic effect (opportunistically capitalizing upon anthropogenic or environmental disturbances), better estimates of its impact on over-winter mortality and population dynamics are of utmost importance to safeguard native

←

(AF125583), *M. hyosynoviae* (U26730), *M. arthritidis* (M24580), *M. phocicerebrale* (AF304323), *M. canadense* (U44769), *M. gatae* (U15796), *M. argininini* (AF125581), *M. alkalescens* (U44764), *M. auris* (U67944), *M. falconis* (AF125591), *M. spumans* (AF125587), *M. hominis* (AJ00268), *M. equirhinis* (AF125585), *M. pulmonis* (AF125582), *M. alligatoris* (U56733), and *Mycoplasma crocodyli* (U63137).

turtle populations for future generations. In addition, the occurrence of this *Mycoplasma* in other turtle species of the US mid-Atlantic region and detailed mapping of the distribution of this *Mycoplasma* sp. are critical to assess its ultimate impact.

#### ACKNOWLEDGMENTS

The authors would like to thank Gregg Kneipp of the National Park Service at the Fredericksburg National Battlefield Memorial Park, in Fredericksburg, Virginia, USA, and Jean Marie Richards and Jane Carman for their valuable assistance. We would also like to thank Elliott Jacobson and two anonymous reviewers for their helpful suggestions. Samples were collected under permit from the Virginia Department of Game and Inland Fisheries (Scientific Collection Permit 022992) and federal permit FRSP-2003-SCI-0002 from the National Park Service.

#### LITERATURE CITED

- BELZER, W. 1996. Box turtle repatriation in north-western Pennsylvania. *Box Turtle Newsletter* 4: 2–3.
- BROWN, D. R. 2002. Mycoplasmosis and immunity of fish and reptiles. *Frontiers in Biosciences* 7: 1338–1346.
- , B. C. CRENSHAW, G. S. McLAUGHLIN, I. M. SCHUMACHER, C. E. McKENNA, P. A. KLEIN, E. R. JACOBSON, AND M. B. BROWN. 1995. Taxonomic analysis of the tortoise mycoplasmas *Mycoplasma agassizii* and *Mycoplasma testudinis* by 16S rRNA gene sequence comparison. *International Journal of Systematic Bacteriology* 45: 348–350.
- BROWN, J. D., AND J. M. SLEEMAN. 2002. Morbidity and mortality of reptiles admitted to the Wildlife Center of Virginia. *Journal of Wildlife Diseases* 38: 699–705.
- BROWN, M. B., I. M. SCHUMACHER, P. A. KLEIN, K. HARRIS, T. CORRELL, AND E. R. JACOBSON. 1994. *Mycoplasma agassizii* causes upper respiratory tract disease in the desert tortoise. *Infection and Immunity* 62: 4580–4586.
- , K. H. BERRY, I. M. SCHUMACHER, K. A. NAGY, M. M. CHRISTOPHER, AND P. A. KLEIN. 1999a. Seroepidemiology of upper respiratory tract disease in the desert tortoise in the Western Mojave Desert of California. *Journal of Wildlife Diseases* 35: 716–727.
- , G. S. McLAUGHLIN, P. A. KLEIN, B. C. CRENSHAW, I. M. SCHUMACHER, D. R. BROWN, AND E. R. JACOBSON. 1999b. Upper respiratory tract disease in the gopher tortoise is caused by *Mycoplasma agassizii*. *Journal of Clinical Microbiology* 36: 2262–2269.
- , D. R. BROWN, P. A. KLEIN, G. S. McLAUGHLIN, I. M. SCHUMACHER, E. R. JACOBSON, H. P. ADAMS, AND J. G. TULLY. 2001. *Mycoplasma agassizii* sp. nov., biotyped from the upper respiratory tract of the desert tortoise (*Gopherus agassizii*) and the gopher tortoise (*Gopherus polyphemus*). *International Journal of Systematic and Evolutionary Microbiology* 51(part 2): 413–418.
- CALLE, P. P., J. McDOUGAL, J. L. BEHLER, I. SCHUMACHER, AND D. R. BROWN. 1998. Mycoplasma survey of captive and free-ranging Eastern box turtles (*Carpentaria carolina*) in New York. In *Proceedings, American Association of Zoo Veterinarians and the American Association of Wildlife Veterinarians*, Omaha, Nebraska, 17–22 October, pp. 285–286.
- DICKINSON, V., J. JARCHOW, M. TRUEBLOOD, AND J. DEVOS. 2002. Are free-ranging Sonoran desert tortoises healthy? In *The Sonoran Desert tortoise*, T. R. Van Devender (ed.). University of Arizona Press, Tucson, Arizona, pp. 67–85.
- DODD, C. K. 2001. North American box turtles: A natural history. University of Oklahoma Press, Norman, Oklahoma, 231 pp.
- , AND M. L. GRIFFEY. 2004. Aural abscesses on Florida box turtles are associated with abnormally wet winters. *Herpetological Reviews* 35: 233–235.
- ERNST, C., AND R. BARBOUR. 1989. *Turtles of the world*. Smithsonian Institution, Washington, D.C., 313 pp.
- HOLLADAY, S. D., J. C. WOLF, S. A. SMITH, D. E. JONE, AND J. L. ROBERTSON. 2001. Aural abscesses in wild-caught box turtles (*Terrapene carolina*): Possible role of organochlorine-induced hypovitaminosis A. *Ecotoxicology and Environmental Safety*, Section B 48: 99–106.
- HOMER, B. L., K. H. BERRY, M. B. BROWN, G. ELLIS, AND E. R. JACOBSON. 1998. Pathology of diseases in wild desert tortoises from California. *Journal of Wildlife Diseases* 34: 508–523.
- JACOBSON, E. R. 1994. The desert tortoise and upper respiratory disease. *Bulletin of the Association of Reptilian and Amphibian Veterinarians* 4: 6–7.
- , J. M. GASKIN, M. B. BROWN, R. K. HARRIS, C. H. GARDNER, J. L. LAFONTE, H. P. ADAMS, AND C. REGGIARDO. 1991. Chronic upper respiratory tract disease of free-ranging desert tortoises (*Xerobates agassizii*). *Journal of Wildlife Diseases* 27: 296–316.
- JUST, F., S. ESSBAUER, W. AHNE, AND S. BLAHAK. 2001. Occurrence of an invertebrate iridescent-like virus (Iridoviridae) in reptiles. *Journal of Veterinary Medicine B* 48: 685–694.
- LAMB, T., AND A. McLUCKIE. 2002. Chapter 4.

- Genetic differences among geographic races of the desert tortoise. *In* The Sonoran Desert tortoise, T. R. Van Devender (ed.). University of Arizona Press, Tucson, Arizona, pp. 67–85.
- LEDERLE, P. E., K. R. RAUTENSTRAUCH, D. L. RAKESTRAW, K. K. ZANDER, AND J. L. BOONE. 1997. Upper respiratory tract disease and mycoplasmosis in desert tortoises from Nevada. *Journal of Wildlife Diseases* 33: 759–765.
- LEE, S. M., P. P. CALLE, R. L. BURKE, J. L. BEHLER, L. WENDLAND, AND M. B. BROWN. 2003. Health assessment of resident and repatriated Eastern box turtles at Caumsett State Park. *In* Abstracts of the Wildlife Society, 10th Annual Conference, Burlington, Vermont, p. 176.
- MAO, J., R. HEDRICK, AND V. CHINCHAR. 1997. Molecular characterization, sequence analysis and taxonomic position of newly biotyped fish iridoviruses. *Virology* 229: 212–220.
- MARSCHANG, R., P. BECHER, H. POSTHAUS, P. WILD, H.-J. THIEL, U. MULLER-DOBLIES, E. KALETA, AND L. BACCIARINI. 1999. Isolation and characterization of an iridovirus from Hermann's tortoises (*Testudo hermanni*). *Archives of Virology* 144: 1909–1922.
- MURRY, M. 1996. Aural abscesses. *In* Reptile medicine and surgery, D. M. Mader (ed.). W. B. Saunders, Philadelphia, Pennsylvania, pp. 349–352.
- ROSSELL, C. R., I. M. ROSSELL, M. M. ORRACA, AND J. W. PETRANKA. 2002. Epizootic disease and high mortality in a population of Eastern box turtles. *Herpetological Review* 33: 99–101.
- SIEFKAS, J., T. FARRELL, AND P. MAY. 1998. Infection by *Mycoplasma agassizi* in a box turtle and its implications for conservation biology. *Florida Scientist* 61(Supp.): 18.
- UNE, Y., M. MURAKAMI, K. UEMURA, H. FUJITANI, T. ISHIBASHI, AND Y. NOMURA. 2000. Polymerase chain reaction (PCR) for the detection of herpesvirus in tortoises. *Journal of Veterinary Medical Science* 62: 905–907.
- UNITED STATES FISH AND WILDLIFE SERVICE. 1994. Desert tortoise (Mojave population) recovery plan. USFWS, Washington D.C., 73 pp. + appendices.
- VAN DEVANTAR, D., P. WARRENER, L. BENNETT, E. SCHULTZ, S. COULTER, R. GARBER, AND T. ROSE. 1996. Detection and analysis of diverse herpesviral species by consensus primer PCR. *Journal of Clinical Microbiology* 34: 1666–1671.
- WIMSATT, J. H., J. JOHNSON, B. A. MANGONE, A. TOTHILL, J. M. CHILDS, AND C. A. PELOQUIN. 1999. Clarithromycin pharmacokinetics in the desert tortoise (*Gopherus agassizii*). *Journal of Zoo and Wildlife Medicine* 30: 36–43.

*Received for publication 29 July 2004.*