



Intracytoplasmic Inclusions in Circulating Leukocytes from an Eastern Box Turtle (*Terrapene carolina carolina*) with Iridoviral Infection

Authors: Allender, Matthew C., Fry, Michael M., Irizarry, Armando R., Craig, Linden, Johnson, April J., et al.

Source: Journal of Wildlife Diseases, 42(3) : 677-684

Published By: Wildlife Disease Association

URL: <https://doi.org/10.7589/0090-3558-42.3.677>

BioOne Complete (complete.BioOne.org) is a full-text database of 200 subscribed and open-access titles in the biological, ecological, and environmental sciences published by nonprofit societies, associations, museums, institutions, and presses.

Your use of this PDF, the BioOne Complete website, and all posted and associated content indicates your acceptance of BioOne's Terms of Use, available at www.bioone.org/terms-of-use.

Usage of BioOne Complete content is strictly limited to personal, educational, and non - commercial use. Commercial inquiries or rights and permissions requests should be directed to the individual publisher as copyright holder.

BioOne sees sustainable scholarly publishing as an inherently collaborative enterprise connecting authors, nonprofit publishers, academic institutions, research libraries, and research funders in the common goal of maximizing access to critical research.

Intracytoplasmic Inclusions in Circulating Leukocytes from an Eastern Box Turtle (*Terrapene carolina carolina*) with Iridoviral Infection

Matthew C. Allender,^{1,5,6} Michael M. Fry,² Armando R. Irizarry,³ Linden Craig,² April J. Johnson,⁴ and Michael Jones^{2,1} University of Illinois, College of Veterinary Medicine, 2001 South Lincoln Ave., Urbana, Illinois 61802, USA; ² University of Tennessee, College of Veterinary Medicine, 2407 River Dr., Knoxville, Tennessee 37996, USA; ³ Eli Lilly and Company, Lilly Research Laboratories, PO Box 708, Greenfield, Indiana 46140, USA; ⁴ University of Florida, College of Veterinary Medicine, PO Box 100126, Gainesville, Florida 32608, USA; ⁵ Current address: University of Tennessee, College of Veterinary Medicine, 2001 South Lincoln Ave, Urbana, Illinois, 61802, USA; ⁶ Corresponding author: (email: mattallender@yahoo.com)

ABSTRACT: A free-ranging adult female eastern box turtle (*Terrapene carolina carolina*) was presented to the University of Tennessee in October 2003 because of suspected trauma and blindness. Physical examination revealed lethargy, clear ocular and nasal discharges, and white oral and laryngeal plaques. Intracytoplasmic inclusions within heterophils and large mononuclear leukocytes were observed on routine blood smear examination. Postmortem findings included necrosis of epithelial and parenchymal cells with intracytoplasmic inclusions. Ultrastructurally, the leukocyte inclusions consisted of variably electron-dense granular material and viral particles consistent with the *Iridoviridae* family of viruses. The virus shared 100% sequence identity to a 420-base pair sequence of frog virus 3 (family *Iridoviridae*, genus *Ranavirus*) as determined by polymerase chain reaction and gene sequencing targeting a portion of the *Ranavirus* major capsid protein gene.

Key words: Electron microscopy, frog virus 3, intracytoplasmic inclusion, iridovirus, leukocyte, PCR, *Ranavirus*, *Terrapene carolina*.

The family *Iridoviridae* consists of four genera of large, icosahedral, enveloped, cytoplasmic, double-stranded DNA (Mao et al., 1997; Marschang et al., 1999), and iridoviruses in the genera *Ranavirus* and *Lymphocystitivirus* cause infections in vertebrate hosts (Mao et al., 1997; Marschang et al., 1999; Jancovich et al., 2003; De Voe et al., 2004). Frog virus 3 (FV3) of the genus *Ranavirus* has been specifically identified as pathogenic to fish, amphibians, and reptiles (Mao et al., 1997). Round-to-ovoid intracytoplasmic inclusions associated with iridoviral infections have been reported from reptiles in

gastric, intestinal, hepatic, tracheal, and pulmonary epithelial cells as well as erythrocytes (Johnsrude et al., 1997; Marschang et al., 1999; Just et al., 2001). However, to date, no intracytoplasmic inclusions have been reported in leukocytes of reptiles or amphibians infected with iridoviruses.

In October 2003, a free-ranging adult female eastern box turtle (*Terrapene carolina carolina*) from Knox County, Tennessee (35°49'N, 83°59'W) was presented to the Avian and Zoological Clinical Service of the Veterinary Medical Teaching Hospital at the University of Tennessee, Knoxville, Tennessee, USA, because of suspected trauma and blindness. On initial examination, the animal weighed 336 g, its eyelids were closed, and it had clear ocular and nasal discharges. Supportive care was initiated with ceftazidime (17.8 mg/kg, Abbott Laboratories, North Chicago, Illinois, USA) and vitamins A and D (0.05 ml, Vedco, Inc., St. Joseph, Missouri, USA). Thoracic radiographs revealed no abnormalities. Ophthalmologic findings consisted of severe conjunctivitis.

The turtle had a packed cell volume of 13%. Absolute and differential white blood cell (WBC) counts were not performed, because the moderate number of disrupted cells noted on routine blood smear prevented an accurate determination of leukocyte populations. Based on subjective blood smear evaluation, the total number of WBCs was considered moderately increased and consisted pre-

dominantly of azurophils and monocytes. Intracytoplasmic inclusions were observed within most monocytes and azurophils, and occasionally within heterophils. The inclusions were pink, granular, usually single, round-to-oval structures of 3–7 μm in diameter, but they were occasionally noted as multiple smaller fragments (Fig. 1). The cause of these inclusions was not known, but possibilities included viral, protozoal, chlamydial, or rickettsial organisms or phagocytosed cellular debris (Desser and Barta, 1984; Johnson and Telford, 1990; Campbell, 1996). Cells with karyorrhexis (nuclear fragmentation) also were noted in low numbers.

The turtle became anorexic, lost weight (317 g body weight), had increased clear ocular and nasal discharges, and became progressively depressed. In addition, slightly raised, white plaques developed on the tongue and later the oral mucosa. Treatment with ceftazidime was continued every third day and was supplemented with Normosol-R (3 ml SQ every 12 hr, Abbott Laboratories), enrofloxacin (10.25 mg/kg SQ every 48 hr, Baytril 22.7 mg/ml, Bayer Health Care, Shawnee Mission, Kansas, USA), and feeding by gavage (3 ml a/d PO every 24 hr, Hill's Prescription Diets, Topeka, Kansas, USA). The animal died 6 days after presentation despite treatment and was submitted for necropsy.

At necropsy, the turtle was dehydrated and in poor body condition. There were multiple coalescing 1- to 3-mm tan-yellow plaques on the tongue, oral cavity, palate, pharynx, and esophagus (Fig. 2). The gastric mucosa had 1–2-mm-diameter depressed red foci with pinpoint white centers. Significant histologic findings included severe necrotizing conjunctivitis with cytoplasmic inclusions, severe acute necrotizing glossitis, esophagitis, and tracheitis, multifocal acute necrotizing pneumonia with cytoplasmic inclusions, moderate multifocal random acute hepatocellular necrosis with cytoplasmic inclu-

sions (Fig. 3), moderate multifocal acute necrotizing enteritis and glomerulonephritis, mild focal acute necrotizing pancreatitis, mild multifocal acute necrotizing cystitis, and intramural gastric nematodes of undetermined species. Numerous gamma-hemolytic *Streptococcus* sp. were isolated from the esophagus.

To characterize the intracytoplasmic inclusions in peripheral blood leukocytes, formalin-fixed fragments of clotted blood from the necropsy tissues were postfixed in modified Karnovsky's fixative and osmium tetroxide, processed routinely to epoxy resin blocks, sectioned, and examined with an electron microscope (FEI/Phillips 100-CM, Hillsboro, Oregon, USA). Consistent with hematologic findings, intracytoplasmic inclusions were within mononuclear leukocytes and heterophils and consisted primarily of round-to-amorphous aggregates of granular material with variable numbers of viral particles (Figs. 4, 5). The aggregates of granular material were variably sized, lightly to moderately electron dense, and were generally free in the cytoplasm. The composition of the material is unknown, although viral-coded protein is suspected. Rarely seen inclusions were lined by a single membrane. The hexagonal icosahedral viral particles were approximately 125 nm in diameter, were present free in the cytoplasm, and were consistent with an iridovirus.

A frozen spleen sample was submitted for virus isolation and polymerase chain reaction (PCR) assays. The sample was homogenized, filtered through a 0.45- μm syringe filter (Corning Life Sciences, Acton, Massachusetts, USA), and inoculated onto a confluent monolayer of *Terrapene* heart cells (ATCC #CCL50). Cell culture demonstrated cytopathic effects 2 days postinfection, and intracytoplasmic inclusion bodies were observed in affected cells (Fig. 6). DNA was extracted from 10 μg of frozen spleen by using the DNEasy kit (QIAGEN, Valencia, California, USA). Polymerase chain reaction using sense primer (5'-GACTTGCC-

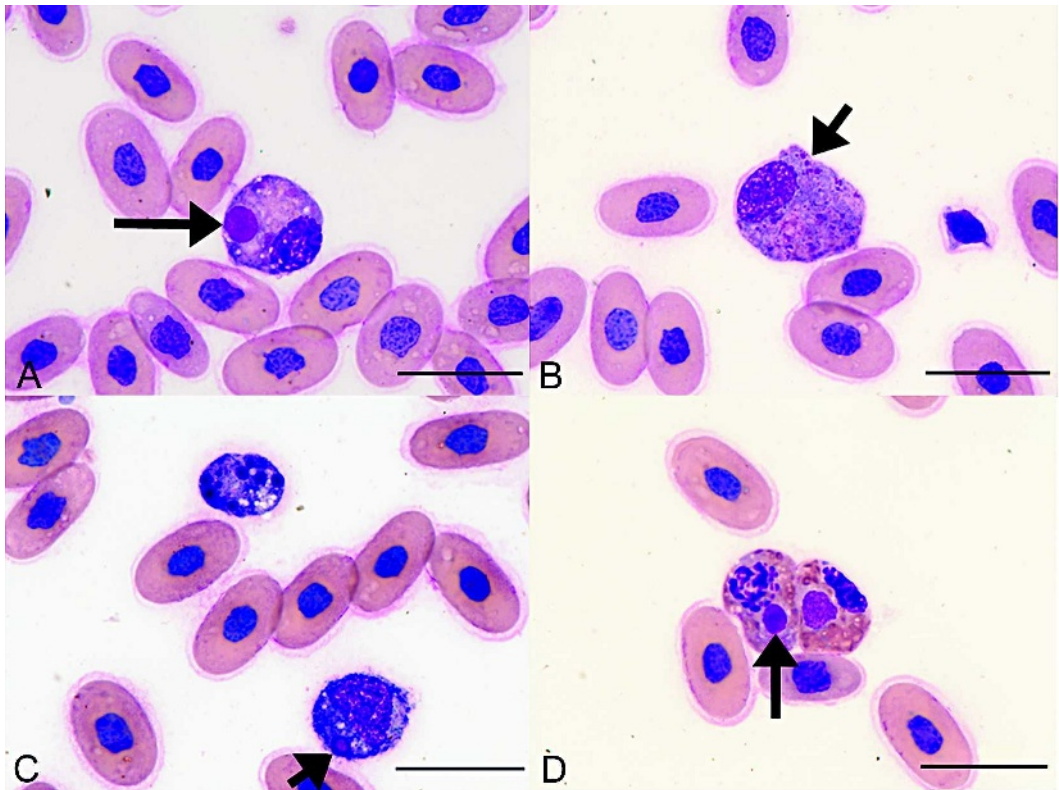


FIGURE 1. Intracytoplasmic inclusions within circulating leukocytes. A: Single large inclusion (arrow) within an azurophil. B: Multiple small inclusions (arrow) within an azurophil. C: Single inclusion (arrow) within a monocyte, and a cell of uncertain lineage with karyorrhexis. D: Single inclusions (arrow) within two heterophils. The cell on the left is beginning to show karyorrhexis. Wright stain. Bar=20 μ m.

CACTTATCAC-3') and antisense primer (5'-GTCTCTGGAGAAGAAGAA-3') targeting a portion of the *Ranavirus* major capsid protein gene was performed as described previously (Mao et al., 1997). The resulting product was resolved in a 1% agarose gel infused with ethidium bromide (Fig. 7). The band was excised from the gel and purified using the QIAquick gel extraction kit (QIAGEN). The product was sequenced directly in both directions by using the Big Dye Terminator kit (PerkinElmer, Branchburg, New Jersey, USA) and analyzed on ABI 377 automated DNA sequencers (Applied Biosystems, Foster City, California, USA) at the University of Florida's Sequencing Center (Gainesville, Florida, USA). Amplification resulted in a 420-base pair product when

primer sequences were edited out. The sequence was compared with known sequences in GenBank (National Center for Biotechnology Information, Bethesda, Maryland, USA), European Molecular Biology Laboratory (Cambridge, United Kingdom), and Data Bank of Japan (Mishima, Shizuoka, Japan) databases by using TBLASTX (Altschul et al., 1997). The TBLASTX results showed the sequence from the box turtle shared 100% sequence identity with the FV3 major capsid protein gene (GenBank accession no. AF157769).

Ranavirus infections are emerging as causes of serious clinical diseases among wild and captive chelonian populations in many parts of the world (Westhouse et al., 1996; Mao et al., 1997; Chen et al., 1999;

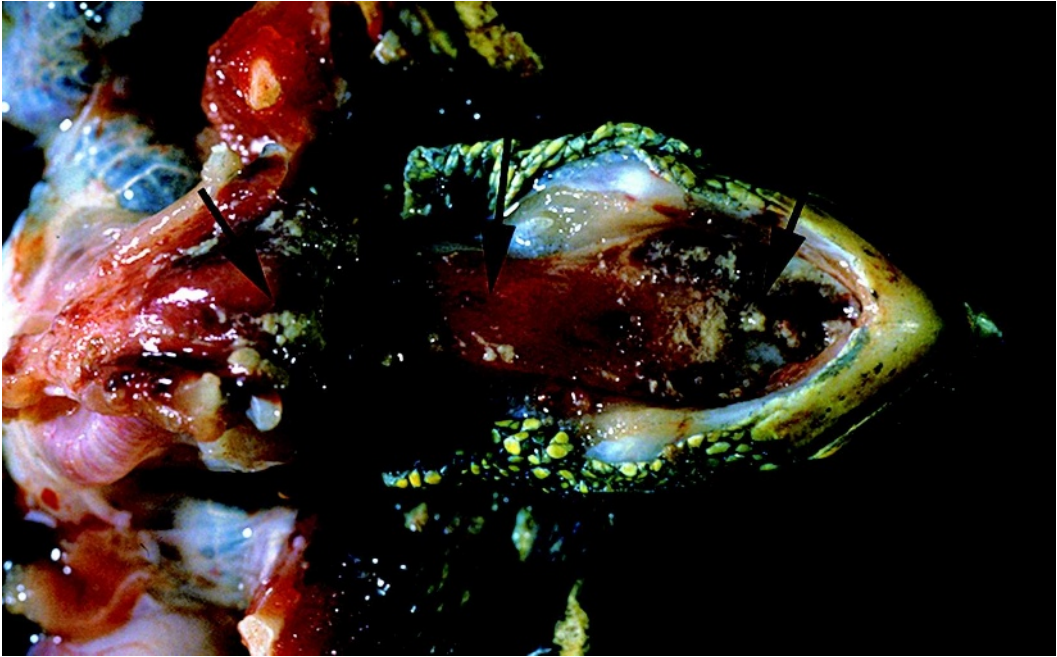


FIGURE 2. Box turtle with fibrinonecrotic plaques on the oral and esophageal mucosa (arrows).

Marschang et al., 1999; De Voe et al., 2004). In addition, reptilian infections from an iridovirus previously thought to infect only invertebrates were documented in two bearded dragons (*Pogona vitticeps*), a chameleon (*Chamaeleo quadricornis*), and a frilled-neck lizard (*Chamydosaurus kingii*) (Just et al., 2001).

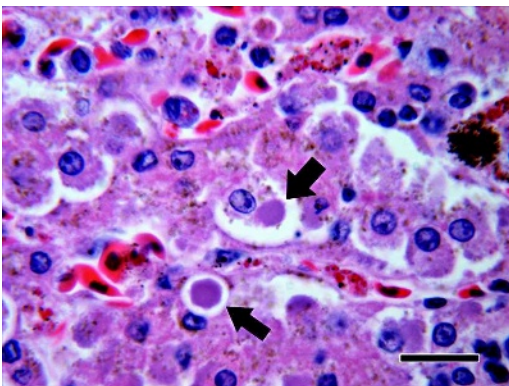


FIGURE 3. Liver: Multifocal intracytoplasmic inclusions within hepatocytes (arrows). H&E stain. Bar=20 μ m.

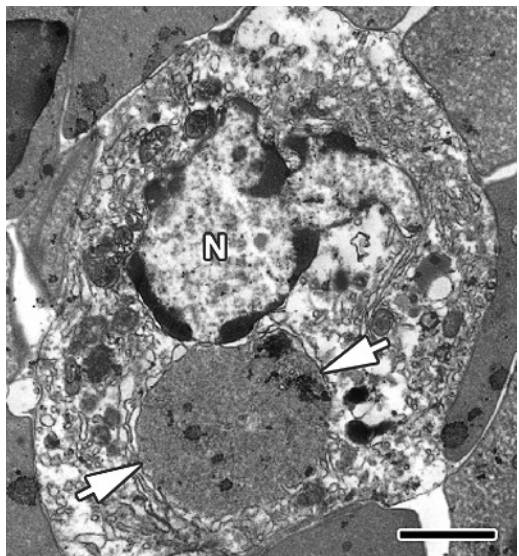


FIGURE 4. Electron micrograph of a peripheral blood monocyte with an intracytoplasmic inclusion (arrows). The inclusion consists of finely granular slightly electron dense material. Viral particles were not associated with the inclusion. N=nucleus. Bar=2 μ m.




FIGURE 5. Electron micrograph of a peripheral blood heterophil with iridoviral particles (V) free in the cytoplasm. HG=heterophil granules, N=nucleus, M=mitochondria. Bar=1 μ m. Inset, greater magnification of area with viral particles. Bar=0.5 μ m.

Clinical manifestations of iridoviral infections in reptiles are not always present, but they may include dyspnea, ocular, nasal and oral discharges, and death (Westhouse et al., 1996; Marschang, 1999).

The turtle of the current report was presented with clinical signs consistent with trauma and respiratory disease. Trauma is a frequent cause of morbidity and mortality in box turtles (Brown and Sleeman, 2002); however, physical examination and diagnostic imaging did not reveal any evidence of trauma. Respiratory disease is commonly reported in chelonians and may be caused by herpesvirus; *Mycoplasma*; iridovirus; various bacterial, fungal, or parasitic agents; nutritional deficiencies; and noninfectious inflammatory diseases (Brown et al., 1994; Murray, 1996; Schumacher, 1996; Origgi et al., 2004). Herpesvirus infections in chelonians typically cause ocular and nasal discharges, stomatitis, regurgitation, anorexia, and rarely central nervous system disease (Schumacher, 1996; Origgi et al., 2004). In the current case, there was no histologic evidence of herpesviral infec-

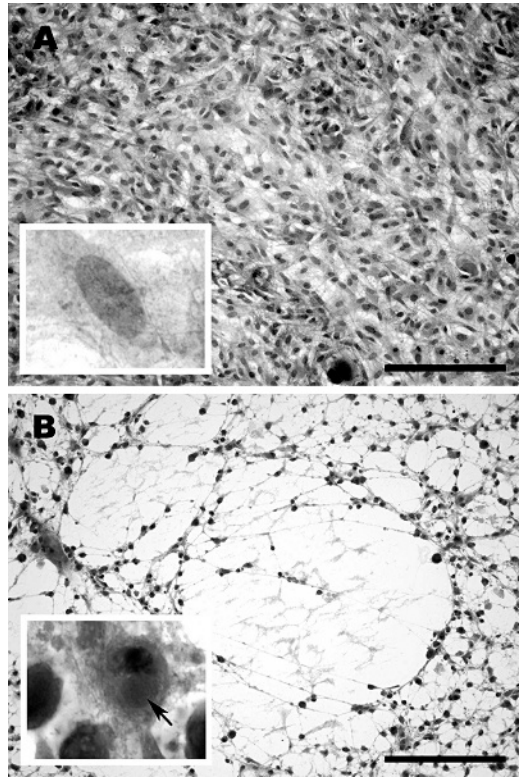


FIGURE 6. H&E staining of uninfected and infected monolayers of *Terrapene* heart cells. A. Uninfected cell layer control. Bar=200 μ m. Inset shows a higher magnification of a normal cell. B. Infected cell monolayer demonstrating cytopathic effects 2 days postinfection. Bar=200 μ m. Inset shows a higher magnification of an infected cell with an intracytoplasmic inclusion body (arrow).

tion, and no herpesviruses were isolated. *Mycoplasma agassizii* infections have been reported in desert tortoise populations in California with upper respiratory signs similar to the signs of the turtle in the current report; however, stomatitis, as was seen in the present case, was not reported (Brown et al., 1994). Additional diagnostic assays for *M. agassizii* were not pursued, because infection with this organism was considered unlikely. Hypovitaminosis A of reptiles frequently results in respiratory disease secondary to squamous metaplasia of the respiratory epithelium, and subsequent opportunistic bacterial infections (Murray, 1996). Noninfectious causes

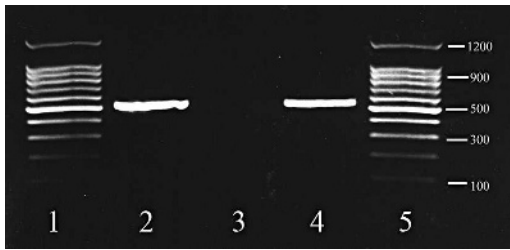


FIGURE 7. Agarose gel showing polymerase chain reaction (PCR) products of a portion of the major capsid protein gene. Lane 1=100-base pair [bp] ladder, lane 2=University of Tennessee box turtle, lane 3=negative control, lane 4=positive control, lane 5=100-bp ladder.

such as foreign bodies and cardiac or liver disease also may cause respiratory signs in turtles (Murray, 1996). The turtle of the current case did not have any microscopic evidence of lesions associated with hypovitaminosis A, other noninfectious causes of respiratory disease, or primary fungal, bacterial, or protozoal infection. The gamma-hemolytic *Streptococcus* sp. cultured from the esophagus was likely a secondary pathogen.

A recent report of iridoviral infection in box turtles showed similar cutaneous and mucosal lesions to the turtle of the current case (De Voe et al., 2004). That report, however, described fibrinoid vasculitis of the integument, liver, lungs, eye, spleen, stomach, intestines, colon, kidney, heart, and great vessels with no inclusions. Differences in the histopathologic findings of the current case and the previous report may represent differences in duration, severity of disease, or host immune status.

The cause of death of the turtle in the current report is likely multiorgan failure due to *Ranavirus* infection. Histopathologically, this diagnosis was supported by clinical signs, gross and histologic lesions, transmission electron microscopy, virus isolation, PCR, and DNA sequencing.

Although iridoviral infections have been reported previously in reptiles and amphibians (Bollinger et al., 1999; Hyatt et al., 2002; De Voe et al., 2004), a novel feature

of the current report was the prominent inclusions seen within the cytoplasm of many leukocytes on routine blood smear examination. To the best of our knowledge, this is the first reported case of intracytoplasmic iridoviral inclusions within reptilian circulating leukocytes. Iridoviral-like inclusions in erythrocytes of reptiles and amphibians have been reported previously (Desser and Barta, 1984; Johnsrude et al., 1997), and viral leukocytic inclusions caused by other viruses have rarely been reported in reptiles (Jacobson and Telford, 1990).

The mode of transmission of reptile iridoviral infections is unknown; however, the occurrence of viral particles in circulating blood cells suggests the possibility that the virus may be transmitted via blood-feeding parasites. Transmission of iridoviruses also may occur via fomites, other forms of mechanical transmission, and ingestion of infected material (Daszak et al., 1999). Amphibian and fish reservoirs have been hypothesized (Johnson et al., 2004).

Iridoviral infections are considered a significant emerging disease of amphibian populations and may be one of multiple causes for declines among amphibian populations around the world (Daszak et al., 1999). The sources and impacts of iridoviral infections in wild reptile populations should be investigated further.

In summary, the turtle from the current report had iridoviral intracytoplasmic inclusions in circulating leukocytes, a feature not previously reported with iridoviral infection in reptiles. Definitive diagnosis requires electron microscopy, virus isolation, polymerase chain reaction with DNA sequencing, or a combination. An effective therapeutic protocol has not been identified, and affected animals should be given supportive therapy that includes fluid replacement, antibiotics to prevent secondary bacterial infections, and other appropriate measures. Iridoviral infection should be considered as an

important differential diagnosis in reptiles with clinical signs of respiratory disease and leukocytic inclusions in peripheral blood smears.

The authors thank Dee Stephenson and Nancy Hutto of the University of Tennessee histology laboratory and Jeff Horn of the Special Microscopy Laboratory at Lilly Research Laboratories. The assistance of Brian Stacy of the University of Florida with photomicrography and Val Beasley in manuscript preparation is greatly appreciated.

LITERATURE CITED

- ALTSCHUL, S. F., T. L. MADDEN, A. A. SCHÄFFER, J. ZHANG, Z. ZHANG, W. MILLER, AND D. J. LIPMAN. 1997. Gapped BLAST and PSI-BLAST: A new generation of protein database search programs. *Nucleic Acids Research* 25: 3389–3402.
- BOLLINGER, T. K., J. MAO, D. SCHOCK, R. M. BRINGHAM, AND V. G. CHINCHAR. 1999. Pathology, isolation, characterization of a novel iridovirus from tiger salamanders in Saskatchewan. *Journal of Wildlife Diseases* 35: 413–429.
- BROWN, J. D., AND J. M. SLEEMAN. 2002. Morbidity and mortality of reptiles admitted to the wildlife center of Virginia. *Journal of Wildlife Diseases* 38: 699–705.
- BROWN, M. B., I. M. SCHUMACHER, P. A. KLEIN, K. HARRIS, T. CORRELL, AND E. R. JACOBSON. 1994. *Mycoplasma agassizii* causes upper respiratory tract disease in desert tortoises. *Infectious Immunology* 62: 4580–4586.
- CAMPBELL, T. W. 1996. Hemoparasites. *In* Reptile medicine and surgery, D. Mader (ed.). W. B. Saunders, Philadelphia, Pennsylvania, pp. 379–381.
- CHEN, Z. X., J. C. ZHENG, AND Y. L. JIANG. 1999. A new iridovirus isolated from soft-shelled turtle. *Virus Research* 63: 147–151.
- DASZAK, P., L. BERGER, A. A. CUNNINGHAM, A. D. HYATT, D. E. GREEN, AND R. SPEARE. 1999. Emerging infectious diseases and amphibian population declines. *Emerging Infectious Diseases* 5: 735–748.
- DESSER, S. D., AND J. R. BARTA. 1984. An intracellular virus and rickettsial of frogs from Algonquin Park, Ontario. *Canadian Journal of Zoology* 62: 1521–1524.
- DE VOE, R., K. GEISSLER, S. ELMORE, D. ROTSTEIN, G. LEWBART, AND J. GUY. 2004. Ranavirus-associated morbidity and mortality in a group of captive eastern box turtles (*Terrapene carolina carolina*). *Journal of Zoo and Wildlife Medicine* 35: 534–543.
- HYATT, A. D., M. WILLIAMSON, B. E. H. COUPAR, D. MIDDLETON, S. G. HENGSTBERGER, A. R. GOULD, P. SELLECK, T. G. WISE, J. KATTENBELT, A. A. CUNNINGHAM, AND J. LEE. 2002. First identification of a ranavirus from green pythons (*Chondropython viridis*). *Journal of Wildlife Diseases* 38: 239–252.
- JACOBSON, E. R., AND S. R. TELFORD. 1990. Chlamydial and poxvirus infections of circulating monocytes of a flap-necked chameleon (*Chamaeleo dilepis*). *Journal of Wildlife Diseases* 26: 572–577.
- JANCOVICH, J. K., J. MAO, V. G. CHINCHAR, C. WYATT, S. T. CASE, S. KUMAR, G. VALENTE, S. SUBRAMANIAN, E. W. DAVIDSON, J. P. COLLINS, AND B. L. JACOBS. 2003. Genomic sequence of a Ranavirus (family Iridoviridae) associated with salamander mortalities in North America. *Virology* 36: 90–103.
- JOHNSON, A. J., J. F. X. WELLEHAN, A. P. PESSIER, T. NORTON, W. R. BELZER, J. W. BROOKS, R. WAGNER, N. L. STEDMAN, J. SPRATT, AND E. R. JACOBSON. 2004. Iridovirus infections of turtles and tortoises. *In* Proceedings: Health and Conservation of Captive and Free-ranging Wildlife Populations—a joint conference, American Association of Zoo Veterinarians, San Diego, California, 28 August–3 September, C. K. Baer (ed.), pp. 11–12.
- JOHNSRUDE, J. D., R. E. RASKIN, A. Y. A. HOGE, AND G. W. ERDOS. 1997. Intraerythrocytic inclusions associated with iridoviral infection in a Fer de Lance (*Bothrops moojeni*) snake. *Veterinary Pathology* 34: 235–238.
- JUST, F., S. ESSBAUER, W. AHNE, AND S. BLAHAK. 2001. Occurrence of an invertebrate iridescent-like virus (Iridoviridae) in reptiles. *Journal of Veterinary Medicine B, Infectious Diseases and Veterinary Public Health* 48: 685–694.
- MAO, J., R. P. HEDRICK, AND V. G. CHINCHAR. 1997. Molecular characterization, sequence analysis, and taxonomic position of newly isolated fish iridoviruses. *Virology* 229: 212–220.
- MARSCHANG, R. E., P. BECHER, H. POSTHAUS, P. WILD, H.-J. THIEL, U. MULLER-DOBLIES, E. F. KALETA, AND L. N. BACCIARINI. 1999. Isolation and characterization of an iridovirus from Hermann's tortoise (*Testudo hermannii*). *Archives of Virology* 144: 1909–1922.
- MURRAY, M. J. 1996. Pneumonia and normal respiratory function. *In* Reptile medicine and surgery, D. Mader (ed.). W. B. Saunders, Philadelphia, Pennsylvania, pp. 396–405.
- ORIGGI, F. C., C. H. ROMERO, D. C. BLOOM, P. A. KLEIN, J. M. GASKIN, S. J. TUCKER, AND E. R. JACOBSON. 2004. Experimental transmission of a Herpesvirus in Greek tortoises (*Testudo graeca*). *Veterinary Pathology* 41: 50–61.
- SCHUMACHER, J. 1996. Viral diseases. *In* Reptile medicine and surgery, D. Mader (ed.). W. B.

Saunders, Philadelphia, Pennsylvania, pp. 224–234.

WESTHOUSE, R. A., E. R. JACOBSON, R. K. HARRIS, K. R. WINTER, AND B. L. HOMER. 1996. Respiratory and pharyngo-esophageal iridovirus infection in

a gopher tortoise (*Gopherus polyphemus*). *Journal of Wildlife Diseases* 32: 682–686.

Received for publication 27 April 2005.