



## **HOOKWORM ENTERITIS WITH BACTEREMIA IN CALIFORNIA SEA LION PUPS ON SAN MIGUEL ISLAND**

Authors: Spraker, Terry R., DeLong, Robert L., Lyons, Eugene T., and Melin, Sharon R.

Source: Journal of Wildlife Diseases, 43(2) : 179-188

Published By: Wildlife Disease Association

URL: <https://doi.org/10.7589/0090-3558-43.2.179>

---

BioOne Complete ([complete.BioOne.org](https://complete.BioOne.org)) is a full-text database of 200 subscribed and open-access titles in the biological, ecological, and environmental sciences published by nonprofit societies, associations, museums, institutions, and presses.

Your use of this PDF, the BioOne Complete website, and all posted and associated content indicates your acceptance of BioOne's Terms of Use, available at [www.bioone.org/terms-of-use](https://www.bioone.org/terms-of-use).

Usage of BioOne Complete content is strictly limited to personal, educational, and non - commercial use. Commercial inquiries or rights and permissions requests should be directed to the individual publisher as copyright holder.

---

BioOne sees sustainable scholarly publishing as an inherently collaborative enterprise connecting authors, nonprofit publishers, academic institutions, research libraries, and research funders in the common goal of maximizing access to critical research.

# HOOKWORM ENTERITIS WITH BACTEREMIA IN CALIFORNIA SEA LION PUPS ON SAN MIGUEL ISLAND

Terry R. Spraker,<sup>1,4</sup> Robert L. DeLong,<sup>2</sup> Eugene T. Lyons,<sup>3</sup> and Sharon R. Melin<sup>2</sup>

<sup>1</sup> Department of Microbiology, Immunology and Pathology, College of Veterinary Medicine and Biomedical Sciences, Colorado State University, Fort Collins, Colorado 80526, USA

<sup>2</sup> National Marine Mammal Laboratory, Alaska Fisheries Science Center, National Marine Fisheries Service, NOAA, 7600 Sand Point Way NE, Seattle, Washington 98115, USA

<sup>3</sup> Department of Veterinary Science, Gluck Equine Research Center, University of Kentucky, Lexington, Kentucky 40546, USA

<sup>4</sup> Corresponding author (email: terry.spraker@colostate.edu)

**ABSTRACT:** Large breeding populations of California sea lions (*Zalophus californianus*) are located on San Miguel and San Nicolas Islands in the Southern California Bight. In 2001, there was a substantial increase in pup mortality in late summer and fall. From June 2002 to January 2003, 208 freshly dead pups were examined on San Miguel Island, the most western of the Channel Islands off the coast of southern California. Tissues from 186 of these pups were examined histologically. The primary lesions in 133 (72%) of the pups were an enteritis associated with hookworms and infections in major organs. Emaciation/starvation in 43 pups (26%) was the second most important cause of death.

**Key words:** Bacteremia, California sea lions, emaciation, enteritis, hookworms, *Uncinaria* spp., *Zalophus californianus*.

## INTRODUCTION

The California sea lion (*Zalophus californianus*) population in US waters has increased by about 5% annually over the past 30 yr with current numbers in excess of 250,000 animals. Large breeding populations of California sea lions are on San Miguel and San Nicolas islands and smaller breeding populations on Santa Barbara and San Clemente islands in the Southern California Bight. Until 2000, most of the pup mortality occurred in the first 2 mo after birth. Pup mortality through the end of July has averaged 23% per year over the past 15 yr excluding El Niño years (DeLong, unpubl. data). In 2001, a substantial increase in pup mortality occurred as late as October when pups were 4 mo of age (DeLong, unpubl. data). In 2002, an investigation was initiated to delineate the causes of mortality by conducting necropsies on freshly dead pups. This article describes a heretofore unreported condition called hookworm enteritis/bacteremia complex that was responsible for the majority of mortality of these pups. This article also contains comments on other conditions

that contributed minimally to the overall mortality.

## MATERIALS AND METHODS

Seven trips of 5- to 7-day duration were made to San Miguel Island (34.03°N, 120.44°W) off the coast of southern California within the Channel Islands National Park; trips were made in June, July, August, October, November, and December 2002 and in January 2003. Each morning freshly dead, moribund, and dying pups were collected from the rookeries and carried to a small outdoor laboratory. Pups from which cultures were taken were classified as code 1 (Geraci and Lounsbury, 1993); all other carcasses were classified as early code 2. Pups from which blood cultures were taken had an average postmortem interval of less than 5 min, and pups in which systemic cultures were taken had an estimated postmortem interval of less than 30 min. Postmortem intervals were known because these pups were picked up moribund and died during the hike back to the necropsy laboratory or were found dying on the rookery.

All pups were weighed and axial girth, standard length, and sternal blubber thickness were measured. Pups with a sternal blubber thickness of  $\geq 5$  mm were considered to be in good body condition and pups with less were considered to be in poor body condition (DeLong and Spraker, pers. obs.). Selected

tissues were collected and preserved in 10% neutral buffered formalin, and then they were embedded in paraffin, sectioned at 5  $\mu$ m, stained with hematoxylin and eosin, and examined under light microscopy.

Hookworms were collected from the intestines of all pups to assess the prevalence and intensity of infections in individual animals (Lyons et al., 2005). The hookworms were identified as *Uncinaria* spp. according to characteristics published in keys to genera of nematodes by Lichtenfels (1980). Representative adult specimens of *Uncinaria* spp. (USNPC nos. 094029.00, 094030.00, and 094031.00) from *Z. californianus* pups were deposited in the US National Parasite Collection (USNPC, Agricultural Research Service, US Department of Agriculture, Beltsville, Maryland, USA).

Swabs for bacterial culture were collected from selected tissues and lesions during necropsies conducted on five of the seven trips. Cultures were not taken on the trips in July and November. Two to eight pups were cultured per trip, and one to three swabs were taken per pup. Swabs were only taken from extremely fresh pups still in rigor or pups that died during the 10- to 20-min hike back to the necropsy station. Solid tissues were cultured by first cutting the organ with a sterile blade, and then swabs were taken on the cut surface. Intestines were cultured by cutting the wall open with a sterile blade and inserting a swab into the lumen. Swabs were placed in transport media (BBL culturettes [BBL Microbiology, BD Biosciences, Cockeysville, Maryland, USA] and Port-A-Culs [BioQuest, BD Biosciences]) and kept cool in a refrigerator until transported to the laboratory in a cooler. Tissues cultured included intestine, peritoneal, and thoracic cavities; brain; eyes; lung; liver; joints; and blood. Blood was cultured by collecting 5 cc of peripheral blood from the caudal gluteal vein from four moribund pups. Bacterial cultures were done at veterinary diagnostic laboratories (Veterinary Teaching Hospital, University of California, Davis, California, USA, and Colorado State University, Fort Collins, Colorado, USA).

## RESULTS

Two hundred eight dead or dying pups were collected from rookeries on San Miguel Island and examined at necropsy. There were 101 males, 100 females, and seven pups whose sex was not recorded. The body condition was good in 151 pups

(75 males, 71 females, and five of unknown sex) and poor in 57 animals (26 males, 29 females, and two of unknown sex) (Fig. 1).

On gross examination, pups were originally placed in five broad categories of cause of death: multifocal hemorrhagic enteritis (hookworms) with systemic infections, emaciation/starvation, bite wounds with infections/cellulitis, miscellaneous causes, and no gross lesions (Table 1). These pups also had a variety of other gross lesions detailed in Table 1.

Histologic examination of tissues from 186 pups confirmed the gross lesions but also added many other lesions and eliminated the cases in which no gross lesions were found. After histopathologic examination, the original five general categories of causes of death were reduced to three: hookworm enteritis/bacteremia complex, emaciation/starvation, and miscellaneous conditions. Two necropsy categories, bite wounds/cellulitis and no gross lesions, could be eliminated because histologic lesions placed pups in one of the other three categories. This elimination demonstrates the importance of doing histopathologic examination of tissues and not relying solely on gross examinations. The hookworm enteritis/bacteremia complex category is described herein with minimal comments on the latter two categories (emaciation/starvation and miscellaneous causes).

### Hookworm enteritis/bacteremia complex

Hookworm enteritis with evidence of bacteremia was found in 133 of the 186 pups. The primary gross lesions associated with this condition were a hookworm infection and multiple systemic organ infections including peritonitis, polyarthritis, pleuritis, multifocal hepatitis, and hematogenous pneumonia.

The most common and consistent gross lesion was multifocal 2–4 mm circular red foci located under the serosa of the small and large intestines; associated with these foci of hemorrhage were small 2–4 mm

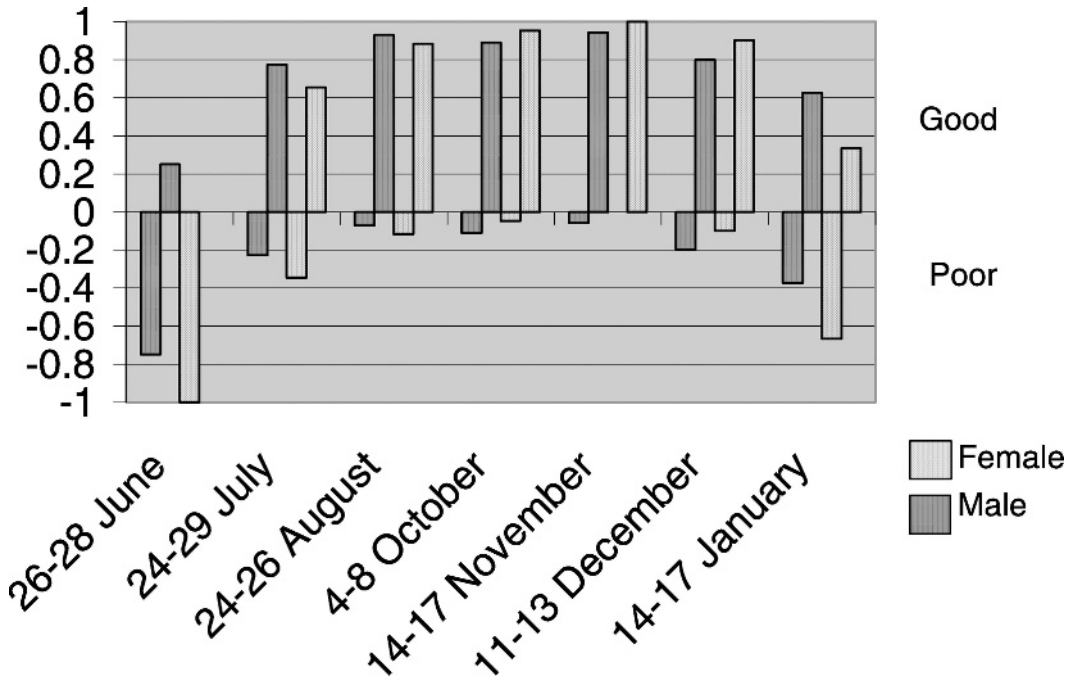


FIGURE 1. Comparison of body condition and sex in 201 male and female California sea lion pups examined postmortem during seven trips to San Miguel Island from June 2002 through January 2003. The y-axis is the percentage of male and female pups that were placed in either good condition (positive numbers) or poor condition (negative numbers). The majority of pups found dead in June were emaciated, but pups found dead from July to December (highest rate of hookworm enteritis) were in good body condition.

firm nodules. The majority of lesions were located in the mid small intestine; however, a few also were present in the large intestine.

These red foci were hookworm feeding sites characterized by tracks through the mucosa and inflammation in the submucosa (Fig. 2). It was common to find feeding tracks that penetrated deep into the submucosa and some even into the muscular wall of the intestines. Feeding sites contained varying degrees of hemorrhage and edema with a mild-to-moderate infiltration of neutrophils, lymphocytes, eosinophils, and plasma cells. Usually, little inflammation was present within the muscular layers; however, inflammation both within and between the muscle layers and under the serosa associated with small focal areas of peritonitis was found in several cases.

Hookworms were found deep within

the submucosa and muscular layers of the small intestine (Fig. 3). Inflammation surrounded the hookworms within the submucosa and often extended down and into the serosa. In about half of the sections of parasites within the submucosa, the internal structures of the parasites were disorganized and not intact, suggesting that the parasites were dead; viable parasites had intact and well-defined internal structures. Both dead and viable parasites were often coated with bacteria on the surface of their cuticle. In two cases, hookworms penetrated through the wall of the small intestine and were located on the surface of the intestine or within the peritoneal cavity (Spraker et al., 2004).

In most cases, the lymphoid follicles of the Peyer's patches had undergone hyperplasia, but they were now depleted. Microabscesses were found in Peyer's

TABLE 1. Summary of gross lesions observed during postmortem examination of 208 California sea lion pups from June 2002 to January 2003, San Miguel Island, California.

Gross lesions	Trip no.						
	1	2	3	4	5	6	7
No. pups examined	30	50	31	31	30	25	11
Emaciation/starvation <sup>a</sup>	14	3	0	0	0	2	5
<u>c</u> <sup>b</sup> blunt trauma	5	6	1	0	0	0	0
<u>c</u> infection	4	0	0	0	0	0	0
<u>c</u> pulmonary edema	1	0	0	0	0	0	0
<u>c</u> enteritis	1	0	0	0	0	1	0
Enteritis <sup>a</sup>	1	12	8	12	26	14	1
<u>c</u> pyothorax	0	0	2	1	0	0	0
<u>c</u> anemia	0	0	15	8	2	1	0
<u>c</u> encephalitis	0	0	0	1	0	3	0
<u>c</u> pneumonia	0	0	0	0	0	0	1
<u>c</u> peritonitis	2	0	0	1	0	0	0
<u>c</u> blunt trauma	1	1	0	0	0	1	0
<u>c</u> bite wounds	0	0	0	0	0	1	0
Bite wounds <sup>a</sup>	1	11	2	0	0	1	0
Miscellaneous lesions <sup>a</sup>							
abscess/infections	0	1	0	0	0	0	0
blunt trauma	0	2	0	0	0	0	0
brain swelling	0	0	1	1	0	0	2
brain tumor	0	0	0	0	0	0	1
hydronephrosis	0	1	0	0	0	0	0
peritonitis	0	0	0	1	0	0	0
peritonitis/pleuritis	0	1	0	0	0	0	0
petechia of stomach	0	1	0	0	0	0	0
pneumonia	0	1	0	0	1	0	0
pulmonary edema	0	5	1	0	1	1	0
pyothorax	0	1	0	0	0	0	0
advanced autolysis	0	0	0	0	0	0	1
No gross lesions <sup>a</sup>	0	4	1	6	0	0	0

<sup>a</sup> Five major mortality categories based on necropsy findings. Numbers indicate number of animals in category without additional conditions.

<sup>b</sup> c is number of animals with the major condition above and the additional condition listed.

patches of the distal jejunum and ileum in a few pups. Evidence of peritonitis was found histologically in 29 of the 133 pups.

On gross examination, the lungs were collapsed and dark maroon. Mild edema was seen in bronchi and bronchioles in most pups. Edema and fibrin was found in alveoli of the lung. Pneumonia was found on gross examination in one pup with hookworm enteritis, but an additional nine cases were found after histologic examination. Bacteria were seen in alveolar spaces, small vessels, and capillaries. In four cases, multifocal areas of necrosis

were found scattered throughout the pulmonary parenchyma. Pyothorax with no evidence of pneumonia was found in three pups.

The mesenteric and axillary lymph nodes were enlarged in nearly all pups. A spectrum of lesions was found histologically and ranged from severe follicular and parafollicular lymphoid hyperplasia to total depletion. This spectrum of proliferation and depletion of lymphoid tissue also was observed in the spleen. Extramedullary hematopoiesis was present within the red pulp of the spleen in most



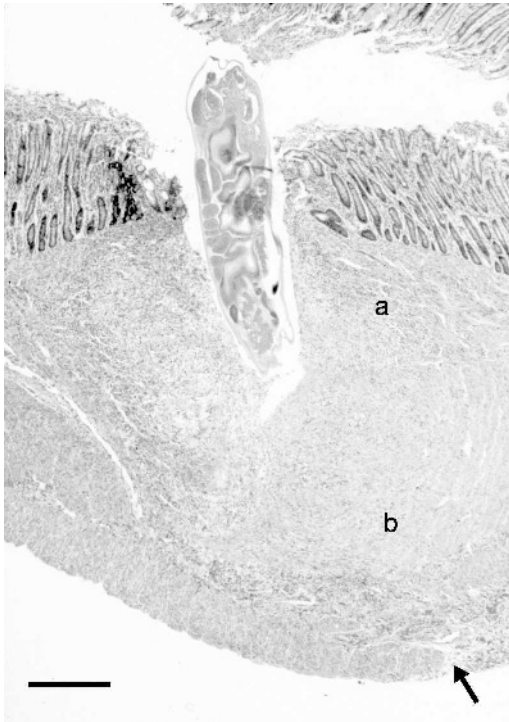


FIGURE 2. Photomicrograph of a hookworm feeding site in the mucosa of the jejunum. Note the longitudinal section of a feeding hookworm that has penetrated deep into the muscular wall. Inflammation surrounds the hookworm in the submucosa (a) and adjacent muscular wall (b). A small focus of peritonitis is present in the serosa (arrow). Bar=300  $\mu$ m.

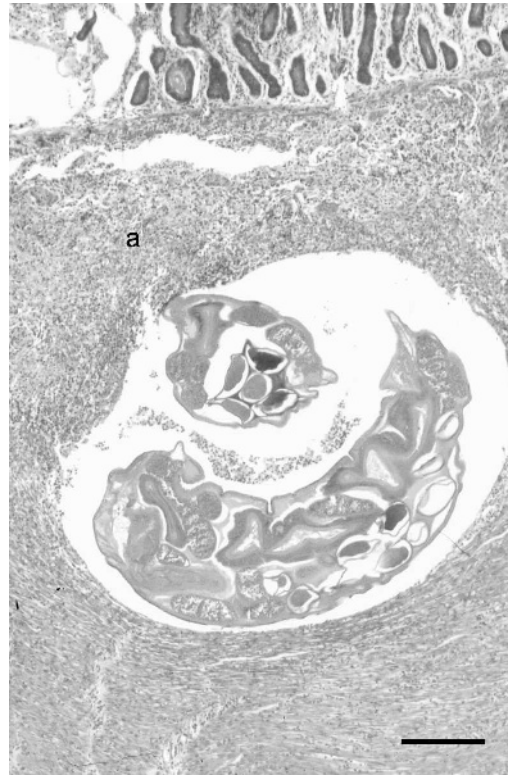


FIGURE 3. Photomicrograph of a hookworm located deep within the submucosa. Minimal inflammation is present in the mucosa, but extensive inflammation is located within the submucosa surrounding the hookworm (a). Bar=250  $\mu$ m.

animals, but it was especially prominent in the anemic animals. Thymic atrophy was found in nearly all of the pups.

Twenty-six of the 133 pups had gross evidence of anemia (pale, mottled internal organs and thin blood); packed cell volumes were not measured on any of the pups. Histologically, 19 of these 26 pups also had mild-to-moderate central lobular fatty degeneration of the liver. Mild-to-moderate multifocal hepatitis was found in 54 pups, suggesting antemortem bacteremia.

On gross examination, five pups with hookworm enteritis had severe swelling of the brain. However, inflammation of the brain was found histologically in 42 pups: meningitis ( $n=9$ ), encephalitis ( $n=13$ ),

and meningoencephalitis ( $n=20$ ). Multifocal areas of necrosis were commonly found in the thalamus. Bacteria often were seen in small cerebral vessels and occasionally in septic thrombi.

Suppurative arthritis was found in eight pups. Affected joints included atlanto-occipital ( $n=4$ ), scapulo-humeral ( $n=2$ ), humero-radial ( $n=1$ ), and carpal/tarsal joints ( $n=1$ ). Incidental lesions found in pups with hookworm enteritis included multifocal necrosis of the heart ( $n=5$ ), adrenal glands ( $n=4$ ), thyroid glands ( $n=2$ ), kidneys ( $n=2$ ), and tongue ( $n=1$ ). Anterior uveitis ( $n=4$ ), panophthalmitis ( $n=1$ ), suppurative myelitis ( $n=1$ ), splenitis ( $n=1$ ), and pyelonephritis ( $n=1$ ) also were found.

TABLE 2. Bacteria isolated and location of isolation from 37 California sea lion pups with hookworm enteritis/bacteremia complex.

Bacteria isolated	Location <sup>a</sup>												
	SI	BR	BL	LN	TC	PC	LU	EY	LI	ST	SP	AB	JO
<i>K. pneumoniae</i>	7	8	4	3	2	3	3	2	0	1	1	2	1
<i>Klebsiella ozaenae</i>	1	2	0	0	0	0	0	1	0	0	0	1	0
<i>Salmonella</i> spp. <sup>b</sup>	9	0	0	1	0	1	0	0	0	0	0	0	0
nh <sup>c</sup> <i>E. coli</i>	17	5	0	0	0	0	1	0	0	0	0	0	0
h <sup>d</sup> <i>E. coli</i>	7	1	0	0	0	0	0	0	0	0	0	0	0
<i>Clostridium perfringens</i>	2	0	0	1	0	1	0	0	1	0	0	0	0
<i>Vibrio</i> spp.	3	0	0	0	0	0	1	0	0	0	0	1	0
<i>Streptococcus</i> spp.	0	2	0	0	0	0	1	0	0	0	0	1	0
<i>Moraxella</i> spp.	1	1	0	0	0	0	1	0	1	1	0	0	0

<sup>a</sup> SI=small intestine, BR=brain, BL=blood, LN=mesenteric lymph nodes, TC=thoracic cavity, PC=peritoneal cavity, LU=lung, EY=eye, LI=liver, ST=stomach, SP=spleen, AB=abscess, JO=joints.

<sup>b</sup> *Salmonella* groups B and C2.

<sup>c</sup> Nonhemolytic.

<sup>d</sup> Hemolytic.

Numerous bacteria were isolated from multiple organs, including the small intestine, mesenteric lymph nodes, liver, lung, brain, thoracic cavity, eye, stomach, spleen, abscess, peritoneal cavity, joints, and blood (Table 2). Bacteria isolated that were considered significant included *Klebsiella* spp. (42 sites), *Salmonella* spp. (11 sites), and hemolytic *Escherichia coli* (eight sites). *Klebsiella pneumoniae* was most commonly isolated from the small intestine, brain, eyes, and blood.

#### Emaciation/starvation

Emaciation/starvation was considered the primary cause of death in 48 pups. The primary gross lesions included moderate-to-severe emaciation, total absence of adipose tissue, thymic atrophy, and a small dark liver. The stomach and intestinal tract were empty except for the presence of bile. Histologically, the primary lesions included atrophy of parenchyma cells, especially hepatocytes, myocytes, pancreas, and myocardial cells. Lipid was absent in lipocytes.

#### Miscellaneous causes of death

Of the 50 pups placed in the bite wounds, miscellaneous, and no gross

lesions categories on gross examination, all but five pups were placed in the hookworm enteritis/bacteremia complex category after histopathologic examination. Causes of death in these five pups included one 8-mo-old pup with a neuroblastoma multiformes of the brain (primarily located within the thalamus), one pup with severe blunt trauma, two pups with acute massive bite wounds to the neck and chest, and one pup born premature.

#### DISCUSSION

The hookworm enteritis with secondary bacteremia observed in this investigation of California sea lion pups is unusual compared with past literature on *Uncinaria* spp. in pinnipeds. Hookworms (*Uncinaria lucasi*) in marine mammals were first documented in northern fur seals (*Callorhinus ursinus*) on the Pribilof Islands of Alaska in 1897 (Lucas, 1899). The life cycle was elucidated 60 yr later (Lyons, 1963; Olsen and Lyons, 1965). The clinical picture described was enteritis with anemia in well-nourished pups (Lyons 1963; Olsen and Lyons, 1965; Keyes, 1965). Bacteremia (manifested by

infections of systemic organs and peritonitis) was not noted in any of the reports.

Early reports of *Uncinaria* spp. (*Uncinaria hamiltoni*) in California sea lions were published by Fiennes (1966) and Dailey and Hill (1970). The life cycle is not known, but all available data suggest that it is similar to northern fur seals in which transmammary transmission has been demonstrated (Fiennes, 1966; Dailey and Hill, 1970; Lyons et al., 1997, 2000, 2001, 2003, 2005). Reference to hookworms perforating the intestinal wall and bacteremia was not found in any of this literature.

Major lesions found in pups in this study were a combination of hookworm enteritis with bacteremia, which resulted in infections in multiple organs and cavities. Bacteremia was most likely secondary to the damage caused by the deep penetration and transmural intestinal migration of hookworms that had bacteria adhered to the cuticle. Thus, the term hookworm enteritis/bacteremia complex was coined for this condition in California sea lions because of differences of this condition compared with that originally described for *Uncinaria* infections.

Taxonomy of *Uncinaria* spp. in pinnipeds is inconclusive at this time. Two species have been described, *U. lucasi* and *U. hamiltoni* (Dailey and Hill, 1970). However, Dailey and Hill (1970) have reported intermediate types of *Uncinaria* from California sea lions and molecular and morphometric differences between hookworms (*Uncinaria* spp.) in northern fur seals and California sea lions on San Miguel Island. Identification of the species of *Uncinaria* in California sea lions in the present study is uncertain and the behavior of these hookworms is unorthodox (transmural migration through the intestinal wall with bacteremia). It was not possible to compare the hookworms found in the California sea lions in the late 1960s and 1970s with the hookworms found in this investigation.

The intensity of hookworm infection in

these pups was low (mean 94 worms;  $n=30$  pups) in June 2002 and was highest in July (mean 629 worms;  $n=50$ ), but then decreased throughout the rest of the year (reported in Lyons et al. [2005]). Mean counts were 320 ( $n=31$ ) in August, 160 ( $n=30$ ) in October, 109 ( $n=30$ ) in November, 38 ( $n=30$ ) in December, and 11 ( $n=9$ ) in January 2003 (reported in Lyons et al. [2005]). The mortality of pups peaked in July–September, and then mortality started to decline (DeLong, unpubl. data). After histologic examination, the primary distinction that could be found in pups that had high hookworm infections (i.e., pups examined in July to pups with lower hookworm infections examined in October through January) was the degree of enteritis and the number of cross sections of hookworms found in the intestinal tract. The numbers of cross sections of worms were not counted, but the overall impression was that the worms were more prevalent in July and August compared with later months.

The importance of hookworm enteritis/bacteremia complex as a cause of sea lion mortality seems to be a relatively recent event (DeLong, unpubl. data). Hookworm enteritis/bacteremia complex in California sea lions may be an example of a density-dependent disease. Over the past 30 yr, the California sea lion population has increased about 5% annually with about 100,000 sea lions on San Miguel Island. The life cycle of *Uncinaria* spp. and their infectivity are probably sensitive to sea lion abundance and density. The prevalence of hookworms in dead pups in this study was 100%, as reported by Lyons et al. (2005), and prevalence was high in live pups in this population in summer 2000 (Lyons et al., 2001). With high-prevalence and high-intensity infections, the greater the number of pups, the greater the number of eggs passed in the feces, resulting in large numbers of infective third-stage larvae in the sandy substrate. Consequently, juveniles and adults have



higher body burdens of parasitic third-stage larvae in the ventral abdominal blubber, which are passed in increasing numbers to pups through the milk of females. This process, in turn, increases the intensity of infection of adult hookworms in pups and apparently increases the probability of mortality.

High density of animals on the rookery also would lead to higher fecal contamination of the sandy beaches, which could increase the number of pathogenic bacteria in the environment. Pups commonly swallow sand that gets into their mouth, thereby resulting in a continual high exposure to numerous species of bacteria. The hookworm feeding sites in the small intestinal wall apparently allow invasion of the blood by enteric bacteria, resulting in bacteremia.

A relatively small population of northern fur seals competes for rookery space with the California sea lions on San Miguel Island during pupping and breeding seasons. Northern fur seals at San Miguel Island also have *Uncinaria* spp. (Lyons et al., 1997, 2000, 2001). The *Uncinaria* spp. of the northern fur seals possibly could infect California sea lions, and infection of an abnormal host may explain the unusually deep penetration into the submucosa and muscular layers by the worms with some worms penetrating into the peritoneal cavity (Spraker et al., 2004). Infection of an abnormal host also may explain the presence of dead worms in the deep muscular layers and the cases of hookworm-associated bacteremia, which have not been observed in other hosts. Moreover, the hookworm infection in these pups may be a combination of the *Uncinaria* spp. of California sea lions and northern fur seals; this aberrant relationship may explain why bacteremia can be associated with relatively low hookworm counts. However, based on molecular and morphometric data of a few hookworms, differences were found in *Uncinaria* spp. collected from the intestines of California sea lion and

northern fur seal pups on San Miguel Island (Nadler et al., 2000).

Pups dying from emaciation/starvation were found primarily in June when they were less than 2 wk of age and in December when they were 6–7 mo of age. The overall number of pups with this condition was considered to be within normal limits for this population of California sea lions (DeLong, unpubl. data). The primary cause of emaciation/starvation was thought to be due to lack of maternal care.

Five pups were placed in the miscellaneous category. One of these pups had a neuroblastoma multiformes in the thalamus of the brain. Tumors are rare in marine mammals, but there has been 93 reported with 15 recorded in California sea lions (Gulland et al., 2001). The neuroblastoma multiformes in this 8-month pup is the first neural tumor reported in California sea lions. The finding of this tumor was considered an interesting finding of undetermined etiology, but it did not have any significance in the overall mortality of pups. This was the first case of neoplasia found in a pup (less than 1 yr of age) in 500–600 pups examined at necropsy on San Miguel Island since 1990 (DeLong and Spraker, unpubl. data).

The cause of death in three of the five pups was related to trauma. Numerous types of trauma have been reported in marine mammals, especially pinnipeds (Gulland et al., 2001). The number of deaths in this study due to intraspecific and interspecific trauma was considered extremely low, even though the rookeries were crowded.

The fifth pup was a premature birth found in January 2003. The cause of this premature birth was not investigated; however, premature births associated with high organochlorine residue levels have been reported in California sea lions (DeLong, 1973).

Cause (agents) and effect (disease) are difficult to determine in many field studies investigating causes of mortality in popu-

lations. In this situation, two probably equally important and pathogenic etiologic agents were consistently found in otherwise large, well-fed pups that were found dead. The two agents were hookworms (*Uncinaria* sp.) and bacteria (*Klebsiella* spp., *Salmonella* spp., and hemolytic *E. coli*), and it is speculated that both components (hookworms and bacteria) played a role in this condition called hookworm enteritis/bacteremia complex. Although no “control pups” (pups without hookworms) were examined in this study, healthy pups on San Miguel Island have been cultured in the past and similar bacteria, including *Klebsiella* spp., *Salmonella* spp., and hemolytic *E. coli* have been isolated (Gilmartin et al., 1979; Spraker, unpubl. data [1990–1992]). These organisms also have been isolated from stranded California sea lions from the California coast (Thornton et al., 1998). Likewise, healthy-looking California sea lion pups have been found infected with hookworms (Lyons et al., 2001). Therefore, the disease in this report that was associated with high pup mortality was likely caused by the combination of infections with hookworms and several species of bacteria. The bacteria were allowed to invade systemic tissues via the gut wall damaged by the hookworms, even in pups with relatively low hookworm counts as seen in the winter (Lyons et al., 2005). There is the possibility that either of these two agents (hookworms and bacteria) could kill a pup alone, but the gross and histologic examinations of these pups did not suggest this scenario, but rather synergism of the two agents.

#### ACKNOWLEDGMENTS

We would like to thank Anthony Orr, Karina Acevedo-Whitehouse, Lisa Bowen and Karim Soto for collection of dead pups and carrying them to the necropsy area and Melissa Schutten, Brian Aldridge, Christie McKnight, and Frances Gulland for aiding in gross necropsies. Appreciation is expressed to Rebecca Sorg for trimming the tissues and Robert and Debbie Zink for embedding,

cutting, and staining the tissue sections. Gratitude is extended to Sharon Tolliver and Frances Gulland for editorial suggestions. This project was supported by the National Marine Mammal Laboratory, Seattle, WA, USA and was conducted under the Marine Mammal Protection Act Permit No. 782-1613, issued to the National Marine Mammal Laboratory, Seattle, WA, USA.

#### LITERATURE CITED

- DAILEY, M. D., AND B. L. HILL. 1970. A survey of metazoan parasites infecting the California (*Zalophus californianus*) and Steller (*Eumetopias jubatus*) sea lion. Bulletin of the Southern California Academy of Science 69: 126–132.
- DELONG, R. L. 1973. Premature births in California sea lions associated with high organochlorine pollutant residue levels. Science 181: 1168–1170.
- FIENNES, R. N. T. 1966. The Zoological Society of London. Report of the Society's Pathologist for the year 1963. Journal of Zoology 148: 341–362.
- GERACI, J. R., AND V. J. LOUNSBURY. 1993. Specimen and data collection. In Marine mammals ashore: A field guild for strandings, J. R. Geraci and V. J. Lounsbury (eds.). Texas A&M Sea Grant Program, Galveston, Texas, pp. 175–228.
- GILMARTIN, W. G., P. M. VAINIK, AND V. M. NEIL. 1979. Salmonellae in feral pinnipeds off the Southern California coast. Journal of Wildlife Diseases 15: 511–515.
- GULLAND, F. M. D., L. J. LOWENSTINE, AND T. R. SPRAKER. 2001. Noninfectious diseases. In CRC handbook of marine mammal medicine. 2nd Edition, L. A. Dierauf and F. M. D. Gulland (eds.). CRC Press, New York, New York, pp. 521–547.
- KEYES, M. C. 1965. Pathology of the northern fur seal. Journal of the Veterinary Medical Association 147: 1090–1095.
- LICHTENFELS, J. R. 1980. No. 8. Keys to genera of the superfamilies Ancylostomatoidea and Diaphanoccephaloidea. In CIH keys to the nematode parasites of vertebrates, R. C. Anderson, A. G. Chabaud and S. Willmott (eds.). CAB International, Wallingford, UK, pp. 1–41.
- LUCAS, F. A. 1899. The causes of mortality among seals. In The fur seals and fur seal islands of the North Pacific Ocean. Part 3, D. S. Jordan (ed.). US Government Printing Office, Washington, D.C., pp. 75–98.
- LYONS, E. T. 1963. Biology of the hookworm, *Uncinaria lucasi* Stiles, 1901, in the northern fur seal, *Callorhinus ursinus* Linn, on the Pribilof Islands, Alaska. PhD Dissertation, Colorado State University, Fort Collins, Colorado, 97 pp.
- , R. L. DELONG, S. R. MELIN, AND S. C.

- TOLLIVER. 1997. Uncinariasis in northern fur seals and California sea lion pups from California. *Journal of Wildlife Diseases* 33: 848–852.
- , T. R. SPRAKER, K. D. OLSON, S. C. TOLLIVER, AND H. D. BAIR. 2000. Prevalence of hookworms (*Uncinaria lucasi*, Stiles) in northern fur seals (*Callorhinus ursinus* Linnaeus) pups on St. Paul Island, Alaska, USA. *Comparative Parasitology* 67: 218–223.
- , S. R. MELIN, R. L. DELONG, A. J. ORR, F. M. GULLAND, AND S. C. TOLLIVER. 2001. Current prevalence of adult *Uncinaria* spp. in northern fur seal (*Callorhinus ursinus*) and California sea lion (*Zalophus californianus*) pups on San Miguel Island, California, with notes on the biology of these hookworms. *Veterinary Parasitology* 97: 309–318.
- , R. L. DELONG, T. R. SPRAKER, S. R. MELIN, AND S. C. TOLLIVER. 2003. Observations in 2001 on hookworms (*Uncinaria* spp.) in otariid pinnipeds. *Parasitology Research* 89: 503–505.
- , ———, ———, ———, J. L. LAAKE, AND S. C. TOLLIVER. 2005. Seasonal prevalence and intensity of hookworms (*Uncinaria* spp.) in California sea lion (*Zalophus californianus*) pups born in 2002 on San Miguel Island, California. *Parasitology Research* 96: 127–132.
- NADLER, S. A., B. J. ADAMS, E. T. LYONS, R. L. DELONG, AND S. R. MELIN. 2000. Molecular and morphometric evidence for separate species of *Uncinaria* (Nematoda: Ancylostomatidae) in California sea lions (*Zalophus californianus*) and northern fur seals (*Callorhinus ursinus*). *Journal of Parasitology* 86: 1099–1106.
- OLSEN, O. W., AND E. T. LYONS. 1965. Life cycle of *Uncinaria lucasi* Stiles, 1901 (Nematoda: Ancylostomatidae) of fur seals, *Callorhinus ursinus* Linn., on the Pribilof Islands, Alaska. *Journal of Parasitology* 51: 689–700.
- SPRAKER, T. R., E. T. LYONS, R. L. DELONG, AND R. R. ZINC. 2004. Penetration of the small intestine of a California sea lion (*Zalophus californianus*) pup by adult hookworms (*Uncinaria* spp.). *Parasitology Research* 92: 436–438.
- THORNTON, S. M., S. NOLAN, AND F. M. D. GULLAND. 1998. Bacterial isolates from California sea lions (*Zalophus californianus*), harbor seals (*Phoca vitulina*), and northern elephant seals (*Mirounga angustirostris*) admitted to a rehabilitation center along the central California coast, 1994–1995. *Journal of Zoo and Wildlife Medicine* 29: 171–176.

Received for publication 7 October 2005.