



## **Notoedric Mange in Two Free-ranging Mountain Lions (Puma concolor)**

Authors: Uzal, Francisco A., Houston, Robin S., Riley, Seth P. D., Poppenga, Robert, Odani, Jenee, et al.

Source: Journal of Wildlife Diseases, 43(2) : 274-278

Published By: Wildlife Disease Association

URL: <https://doi.org/10.7589/0090-3558-43.2.274>

---

BioOne Complete ([complete.BioOne.org](https://complete.BioOne.org)) is a full-text database of 200 subscribed and open-access titles in the biological, ecological, and environmental sciences published by nonprofit societies, associations, museums, institutions, and presses.

Your use of this PDF, the BioOne Complete website, and all posted and associated content indicates your acceptance of BioOne's Terms of Use, available at [www.bioone.org/terms-of-use](https://www.bioone.org/terms-of-use).

Usage of BioOne Complete content is strictly limited to personal, educational, and non - commercial use. Commercial inquiries or rights and permissions requests should be directed to the individual publisher as copyright holder.

---

BioOne sees sustainable scholarly publishing as an inherently collaborative enterprise connecting authors, nonprofit publishers, academic institutions, research libraries, and research funders in the common goal of maximizing access to critical research.

## Notoedric Mange in Two Free-ranging Mountain Lions (*Puma concolor*)

Francisco A. Uzal,<sup>1,6</sup> Robin S. Houston,<sup>2</sup> Seth P. D. Riley,<sup>3</sup> Robert Poppenga,<sup>4</sup> Jenee Odani,<sup>1</sup> and Walter Boyce<sup>5</sup> <sup>1</sup> California Animal Health and Food Safety, San Bernardino Branch, School of Veterinary Medicine, University of California, Davis, California 92408, USA; <sup>2</sup> Veterinary Medical Teaching Hospital, School of Veterinary Medicine, University of California, Davis, California 95616, USA; <sup>3</sup> National Park Service, Santa Monica Mountains National Recreation Area, Thousand Oaks, California 91360, USA; <sup>4</sup> California Animal Health and Food Safety Laboratory, Davis Branch, School of Veterinary Medicine, University of California, Davis, California 95616, USA; <sup>5</sup> Wildlife Health Center, School of Veterinary Medicine, University of California, Davis, California 95616, USA; <sup>6</sup> Corresponding author (email: fuzal@cahfs.ucdavis.edu)

**ABSTRACT:** Two mountain lions (*Puma concolor*) were found dead in the Simi Hills area of southern California (Ventura County). Post-mortem examination and toxicological analyses indicated that the cause of death was anticoagulant rodenticide intoxication. In addition, both lions had marked alopecia and skin crusts, caused by *Notoedres cati*. The diagnosis of notoedric mange was confirmed by histology and direct examination of mites obtained from skin scrapings of the two animals. Histologically, the affected skin showed acanthotic epidermis with parakeratosis and parasitic tunnels in the stratum corneum. This is the first report of the pathological changes associated with notoedric mange in free-ranging mountain lions.

**Key words:** Anticoagulant, mange, mountain lion, *Notoedres cati*.

Notoedric mange is a cutaneous disease of mammals caused by the mite *Notoedres cati* (Astigmata: Sarcoptidae). The condition has been described in felids (Young et al., 1972; Fletcher, 1978; Pence et al., 1982; Foley, 1991; Maehr et al., 1995; Pence et al., 1995; Scott et al., 2001), white-nosed coatis (*Nasua narica*) (Valenzuela et al., 2000), ring-tail cats (*Bassariscus astutus*; Klompen, 1992), masked palm civets (*Paguma larvata*; Hamir et al., 1993), and raccoons (*Procyon lotor*; Nino-miya and Ogata, 2002). Among felids, *N. cati* parasitism has been described in a 10-day-old Florida panther (*Puma concolor coryi*), an endangered subspecies of mountain lion (*Puma concolor*), which was recently incorporated into a captive breeding colony (Maehr et al., 1995). However, to the best of our knowledge, the pathological changes of this mite infestation have not been described in

mountain lions. This report describes two cases of notoedric mange in free-ranging mountain lions in southern California.

Two radiocollared adult mountain lions (a male and a nonpregnant female) were found dead in the Simi Hills area of southern California (Ventura County). The Universal Transverse Mercator coordinates where the carcasses were found were X: 334,422 Y: 3784,646 (male) and X: 344,132 Y: 3791,074 (female). This area consists mostly of chaparral intermixed with occasional exotic grasslands, oak woodlands, and riparian woodlands. The date and time of death was unknown. The carcass of the male lion was frozen and maintained in that state until it was transported to the California Animal Health and Food Safety Laboratory in San Bernardino, California, and necropsied. A field necropsy was performed on the female lion and the whole head, hide, and a sample of liver from this animal were also frozen, and then submitted to the laboratory.

At the laboratory, the frozen carcass of the male lion and the specimens from the female lion were thawed at 4 C over a 48 hr period. A full necropsy was performed on the male lion, and the hide, head, and liver of the female animal were examined. Samples of liver, heart, lung, small and large intestine, kidney, and skeletal muscle from the male lion, and samples of brain and skin from both lions, were fixed in neutral buffered formalin overnight, embedded in paraffin wax, sectioned at 5 µm, and stained with hematoxylin and eosin




FIGURE 1. Multifocal to coalescing dermatitis in a mountain lion, produced by *Notoedres cati*.

(HE). Skin scrapings from both lions were obtained from the periphery of gross skin lesions of the head (see below), treated with 10% KOH, and prepared as whole mounts in lactophenol and Hoyer's mounting media. One-half brain from each lion was collected and stored frozen until analyzed for cholinesterase activity using the Ellman procedure adapted to a 96-well microliter plate reader (Tor et al., 1994). The liver also was collected from each lion and stored frozen until processed for anticoagulant rodenticide screening by HPLC using both fluorescence and photodiode array detection. Brodifacoum, bromodiolone, chlorophacinone, coumaphlor, difethialone, diphacinone, and warfarin were included in the screen.

Both carcasses were in a moderate state of post-mortem decomposition. The two animals had extensive multifocal to coalescing dermatitis involving the head (mostly face and ears), shoulders, and ventral aspects of forepaws (Fig. 1). The affected skin was multifocally alopecic, had numerous nodules and was lichenified (Fig. 1). Large quantities of unclotted blood were present in the pleural, pericardial, and peritoneal cavities of both lions. In addition, the male lion had

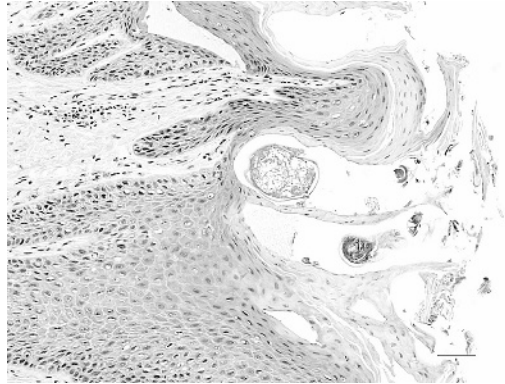


FIGURE 2. Multifocal to coalescing dermatitis in a mountain lion, produced by *Notoedres cati*. Observe hyperkeratosis and acanthosis with dermal pegs and intracorneal mites. HE. Bar 100  $\mu$ m.

multiple subserosal hemorrhages (petechiae and ecchymoses) in thoracic and abdominal organs. Because of the extensive hemorrhages seen in both animals, an intensive search for traumatic injuries was performed, which included complete skinning of the carcasses, para-medial sectioning of the skull of both animals, and examination of most joints and spinal column of the male lion. However, no evidence of trauma was found in either of the two carcasses.

Histologically, both lions had diffuse proliferative and chronic dermatitis characterized by diffuse, irregular, orthokeratotic, and parakeratotic hyperkeratosis and acanthosis, with deep epidermal downgrowths and variable numbers of intracorneal mites (Fig. 2). The epidermis was multifocally covered by thick, sometimes spongiform crusts composed of degenerate keratinocytes, blood, fibrin, neutrophils, lymphocytes, plasma cells, macrophages, and cellular debris with intralesional colonies of coccoid bacteria and nests of mites. The mites measured 110  $\mu$ m by 33  $\mu$ m and were ovoid, with spiny cuticles, striated skeletal muscle, and a hemocoelom. Parasitic tunnels were present within the stratum corneum (less commonly, within the stratum spinosum), often forming a crescent-shaped notch

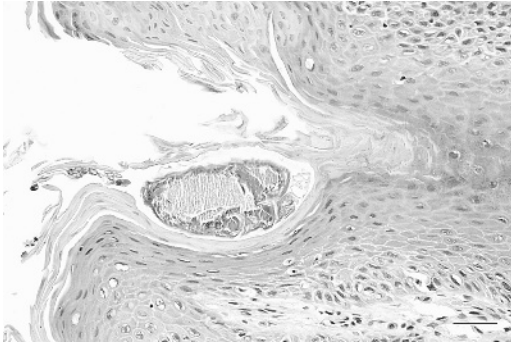


FIGURE 3. Multifocal to coalescing dermatitis in a mountain lion, produced by *Notoedres cati*. Observe a parasitic tunnel in the stratum corneum and a crescent-shaped notch on the surface of the epidermis. HE. Bar 30  $\mu$ m.

within which one to three mites could be found (Fig. 3). These epidermal tunnels occasionally extended to hair follicles, contained keratinocytes and cellular debris, and had parakeratosis and compression of the stratum basale. Occasionally, severely affected hair follicles had disrupted architecture, lost their hair shaft, and contained only cellular debris. Mild to moderate, multifocal, lymphoplasmacytic, occasionally neutrophilic perivascular infiltrates were present within the superficial dermis. The deep dermis was variably expanded by multifocally degenerate collagen (dermal scarring). In the ears, lesions were generally more severe on the outer pinna vs. the inner pinna.

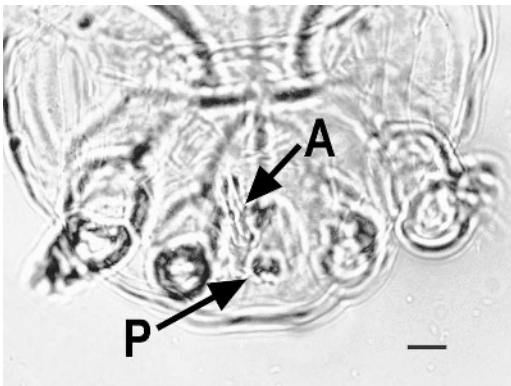


FIGURE 4. *Notoedres cati* male, dorsal surface in focus. A: anus; P: penis.

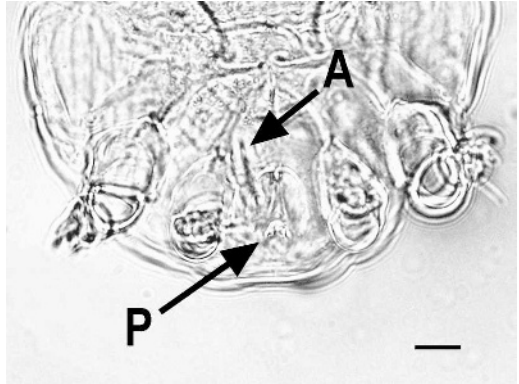


FIGURE 5. *Notoedres cati* male, ventral surface in focus. A: anus; P: penis.

Skin scrapings of lesions revealed large numbers of larval, nymphal, and adult astigmatid mites. Tarsi of adult specimens possessed distinctly unsegmented pedicels indicative of family Sarcoptidae. The placement of the anal aperture was dorsal (Figs. 4, 5, and 6) on all specimens observed, and mid-dorsal blunt dorsal spines were present (Fig. 6). Females lacked a mid-dorsal shield. The mites were thus identified as *Notoedres cati* (vs. *Sarcoptes* spp.) on the basis of these morphologic features (Flynn, 1973; McDaniel, 1979). Representative specimens have been deposited at the United States National Parasite Museum Collection with accession number 210A-17/18; 1181.

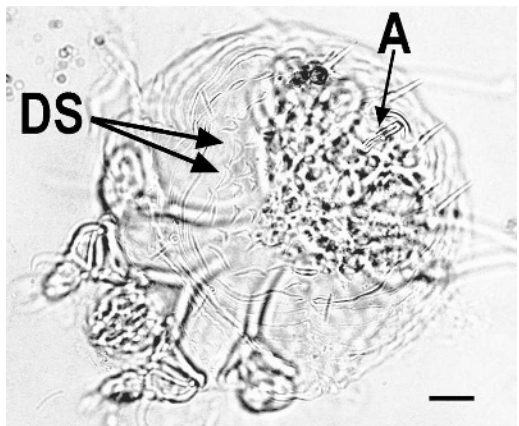


FIGURE 6. *Notoedres cati* female, dorsal surface in focus. A: anus; DS: blunt dorsal spines.



The cholinesterase activities in both brains were somewhat below activities reported to be normal for domestic cats, but reference ranges have not been established for mountain lions (Harlin and Ness, 1986). The rodenticides bromadiolone (1.27 ppm and 0.51 ppm, male and female lion, respectively), brodifacoum (0.57 ppm and 0.31 ppm, male and female lion, respectively), diphacinone, and difethialone (both at trace concentrations in both animals) were detected in liver samples from both lions.

Mountain lions are found throughout California, including many areas of southern California where large expanses of natural habitat remain. As human population size and development increase in southern California, mountain lions increasingly are living in proximity to people and their pets. *Notoedres* mites parasitize several mammalian species and, although the life cycle of this parasite is poorly understood, it has been established that the closely related *Sarcoptes scabiei* can live for as much as 3 wk off the host (Arlian et al., 1989). Sarcoptid mites are transmitted primarily by direct contact between animals or by contact with infested bedding or sites recently visited by infested animals.

Information about prevalence of notoedric mange in mountain lions in southern California is not available, but if the mites maintain a population in free-ranging mountain lions in the region, it is possible that the infestation is transmitted by direct contact between lions. Mountain lions eat a wide variety of mostly mammalian prey, including potential *Notoedres* hosts such as raccoons and ground squirrels (*Spermophilus* spp.), but in southern California, they generally prey on ungulates, especially mule deer (*Odocoileus hemionus*; Beier and Barrett 1993). Mountain lions in southern California occasionally kill and/or eat domestic cats (unpubl. data), and infected cats can serve as a source of infection because notoedric mange is highly prevalent in domestic cats of southern California (Brooks, 2005). It is also

possible that infected bobcats (*Felis rufus*) transmitted mites to these two lions because notoedric mange has been frequently diagnosed in bobcats in the area where these two mountain lions originated (National Park Service, unpubl. data). Wildlife managers need to be aware that notoedric mange could affect free-ranging mountain lions, particularly in southern California.

*Notoedres cati* excavates tunnels in the skin; this seem to vary between host species. In raccoons, tunnels are relatively shallow and are located between hair follicles (Webb, 1980), whereas tunnels in masked palm civets are located close to hair shafts and excavated along the hair follicles where the mites inhabit deep in the hair root, similarly to *Demodex* spp. mites (Hamir et al., 1993). In the mountain lions presented here, the tunnels were generally shallow and located between hair follicles, although rarely a few follicles were affected. In this regard, the lesions were similar to the shallow tunnels produced by *S. scabiei* in different animal species (Ninomiya and Ogata, 2002; Webb, 1980)

The detection of multiple anticoagulant rodenticides in the liver from both mountain lions, along with the gross necropsy findings of large amounts of free, unclotted blood in the pleural, pericardial and peritoneal cavities is indicative of anticoagulant rodenticide intoxication. Unfortunately, it was not possible to determine the source of exposure to the rodenticides in this case. It is possible that the lions ingested rodent baits directly, or that they were exposed indirectly via intoxicated prey. To the authors' knowledge there are no currently available commercial products that contain more than one anticoagulant, which suggests that these animals had access to different baits, or to prey exposed to different rodenticides. Mountain lions are both predators and scavengers (Bauer et al., 2005), so they could have been intoxicated by eating live or dead prey. However, it seems unlikely that they would ingest baits intended for rodent control.

Sarcoptic mange has been documented as a cause of epizootic mortality in other wildlife, especially coyotes (*Canis latrans*; Pence et al., 1983), so further investigation is warranted to determine the extent and impact of *N. cati* infection in free-ranging mountain lions. We are not aware of any causal relationship between the occurrence of notoedric mange and anticoagulant exposure. However, a high prevalence of notoedric mange was detected concurrently with anticoagulant rodenticide exposure in a series of bobcats examined in the same general area (National Park Service, unpubl. data). Thus the relationship, if any, between mange and anticoagulant exposure warrants further investigation.

We thank S. Kwiek and E. J. Hurley for excellent technical assistance and S. Fiti-semanu and C. Garcia for their patient secretarial work.

#### LITERATURE CITED

- ARLIAN, L. G., D. L. VYSZENCKI-MOHRER, AND M. J. POLE. 1989. Survival of adults and development stages of *Sarcoptes scabiei* var. *canis* when off the host. *Experimental and Applied Acarology* 6: 181–187.
- BAUER, J. W., K. A. LOGAN, L. L. SWEANOR, AND W. M. BOYCE. 2005. Scavenging behavior in puma. *Southwestern Naturalist* 50: 466–471.
- BEIER, P., AND R. H. BARRET. 1993. The cougar in the Santa Ana mountain range. Final report. Orange County Cooperative Mountain Lion Study. Department of Forestry and Resource Management, University of California, Berkeley, California, 12 pp.
- BROOKS, W. S. 2005. The pet healthy library. <http://www.veterinarypartner.com/Content.plx?P=A&S=0&C=O&A=512>. Accessed January 2006.
- FLETCHER, K. C. 1978. Notoedric mange in a litter of snow leopards. *Journal of the American Veterinary Medical Association* 173: 1231–1232.
- FLYNN, R. J. 1973. Parasites of laboratory animals., Iowa State University Press, Ames, Iowa, 454 pp.
- FOLEY, R. H. 1991. A notoedric mange epizootic in an island's cat population. *Feline Practice* 19: 8–10.
- HAMIR, A. N., D. E. SNYDER, C. A. HANLON, AND C. E. RUPPRECHT. 1993. First report of a *Demodex* sp. in raccoons (*Procyon lotor*). *Journal of Wildlife Diseases* 29: 139–141.
- HARLIN, K. S., AND D. NESS. 1986. Brain cholinesterase: normal enzyme activity levels in several large and small animal species. In *Proceedings of the 29th Annual Meeting of the American Association of Veterinary Laboratory Diagnosticians*. Louisville, Kentucky, 15–20 October 1986, pp. 457–459.
- KLOMPEN, H. 1992. Phylogenetic relationships in the mite family Sarcoptidae (Acari: Astigmata)., *Miscellaneous Publication Museum of Zoology #180*: University of Michigan, pp. 1–159.
- MAEHR, D. S., E. C. GREINER, J. E. LANIER, AND D. MURPHY. 1995. Notoedric mange in the Florida panther (*Felis concolor coryi*). *Journal of Wildlife Diseases* 31: 251–254.
- MCDANIEL, B. 1979. How to know the mites and ticks., Wm. C. Brown Company Publishers, Dubuque, Iowa, pp. 270–271.
- NINOMIYA, H., AND M. OGATA. 2002. Notoedric mange in two free-ranging North American raccoons (*Procyon lotor*) in Japan. *Veterinary Dermatology* 13: 119–121.
- PENCE, D. B., F. D. MATTHEWS, AND L. A. WINDBERG. 1982. Notoedric mange in the bobcat, *Felis rufus*, from South Texas. *Journal of Wildlife Diseases* 18: 47–50.
- , L. A. WINDBERG, B. C. PENCE, AND R. SPROWLS. 1983. The epizootiology and pathology of sarcoptic mange in coyotes, *Canis latrans*, from south Texas. *Journal of Parasitology* 69: 1100–1115.
- , M. E. TEWES, D. B. SHINDLE, AND D. M. DUNN. 1995. Notoedric mange in an ocelot (*Felis pardalis*) from southern Texas. *Journal of Wildlife Diseases* 31: 558–562.
- SCOTT, D. W., W. H. MILLER, AND C. E. GRIFFIN. 2001. Parasitic skin diseases. In *Muller and Kirk's small animal dermatology*, 6th ed. W. B. Saunders, Philadelphia, Pennsylvania, pp. 483–493.
- TOR, E. R., D. M. HOSTEDGE, AND F. D. GALEY. 1994. Determination of cholinesterase activity in brain and blood samples using a plate reader. *Journal of the American Association of Official Analytical Chemists International* 77: 1308–1313.
- VALENZUELA, D., G. CEBALLOS, AND A. GARCIA. 2000. Mange epizootic in white-nosed coatis in western Mexico. *Journal of Wildlife Diseases* 36: 56–63.
- WEBB, J. W. 1980. Parasites of small Indian mongoose on St. Croix, Virgin Islands. *Journal of Parasitology* 66: 176–178.
- YOUNG, E., F. ZUMPT, AND I. J. WHYTE. 1972. *Notoedres cati* (Hering, 1883) infestation of the cheetah: Preliminary report. *Journal of the South African Veterinarian Medical Association* 43: 205.

Received for publication 1 April 2006.