

A Case of Chondrosarcoma in a Free-flying Great Egret

Authors: Kubo, Masahito, Kobayashi, Keiya, Masegi, Toshiaki, Sakai, Hiroki, Tsubota, Toshio, et al.

Source: Journal of Wildlife Diseases, 43(3) : 542-544

Published By: Wildlife Disease Association

URL: <https://doi.org/10.7589/0090-3558-43.3.542>

BioOne Complete (complete.BioOne.org) is a full-text database of 200 subscribed and open-access titles in the biological, ecological, and environmental sciences published by nonprofit societies, associations, museums, institutions, and presses.

Your use of this PDF, the BioOne Complete website, and all posted and associated content indicates your acceptance of BioOne's Terms of Use, available at www.bioone.org/terms-of-use.

Usage of BioOne Complete content is strictly limited to personal, educational, and non - commercial use. Commercial inquiries or rights and permissions requests should be directed to the individual publisher as copyright holder.

BioOne sees sustainable scholarly publishing as an inherently collaborative enterprise connecting authors, nonprofit publishers, academic institutions, research libraries, and research funders in the common goal of maximizing access to critical research.

A Case of Chondrosarcoma in a Free-flying Great Egret

Masahito Kubo,^{1,2} Keiya Kobayashi,² Toshiaki Masegi,^{1,2} Hiroki Sakai,² Toshio Tsubota,³ Makoto Asano,³ Miki Itani,⁴ and Tokuma Yanai^{1,2,5} ¹ United Graduate School of Veterinary Sciences, Gifu University, 1-1 Yanagido, Gifu 501-1193, Japan; ² Laboratory of Veterinary Pathology, Faculty of Applied Biological Sciences, Gifu University, 1-1 Yanagido, Gifu 501-1193, Japan; ³ Laboratory of Zoo and Wildlife Medicine, Faculty of Applied Biological Sciences, Gifu University, 1-1 Yanagido, Gifu 501-1193, Japan; ⁴ COE Wildlife Rescue Center, Gifu University, 1-1 Yanagido, Gifu 501-1193, Japan; ⁵ Corresponding author (email: yanai@gifu-u.ac.jp)

ABSTRACT: A free-flying Great Egret (*Ardea alba*) captured in Gifu, central Japan, in May 2006 had a large mass on the right carpal joint. The tumor was diagnosed as chondrosarcoma by histopathologic examination.

Key words: *Ardea alba*, carpal joint, chondrosarcoma, free-flying, Great Egret.

Neoplastic diseases in wild birds are found infrequently. Siegfried (1983) reported nine cases (<0.05%) of neoplasm diagnosed in more than 18,000 carcasses of free-flying birds examined at the National Wildlife Health Laboratory, Wisconsin, USA. Spalding and Woodard (1992) found only one case (0.1%) of chondrosarcoma in 957 carcasses of ciconiiformes from Florida. Gates et al. (1992) described two cases (0.2%) of spindle cell sarcoma in 1,272 wild Canada geese (*Branta canadensis interior*) from North America. Multicentric intramuscular lipomatosis/fibromatosis in 9 (1.1%) of 818 geese was also reported from North America (Daoust et al., 1991). Here, we report a case of chondrosarcoma in a free-flying Great Egret (*Ardea alba*) from central Japan.

A Great Egret was captured in Yamagata, Gifu, Japan (35°30'N, 136°47'E) in May 2006, and then transported to the COE Wildlife Rescue Center of Gifu University. The bird was severely emaciated and weakened, weighed approximately 1.2 kg, and had a firm, green-black, approximately 6-cm-diameter mass on the right carpal joint; the right wing was hanging down. The bird died and was necropsied the following day.

At necropsy, this mature male Great Egret had poorly developed subcutaneous fat tissue and muscles. Numerous biting

lice were seen on the body surface. The mobility of the right carpal joint was decreased by the mass (Fig. 1), which was white, semitransparent and cartilage-like in appearance on cut surface (Fig. 2). The tumor encompassed several tendons but did not connect with these tendons or bones. Gross lesions in other organs included white firm foci in the liver and unidentified nematode infection in the stomach.

Tissue samples of the tumor and major organs were fixed in 10% neutral buffered formalin, embedded in paraffin, sectioned, and stained with hematoxylin and eosin (H&E). Some sections were stained with Masson trichrome stain or alcian blue–periodic acid Schiff (PAS) double stain.

Histopathologically, the tumor was diagnosed as chondrosarcoma based on the existence of various-sized lobules of neoplastic cartilage, which consisted of atypical chondrocyte-like cells and light basophilic matrix, divided by fibrous connective tissue. Nuclear pleomorphism was remarkable, there was some evidence of degeneration, and occasional multinucleated cells were observed (Fig. 3); mitotic figures were infrequent. No inclusion bodies were observed. In the section of tumor stained with alcian blue–PAS double stain, there was a tendency for areas surrounding chondrocytes to be strongly stained with alcian blue, whereas the periphery of cartilage lobules stained positively with PAS. There were large necrotic areas and the surface of the tumor was covered by a crust that contained bacterial colonies and fungal hyphae. Histologic lesions in other organs included parasitic hepatitis and cholecys-

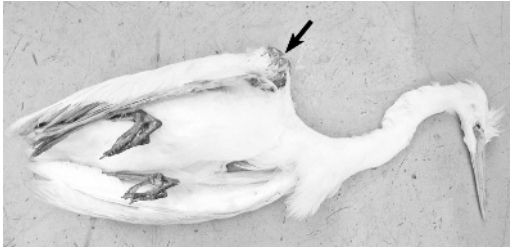

FIGURE 1. Great Egret with large mass on the right carpal joint (arrow).

titis caused by unidentified trematodes, pulmonary congestion, a foreign-body granuloma in the muscular layer of the small intestine and microfilariae in peripheral blood (no adult filarid worms were detected). There was no evidence of metastasis of the neoplasm in any organ.

There are only three published reports of chondrosarcoma in wild birds (Siegfried, 1983; Spalding and Woodard, 1992; Forrester and Spalding, 2003). Siegfried (1983) reported a case of chondrosarcoma that consisted of cartilaginous islands and fibroblastic stroma on the metatarsal-phalangeal joint of a free-flying Ruffed Grouse (*Bonasa umbellus*). In the Ruffed Grouse, the neoplasm eroded or invaded

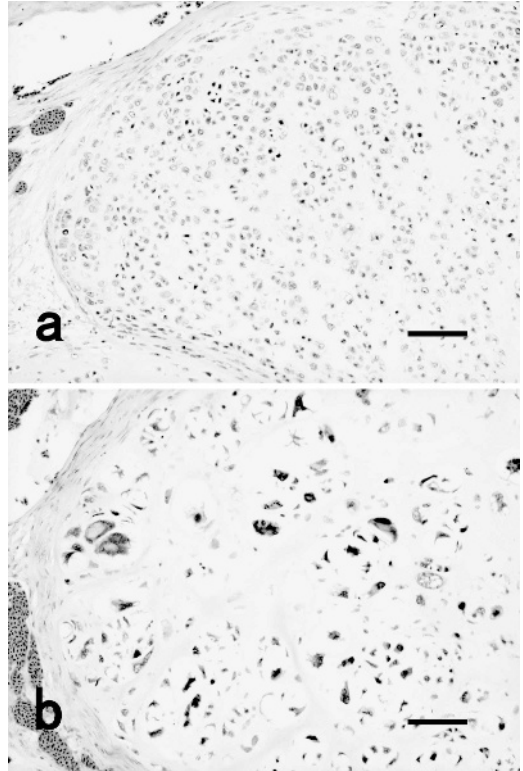


FIGURE 3. Photomicrograph of chondrosarcoma. (a) One portion consisted of smaller chondrocyte-like cells arranged irregularly and (b) another portion consisted of very atypical cells. Note remarkable nuclear pleomorphism. H&E stain. Bars=75 μ m.




FIGURE 2. The cut surface of mass on right carpal joint. Note its white, semitransparent, cartilage-like appearance. Several tendons (arrow) are encircled by the tumor. Scale=0.5 cm divisions.

adjacent bones (Siegfried, 1983). Spalding and Woodard (1992) reported a case of chondrosarcoma in a Great White Heron (*Ardea herodias occidentalis*) from southern Florida. That tumor seemed to have originated in the right nictitating membrane, probably the tendon of the pyramidalis, and consisted of three portions: a dense white tissue band comprised histologically of dense collagenous connective tissue, elastic firm tan tissue comprised histologically of dense spindle cells in a regular pattern with interlacing bundles, and variably sized islands of cartilage (Spalding and Woodard, 1992). Forrester and Spalding (2003) described multiple cutaneous chondromas and chondrosarcomas on the legs of free-flying Sandhill (*Grus canadensis*) and Whooping

Cranes (*Grus americana*). In the great egret described in the present report, the neoplasm did not connect with bones, articular cartilages, or tendons; thus, it was thought to have originated in an articular capsule or soft tissue around the joint. Unlike the tumor in the great white heron described by Spalding and Woodard (1992), the tumor in this case contained only cartilaginous regions.

Although the neoplasm in this case had only a few mitotic figures, it is likely the tumor grew rapidly. The right wing of the bird did not move sufficiently, and wild birds cannot survive for a long time without the ability to fly.

Some oncogenic viruses, such as retroviridae, may cause neoplasia. Siegfried (1983) suggested that some cases of neoplasm in wild birds might be associated with viral infection. Forrester and Spalding (2003) detected intranuclear viral particles in the neoplasms of cranes by electron microscopy, although the virus could not be identified. Viral inclusion bodies were not found in the neoplasm of this great egret, but this does not rule out potential viral induction, because ancillary testing for virus infection, e.g., virologic or serologic examination, was not performed in this case.

The authors would like to thank Marilyn G. Spalding at the Department of Infectious Diseases and Pathology, College of Veterinary Medicine, University of Florida, for providing the excerpt from her book. This study was supported in part by a Grant-in-Aid for Scientific Research (the 21st Century COE Program) from the Ministry of Education, Sports, Science and Technology of Japan.

LITERATURE CITED

- DAOUST, P. Y., G. WOBESER, D. J. RAINNIE, AND F. A. LEIGHTON. 1991. Multicentric intramuscular lipomatosis/fibromatosis in free-flying white-fronted and Canada geese. *Journal of Wildlife Diseases* 27: 135–139.
- FORRESTER, D. J., AND M. G. SPALDING. 2003. *Parasites and diseases of wild birds in Florida*. University Press of Florida, Gainesville, Florida. 1132 pp.
- GATES, R. J., A. WOOLF, D. F. CAITHAMER, AND W. E. MORITZ. 1992. Prevalence of spindle cell sarcomas among wild Canada geese from southern Illinois. *Journal of Wildlife Diseases* 28: 666–668.
- SIEGFRIED, L. M. 1983. Neoplasms identified in free-flying birds. *Avian Diseases* 27: 86–99.
- SPALDING, M. G., AND J. C. WOODARD. 1992. Chondrosarcoma in a wild great white heron from southern Florida. *Journal of Wildlife Diseases* 28: 151–153.

Received for publication 24 September 2006.