

AN UNIDENTIFIED FILARIAL SPECIES AND ITS IMPACT ON FITNESS IN WILD POPULATIONS OF THE BLACK-FOOTED FERRET (MUSTELA NIGRIPES)

Authors: Wisely, Samantha M., Howard, JoGayle, Williams, Steven A., Bain, Odile, Santymire, Rachel M., et al.

Source: Journal of Wildlife Diseases, 44(1) : 53-64

Published By: Wildlife Disease Association

URL: <https://doi.org/10.7589/0090-3558-44.1.53>

BioOne Complete (complete.BioOne.org) is a full-text database of 200 subscribed and open-access titles in the biological, ecological, and environmental sciences published by nonprofit societies, associations, museums, institutions, and presses.

Your use of this PDF, the BioOne Complete website, and all posted and associated content indicates your acceptance of BioOne's Terms of Use, available at www.bioone.org/terms-of-use.

Usage of BioOne Complete content is strictly limited to personal, educational, and non - commercial use. Commercial inquiries or rights and permissions requests should be directed to the individual publisher as copyright holder.

BioOne sees sustainable scholarly publishing as an inherently collaborative enterprise connecting authors, nonprofit publishers, academic institutions, research libraries, and research funders in the common goal of maximizing access to critical research.

AN UNIDENTIFIED FILARIAL SPECIES AND ITS IMPACT ON FITNESS IN WILD POPULATIONS OF THE BLACK-FOOTED FERRET (*MUSTELA NIGRIPES*)

Samantha M. Wisely,^{1,7} JoGayle Howard,² Steven A. Williams,³ Odile Bain,⁴ Rachel M. Santymire,^{2,5} Katherine D. Bardsley,⁶ and Elizabeth S. Williams⁶

¹ Division of Biology, Kansas State University, Manhattan, Kansas 66506, USA

² Department of Reproductive Sciences, Smithsonian's National Zoological Park, Washington, District of Columbia 20008, USA

³ Department of Biological Sciences and NIH/NIAID Filarial Research Resource Repository Center, Clark Science Center, Smith College, Northampton, Massachusetts 01063, USA

⁴ Parasitologie comparée et Modèles expérimentaux, USM307, Muséum National d'Histoire Naturelle, 61 rue Buffon, 75231, Paris, France

⁵ Davee Center for Epidemiology and Endocrinology, Lincoln Park Zoo, Chicago, Illinois 60614, USA

⁶ Wyoming State Veterinary Laboratory, University of Wyoming, Laramie, Wyoming 82071, USA

⁷ Corresponding author (email: wisely@ksu.edu)

ABSTRACT: Disease can threaten the restoration of endangered species directly by substantially decreasing host survival or indirectly via incremental decreases in survival and reproduction. During a biomedical survey of reintroduced populations of the highly endangered black-footed ferret from 2002 to 2005, microfilariae discovered in the blood were putatively identified as *Dirofilaria immitis*, and widespread screening was initiated using a commercially available antigen-based ELISA test. A subset of animals ($n=16$) was screened for *D. immitis* using a highly sensitive PCR-based assay. Microfilariae were also molecularly and morphologically characterized. Of 198 animals at six reintroduction sites, 12% had positive results using the ELISA test. No antigen-positive animals which were screened via PCR ($n=11$) had positive PCR results, and all antigen-positive animals ($n=24$) were asymptomatic. No significant differences were found in body mass of antigen-positive (male: 1223 ± 82 g [mean \pm SD], female: 726 ± 75 g) vs. antigen-negative (male: $1,198 \pm 119$ g, female: 710 ± 53 g) individuals ($P=0.4$). Antigen prevalence was lower in juveniles (3%) than adults (12%; $P=0.03$), and higher in in situ, captive-reared individuals (33%) than wild-born individuals (10%; $P=0.005$). Morphologic analysis of microfilariae revealed they were neither *D. immitis* nor any other previously characterized North American species. PCR amplification of the 5S spacer region of rDNA revealed that the filarial sequence shared only 76% identity with *D. immitis*. This previously unidentified filarial sequence was present in all antigen positive animals (11 of 11 tested). It appears that black-footed ferrets were infected with a previously undescribed species of filaria whose antigen cross-reacted with the ELISA assay, although further analysis is needed to make a conclusive statement. Nonetheless, this previously undescribed filaria does not appear to threaten recovery for this highly endangered mammal.

Key words: Black-footed ferret, cross-reactivity, *Dirofilaria immitis*, heartworm antigen, microfilaria, molecular characterization, *Mustela nigripes*, seroprevalence.

INTRODUCTION

Conservation and wildlife biologists recognize disease as a potential threat to the restoration of endangered species (Deem et al., 2001). Infectious diseases and the resulting pathology can have a direct negative effect on host survival. Epizootics have been implicated in the decline or extirpation of such species as the lion (*Panthera leo*) from Serengeti National Park (Roelke-Parker et al., 1996), albatross (*Diomedea chlororhynchos*, *D. amsterdamensis*, and *Phoebastria fusca*) from the Southern Ocean (Weimerskirch, 2004), and Hawaiian hon-

eycreepers (Drepanidinae, Warner, 1968). Infectious diseases, however, are not always lethal, but can reduce the fitness of individuals by increasing the risk of predation, decreasing an individual's ability to compete for resources, decreasing reproductive potential, or decreasing the ability to disperse (Scott, 1988). These sublethal effects of disease on individual fitness may have significant consequences to the viability of populations (Dobson and May, 1986); however, the effects of some diseases are subtle and thus can be more difficult to detect and quantify (Daszak et al., 2000).

The black-footed ferret was nearly

extirpated by epizootics of the canine distemper virus and sylvatic plague (*Yersinia pestis*; Thorne and Williams, 1988). Twenty-one years of captive breeding (from 1985 to 2006) and 15 yr of reintroduction efforts (from 1991 to 2006) have resulted in a population increase from a nadir of 18 captive individuals to more than 500 individuals in the wild and 240 individuals in the captive breeding program (Conservation Breeding Specialist Group, 2003). Although the black-footed ferret is no longer in immediate risk of extinction, disease remains a persistent threat to the success of reintroduction and species recovery efforts. Besides the omnipresent threats of canine distemper virus and sylvatic plague, other diseases have the potential to threaten or impede the recovery of the black-footed ferret.

To further our understanding of the health and disease threats to the reintroduced populations, a biomedical survey of wild black-footed ferrets was conducted to assess health, disease, immunology, reproduction, and genetics (Howard et al., 2006). From 2002 through 2006, a total of 253 black-footed ferrets were captured at reintroduction sites in South Dakota, Montana, Wyoming, Arizona, Utah, Colorado, and Mexico. Each animal was trapped and anesthetized for a physical examination and blood collection, then returned to the capture site. Blood smears prepared for hematology revealed the presence of microfilariae in two black-footed ferrets from northeast Utah. Superficial similarity of the microfilariae to those of *D. immitis* and positive results from a commercially available, enzyme-linked immuno-sorbent antigen assay (ELISA) led us to initially identify the species as *D. immitis*.

Dirofilaria immitis is a ubiquitous filarial nematode with an expanding geographic range throughout the Americas (Sacks and Caswell-Chen, 2003; Labarthe and Guerrero, 2005). This filaria infects multiple companion species including dogs, cats, and domestic ferrets and has

been implicated as an infective agent of many free-ranging wildlife worldwide (e.g., Weissman, 1992; Marks and Bloomfield, 1998; Nakagaki et al., 2000; Sacks and Blejwas, 2000; Pence et al., 2003; Bakker et al., 2006). Domestic ferrets have been shown to be a highly suitable and susceptible host of *D. immitis* (McCall, 1998). Symptoms, based on clinical observations of naturally infected domestic ferrets, include coughing, severe dyspnea, moderate to severe exercise intolerance, moderate cyanosis, severe pleural effusion, heart murmur, decreased appetite, and weight loss consistent with adult worms residing in the heart and associated vessels (Antinoff, 2001). Given the substantial pathology of infected domestic ferrets, infection in the endangered black-footed ferret could have a significant impact on the recovery of this species.

Prior to the initiation of this biomedical survey, *D. immitis* had not been observed in the black-footed ferret and was not considered a threat to the wild population. To assess the prevalence of the filarial infection, widespread testing at six reintroduction sites using a commercially available antigen-based ELISA test for *D. immitis* was initiated. Rates of infectivity among juveniles vs. adults and captive-reared vs. wild-born individuals were compared. As a crude assessment of fitness, body mass among antigen positive and antigen negative animals were compared. Results of the ELISA test were validated with molecular tests and morphologic characterization of the filariae in black-footed ferrets.

MATERIALS AND METHODS

Animals, anesthesia, and blood analysis

Black-footed ferrets were evaluated during the fall or spring monitoring surveys at six reintroduction sites in Buffalo Gap National Grasslands and Badlands National Park, South Dakota, USA (43°15'N, 109°06'W); Janos, Chihuahua State, Mexico, (31°04'N, 107°51'W); Aubrey Valley, Arizona, USA (35°32'N, 113°10'W), Coyote Basin, Utah and Wolf Creek, Colorado, USA

(40°15'N, 109°06'W), Shirley Basin, Wyoming, USA (42°07'N, 106°03'W), and Charles M. Russell National Wildlife Refuge, Montana, USA (47°37'N, 107°46'W). All animals were captured in the wild but were born either in the wild or in captivity and then reintroduced. Trapping and anesthesia protocols for the black-footed ferret are well established (Sheets, 1972; Kreeger et al., 1998). Animals were cage-trapped at night and returned to the same trap location following examination and recovery from anesthesia. Additionally, 21 *ex situ* black-footed ferrets from the U.S. Fish and Wildlife Service—National Black-Footed Ferret Conservation Center in Wheatland, Wyoming (41°46'N, 105°19'W) were sampled. All animals received detailed physical examinations by veterinarians. All trapping and handling was authorized, coordinated, and conducted by the U.S. Fish and Wildlife Service's Black-Footed Ferret Recovery Implementation Team as part of routine population monitoring for reintroduction sites.

Each black-footed ferret was transferred to an anesthesia induction chamber and anesthetized via inhalation using isoflurane. A physical examination was conducted and weight obtained. Whole blood was collected from the jugular vein and aliquoted into EDTA tubes (for hematology) and serum separator clot tubes (for serum chemistry). Following clotting, serum tubes were centrifuged, and serum was recovered and frozen on site. The blood sample in EDTA and the blood smears prepared from each EDTA sample were shipped within 24 hr of collection to the Wyoming State Veterinary Laboratory (Laramie, Wyoming) for assessment of a complete blood count (CBC) with differential evaluation of white blood cells. Blood smears also were evaluated for microscopic detection of circulating microfilariae. This test is less sensitive than other approaches (e.g., modified Knott test) for evaluating prevalence of microfilariae, and likely underestimated the number of individuals with circulating microfilariae. Serum samples were maintained frozen and later shipped to Wyoming for diagnostic testing. Both plasma and serum samples were evaluated for heartworm using a commercially available ELISA kit designed to detect adult *D. immitis* antigen (DIROCHEK®, Synbiotics, Inc., San Diego, California). Plasma was used initially for the ELISA test; tests were reevaluated using serum.

To determine if antigen-positive animals had less body mass than antigen-negative animals, a univariate analysis of variance (ANOVA) on body with sex as an additional treatment was conducted. For this analysis, only wild-born adult animals were used; the

analysis was conducted with and without location as a treatment. To test if adults and juveniles had significantly different frequencies of antigen-positive ELISA tests, a Yates corrected chi-square (χ^2) test of independence was used for *in situ* animals. The same statistical test was used to determine whether the prevalence of antigen-positive animals was different for *in situ* animals that were captive-reared or wild-born.

Molecular and morphologic identification of filarial DNA

An aliquot of whole blood (250 μ l) from ferrets was stored in 1 ml standard lysis buffer and stored at 4 C until DNA was extracted with a Qiagen Tissue Kit (Qiagen Inc., Hilden, Germany) following the manufacturer's protocol. We conducted two polymerase chain reaction (PCR)-based screens on a subset of the DNA samples extracted from ferret blood; nine individuals in which microfilariae were seen and ELISA tests were positive, two individuals that had positive ELISA tests but no microfilariae were seen on blood smears, and five individuals that were negative for both ELISA tests and microfilariae. We used universal primers to amplify the coding region of the 5S rDNA of all filarial parasites (Xie et al., 1994). In addition, we used a highly sensitive, nested PCR protocol with *D. immitis* specific primers to more accurately diagnose infection in these animals (US Patent No. 6268153). PCR was conducted with positive and negative controls and products were run on a 2.5% agarose gel to visualize the presence of amplified DNA. All PCR reagents except primers were obtained from Applied Biosystems (Foster City, California). The PCR reaction contents included: 5 μ l 10 \times reaction buffer, 8 μ l 1.25 mM dNTP mixture, 20 pmoles of each primer, and 1 unit of *Taq*Gold DNA polymerase. The PCR cycling conditions were 95 C 12 min, followed by 30 cycles of 95 C 1 min, 55 C 1 min, 72 C 1 min, and a 10 min final extension at 72 C.

The amplified 5S spacer DNA was sequenced using the same primers as used for PCR. Sequencing reactions used the Big Dye v. 3.1 Cycle Sequencing Mix (Applied Biosystems). The 5S spacer sequences were aligned using Megalign software (Lasergene, DNASTAR, Inc., Madison, Wisconsin). Phylogenetic trees using the unknown ferret filarial 5S sequence and all of the filarial 5S ribosomal spacer sequences previously published (Xie et al., 1994) were calculated using the ClustalW "slow/accurate" method (Thompson et al., 1994) in Lasergene.

TABLE 1. Location, sample size, number of antigen-positive black-footed ferrets, number of black-footed ferrets with microfilariae circulating in the blood, and number of animals positive for unknown filarial sequence (number tested in parentheses).

| Location | Sample size | No. antigen-positive | No. microfilaria positive | No. sequence positive ^a |
|------------------|-------------|----------------------|---------------------------|------------------------------------|
| Arizona | 45 | 6 | 0 | 4 (5) |
| Utah/Colorado | 9 | 7 | 9 | 8 (9) |
| Mexico | 9 | 3 | 0 | 0 (0) |
| South Dakota | 101 | 5 | 0 | 0 (0) |
| Montana | 2 | 0 | 0 | 0 (2) |
| Wyoming | 32 | 3 | 0 | 0 (0) |
| Captive facility | 21 | 0 | 0 | 0 (0) |

^a These 16 samples were also PCR-assayed for *Dirofilaria immitis*. No positive samples were found.

The morphology of microfilariae collected from two black-footed ferrets at the Utah/Colorado location was examined by one co-author (OB) using light microscopy and accessioned into the Muséum National d'Histoire Naturelle (Accession No. 156 JW). Specimens were keyed to family based on microfilaria morphology. Genus and species cannot be identified solely by microfilariae; however, certain taxa could be eliminated on the basis of their morphologic characteristics. Particular attention was paid to species known to occur in North America.

RESULTS

Antigen prevalence and physical examination

Two hundred twenty plasma or serum samples collected from 198 free-ranging individuals at the six reintroduction sites from 2002 to 2005 were tested. Twenty-four individuals (12%) distributed among five of the six ex situ reintroduction sites had positive ELISAs; no positive animals were found at the breeding center. Nine individuals, all from the Utah/Colorado reintroduction site, had microfilariae visible in the blood; this site also had the highest frequency (78%) of positive antigen tests (Table 1). Twenty-two individuals were recaptured; two individuals seroconverted between captures, and three antigen-positive individuals were recaptured on multiple occasions. Two of these individuals dispersed 17 km between captures (Table 2).

All animals appeared free of symptoms associated with *D. immitis* infection. No

evidence of dyspnea, cyanosis, or unusual heart rhythms was detected. Animals with chronic infection, as detailed by our recaptures, appeared healthy at each capture (up to 1 yr between captures). No substantial weight fluctuation in these animals was found (Table 2). For the comparison of body mass between antigen-positive and antigen-negative animals, results did not differ between models that included or excluded location as a factor; therefore, only results of the ANOVA model conducted without location effect were reported. No significant difference in body mass of wild-born adults that were antigen-positive vs. negative was found; all of the variance in the model was explained by the difference in body mass between sexes as expected in this sexually dimorphic species (mean±S.D. for antigen-positive females: 726±75 g; antigen-negative females: 710±53 g; antigen-positive males: 1,223±82 g; antigen-negative males: 1,197±119 g; overall model: $F_{3,103}=237$, $P<0.001$, antigen: $F_{1,103}=0.7$, $P=0.4$, sex: $F_{1,103}=381$, $P<0.001$).

The prevalence of antigen-positive juveniles (2 of 77) was significantly less than that of adults (15 of 122; $\chi^2=4.5$, $df=1$, $P=0.03$); however, in situ, the prevalence of antigen-positive captive-reared individuals (7 of 21) was significantly higher than wild-born individuals (17 of 178; $\chi^2=7.9$, $df=1$, $P=0.005$). No antigen-positive animals were found in the ex situ captive breeding population.

TABLE 2. Chronology of infection, sex, and body mass for five black-footed ferrets that were recaptured during the biomedical survey.

| Individual | Date of initial capture Body mass (g) Serology (+/-) | Date of second capture Body mass (g) Serology (+/-) | Date of third capture Body mass (g) Serology (+/-) |
|-----------------------------|--|---|--|
| Arizona 8, male | October 2004 1,212 (-) | March 2005 1,196 (+) | |
| Arizona 3, female | October 2004 688 ^a (+) | March 2005 614 (-) | |
| South Dakota 109, male | September 2002 678 ^a (-) | March 2003 1,124 (+) | |
| Utah 3, male ^b | August 2004 1,024 (+) | March 2005 1,080 (+) | August 2005 1,188 (+) |
| Utah 4, female ^b | August 2004 732 (+) | April 2005 850 (+) | |
| Utah 5, male ^b | March 2005 1,228 (+) | August 2005 1,180 (+) | |

^a These individuals were juveniles (less than 1 yr old) at date of first capture.

^b Microfilariae were observed in these individuals at each capture.

Molecular identification of a filarial species

All 5S spacer sequences obtained from samples of 16 ferrets were identical and amplified in 12 of 16 samples (Table 1). The sequence was 360 base pairs long (GenBank Accession No. EU055542) and did not match published *D. immitis* 5S spacer sequences. In fact, the ferret parasite sequence and *D. immitis* sequence were very dissimilar. When compared with all published filarial 5S spacer sequences, the unknown ferret parasite sequence was most similar to *Acanthocheilonema viteae* (97% identity, Fig. 1). All of the other filarial species (*Litomosoides sigmodontis*, *Loa loa*, *Mansonella perstans*, *Brugia pahangi*, *Brugia buckleyi*, *Wuchereria bancrofti*, *Onchocerca volvulus*, *Onchocerca gutturosa*, and *D. immitis*) were much more divergent than *A. viteae*. In this data set, the *D. immitis* 5S spacer sequence was the least similar to the unknown ferret parasite sequence (76% identity). The ClustalW alignment and the resulting phylogenetic tree confirmed the distant relationship between *D.*

immitis and the filaria found in black-footed ferrets (Fig. 1). None of the 16 animals, whether antigen-positive or negative, were positive for the PCR-based *D. immitis* test. All positive controls amplified at the expected length of 155 base pairs, which indicated that negative results from ferret samples were due to a lack of *D. immitis* DNA in the blood, not because of PCR failure.

Morphology

Microfilariae from both black-footed ferrets had similar morphologic characters, thus they were considered to be the same species. Microfilariae were 165–185 µm long and 5 µm wide with no sheath (Figs. 2 and 3). The tail was attenuated with an anucleated caudal filament 9–13 µm long. The internal body had a long cephalic space (5–8 µm) with one or two masses. The cephalic hook was relatively long; the nerve ring, excretory pore, and anus were identified. Based on morphology, this parasite belongs to the family Onchocercidae.

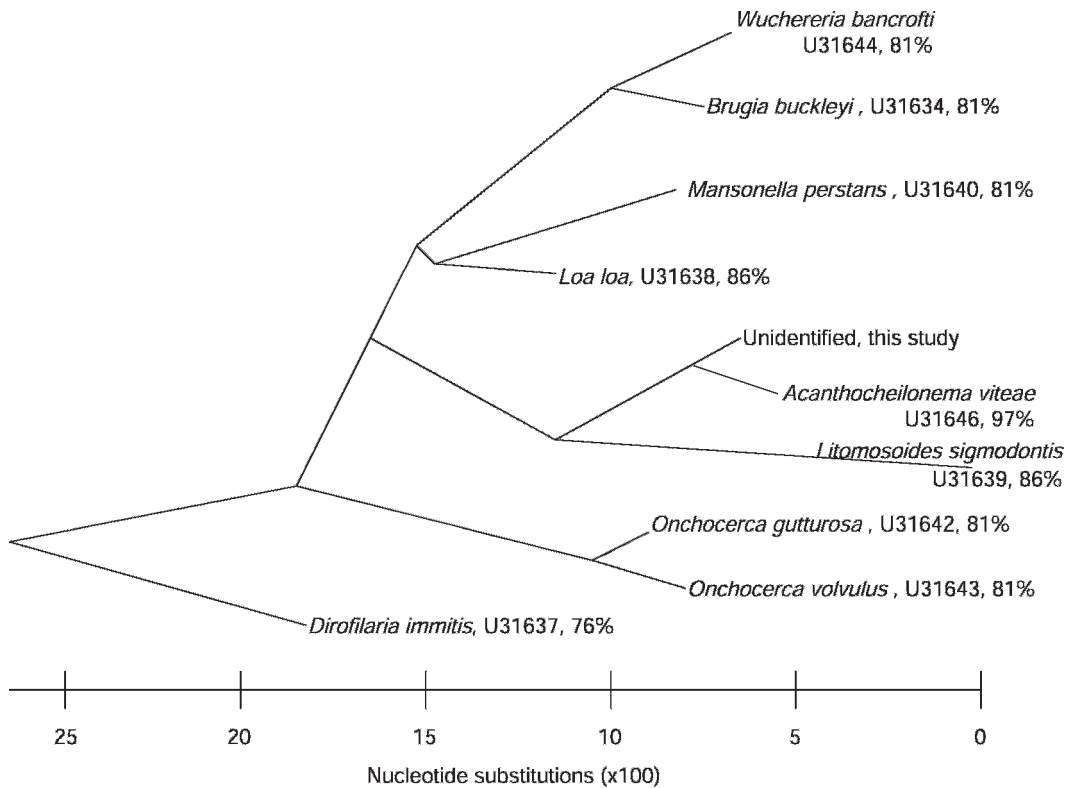


FIGURE 1. Unrooted phylogenetic tree of the 5S spacer sequence of nine known filarial species and the unknown filarial sequence isolated from the blood of a black-footed ferret. The tree was constructed using the slow/accurate algorithm of computer program, ClustalW. Branch tips are labeled with the filarial species, the Genbank accession number of the sequence used to build the tree, and percent similarity (base pair congruence) between the ferret filarial 5S spacer sequence and the 5S spacer sequence from other filarial parasites.

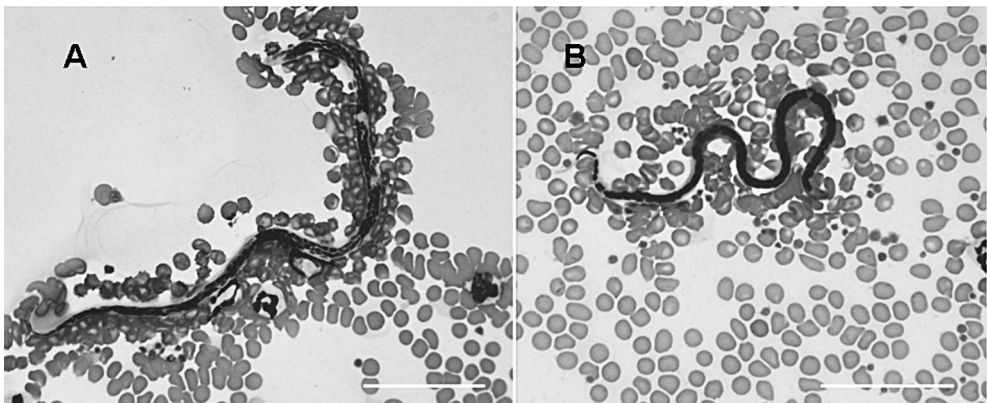


FIGURE 2. A. *Dirofilaria immitis* from a blood smear of a domestic dog. B. Unidentified microfilariae from a blood smear of a black-footed ferret. Bar in lower right corner of each photograph represents 50 μ m.

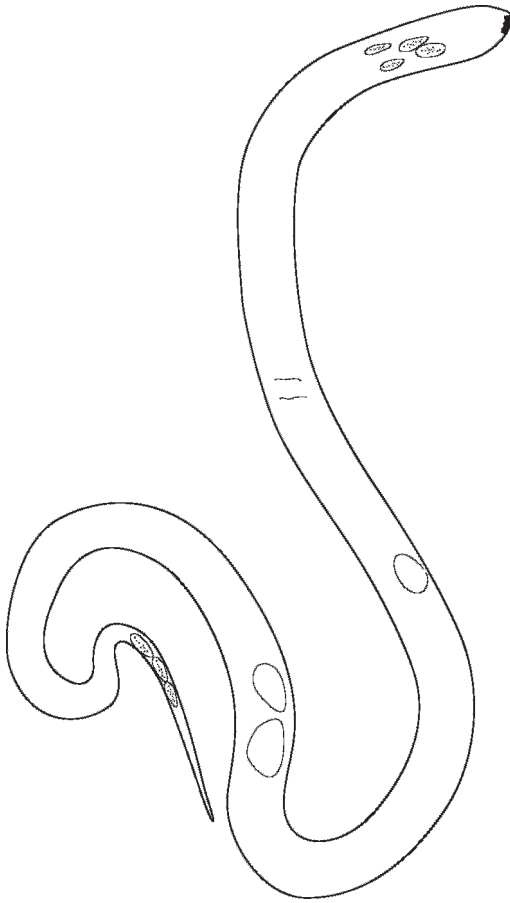


FIGURE 3. A microfilaria, 165 μm , long from a stained blood smear, showing the main characters: cephalic hook, cephalic space and most anterior nuclei, nerve ring, excretory cell, inner body (in two parts in this specimen), last caudal nuclei, and anucleated filament. On right, entire microfilaria, right lateral view; on left, anterior part of another microfilaria, median view (slide 156 JW, MNHN collection, Paris).

A comparison of morphologic features among filarial species reported in North America (Table 3), allowed exclusion of these species. The first 15 species listed in Table 3 have longer microfilariae than the unidentified filariae. Furthermore, in the subfamily Dirofilarinae, *D. immitis* and *D. tenuis* were conclusively excluded because they lack an internal body. *Loaia uniformis* was excluded because this taxon is characterized by having a sheath. *Pelecitus scapiceps* was excluded because it is

sheathed and the caudal extremity has a rounded shape. In the subfamily Onchocercinae, *Brugia beaveri* and *B. lepori* were excluded because they have a sheath and a longer internal body. *Mansonella* (*M.*) *llewellyni*, *M. (M.) interstitium* were excluded because they have no internal body. The two *Molinema* species had a longer caudal filament. *Acanthocheiloneuma reconditum*, as well as *A. mephitis* and *A. procyonis* were excluded because they lack an internal body. Microfilariae of *Monanema* are not found in blood but in skin (in marmots) and are sheathed.

DISCUSSION

The identity of the infective agent of antigen-positive animals remains elusive, but we hypothesize that the antigen of an unidentified filaria, whose microfilariae were observed in some animals, cross-reacted with the *D. immitis* ELISA test, and thus the widespread positive results were attributable to a wide-ranging unidentified filariae. We base our hypothesis on four lines of evidence: 1) PCR-based *D. immitis* tests were negative for all antigen-positive animals that we tested ($n=11$) suggesting that the ELISA test produced false positives; 2) unidentified filariae sequence was found in 10 of 11 antigen-positive animals, including eight of the nine animals in which we visually identified circulating microfilariae, which suggests that the unidentified filariae cross-reacted with the ELISA test; 3) the ferret population with the highest prevalence of circulating microfilariae (Utah/Colorado) also had the highest prevalence of antigen-positive animals and the highest prevalence of unidentified filariae based on molecular sequence data; 4) all antigen-positive animals were asymptomatic, including six animals which were captured 6 mo to 1 yr later. Given the highly debilitating nature of *D. immitis* in domestic ferrets, symptoms of dyspnea and cyanosis during the stress of capture and anesthesia were expected to occur,

TABLE 3. Characteristics of microfilariae of onchocercids from North American mammals. Species with skin-dwelling microfilariae excluded, except *A. procyonis* with blood and skin microfilariae (Smith, 1980). I. b.: Inner body; C. f.: Caudal filament.

| Filarial species | Length | Width | Sheath | I. b. | C. f. | References | Host |
|---|----------------------|---------|--------|-------|---------|------------------------------|------------------------------|
| ? | 165–185 | 5 | — | 9–13 | 9–13 | Present study | <i>Mustela nigripes</i> |
| <i>Dirofilaria immitis</i> (Leidy 1856) | 233–270 ^a | 5.4–6.5 | — | — | 25 | Fuelleborn, 1912 | <i>Canis familiaris</i> |
| | 307–322 | 6.7–7.1 | — | — | — | Newton and Wright, 1956 | <i>Canis familiaris</i> |
| <i>Dirofilaria striata</i> (Molin 1858) | 230–240 | 2–3 | — | ND | ++ | Orihel and Ash, 1964 | <i>Lynx rufus</i> |
| | 327–371 ^a | 4–5 | — | — | — | — | — |
| <i>Dirofilaria tenuis</i> (Chandler 1942) | 220–250 | 2–3 | — | — | 22–25 | Orihel and Beaver, 1965 | <i>Procyon lotor</i> |
| <i>Dirofilaria subdermata</i> (Mönnig 1924) | ND | ND | ND | ND | ND | No reference | <i>Erethizon dorsatum</i> |
| <i>Loaima uniformis</i> (Price 1957) | 285 ^a | 6 | + | 35 | 0 | Eberhard and Orihel, 1984 | <i>Sylvilagus floridanus</i> |
| <i>Pelecitus scapiceps</i> (Leidy 1886) | 220–250 ^a | 5 | + | 35 | 0 | Bartlett, 1983 | <i>Lepus americanus</i> |
| <i>Dirofilariaeformia pulmoni</i> (Davidson 1975) | 213–288 | 3–4 | — | — | 15 | Davidson, 1975 | <i>Sciurus carolinensis</i> |
| <i>Brugia beaveri</i> (Ash and Little 1964) | 300 ^a | 6 | + | 45 | 0 | Ash and Little, 1964 | <i>Procyon lotor</i> |
| <i>Brugia lepori</i> (Eberhard 1984) | 210–266 | 4–6 | + | 35 | 0 | Eberhard, 1984 | <i>Sylvilagus aquaticus</i> |
| | 275–330 ^a | 5–7 | — | — | — | — | — |
| <i>Mansonella (Mansonella) llewellyni</i> (Price 1962) | 290±5 ^a | 2.5 | — | 0 | 15 | Price, 1962 | <i>Procyon lotor</i> |
| <i>Mansonella (Mansonella) interstitium</i> (Price 1962) | 250±5 ^a | 3.5 | — | — | 13 | Price, 1962 | <i>Sciurus carolinensis</i> |
| <i>Molinema arbuta</i> (Highby 1943) | 280–297 ^a | 6 | — | — | 40 | Highby, 1943 | <i>Erethizon dorsatum</i> |
| <i>Molinema spreuti</i> (Anderson 1953) | 400–450 ^a | 8 | — | 80 | 35 | Anderson, 1953 | <i>Castor canadensis</i> |
| <i>Dasyspilaria averji</i> (Eberhard 1984) | 284–394 | 7–9 | + | ND | 5 | Eberhard, 1984 | <i>Dasypus novemcinctus</i> |
| <i>Acanthocheilonema reconditum</i> (Grassi 1890) | 269–283 ^a | 4.3–4.8 | — | — | 17 | Newton and Wright, 1956 | <i>Canis familiaris</i> |
| <i>Acanthocheilonema mephitis</i> (Webster and Beauregard 1964) | 186–218 | 3–3.8 | — | — | 6.6–9.5 | Webster and Beauregard, 1964 | <i>Mephitis mephitis</i> |
| <i>Acanthocheilonema procyonis</i> (Price 1955) | 129–149 | 3.6–4.9 | — | — | — | Smith, 1980 | <i>Procyon lotor</i> |

^a Measurements from fixed blood or female uteri, otherwise in blood smears, all in µm.

but were not observed. Recaptured, antigen-positive animals exhibited no weight loss, and in two cases, animals had dispersed substantial distances (~17 km) between captures. Additionally, no difference in body mass among antigen-positive and antigen-negative adults was observed. These observations suggest that the antigen-producing filariae did not produce obviously debilitating symptoms, and is likely not a major threat to black-footed ferret recovery. Although our results are highly suggestive, further testing with larger sample sizes is warranted.

Filaria identification

Both molecular and morphologic analysis indicated that the microfilariae seen in blood smears were not *D. immitis*. The molecular sequence of this species has not been previously described. The filaria shares 97% sequence similarity with *Acanthocheilonema viteae*, but this level of divergence indicates that the filaria is a separate species. Furthermore, the morphology was not consistent with *A. viteae*. Morphologic identification of the adult filariae remains undetermined, because adult worms have yet to be located. Clearly, infected individuals of an endangered species cannot be sacrificed to locate and collect adult worms. Further complicating matters, black-footed ferrets are an elusive, fossorial animal; dead individuals are rarely found above ground. Monitoring of captive individuals will continue, and necropsies will include a search for adult worms.

Several suppositions can be proposed about the life history of the antigen-producing filariae, whatever its identity may be, and the effect it has on its host. All juvenile black-footed ferrets were captured between the ages of 2 and 4 mo of age, based on an estimated June 1st birth date. The low antigen prevalence of the filariae in 2–4-mo-old juveniles suggests that either the life cycle of the filariae had not been completed or that juveniles were not infected at that age. A low prevalence

of *D. immitis* infection in host juveniles was found in the coyote (*Canis latrans*, Sacks and Blejwas, 2000), which was due to the 6–7 mo prepatent period of *D. immitis*. The life cycle of the filariae found in our study remains unknown, yet the high prevalence of microfilariae in Utah/Colorado animals (100%) suggests that the black-footed ferret is a suitable host for the completion of the filariae's life cycle.

Free ranging individuals that were captive-reared had a significantly higher prevalence of infection (33%) than wild-born individuals (10%). Two explanations are possible for this increased prevalence. The captive environment could have increased an animal's risk of exposure to the vector. A sample of captive individuals revealed no antigen-positive animals; however, our sample size ($n=21$) was small and confined to one of the six captive breeding facilities. Alternatively, captive-reared individuals that were reintroduced to the wild could have been more susceptible to infection in the wild. Recently released animals likely spend more time above ground in an attempt to find resources and establish territories, which could increase their risk of exposure to vectors of filariae. In addition, the stress of the release could suppress the immune system making these animals more susceptible to disease and infections (Wingfield and Romero, 2001).

Management implications

It appears that the ubiquitous prevalence of this filarial species across the range of the black-footed ferret does not pose an immediate threat to the recovery of this highly endangered species. The debilitating effects of heartworm infection on the survival of animals were not observed; however, the study was not designed to look at the other important contributor to fitness, reproduction. Parasitic infections can cause subtle, but important decreases in reproduction, which in turn can increase the risk of extinction (Anderson and May, 1978). For

the black-footed ferret, decreases in any vital rate that limits the growth rate could have devastating consequences to species recovery. The increased prevalence of infection in captive-reared free-ranging animals merits further investigation.

Antigen-based ELISA kits may not be a reliable test for diagnosing heartworm in free-ranging animals. Indeed, it was suspected that these kits also provided false-positives when used in the Channel Island fox (Roemer et al., 2000). Future assessments of prevalence of *D. immitis* in black-footed ferrets should utilize the PCR-based assay.

ACKNOWLEDGMENTS

All animal handling was authorized and coordinated by the U.S. Fish and Wildlife Service's Black-Footed Ferret Recovery Implementation Team. Animal handling protocols were reviewed and authorized by Kansas State University's Institutional Animal Care and Use Committee (protocol no. 2310). The authors thank M. Lockhart, P. Marinari, and R. Matchett of U.S. Fish and Wildlife Service; T. Livieri of Prairie Wildlife Research; B. Van Pelt, C. King, S. Goodman, R. Lonsinger, J. Broescher, and A. Siniawski of Arizona Game and Fish; B. Oakleaf and M. Grenier of Wyoming Game and Fish Department; B. Perry and D. Sargent of U.S. Department of Agriculture Forest Service; D. Albertson, G. Schroeder and B. Kenner of the National Park Service; R. List and J. Pacheco of Universidad Nacional Autónoma de México; B. Maxfield of Utah Division of Natural Resources; and B. Zwetzig of Bureau of Land Management for accommodating us in the field. We thank the many additional people who volunteered their time to help survey for black-footed ferrets. We also thank M. Bush and E. Bronson of Smithsonian's National Zoological Park; D. Garelle of Cheyenne Mountain Zoo; H. Mutlow, D. Gasper, J. Bachtel, and J. Kreeger for veterinary services. The authors thank the Wyoming State Veterinary Laboratory for providing hematology and chemistry analyses during this biomedical survey. Phoenix Zoo, Arizona Game and Fish Department, Wyoming Game and Fish Department, U.S.D.A. Forest Service, National Park Service, National Fish and Wildlife Foundation, Division of Biology at Kansas State University, and Friends of the National Zoo provided financial support for this research. We thank S. Upton

for initial discussions about this wildlife infection. We appreciate an informative and helpful review by B. Sacks.

LITERATURE CITED

- ANDERSON, R. C. 1953. *Dipetalonema sprengi* n. sp. from *Castor canadensis* Kuhl. Parasitology 43: 215–221.
- ANDERSON, R. M., AND R. M. MAY. 1978. Regulation and stability of host-parasite population interactions: I. Regulatory processes. Journal of Animal Ecology 47: 219–247.
- ANTINOFF, N. 2001. Clinical observations in ferrets with naturally occurring heartworm disease, and preliminary evaluation of treatment with ivermectin with and without melarsomine. In Proceedings of the Heartworm Symposium, San Antonio, Texas, April 20–22, 2001, R. L. Seward (ed.); American Heartworm Association, Batavia, Illinois, pp. 45–47.
- ASH, L. R., AND M. D. LITTLE. 1964. *Brugia beaveri* n. sp. (Nematoda: Filarioidea) from the raccoon (*Procyon lotor*) in Louisiana. Journal of Parasitology 50: 119–123.
- BAKKER, V. J., D. H. VAN VUREN, K. R. CROOKS, C. A. SCOTT, J. T. WILCOX, AND D. K. GARCELON. 2006. Serologic survey of the island spotted skunk on Santa Cruz Island. Western North American Naturalist 66: 456–461.
- BARTLETT, C. M. 1983. Zoogeography and taxonomy of *Dirofilaria scapiceps* (Leidy, 1886) and *D. uniformis* Price, 1957 (Nematoda: Filarioidea) of lagomorphs in North America. Canadian Journal of Zoology 6: 1011–1022.
- CONSERVATION BREEDING SPECIALIST GROUP. 2003. Black-footed ferret population management workshop. World Conservation Union, Apple Valley, pp. 128.
- DASZAK, P., A. A. CUNNINGHAM, AND A. D. HYATT. 2000. Emerging infectious diseases of wildlife—Threats to biodiversity and human health. Science 287: 443–449.
- DAVIDSON, W. R. 1975. *Dirofilariaeformia pulmonis* sp. n. (Nematoda: Onchocercidae) from the eastern gray squirrel (*Sciurus carolinensis* Gmelin). Journal of Parasitology 61: 351–354.
- DEEM, S. L., W. B. KARESH, AND W. WEISMAN. 2001. Putting theory into practice: Wildlife health in conservation. Conservation Biology 15: 1224–1233.
- DOBSON, A. P., AND R. M. MAY. 1986. Disease and conservation. In Conservation biology: The science of scarcity and diversity, M. Soulé (ed.). Sinauer Associates, Sunderland, Massachusetts, pp. 345–365.
- EBERHARD, M. L. 1984. *Brugia lepori* sp. n. (Filarioidea: Onchocercidae) from rabbits (*Sylvilagus aquaticus*, *S. floridanus*) in Louisiana. Journal of Parasitology 70: 576–579.

- , AND T. C. ORIHIEL. 1984. *Loaina* gen. n. (Filarioidea: Onchocercidae) for the filariae parasitic in rabbits in North America. *Proceedings of the Helminthological Society of Washington* 51: 49–53.
- FUELLEBORN, F. 1912. Zur morphologie de *Dirofilaria immitis* Leidy, 1856. *Zentralblatt für Bakteriologie, Parasitenkunde, Infektionskrankheiten und Hygiene* 65: 341–349.
- HIGHBY, P. R. 1943. *Dipetalonema arbuta* n. sp. (Nematoda) from the porcupine, *Erethizon dorsatum* (L.). *Journal of Parasitology* 29: 239–242.
- HOWARD, J. G., S. M. WISELY, R. M. SANTYMIRE, T. M. LIVIERI, S. A. WILLIAMS, J. S. KREEGER, P. E. MARINARI, D. E. WILDT, AND E. S. WILLIAMS. 2006. Biomedical survey of wild black-footed ferrets (*Mustela nigripes*): Integration of science and veterinary medicine. *Proceedings: American Association of Zoo Veterinarians*, pp. 34–35.
- KREEGER, T. J., A. VARGIS, G. E. PLUMB, AND T. E. THORNE. 1998. Ketamine-medetomidine or isoflurane immobilization of black-footed ferrets. *Journal of Wildlife Management* 62: 654–662.
- LABARTHE, N., AND J. GUERRERO. 2005. Epidemiology of heartworm: What is happening in South America and Mexico? *Veterinary Parasitology* 133: 149–156.
- MARKS, C. A., AND T. E. BLOOMFIELD. 1998. Canine heartworm (*Dirofilaria immitis*) detected in red foxes (*Vulpes vulpes*) in urban Melbourne. *Veterinary Parasitology* 78: 147–154.
- MCCALL, J. W. 1998. *Dirofilariasis* in the domestic ferret. *Clinical Techniques in Small Animal Practice* 13: 109–112.
- NAKAGAKI, K., T. SUZUKI, S. I. HAYAMA, AND E. KANDA. 2000. Prevalence of dirofilarial infection in raccoon dogs in Japan. *Parasitology International* 49: 253–256.
- NEWTON, W. L., AND W. H. WRIGHT. 1956. The occurrence of a dog filariid other than *Dirofilaria immitis* in the United States. *Journal of Parasitology* 42: 246–258.
- ORIHIEL, T. C., AND L. R. ASH. 1964. Occurrence of *Dirofilaria striata* in the bobcat (*Lynx rufus*) in Louisiana with observations on its larval development. *Journal of Parasitology* 50: 590–591.
- , AND P. C. BEAVER. 1965. Morphology and relationship of *Dirofilaria tenuis* and *Dirofilaria conjunctivae*. *American Journal of Tropical Medicine and Hygiene* 14: 1030–1043.
- PENCE, D. B., M. E. TEWES, AND L. L. LAACK. 2003. Helminths of the ocelot from southern Texas. *Journal of Wildlife Diseases* 39: 683–689.
- PRICE, D. L. 1962. Description of *Dipetalonema interstitium* n. sp. from the gray squirrel and *Dipetalonema llewellyni* n. sp. from the raccoon. *Proceedings of Helminthological Society of Washington* 29: 77–82.
- ROELKE-PARKER, M. E., L. MUNSON, C. PACKER, R. KOCK, S. CLEAVELAND, M. CARPENTER, S. J. O'BRIEN, A. POSPISCHIL, R. HOFMANN-LEHMANN, H. LUTZ, G. L. M. MWAMENGELE, M. N. MGASA, G. A. MACHANGE, B. A. SUMMERS, AND M. J. G. APPEL. 1996. A canine distemper virus epidemic in Serengeti lions (*Panthera leo*). *Nature* 379: 441–445.
- ROEMER, G. W., T. J. COONAN, D. K. GARCELON, C. H. STARBIRD, AND J. W. MCCALL. 2000. Spatial and temporal variation in the seroprevalence of canine heartworm antigen in the island fox. *Journal of Wildlife Diseases* 36: 723–728.
- SACKS, B. N., AND K. M. BLEJWAS. 2000. Effects of canine heartworm (*Dirofilaria immitis*) on body condition and activity of free-ranging coyotes (*Canis latrans*). *Canadian Journal of Zoology* 78: 1042–1051.
- , AND E. P. CASWELL-CHEN. 2003. Reconstructing the spread of *Dirofilaria immitis* in California coyotes. *Journal of Parasitology* 89: 319–333.
- SCOTT, M. E. 1988. The impact of infection and disease on animal populations: Implications for conservation biology. *Conservation Biology* 2: 40–56.
- SHEETS, R. G. 1972. A trap for capturing black-footed ferrets. *American Midland Naturalist* 88: 461–462.
- SMITH, J. L. 1980. Redescription of *Dipetalonema* (*Acanthocheilonema*) *procyonis* Price, 1955 (Nematoda: Filarioidea) from the raccoon. *Journal of Parasitology* 66: 333–336.
- THOMPSON, J. D., D. G. HIGGINS, AND T. J. GIBSON. 1994. CLUSTAL W: Improving the sensitivity of progressive multiple sequence alignment through sequence weighting, position specific gap penalties and weight matrix choice. *Nucleic Acids Research* 22: 4673–4680.
- THORNE, E. T., AND E. S. WILLIAMS. 1988. Disease and endangered species: The black-footed ferret as a recent example. *Conservation Biology* 2: 66–74.
- WARNER, R. E. 1968. The role of introduced diseases in the extinction of the endemic Hawaiian avifauna. *The Condor* 70: 101–120.
- WEBSTER, W. A., AND M. BEAUREGARD. 1964. *Dipetalonema mephitis* n. comb. (= *Microfilaria mephitis*: Webster and Beauregard, 1964) from the skunk, *Mephitis mephitis*. *Canadian Journal of Zoology* 43: 325–332.
- WEIMERSKIRCH, H. 2004. Diseases threaten Southern Ocean albatrosses. *Polar Biology* 27: 374–379.
- WEISSMAN, B. W. 1992. Raccoon heartworm causing a facial mass. *Southern Medical Journal* 85: 845–846.
- WINGFIELD, J. C., AND L. M. ROMERO. 2001. Adrenocortical responses to stress and their modulation in free-living vertebrates. In *Handbook of physiology: A critical, comprehensive presentation of physiological knowledge and con-*

cepts, B. S. McEwen and H. M. Goodman (eds.).
Oxford University Press, Oxford, pp. 211–234.

XIE, H., O. BAIN, AND S. A. WILLIAMS. 1994.
Molecular phylogenetic studies on filarial para-

sites based on 5S ribosomal spacer sequences.
Parasite 1: 141–151.

Received for publication 20 February 2007.