

## **DETECTION AND GENETIC CHARACTERIZATION OF PORCINE CIRCOVIRUS 2 ISOLATES FROM THE FIRST CASES OF POSTWEANING MULTISYSTEMIC AND WASTING SYNDROME IN WILD BOARS IN GREECE**

Authors: Sofia, Marina, Billinis, Charalambos, Psychas, Vassilios, Birtsas, Periklis, Sofianidis, George, et al.

Source: Journal of Wildlife Diseases, 44(4) : 864-870

Published By: Wildlife Disease Association

URL: <https://doi.org/10.7589/0090-3558-44.4.864>

---

BioOne Complete ([complete.BioOne.org](https://complete.BioOne.org)) is a full-text database of 200 subscribed and open-access titles in the biological, ecological, and environmental sciences published by nonprofit societies, associations, museums, institutions, and presses.

Your use of this PDF, the BioOne Complete website, and all posted and associated content indicates your acceptance of BioOne's Terms of Use, available at [www.bioone.org/terms-of-use](https://www.bioone.org/terms-of-use).

Usage of BioOne Complete content is strictly limited to personal, educational, and non - commercial use. Commercial inquiries or rights and permissions requests should be directed to the individual publisher as copyright holder.

---

BioOne sees sustainable scholarly publishing as an inherently collaborative enterprise connecting authors, nonprofit publishers, academic institutions, research libraries, and research funders in the common goal of maximizing access to critical research.

# DETECTION AND GENETIC CHARACTERIZATION OF *PORCINE CIRCOCIRUS 2* ISOLATES FROM THE FIRST CASES OF POSTWEANING MULTISYSTEMIC AND WASTING SYNDROME IN WILD BOARS IN GREECE

Marina Sofia,<sup>1</sup> Charalambos Billinis,<sup>1,7</sup> Vassilios Psychas,<sup>2</sup> Periklis Birtsas,<sup>3</sup> George Sofianidis,<sup>2</sup> Leonidas Leontides,<sup>4</sup> Nick Knowles,<sup>5</sup> and Vassiliki Spyrou<sup>6</sup>

<sup>1</sup> Laboratory of Microbiology and Parasitology, Faculty of Veterinary Medicine, University of Thessaly, Trikalon 224, 43100 Karditsa, Greece

<sup>2</sup> Laboratory of Pathology, Faculty of Veterinary Medicine, Aristotle University, 54124 Thessaloniki, Greece

<sup>3</sup> Hunting Federation of Macedonia and Thrace, Ethnikis Antistasis 173–175, 55134 Thessaloniki, Greece

<sup>4</sup> Laboratory of Epidemiology, Biostatistics and Economics of Animal Production, Faculty of Veterinary Medicine, University of Thessaly, Trikalon 224, 43100 Karditsa, Greece

<sup>5</sup> Institute for Animal Health, Pirbright Laboratory, Ash Road, Pirbright, Woking, Surrey, GU24 0NF, United Kingdom

<sup>6</sup> Department of Animal Production, Technological Educational Institution, 41110 Larissa, Greece

<sup>7</sup> Corresponding author (email: billinis@vet.uth.gr)

**ABSTRACT:** In 2002, postweaning multisystemic wasting syndrome (PMWS) was diagnosed in a European female wild boar (*Sus scrofa*), based on the detection of porcine circovirus 2 (PCV2) DNA in various organs, including the uterus, and on histopathologic lesions. This is the first detection of PCV2 DNA in the uterus of a wild boar. Three years later (2005), a wild boar <6–8 mo of age was found moribund. It presented wasting and dyspnea and finally died. PCV2 DNA was detected in tissue samples, and histopathologic lesions consistent with PMWS were observed. Both wild boars were from neighboring hunting areas in central Greece. Two PCV2 strains from the wild boars were genetically characterized and compared to other reported PCV2 sequences from wild boars and domestic pigs. The PCV-2 sequences from the wild boars in this study were closely related to each other and were grouped with two isolates from wild boars from Hungary. The phylogenetic analysis revealed that the virus might be transmitted between hunting areas. In addition, PCV2 may spread from domestic pigs to wild boars and vice versa.

**Key words:** PCV2, phylogenetic analysis, PMWS, porcine circovirus 2, postweaning multisystemic wasting syndrome, wild boar.

## INTRODUCTION

Porcine circovirus 2 (PCV2; *Circovirus*, *Circoviridae*; Hamel et al., 1998) is a small, icosahedral, nonenveloped virus that contains a single-stranded circular DNA genome of 1.76 kb (Tischer et al., 1982). This virus is the causative agent of postweaning multisystemic wasting syndrome (PMWS) in domestic pigs (Allan et al., 1998). The disease affects 5–12-wk-old piglets, occurs in herds that are usually in good health, and has a low morbidity but a relatively high mortality rate (Harding and Clark, 1997). The diagnosis of PMWS in domestic pigs is based on clinical signs (progressive weight loss, respiratory distress, diarrhea, and pallor of the skin), histopathologic lesions in lymphoid tissues (lymphocyte depletion, granulomatous inflammation, or both), and the presence of

PCV2 in these tissues (Sorden, 2000). Both PMWS-affected and non-affected pigs can be infected with PCV2 (Calsamiglia et al., 2002).

Wild boars (*Sus scrofa*) infected with PCV2 have been reported (Vicente et al., 2004; Knell et al., 2005; Csagola et al., 2006). A PCV2-antibody prevalence of 47% has been reported for wild boar sampled in Spain; antibody prevalence was highest in intensively managed populations rather than in those living in more natural conditions (Vicente et al., 2004). In addition, the incidence of PCV2 DNA in tissue samples from wild boars sampled in Hungary was 20.5% (Csagola et al., 2006).

Histopathologic lesions consistent with PMWS have been reported in wild boars (Ellis et al., 2003; Schulze et al., 2004; Vicente et al., 2004), and these lesions have been associated with the detection of

PCV2 DNA in tissues (Toplak et al., 2004; Vicente et al., 2004). Histopathologic lesions reported in the above-mentioned cases were identical to those observed in PMWS-affected domestic pigs; however, to date PMWS has been reported only from wild boars over 6 mo of age (Schulze et al., 2004; Vicente et al., 2004).

The genome of PCV2 includes two major open reading frames (ORFs) that are oriented in opposite directions. The ORF1 is on the viral strand and encodes the Rep-associated proteins (Rep, Rep') with the Rep protein comprising 314 amino acids (aa) (Mankertz et al., 1997), whereas ORF2 is located on the complementary strand and encodes the capsid protein (CapP) of 233 aa (Nawagitgul et al., 2000). Different strains of PCV2 display greater than 90% nucleotide identity (Fenaux et al., 2000), and while ORF1 is very conserved, ORF2 is a more variable region (Fenaux et al., 2000). Genomic sequences of PCV2 isolates from domestic pigs, with or without PMWS, are closely related (De Boisseson et al., 2004). A number of PCV2 strains have been genetically characterized from wild boars with subclinical infection (Knell et al., 2005; Csagola et al., 2006), but only one has been characterized from a PMWS case (Schulze et al., 2004).

The objectives of this study were: 1) to determine whether PCV2 infects and causes PMWS in wild boars in Greece and, if infected; 2) to genetically characterize PCV2 strains from wild boars in Greece and phylogenically determine their relationship with other previously sequenced PCV2 strains derived from domestic swine and wild boars.

## MATERIALS AND METHODS

### Field cases

In 2002, a pregnant female wild boar was found dead in a hunting reserve (5 km<sup>2</sup>) in central Greece (39°48'N, 21°17'E). Using an isothermal container with ice packs, the Hunting Federation submitted to our laboratory frozen tissue samples of spleen, lung,

liver, and uterus (including two embryos). In 2005, a male wild boar was found moribund in an adjacent hunting reserve (479 km<sup>2</sup>) in central Greece (39°48'N, 21°17'E). It was in a poor body condition and had dyspnea. The wild boar died during transfer to the Veterinary School of Thessaly, Greece. It was <6–8 mo old, based on tooth eruption and wear pattern (Boitani and Mattei, 1992). Necropsy was performed and tissue samples of lung, heart, liver, kidney, intestine, and lymph nodes (submandibular, bronchial, mesenteric, superficial inguinal) were collected. All samples were stored at –70 C for PCR, except for portions that were fixed in neutral 10% formalin for histopathology. Bacteriologic examinations were not performed. The two hunting reserves are adjacent and movement of wild boar may occur between them.

### DNA and RNA extraction

DNA was isolated from 10 mg of each tissue sample using a commercial extraction DNA isolation cell and tissue kit (Puregene, Gentra Systems, Minneapolis, Minnesota, USA) according to the manufacturer's instruction. The RNA was isolated from 10 mg of tissue samples using a commercial extraction RNA isolation cell and tissue kit (Puregene, Gentra Systems).

### Polymerase chain reaction (PCR)

The primers and the PCR conditions for amplification of the PCV2 genome, and for detection of PCV1 (Mankertz et al., 2000), PCV2 (Mankertz et al., 2000), porcine parvovirus (PPV; Kim et al., 2003), and porcine reproductive and respiratory syndrome virus (PRRSV; Gilbert et al., 1997) were performed as previously described. Ten microliters of each PCR product were analyzed by electrophoresis on a 2% agarose gel and stained with ethidium bromide (0.5 µg/ml). A 100-base pair (bp) DNA ladder (Invitrogen, Paisley, UK) was analyzed on the same gel to serve as a size marker.

### Histopathologic examination

Tissues samples were fixed in neutral buffered formalin 10%, embedded in paraffin, sectioned at 4–6 µm, and stained with hematoxylin and eosin (H&E).

### Sequence analysis

A virus strain was genetically characterized from each wild boar. The PCR products were gel-purified (QIAquick Gel Extraction Kit, Qiagen Ltd., West Sussex, UK) and sequence

analysis was performed twice on the complete viral genome (MWG Biotech, Ebersberg, Germany) using forward and reverse PCR primers. All samples were analyzed twice, and only high-quality sequences were used. The viruses were designated by the codes GRE-WB1 (wild boar; GenBank accession no. DQ915583) and GRE-WB2 (female wild boar; GenBank accession no. DQ915584). The GRE-WB1 was detected from inguinal lymph nodes while GRE-WB2 was detected from the uterus. Nucleotide sequences from eighteen PCV2 isolates were retrieved from the GenBank. A phylogenetic and molecular evolutionary analysis was performed on the complete viral genome and the ORF2 gene, using the MEGA 3.1 program (Kumar et al., 2004). Neighbor-joining trees were constructed from a difference matrix employing the Kimura 2-parameter correction. One thousand bootstrap pseudo-replicates were used to test the branching (shown as percentages). The trees were outgroup-rooted using four PCV1 sequences.

## RESULTS

For the male wild boar, PCV2 DNA was detected in lung, heart, intestine, and lymph nodes. For the female wild boar, PCV2 DNA was detected in spleen, lung, liver, and uterus, but not in the two embryos. Both wild boars were negative for PCV1 and PPV DNA; however, the female wild boar was positive for PRRSV RNA in the lung.

The male wild boar was in a poor body condition. Gross lesions consisted of moderate enlargement of the submandibular, superficial inguinal, bronchial, and mesenteric lymph nodes and mildly rubbery lungs. On histologic examination, various degrees of lymphocyte depletion, macrophage infiltration, and occasional syncytial cell formation were detected in lymphoid organs (Fig. 1); these lesions are typical of PMWS. In the lungs, interstitial pneumonia with congestion and edema was seen (Fig. 2). Focal or multifocal areas of interstitial nephritis were observed (Fig. 3). Periportal mononuclear cell infiltration as well as collagen fibers were detected in the liver. In the heart, mild to moderate focal interstitial myocarditis,

consisting mainly of perivascular accumulations of macrophages and lymphocytes, was also observed (Fig. 4). In the female wild boar, lesions were seen in spleen, lungs, and liver and were more severe. In particular, the lungs were enlarged and rubbery, and histopathologically severe interstitial pneumonia was detected. Additionally, various degrees of lymphocyte depletion were seen in the spleen, while in the liver, periportal mononuclear cell infiltration was observed throughout the tissue.

The PCV2 sequences recovered from the two wild boars (GRE-WB1, GRE-WB2) were 1,767 bp and lacked the same nucleotide at position 1040–1042 on the 1768 nucleotide strand (Fenaux et al., 2000). Phylogenetic analysis was performed on the complete viral genome of 18 PCV2 isolates from domestic and wild pigs, including those described in this study (Fig. 5). The PCV2 strains formed two groups. The Greek strains from wild boars were closely related (98.5% nucleotide identity) and were clustered with two isolates (WB-H-1, WB-H-6) from wild boars from Hungary (98.6–99.3% nucleotide similarity). The remaining strains from wild boars formed a separate cluster and displayed 94.8–98.9% nucleotide identity. Isolates did not cluster according to their geographic origin. Phylogenetic analysis on the ORF2 gene resulted in a phylogenetic tree similar to the one mentioned above.

## DISCUSSION

Previous studies have shown that PCV2 can infect wild boars (*Sus scrofa*) and that infection can lead to PMWS (Schulze et al., 2004; Vicente et al., 2004). Results from serologic studies indicate that PCV2 antibody prevalence is lower in free-living wild boars than in domestic pigs (Vicente et al., 2004). Factors such as living conditions, age of infection, extent of PCV2 shedding, early weaning, and vaccinations (Vicente et al., 2004), factors that



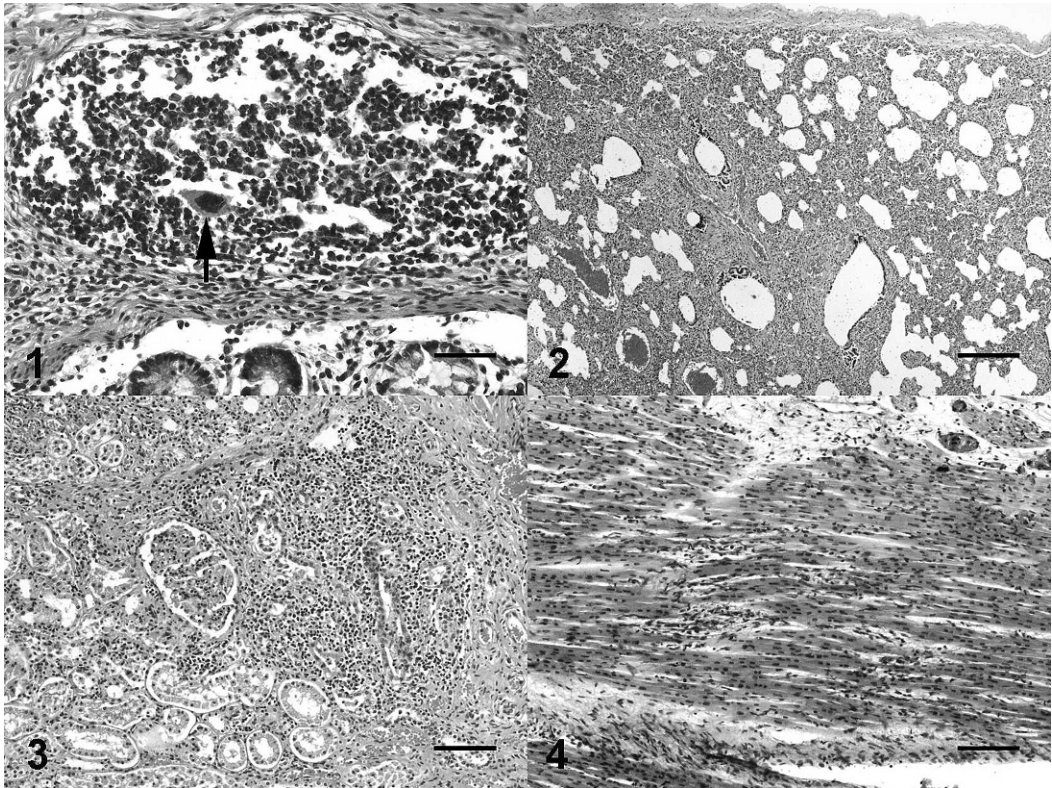


FIGURE 1. Intestine: Peyer's patches. Depletion of lymphocytes, infiltration of large macrophages, and syncytial cell (arrow) formation. H&E, Bar = 50  $\mu$ m. FIGURE 2. Lung: Moderate interstitial pneumonia accompanied by hyperemia. H&E, Bar = 250  $\mu$ m. FIGURE 3. Kidney: Multifocal to diffuse interstitial mononuclear cell infiltration. H&E, Bar = 100  $\mu$ m. FIGURE 4. Heart: Multifocal interstitial myocarditis. H&E, Bar = 100  $\mu$ m.

may enhance the spread of the virus in commercial swine, may not be applicable to wild boar populations.

This is the first report of PMWS in wild boars in Greece, further establishing the already reported view that histopathologic lesions consistent with PMWS occur in European wild boar (Toplak et al., 2004; Vicente et al., 2004). Although no clinical signs have been recorded in wild boars in any of the previous studies, we observed wasting and dyspnea in one wild boar that was <6–8 mo old. Histopathologic lesions observed in this animal were identical to those described for PMWS in domestic pigs and wild boars (Schulze et al., 2004; Toplak et al., 2004; Vicente et al., 2004), and PCV2 was present in tissue from this animal. Thus, the diagnosis of PMWS in

this wild boar fulfilled the three common criteria (Sorden, 2000). Prior to this case, lesions had been detected only in wild boars that were older than the average age (2–4 mo) of domestic pigs at which PMWS is most often observed (Segales and Domingo, 2002). This report of PMWS in a wild boar reveals that the virus infects young wild boars and that infection can result in the development of PMWS.

The occurrence of PMWS in a female wild boar is also in accordance with previous reports (Schulze et al., 2004). The diagnosis was based on histopathologic lesions and the detection of PCV2 in tissues. We cannot conclude that death was caused by PMWS because only tissue samples were submitted to our laboratory

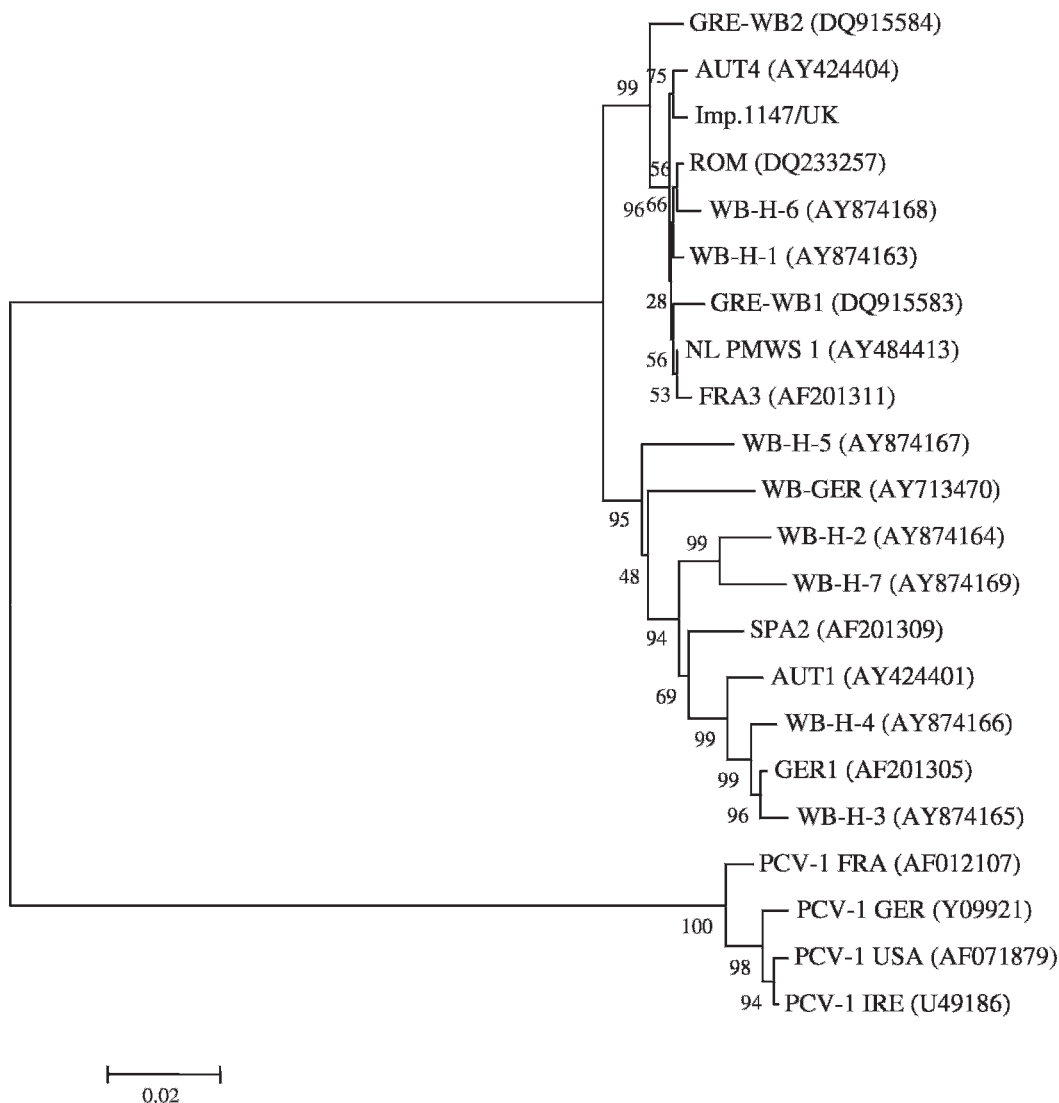


FIGURE 5. Phylogenetic analysis in the complete viral genome of 18 PCV2 isolates and four PCV1 as an outgroup. GenBank accession numbers and geographic origins are shown (AUT = Austria; FRA = France; GER = Germany; GRE = Greece; H = Hungary; IRE = Ireland; NL = The Netherlands; ROM = Romania; SPA = Spain; UK = United Kingdom). Isolates from wild boars are indicated as WB.

and clinical signs were not recorded. In the female wild boar, PRRSV RNA was also detected. It is possible that the severity of histopathologic lesions was the result of co-infection with PCV2 and PRRSV. In domestic pigs, PCV2 is the primary cause of PMWS, but concurrent PRRSV infection leads to more severe disease forms (Harms et al., 2001).

To our knowledge, this is the first report

of PCV2 DNA detection in the uterus of a female wild boar with PMWS. This finding was not expected, and as a result, tissue samples for histopathology were not collected. Viral DNA was not present in the fetuses but, in a previous experimental study, it was shown that PCV2 can infect late-term fetuses in domestic pigs via the placenta (Park et al., 2005). Our findings suggest that it is possible that PCV2 may

cause reproductive disorders in wild boars similar to those already described in domestic pigs (O'Connor et al., 2001). The possibility that PCV2 is a causative agent of reproductive problems in wild boars, and that it may be vertically transmitted, should be further investigated.

Our first case of PMWS in wild boars occurred in 2002, and the second case was reported in 2005. The two PMWS cases were from neighbouring hunting reserves in the same prefecture. The high nucleotide identity of the viruses associated with these cases probably reflects movement of the wild boars between these populations, and the nucleotide variation of these isolates is probably the result of point mutations.

The phylogenetic analysis in the ORF2 gene and in the complete viral genome showed that isolates from wild boars and domestic pigs are closely related. This may indicate the transmission of PCV2 from domestic to wild boars, or vice versa. Wild boars may be carriers of PCV2 infection for domestic pigs in regions where domestic pig farms are neighbor to hunting areas. At present, a reservoir of the virus has not been detected that would serve as a common source of both wild boar and domestic pig PCV2 infections. It is possible that wild boars may serve as a natural reservoir of the virus, but further studies are needed in order to clarify the extent of PCV2 infection in wild boar populations and to better understand the epidemiology of this virus.

#### ACKNOWLEDGMENTS

This project was co-funded by the European Social Fund and National Treasurers – ΕΠΕΑΕΚ II- ΙΡΑΚΛΙΤΟΣ.

#### LITERATURE CITED

- ALLAN, G. M., F. MCNEILLY, S. KENNEDY, B. DAFT, E. CLARK, J. ELLIS, D. HAINES, B. MEEHAN, AND B. ADAIR. 1998. Isolation of porcine circovirus-like viruses from pigs with a wasting disease in the USA and Europe. *Journal of Veterinary Diagnostic Investigation* 10: 3–10.
- BOITANI, L., AND L. MATTEI. 1992. Aging wild boar by tooth eruption. *Ongules/Ungulates* 91: 419–421.
- CALSAMIGLIA, M., J. SEGALÉS, J. QUINTANA, C. ROSELL, AND M. DOMINGO. 2002. Detection of porcine circovirus types 1 and 2 in serum and tissue samples of pigs with and without postweaning multisystemic wasting syndrome. *Journal of Clinical Microbiology* 40: 1848–1850.
- CSAGOLA, A., S. KECSKEMETI, G. KARDOS, I. KISS, AND T. TUBOLY. 2006. Genetic characterization of type 2 porcine circoviruses detected in Hungarian wild boars. *Archives of Virology* 151: 495–507.
- DE BOISSESON, C., V. BEVEN, L. BIGARRE, R. THIERY, N. ROSE, E. EVENO, F. MADEC, AND A. JESTIN. 2004. Molecular characterization of Porcine circovirus type 2 isolates from post-weaning multisystemic wasting syndrome-affected and non-affected pigs. *Journal of General Virology* 85: 293–304.
- ELLIS, J., M. SPINATO, C. YONG, K. WEST, F. MCNEILLY, B. MEEHAN, S. KENNEDY, E. CLARK, S. KRAKOWKA, AND G. ALLAN. 2003. Porcine circovirus 2-associated disease in Eurasian wild boar. *Journal of Veterinary Diagnostic Investigation* 15: 364–368.
- FÉNAUX, M., P. G. HALBUR, M. GILL, T. E. TOTH, AND X. J. MENG. 2000. Genetic characterization of type 2 porcine circovirus (PCV-2) from pigs with postweaning multisystemic wasting syndrome in different geographic regions of North America and development of a differential PCR-restriction fragment length polymorphism assay to detect and differentiate between infections with PCV-1 and PCV-2. *Journal of Clinical Microbiology* 38: 2494–2503.
- GILBERT, S. A., R. LAROCHELLE, R. MAGAR, H. J. CHO, AND D. DERECT. 1997. Typing of porcine reproductive and respiratory syndrome viruses by a multiplex PCR assay. *Journal of Clinical Microbiology* 35: 264–267.
- HAMEL, A. L., L. L. LIN, AND G. P. NAYAR. 1998. Nucleotide sequence of porcine circovirus associated with postweaning multisystemic wasting syndrome in pigs. *Journal of Virology* 72: 5262–5267.
- HARDING, J. C., AND E. G. CLARK. 1997. Recognizing and diagnosing postweaning multisystemic wasting syndrome (PMWS). *Journal of Swine Health and Production* 5: 201–203.
- HARMS, P. A., S. D. SORDEN, G. P. HALBUR, S. R. BOLIN, K. M. LAGER, I. MOROZOV, AND P. S. PAUL. 2001. Experimental reproduction of severe disease in CD/CD pigs concurrently infected with type 2 porcine circovirus and PRRSV. *Veterinary Pathology* 38: 528–539.
- KIM, J., D. U. HAN, C. CHOI, AND C. CHAE. 2003. Simultaneous detection and differentiation between porcine circovirus and porcine parvovirus in boar semen by multiplex semi-nested poly-

- merase chain reaction. *Journal of Veterinary Medical Science* 65: 741–744.
- KNELL, S., H. WILLEMS, B. HERTRAMPF, AND G. REINER. 2005. Comparative genetic characterization of Porcine Circovirus type 2 samples from German wild boar populations. *Veterinary Microbiology* 109: 169–177.
- KUMAR, S., K. TAMURA, AND M. NEI. 2004. MEGA 3.1: Integrated software for molecular evolutionary genetics analysis and sequence alignment. *Briefings in Bioinformatics* 5: 150–163.
- MANKERTZ, A., F. PERSSON, J. MANKERTZ, G. BLAESS, AND H. J. BUHK. 1997. Mapping and characterization of the origin of DNA replication of porcine circovirus. *Journal of Virology* 71: 2562–2566.
- , M. DOMINGO, J. M. FOLCH, P. LECANN, A. JESTIN, J. SEGALÉS, B. CHMIELEWICZ, J. PLANA-DURAN, AND D. SOIKE. 2000. Characterization of PCV-2 isolates from Spain, Germany and France. *Virus Research* 66: 65–77.
- NAWAGITGUL, P., I. MOROZOV, S. R. BOLIN, P. A. HARMS, S. D. SORDEN, AND P. S. PAUL. 2000. Open reading frame 2 of porcine circovirus type 2 encodes a major capsid protein. *Journal of General Virology* 81: 2281–2287.
- O'CONNOR, B., H. GAUVREAU, K. WEST, J. BOGDAN, M. AYROUD, E. G. CLARK, C. KONOBY, G. ALLAN, AND J. A. ELLIS. 2001. Multiple porcine circovirus 2-associated abortions and reproductive failure in a multisite swine production unit. *Canadian Veterinary Journal* 42: 551–553.
- PARK, J. S., J. KIM, Y. HA, K. JUNG, C. CHOI, J. K. LIM, S. H. KIM, AND C. CHAE. 2005. Birth abnormalities in pregnant sows infected intranasally with porcine circovirus 2. *Journal of Comparative Pathology* 132: 139–144.
- SCHULZE, C., J. SEGALÉS, G. NEUMANN, A. HLINAK, M. CALSAMIGLIA, AND M. DOMINGO. 2004. Identification of postweaning multisystemic wasting syndrome in European wild boar (*Sus Scrofa*). *Veterinary Record* 154: 694–696.
- SEGALÉS, J., AND M. DOMINGO. 2002. Postweaning multisystemic wasting syndrome (PMWS) in pigs. *Veterinary Quarterly* 24: 109–124.
- SORDEN, S. D. 2000. Update on porcine circovirus and postweaning multisystemic wasting syndrome. *Journal of Swine Health and Production* 8: 133–136.
- TISCHER, I., H. GELDERBLUM, W. VETTERMANN, AND M. A. KOCH. 1982. A very small porcine virus with circular single-stranded DNA. *Nature* 91: 64–66.
- TOPLAK, I., J. GROM, P. HOSTNIK, AND D. BARLIC-MAGANJA. 2004. Phylogenetic analysis of type 2 porcine circoviruses identified in wild boar in Slovenia. *Veterinary Record* 155: 178–180.
- VICENTE, J., J. SEGALÉS, U. HOFLE, M. BALASCH, J. PLANA-DURAN, M. DOMINGO, AND C. GORTAZAR. 2004. Epidemiological study on porcine circovirus type 2 (PCV2) infection in the European wild boar (*Sus scrofa*). *Veterinary Research* 35: 243–253.

Received for publication 18 June 2007.